

# Insights into the role of endoscopic ultrasound-guided vascular therapy

Roberto Oleas and Carlos Robles-Medrandá 

*Ther Adv Gastrointest Endosc*

2019, Vol. 12: 1–9

DOI: 10.1177/

2631774519878282

© The Author(s), 2019.  
Article reuse guidelines:  
[sagepub.com/journals-permissions](https://sagepub.com/journals-permissions)

**Abstract:** Gastroesophageal variceal bleeding is a life-threatening complication in patients with liver cirrhosis and portal hypertension. The endoscopic injection of cyanoacrylate is considered as the first-line alternative for gastric varices treatment; however, the incidence of adverse events supports the endoscopic ultrasound-guided approach. Endoscopic ultrasound-guided interventions are a safe and feasible technique for the injection of sclerosants, cyanoacrylate, thrombin, and the deployment of coils into targeted vessels. This review article aims to offer an overview of the role of endoscopic ultrasound-guided vascular therapy and present the available data regarding endoscopic ultrasound-guided management of gastrointestinal bleeding and other vascular therapies. The available data have shown the superiority of endoscopic ultrasound-guided endovascular therapy over the endoscopic technique, which supports the implementation of endoscopic ultrasound-guided therapy in therapeutical algorithms and guidelines. Regarding whether injecting cyanoacrylate, the deployment of coils, or combined therapy, we recommend the endoscopic ultrasound-guided combined therapy in patients with gastric varices due to the high eradication rate with lower rebleeding and reintervention rates. Multicenter worldwide studies are required to confirm the actual clinical applicability of endoscopic ultrasound-guided endovascular therapy and establish treatment algorithms. Endoscopic ultrasound offered a safe and effective alternative in the management of variceal and nonvariceal gastrointestinal bleeding, with the implementation of new diagnostic and treatment options for various gastrointestinal conditions, representing a new territory for research and development.

**Keywords:** endoscopic ultrasonography, endosonography, gastric variceal bleeding, gastrointestinal hemorrhage, portal vein

Received: 24 April 2019; revised manuscript accepted: 4 September 2019.

## Introduction

Endoscopic ultrasound (EUS) indications have expanded from diagnostic modalities to therapeutic purposes in various fields, especially in the area of endovascular therapy. In the beginning, EUS was considered a supplementary diagnostic method, which was available only in a few tertiary centers, but now this tool has become more accessible worldwide.

The necessity of developing less invasive alternatives to surgical or radiologic interventions has contributed to the development of EUS-guided vascular therapy. EUS offers real-time imaging with the possibility of accessing vascular sites that

would otherwise be inaccessible, or less accessible, using conventional techniques. The advantage of targeting specific vascular sites for the deployment or injection of tools as well as the implementation of therapeutic procedures from interventional radiology has become the main reason for the development of new EUS-guided vascular techniques.

For many decades, interventional radiologists developed selective angiographic embolization and transjugular intrahepatic portosystemic shunts (TIPS) for refractory gastrointestinal hemorrhage. However, EUS is superior to interventional radiology techniques because the gastrointestinal tract is

Correspondence to:  
**Carlos Robles-Medrandá**  
Gastroenterology and  
Endoscopy Division,  
Instituto Ecuatoriano de  
Enfermedades Digestivas  
(IECED), Av. Abel Romeo  
Castillo y Av. Juan Tanca  
Marengo, Torre Vitalis,  
Mezanine 3, Guayaquil  
090505, Ecuador  
[carlosoakm@yahoo.es](mailto:carlosoakm@yahoo.es)

**Roberto Oleas**  
Gastroenterology and  
Endoscopy Division,  
Instituto Ecuatoriano de  
Enfermedades Digestivas  
(IECED), Guayaquil,  
Ecuador

located more proximal to vascular structures in the mediastinum and abdomen (such as the aorta, celiac axis, portal, and hepatic vein; mesenteric vessels; and aberrant vascular shunts), offering safer and more feasible techniques.

EUS-guided interventions are promising methods that have demonstrated their safety and feasibility in various experimental and clinical studies that have evaluated the injection of sclerosants, cyanoacrylate, thrombin, and the deployment of coils using an EUS fine-needle aspiration into targeted vessels. This review article aims to offer an overview of the emerging role of EUS-guided vascular therapy and present the available evidence regarding EUS-guided management of gastrointestinal bleeding and other vascular therapies.

### Gastrointestinal bleeding

Gastroesophageal varices (GOV) are a complication of liver cirrhosis and represent the development of portosystemic collateral vessels as a consequence of portal hypertension. The frequency of GOV is associated with the severity of the disease, ranging from 40% in those patients with Child A and raise to 85% in those with Child D.<sup>1</sup>

### Variceal bleeding

Gastroesophageal variceal bleeding is a common and life-threatening complication with an annual bleeding rate of 5–15% and a 6-week mortality rate of 20%.<sup>2</sup> Even though the bleeding ceases spontaneously in 40–50% of patients, early rebleeding can occur in 30–40% of patients, with 40% of patients rebleeding within the first 5 days.<sup>3</sup> The expansion of therapeutic interventions has improved the management and mortality rate associated with acute variceal bleeding; however, bleeding remains as one leading cause of death in cirrhotic patients.<sup>2</sup>

Endoscopy is the standard of care for the detection and grading of esophageal varices, with endoscopic band ligation considered as the most appropriate treatment of bleeding and eradication of varices. However, EUS is useful in the evaluation of periesophageal veins, in which the presence of severe periesophageal collateral veins and large perforating veins correlates with bleeding risk and recurrence.<sup>4–6</sup>

In one study, EUS-guided injection of sclerosants into periesophageal veins was evaluated in five patients, showing no recurrence of bleeding during

15 months of follow-up; however, 2.2 sessions were necessary for achieving obliteration.<sup>7</sup> A randomized controlled trial comparing endoscopic *versus* EUS-guided sclerotherapy into collateral veins showed that EUS-guided sclerotherapy is as safe and effective as endoscopic sclerotherapy; however, there was no statistical difference in the amount of sclerosants and number of sessions to achieve eradication or recurrence of varices.<sup>8</sup>

Further studies comparing standard endoscopic therapies *versus* EUS-guided deployment of coils, cyanoacrylate injection, or combined treatment are required to demonstrate the real clinical effect in obliterating periesophageal collateral veins and large perforating veins for the eradication of esophageal varices.

### Gastric varices

Endoscopic classification of gastric varices (GV) according to their location in the stomach and involvement of the esophagus can be performed using Sarin's classification. GOV type 1 are the most common type, arising from the lesser curvature of the stomach and extending above the gastroesophageal junction as esophageal varices, accounting for 74% of all GV. GOV type 2 are located in the gastric fundus and continue toward the esophagus. Isolated gastric varices (IGV) type 1 arise only in the gastric fundus and occur independently of esophageal varices and have the highest incidence of bleeding, whereas IGV type 2 are ectopic varices and can appear elsewhere in the stomach, such as the gastric body or antrum.<sup>9</sup>

Bleeding from GV is associated with a high mortality rate, with the highest risk from the first hemorrhage in those patients with large varices or decompensated cirrhosis.<sup>10</sup> Band ligation or sclerotherapy of GV has inferior hemostasis and higher rebleeding rates than endoscopic injection of cyanoacrylate.<sup>11,12</sup> However, the endoscopic technique is associated with severe adverse events, mainly pulmonary or systemic embolisms, bleeding ulcers from the injection site, peritonitis, needle impaction, and even death. In addition, the injection of cyanoacrylate carried out by direct visualization using standard gastroscopes has been related to damage of the working channel of the endoscope.<sup>13–18</sup>

Likewise, endoscopic therapy via cyanoacrylate injection is challenging in the setting of severe hemorrhage due to impaired visualization, a

limitation overcome with the implementation of EUS and the Doppler effect. EUS-guided vascular therapy has the advantage of precisising the target of the varix lumen or the afferent feeder veins. Initial studies described the endoscopic injection of embolization glue within varix. However, EUS-guided vascular therapy allows some modification in the injection technique, in which glue can be injected directly within the feeder vessel of GV, for example, the left gastric vein.<sup>19</sup> Also, EUS-Doppler offers a real-time evaluation of the vessel flow, a necessary finding to confirm varix obliteration.

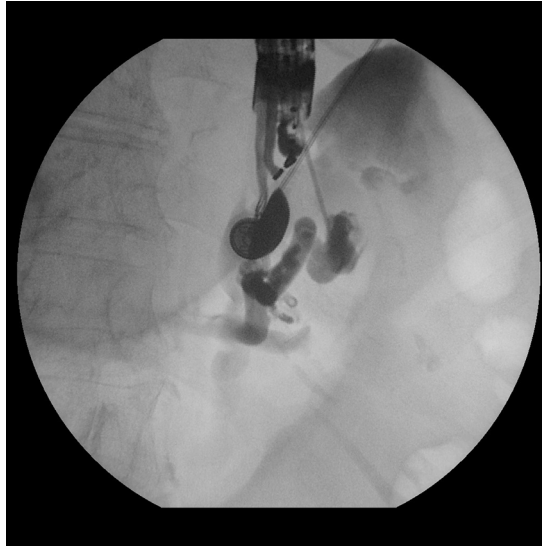### *Endosonographic varicealography*

Although EUS-guided endovascular therapy has shown promising results, interventions in patients with a vascular shunt can be catastrophic. Endosonographic varicealography (EV) provides several benefits during EUS vascular therapy. First, it provides endoscopists a technique to classify varices into type I (localized) and type II (diffuse), following the distribution of the feeder vessels. Type I varices are formed by a single large feeder vessel; meanwhile, type II are formed by a network of vessels within the gastric wall with multiple communications between them.<sup>20</sup> Second, the addition of systematic EV facilitates the therapeutic decision-making and ensures procedural safety, decreasing the risk of embolization secondary to accident glue injection into efferent vessels. EV offers the benefit of ruling out portosystemic shunts, which contraindicate the injection of cyanoacrylate due to a higher risk of embolization (Figure 1). Also, EV evaluates the anatomy of the splenic vein and avoids the exacerbation of portal hypertension secondary to the embolization of this vein.

In the setting of active hemorrhage, EV may identify the bleeding vessels for the assessment and targeting of the obliteration. Other benefits are the confirmation of the directional flow relative to varix (afferent or efferent), varix diameter, and confirmation of flow absence after obliteration.<sup>19</sup> However, fluoroscopy availability in the endoscopy setting, contraindication, or allergy to contrast agents and increase in procedure time and cost are still situations to consider for EV implementation.

### **EUS-guided glue injection**

Endoscopic therapy with cyanoacrylate injection is considered the first-line alternative for GV treatment and TIPS as the second alternative after failed cyanoacrylate injection or balloon



**Figure 1.** Left gastric vein shunt detected during endosonographic varicealography before EUS-guided endovascular therapy. EUS, endoscopic ultrasound.

deflation in accordance with the International Consensus in Portal Hypertension Workshop held in 2015 (Baveno VI).<sup>21</sup> Despite the high eradication rate of endoscopic cyanoacrylate injection,<sup>22</sup> complications such as the high incidence of pulmonary embolism<sup>23</sup> and the high risk of systemic embolization, sepsis, and endoscopic working channel occlusion are strong consideration points and the rationale for supporting the EUS-guided approach.

The EUS-guided cyanoacrylate injection is superior over the endoscopic technique because of several advantages: (1) the identification of the afferent feeder vessel, which allows direct delivery, thereby (2) potentially decreasing the amount of glue injected and therefore (3) reducing the risk of glue embolization, and also, (4) the confirmation of the obliteration of the GV by EUS color Doppler. The localization and approach of the feeder vessel are difficult, time-consuming, and require additional training; however, it has shown several benefits, mainly in the safety of the procedure due to the fewer amount of glue needed for obliteration.<sup>22,24</sup>

Injection of embolization glue, such as 2-octyl-cyanoacrylate and *N*-butyl-cyanoacrylate, has been described and compared in several studies, showing similar hemostasis effectiveness and prevention of rebleeding in patients. The later requires dilution with Lipiodol, a component that

enables fluoroscopic visualization of the injected vessel and is useful for the identification of pulmonary embolism on chest X-ray, especially in asymptomatic cases; although if embolism is highly suspicious, computed tomography is necessary for confirmation. A disadvantage of this product is that it forms a more viscous solution that might be more difficult to inject.

Conversely, 2-octyl-cyanoacrylate has a longer polymerization time, offering a longer injection time and decreasing the risk for glue impaction in the needle, the injection site, or the working channel of the scope.

### **EUS-guided coil embolization**

The deployment of intravascular embolization coils under direct EUS visualization has demonstrated a GV eradication rate of 75% when used as monotherapy.<sup>25</sup> These metal coils are covered with synthetic, stainless steel fibers, which induce variceal thrombosis and obliteration. These embolization coils are advanced through the fine-needle aspiration using the stylet to push them. Most coils are deployed through a 19G needle (up to 0.035-in coils) and smaller coils (0.018-in coils) are available for deployment through 22G.<sup>19,23,25-27</sup>

There are no reports of embolization secondary to deployment of coils. This complication could be possible if the diameters of the coils are less than that of the varix; thus, the size of the coil chosen must be larger than 120% of the varix diameter and injected in the direction of the portal vein (in the blood-outflowing trajectory). There is, however, a risk of perforation, bleeding, and coils extrusion that might be minimized by placing the needle tip on the opposite wall of varix.<sup>19</sup>

A multicenter trial comparing EUS-guided coiling *versus* EUS-guided cyanoacrylate injection in 30 patients favored coiling because the risk of coil migration and pulmonary coil embolism was very low compared with a 58% rate of adverse events in the cyanoacrylate group, pointing out that most were asymptomatic pulmonary embolism from glue injection, with little clinical significance. Another benefit of coiling was that 82% of patients achieved a complete obliteration in one session; however, no statistically significant difference was noted in regard to the obliteration rate between both techniques (95% for cyanoacrylate *versus* 91% for coiling).<sup>23</sup> Also, 18% of patients, in whom complete obliteration is not

achieved with EUS-guided coiling alone, might benefit for novel approaches such as the EUS-guided combined therapy with embolization coils and cyanoacrylate injection.

EUS-guided deployment of coils is limited by the technical difficulty of delivering various coils within the varix lumen and the cost of the procedure when more significant numbers of coils are required for varix obliteration.<sup>23</sup> Right now, EUS-guided coiling for the treatment of GV is a novel procedure with data limited to few studies; large randomized multicenter trials are needed to compare the clinical benefits of EUS-coiling over the EUS-guided injection of cyanoacrylate.

### **EUS-guided glue and coil combination therapy**

The EUS-guided deployment of coils in combination with cyanoacrylate injection has demonstrated to reduce the risk of glue embolization because embolization coils function as a scaffold to retain the glue within varix. Moreover, a lesser amount of cyanoacrylate is required in the combined technique to achieve obliteration of the varices.

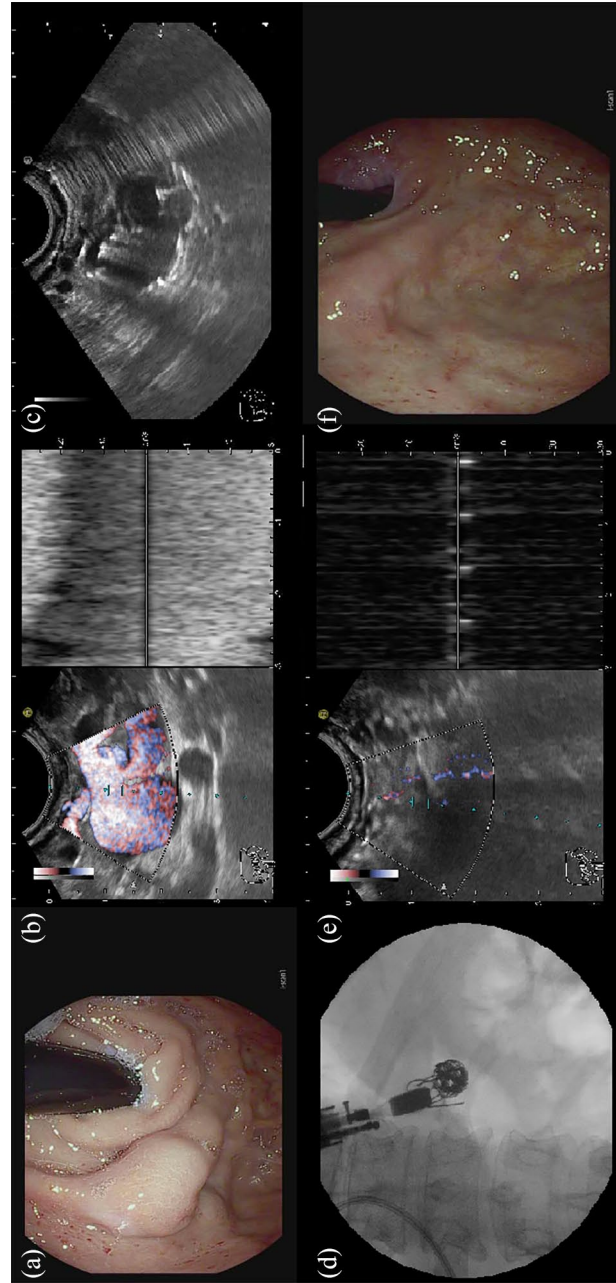
The combined therapy in the afferent portion of the feeder vessels has reported high efficacy and safety, with a 100% technical success and complete variceal obliteration in 96.6% of cases and immediate disappearance of varix in 80% of patients.<sup>19</sup>

In a retrospective study of 152 patients with gastric fundal varices in whom EUS-guided combined deployment of coils and cyanoacrylate injection was performed, 93% achieved a complete obliteration rate evaluated via EUS; however, these data were driven from 100 individuals in whom EUS was available during follow-up.<sup>28</sup>

In another recent randomized clinical trial from our group, we found that EUS-combined therapy was superior over EUS-coiling alone in terms of rebleeding and reintervention rates during follow-up.<sup>29</sup> Figure 2 summarizes the procedure steps for EUS-guided GVs obliteration, with the advantage of EUS-Doppler for flow and obliteration confirmation (Figure 1(b) and (e)).

### **Primary prophylaxis of GV bleeding**

Although primary prevention for GV bleeding has not been established in current guidelines,



**Figure 2.** (a) Endoscopic image of a large gastroesophageal varices type II with the indication for primary prophylaxis. (b) Endoscopic ultrasound image with color Doppler before obliteration. (c) Endoscopic ultrasound-guided deployment of coils via a 19G fine-needle aspiration within the feeder vessel. (d) Fluoroscopic image with the deployment of coils within the feeder vessel. (e) Endoscopic ultrasound with color Doppler after the treatment with combined therapy. (f) Immediate disappearance of varix after the endovascular intervention.

there are studies in which GV with a high risk of first bleeding (a gastric varix diameter >20 mm, an MELD (Model for End-Stage Liver Disease) score >17, and presence of portal hypertensive gastropathy) were obliterated with EUS-guided endovascular procedures.<sup>19,24,28</sup>

The mortality rate from first variceal bleeding within 6 weeks is as high as 20%.<sup>2</sup> Despite the controversy and lack of consensus about the role of GV primary prophylaxis, Mishra and colleagues<sup>30</sup> described a 2-year probability of bleeding of 13% in those patients with IGV1 and GOV2 treated with endoscopic injection of cyanoacrylate compared with 45% in those patients in whom no intervention was instituted and 28% in those taking beta-blockers.

In another study in which 40 patients were treated with combined EUS coiling and cyanoacrylate injection for primary prophylaxis of GV, 96% of patients had an EUS that confirmed obliteration and only two experienced minor bleeding,<sup>28</sup> supporting the rationale for considering the EUS-guided therapy as prophylaxis in high-risk patients. However, further studies are needed to evaluate the safety and clinical benefits of using EUS in the variceal injection of cyanoacrylate, deployment of embolization coils, or combined therapy in the prevention of first bleeding in high-risk patients.

### **Ectopic variceal bleeding**

Rectal varices are common in patients with cirrhosis and portal hypertension and are a cause of lower gastrointestinal bleeding in these population. The risk of bleeding is inferior compared with gastroduodenal varices; however, sometimes, bleeding can occur massively. EUS-guided therapy, including EUS-guided coil deployment or EUS-guided cyanoacrylate injection, has been described for other anatomical locations, such as the duodenum and rectum, especially in the setting of massive gastrointestinal bleeding.<sup>31-33</sup> There are insufficient data to support these techniques as first-line therapy; however, they remain as an alternative option for rescue therapy.

### **EUS-guided endovascular therapy in nonvariceal bleeding**

EUS-guided endovascular treatment in patients with severe, refractory, or recurrent nonvariceal gastrointestinal bleeding, or unsuitable candidates

for radiologic or surgical intervention, might benefit from EUS-guided hemostatic interventions. Currently, there are series described with a success rate of 88% to 100% in the treatment of gastrointestinal stromal tumors, Dieulafoy lesions, duodenal ulcers, pancreatic pseudoaneurysms, ulcers related to esophageal cancer, and after Roux-en-Y gastric bypass.<sup>34,35</sup>

### **EUS-guided vascular therapy-related adverse events**

EUS-guided endovascular therapy offers a safe technique for the precise targeting of vessels, with fewer adverse events in contrast to the direct endoscopic visualization approach. However, adverse event rates vary with specific endovascular therapy. The endoscopic visualization approach carries the risk of embolic adverse events, within the brain, portal vein, spleen, fatal, and nonfatal pulmonary embolism.<sup>17,18</sup> Besides, the EUS real-time evaluation of vessels and Doppler flow increase the detection of fundal varices, preclude treatment contraindication, and reduce the risk of bleeding when used during monitoring after obliteration therapy.

### **Intrahepatic portosystemic shunt**

Baveno VI consensus indicates that TIPS via transjugular access is the current rescue therapy in the setting of refractory gastroesophageal bleeding. EUS has a theoretical advantage over percutaneous access due to the closeness of the gastrointestinal tract to the intra-abdominal vascularity. The EUS-guided intrahepatic portosystemic shunt placement was first described in 2009 in a porcine model, and the current experimental case series was performed on five porcine models, with no reports on humans available.<sup>36,37</sup>

### **EUS-guided portal angiotherapy**

Differentiating benign and malignant portal vein thrombus in the setting of hepatocellular carcinoma impacts clinical management. However, transabdominal ultrasound sampling carries the risk of sample contamination, biliary, and vascular injury. The EUS-guided fine-needle aspiration offers a safer alternative, with more direct access, for the diagnosis, staging, and ruling out of malignant portal vein thrombi that alter the clinical management.<sup>38</sup> Also, the collection of portal venous blood for the identification of circulating tumor cells in a nonmetastatic borderline

resectable tumor is feasible via EUS guidance, playing an important role for staging and guiding clinical management.<sup>39</sup>

EUS-guided portal vein access can also be applied for therapeutic purposes, such as liver-directed chemotherapy. Recently, EUS-guided portal injection chemotherapy was described in porcine models, with the advantage of targeting the liver parenchyma and sparing the bile duct, decreasing the risk of ischemic biliary strictures, and achieving higher concentrations of the therapeutic agent within the liver parenchyma and lower systemic levels, being beneficial in cases in which targeted hepatic drug exposure is desired.<sup>40</sup>

Possible selective thrombolysis and stenting of the vessels after initial EUS-guided portal vein access might be promising.<sup>41</sup> On the contrary, selective portal embolization with a coil and cyanoacrylate was reported on a porcine model. Embolization is performed to achieve compensatory hypertrophy of the contralateral hepatic lobe before extensive liver resection.<sup>42</sup>

## Conclusion

EUS-guided endovascular therapy is a safe and effective technique for the treatment of GV bleeding. It has improved the therapeutical arsenal with excellent results, demonstrated by the high obliteration rate achieved of GV in a single procedure. The available data have shown superiority of EUS-guided endovascular therapy over the endoscopic technique, which supports the implementation of EUS-guided therapy in therapeutical algorithms and guidelines.

Regarding the decision of whether injecting cyanoacrylate, the deployment of coils, or combined therapy, we recommend the EUS-guided combined treatment in patients with GV due to the high eradication rate with lower rebleeding and reintervention rates. However, the generalizability of these findings is limited by the number of institutions and operators capable of performing these procedures; likewise, more multicenter worldwide studies are required to confirm their actual clinical applicability and establish treatment guidelines.

EUS offered a safer and more effective alternative for the management of variceal and nonvariceal gastrointestinal bleeding. In addition, newer techniques are described for the access of the portal

vein, with diagnostic and interventional implications. There is no doubt that EUS-guided endovascular therapies are advancing tremendously, expanding its roles in various gastrointestinal conditions, and representing a new territory for investigation and development.

## Author contributions

R.O. and C.R.-M. reviewed the literature, wrote the article, and approved the final manuscript.

## Funding

The authors received no financial support for the research, authorship, and/or publication of this article.

## Conflict of interest statement

The authors declared no potential conflicts of interest with respect to the research, authorship, and/or publication of this article.

## ORCID iD

Carlos Robles-Medranda  <https://orcid.org/0000-0003-2434-3369>

## References


1. Sanyal AJ, Fontana RJ, Di Bisceglie AM, *et al.* The prevalence and risk factors associated with esophageal varices in subjects with hepatitis C and advanced fibrosis. *Gastrointest Endosc* 2006; 64: 855–864.
2. Carbonell N, Pauwels A, Serfaty L, *et al.* Improved survival after variceal bleeding in patients with cirrhosis over the past two decades. *Hepatology* 2000; 40: 652–659.
3. D'Amico G and De Franchis R. Upper digestive bleeding in cirrhosis. Post-therapeutic outcome and prognostic indicators. *Hepatology* 2003; 38: 599–612.
4. Sato T, Yamazaki K, Toyota J, *et al.* Endoscopic ultrasonographic evaluation of hemodynamics related to variceal relapse in esophageal variceal patients. *Hepatol Res* 2009; 39: 126–133.
5. Irisawa A, Saito A, Obara K, *et al.* Endoscopic recurrence of esophageal varices is associated with the specific EUS abnormalities: severe periesophageal collateral veins and large perforating veins. *Gastrointest Endosc* 2001; 53: 77–84.
6. Faigel D, Rosen H, Sasaki A, *et al.* EUS in cirrhotic patients with and without prior variceal hemorrhage in comparison with noncirrhotic control subjects. *Gastrointest Endosc* 2000; 52: 455–462.

7. Lahoti S, Catalano M, Alcocer E, *et al.* Obliteration of esophageal varices using EUS-guided sclerotherapy with color Doppler. *Gastrointest Endosc* 2000; 51: 331–333.
8. De Paulo GA, Ardengh JC, Nakao FS, *et al.* Treatment of esophageal varices: a randomized controlled trial comparing endoscopic sclerotherapy and EUS-guided sclerotherapy of esophageal collateral veins. *Gastrointest Endosc* 2006; 63: 396–402; quiz 463.
9. Sarin S and Kumar A. Gastric varices: profile, classification, and management. *Am J Gastroenterol* 1989; 84: 1244–1249.
10. Garcia-Pagán J, Barrufet M, Cardenas A, *et al.* Management of gastric varices. *Clin Gastroenterol Hepatol* 2014; 12: 919.e1–928.e1.
11. Hashizume M, Akahoshi T and Tomikawa M. Management of gastric varices. *J Gastroenterol Hepatol* 2011; 26: 102–108.
12. Irani S, Kowdley K and Kozarek R. Gastric varices: an updated review of management. *J Clin Gastroenterol* 2011; 45: 133–148.
13. Kok K, Bond R, Duncan I, *et al.* Distal embolization and local vessel wall ulceration after gastric variceal obliteration with N-butyl-2-cyanoacrylate: a case report and review of the literature. *Endoscopy* 2004; 36: 442–446.
14. Hwang S, Kim H, Park S, *et al.* N-butyl-2-cyanoacrylate pulmonary embolism after endoscopic injection sclerotherapy for gastric variceal bleeding. *J Comput Assist Tomogr* 2001; 25: 16–22.
15. Noophun P, Kongkam P, Gonlachanvit S, *et al.* Bleeding gastric varices: results of endoscopic injection with cyanoacrylate at King Chulalongkorn Memorial Hospital. *World J Gastroenterol* 2005; 11: 7531–7535.
16. Bhasin D, Sharma B, Prasad H, *et al.* Endoscopic removal of sclerotherapy needle from gastric varix after N-butyl-2-cyanoacrylate injection. *Gastrointest Endosc* 2000; 51: 497–498.
17. Saracco G, Giordanino C, Roberto N, *et al.* Fatal multiple systemic embolisms after injection of cyanoacrylate in bleeding gastric varices of a patient who was noncirrhotic but with idiopathic portal hypertension. *Gastrointest Endosc* 2007; 65: 345–347.
18. Rickman O, Utz J, Aughenbaugh G, *et al.* Pulmonary embolization of 2-octyl cyanoacrylate after endoscopic injection therapy for gastric variceal bleeding. *Mayo Clin Proc* 2004; 79: 1455–1458.
19. Robles-Medranda C, Valero M, Nebel JA, *et al.* Endoscopic-ultrasound-guided coil and cyanoacrylate embolization for gastric varices and the roles of endoscopic Doppler and endosonographic varicealography in vascular targeting. *Dig Endosc* 2019; 31: 283–290.
20. Arakawa M, Masuzaki T and Okuda K. Pathology of fundic varices of the stomach and rupture. *J Gastroenterol Hepatol* 2002; 17: 1064–1069.
21. De Franchis R and Baveno VIF. Expanding consensus in portal hypertension: report of the Baveno VI Consensus Workshop: stratifying risk and individualizing care for portal hypertension. *J Hepatol* 2015; 63: 743–752.
22. Romero-Castro R, Pellicer-Bautista FJ, Jimenez-Saenz M, *et al.* EUS-guided injection of cyanoacrylate in perforating feeding veins in gastric varices: results in 5 cases. *Gastrointest Endosc* 2007; 66: 402–407.
23. Romero-Castro R, Ellrichmann M, Ortiz-Moyano C, *et al.* EUS-guided coil versus cyanoacrylate therapy for the treatment of gastric varices: a multicenter study (with videos). *Gastrointest Endosc* 2013; 78: 711–721.
24. Bick B, Al-Haddad M, Liangpunsakul S, *et al.* EUS-guided fine needle injection is superior to direct endoscopic injection of 2-octyl cyanoacrylate for the treatment of gastric variceal bleeding. *Surg Endosc* 2019; 33: 1837–1845.
25. Romero-Castro R, Pellicer-Bautista F, Giovannini M, *et al.* Endoscopic ultrasound (EUS)-guided coil embolization therapy in gastric varices. *Endoscopy* 2010; 42: E35–E36.
26. Binmoeller KF, Weilert F, Shah JN, *et al.* EUS-guided transesophageal treatment of gastric fundal varices with combined coiling and cyanoacrylate glue injection (with videos). *Gastrointest Endosc* 2011; 74: 1019–1025.
27. Levy MJ, Wong Kee and Song LM. EUS-guided angiotherapy for gastric varices: coil, glue, and sticky issues. *Gastrointest Endosc* 2013; 78: 722–725.
28. Bhat YM, Weilert F, Fredrick RT, *et al.* EUS-guided treatment of gastric fundal varices with combined injection of coils and cyanoacrylate glue: a large U.S. *Gastrointest Endosc* 2016; 83: 1164–1172.
29. Robles-Medranda C, Valero M, Soria-Alcivar M, *et al.* 1036 coils + cyanoacrylate vs. coils alone in the endoscopic ultrasound-guided management of gastric varices [GOV II and IGV I]: a randomized, controlled therapeutic trial. *Gastrointest Endosc* 2018; 87: AB145.
30. Mishra SR, Sharma BC, Kumar A, *et al.* Primary prophylaxis of gastric variceal bleeding comparing cyanoacrylate injection and beta-blockers: a



- randomized controlled trial. *J Hepatol* 2011; 54: 1161–1167.
31. Weilert F, Shah JN, Marson FP, *et al.* EUS-guided coil and glue for bleeding rectal varix. *Gastrointest Endosc* 2012; 76: 915–916.
  32. Sharma M and Somasundaram A. Massive lower GI bleed from an endoscopically invident rectal varices: diagnosis and management by EUS (with videos). *Gastrointest Endosc* 2010; 72: 1106–1108.
  33. So H, Park do H, Jung K, *et al.* Successful endoscopic ultrasound-guided coil embolization for severe duodenal bleeding. *Am J Gastroenterol* 2016; 111: 925.
  34. Levy MJ, Wong Kee, Song LM, Farnell MB, *et al.* Endoscopic ultrasound (EUS)-guided angiotherapy of refractory gastrointestinal bleeding. *Am J Gastroenterol* 2008; 103: 352–359.
  35. Law R, Fujii-Lau L, Wong Kee, Song LM, *et al.* Efficacy of endoscopic ultrasound-guided hemostatic interventions for resistant nonvariceal bleeding. *Clin Gastroenterol Hepatol* 2015; 13: 808.e1–812.e1.
  36. Buscaglia JM, Dray X, Shin EJ, *et al.* A new alternative for a transjugular intrahepatic portosystemic shunt: EUS-guided creation of an intrahepatic portosystemic shunt (with video). *Gastrointest Endosc* 2009; 69: 941–947.
  37. Giday SA, Clarke JO, Buscaglia JM, *et al.* EUS-guided portal vein catheterization: a promising novel approach for portal angiography and portal vein pressure measurements. *Gastrointest Endosc* 2008; 67: 338–342.
  38. Gimeno Garcia AZ, Aparicio JR, Barturen A, *et al.* Short article: endoscopic ultrasound-guided fine-needle aspiration of portal vein thrombosis in patients with chronic liver disease and suspicion of hepatocellular carcinoma. *Eur J Gastroenterol Hepatol* 2018; 30: 418–423.
  39. Catenacci DVT, Chapman CG, Xu P, *et al.* Acquisition of portal venous circulating tumor cells from patients with pancreaticobiliary cancers by endoscopic ultrasound. *Gastroenterology* 2015; 149: 1794.e4–1803.e4.
  40. Faigel DO, Lake DF, Landreth TL, *et al.* EUS-guided portal injection chemotherapy for treatment of hepatic metastases: feasibility in the acute porcine model. *Gastrointest Endosc* 2016; 83: 444–446.
  41. Abdel-Aal AK, Ezzeldin IB, Hamed MF, *et al.* Endovascular treatment of acute portal vein thrombosis using ultrasound-accelerated catheter-directed thrombolysis. *Vasc Endovascular Surg* 2014; 48: 460–465.
  42. Park T, Seo D-W, Kang H-J, *et al.* Feasibility and safety of EUS-guided selective portal vein embolization with a coil and cyanoacrylate in a live porcine model. *Endosc Ultrasound* 2018; 7: 389–394.

Visit SAGE journals online  
[journals.sagepub.com/  
 home/cmj](http://journals.sagepub.com/home/cmj)

 SAGE journals