

## Case report

## Ruptured clear cell carcinoma of the ovary presenting as acute abdomen

Zhen Ni Zhou <sup>a</sup>, Christina Tierney <sup>a,\*</sup>, William H. Rodgers <sup>b</sup>, Long Nguyen <sup>c</sup>, David Fishman <sup>c</sup><sup>a</sup> Department of Obstetrics & Gynecology, Weill Cornell Medical College — New York Presbyterian Hospital, United States<sup>b</sup> Department of Pathology, Weill Cornell Medical College and New York Presbyterian/Queens Hospital, United States<sup>c</sup> Department of Obstetrics & Gynecology, Division of Gynecologic Oncology, Weill Cornell Medical College and New York Presbyterian/Queens Hospital, United States

## ARTICLE INFO

## Article history:

Received 30 November 2015

Received in revised form 11 January 2016

Accepted 24 January 2016

Available online 26 January 2016

## Keywords:

Gynecologic malignancy

Clear cell pathology

Acute abdomen

Ovarian cancer

Surgical emergency

Tumor capsule rupture

## ABSTRACT

**Background:** Ovarian cancer remains one of the leading causes of cancer-related deaths among women. Clear cell ovarian carcinoma is a rare histologic subtype accounting for 5–10% of all epithelial ovarian cancers and is often associated with endometriosis. Patients generally present with vague abdominal and pelvic complaints. However, patients can present in the acute setting with pleural effusions, ascites, bowel obstructions, and deep vein thrombosis.

**Case:** A 54 year old woman presenting with an acute abdomen secondary to rupture of ovarian clear cell carcinoma.

**Conclusion:** Ovarian clear cell carcinoma should remain in the differential diagnosis in a patient presenting with an acute abdomen and imaging suspicious for a gynecologic malignancy originating from the ovary.

© 2016 The Authors. Published by Elsevier Inc. This is an open access article under the CC BY-NC-ND license (<http://creativecommons.org/licenses/by-nc-nd/4.0/>).

## 1. Introduction

Despite advances in research, diagnosis, and treatment, ovarian cancer remains the deadliest cancer of the female reproductive tract. According to the American Cancer Society, approximately 21,000 women are diagnosed with ovarian cancer in the United States and 14,000 women will succumb to this disease annually. Clear cell ovarian carcinoma, a histologic subtype of epithelial ovarian carcinoma, accounts for approximately 5–10% of ovarian cancers. Women with ovarian clear cell carcinoma, similar to the other ovarian epithelial carcinomas, often present with vague pelvic and abdominal signs and symptoms, such as bloating, early satiety, abdominal pain and distention, constipation, and changes in urinary habits. Acutely, patients may present with pleural effusions, ascites, small bowel obstructions, or deep vein thrombosis (Lim et al., 2009; Tan and Kaye, 2007). Here we present the first documented case of a ruptured ovarian clear cell carcinoma presenting as an acute abdomen.

## 2. Case

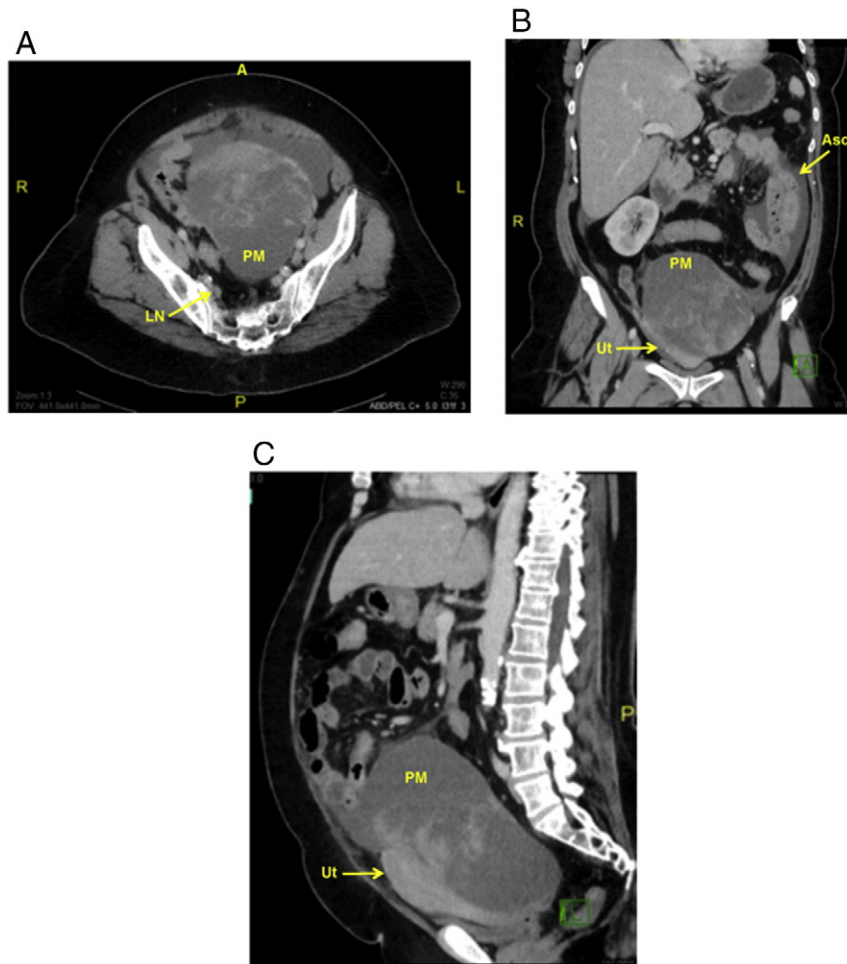
The patient is a 54 year old G1P1001, postmenopausal woman who presented to the emergency department complaining of severe abdominal pain for the past 24 h. She reported that the pain was diffuse and

constant; review of systems was otherwise negative. Past gynecological history was remarkable for endometriosis. Past medical, surgical, family, and social histories were non-contributory. On presentation, her vital signs were remarkable for tachycardia with a pulse of 105. The remainder of her vital signs was within normal limits. On physical exam, her abdomen was distended, diffusely tender, dull to percussion, and positive for both rebound and guarding. Her pelvic exam was remarkable for cervical motion tenderness and diffuse tenderness. A palpable mass was appreciated on the abdominal and rectovaginal exam. Lab work was significant for leukocytosis with a WBC count of 38.0 as well as an elevated lactate of 3.6. An abdominal X-ray was negative for free air. Computed tomography (CT) scan demonstrated a 15.5 × 16.6 × 18.2 cm heterogeneous pelvic mass worrisome for malignancy, possibly ovarian (Fig. 1A–C). Ascites was present, but no evidence of small bowel obstruction was noted (Fig. 1A–C). The liver, spleen, pancreas, and appendix appeared normal (Fig. 1A–C).

As the patient had an acute abdomen, the recommendation was made by gynecologic oncology for immediate surgical intervention by exploratory laparotomy. Exploration of the abdominal cavity revealed hemoperitoneum, a ruptured large left adnexal mass adherent to the posterior aspect of the uterus, which was surrounded by dark brown ascites and actively extravasating bright red blood. At the base of the lesion, a 6 cm fungating mass was noted. The ovarian capsule was densely adherent to the mesentery of the small bowel and transverse colon, which was surgically separated without incident. The uterus and right fallopian tube and ovary appeared normal. There was no obvious bowel or omental disease. A full staging procedure was not performed because the patient was noted to have a large amount of

\* Corresponding author at: 525 East 68th Street, Box 122, New York, NY 10065, United States.

E-mail address: [cht9062@nyp.org](mailto:cht9062@nyp.org) (C. Tierney).



**Fig. 1.** Post contrast enhanced CT images demonstrating a large heterogenous mass (PM) occupying the majority of the pelvis. The pelvic mass can be seen compressing the uterus (Ut). Enhancing nodularity is noted in the pelvic mass, which is suspicious for malignancy. Small pelvic ascites is noted (Asc). Several subcentimeter retroperitoneal lymph nodes are noted (LN). A, Axial view. B, Coronal view. C, Sagittal view.

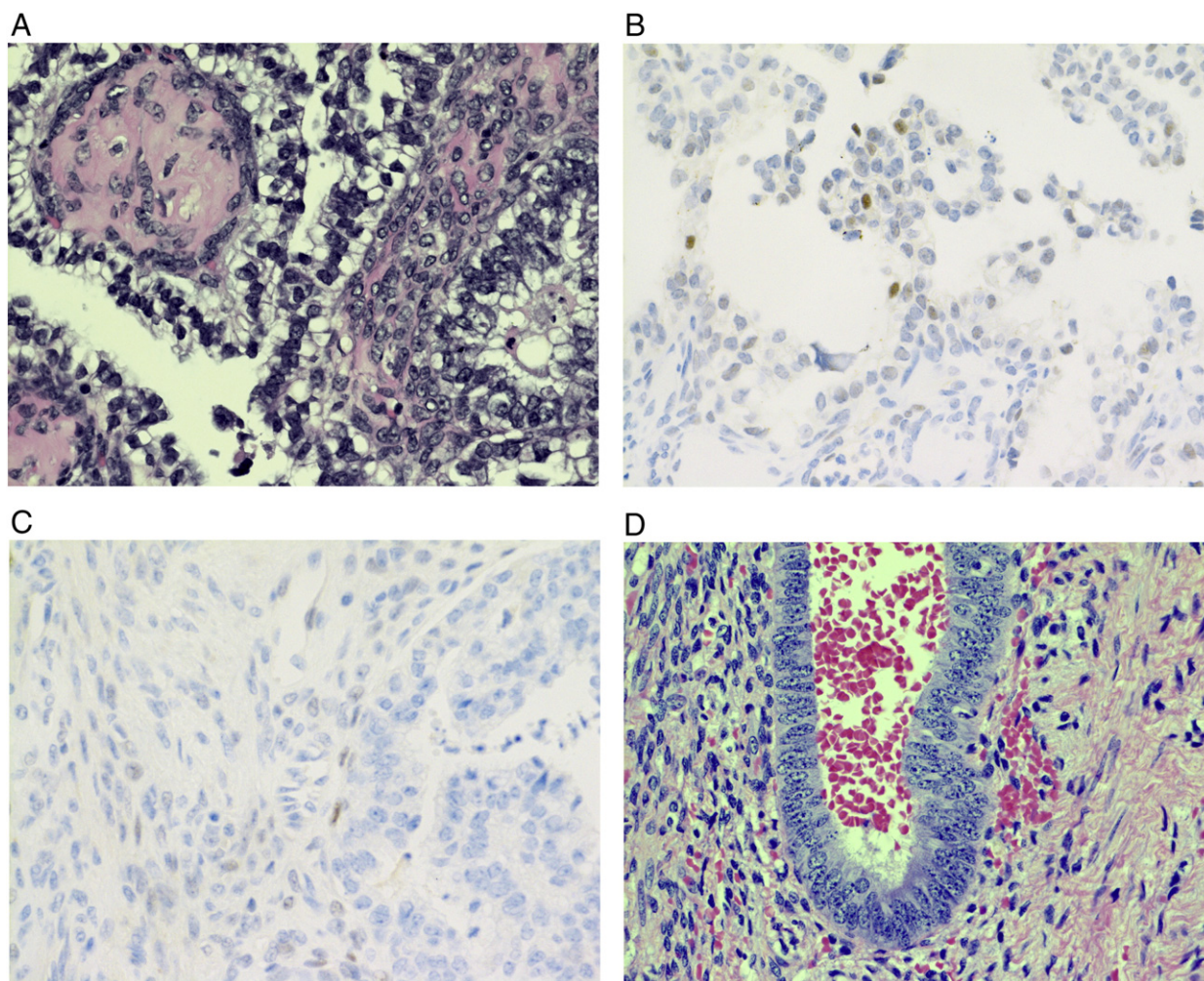
hemoperitoneum due to the ruptured adnexal mass that was actively extravasating upon initial entry into the abdomen with an estimated blood loss of approximately 500 cc. Only a systematic examination of the pelvis and para-aortic regions was performed. A small mobile enlarged para-aortic lymph node was palpated and excised. The patient ultimately underwent an exploratory laparotomy, total abdominal hysterectomy, bilateral salpingo-oophorectomy, excision of the pelvic mass, omentectomy, and para-aortic lymph node dissection. An intra-operative frozen section of the pelvic mass was performed and was positive for ovarian carcinoma.

Final pathology returned as moderately differentiated clear cell carcinoma of the ovary limited to the left ovary with ovarian surface involvement (Fig. 2A-C). The immunohistological features of the tumor including hyalinized papillary architecture lined by cytologically atypical cells with clear cytoplasm with lack of immunohistochemical evidence of p53 mutation or estrogen receptor (ER) expression, are typical of clear cell carcinoma (Fig. 2B-C). The uterus, cervix, contralateral fallopian tube and ovary, omentum, and para-aortic lymph nodes were negative for carcinoma. Incidentally, endometriosis was noted on the ovaries bilaterally (Fig. 2D). The patient's post-operative course was uncomplicated; she was discharged home on post-operative day 4. The patient's case was discussed at our multidisciplinary tumor board and the recommendation is for her to be treated with a 6-course regimen of systemic adjuvant chemotherapy with carboplatin and paclitaxel.

### 3. Discussion

Ovarian cancer remains the fifth leading cause of cancer related death among women in the United States according to the National Cancer Institute. Clear cell ovarian cancer is a rare histological subtype of epithelial ovarian carcinomas that commonly presents in the perimenopausal period and comprises a larger proportion of ovarian cancers in the Asian population (del Carmen et al., 2012). When discovered at an early stage, clear cell carcinoma of the ovary is associated with a relatively good prognosis (del Carmen et al., 2012; Miyamoto et al., 2013). However, advanced stage disease is often associated with worse outcomes because of increased resistance to platinum-based chemotherapy when compared to other histologic subtypes of epithelial ovarian cancer (Tan and Kaye, 2007; Miyamoto et al., 2013). Although ovarian cancer generally presents with nonspecific abdominal symptoms or even as an incidental finding on imaging, previous reports have documented cases of an acute abdomen secondary to spontaneous rupture of ovarian granulosa cell tumors and ovarian adenocarcinoma of mesonephrotic origin, respectively (Oge et al., 2012; Bastu et al., 2013; Temelkov and Paskalev, 1976). To our knowledge, this is the first documented case of rupture of an ovarian clear cell carcinoma presenting as an acute abdomen.

Based on the final pathology, the patient was diagnosed with Stage IC2 clear cell carcinoma of the ovary secondary to spontaneous rupture of the tumor capsule. In a recent retrospective single-institution cohort



**Fig. 2.** Photomicrographs of left ovarian clear cell carcinoma (A–C) and right ovarian endometriosis (D). Prominent hyalinized stroma is often seen in clear cell ovarian carcinomas. Neoplastic cells are noted to have distinct cell borders and a wide range of nuclear and cytologic atypia. A, 400× H&E. B, 400× p53 immunohistochemistry (negative). C, 400× estrogen receptor immunohistochemistry (negative). D, 400× H&E.

study examining treatment outcomes in 177 patients, 62.2% of patients presented with Stage I disease at the time of diagnosis. Of these patients, 45.5% of patients were diagnosed with Stage IC disease, which was defined as disease with surface involvement, ascites positive for malignancy, or intra-operative tumor rupture. The majority of patients underwent adjuvant chemotherapy with carboplatin and paclitaxel, and 89.2% of patients received more than 3 cycles of chemotherapy. No statistical significance in survival was conferred in patients receiving more than 3 cycles of chemotherapy at a given stage of disease. Interestingly, survival for stage IA and IC intra-operative rupture only disease was statistically similar. While the prognostic implications of intra-operative tumor rupture remain unclear, less favorable patient outcomes are seen when surface involvement or malignant ascites is present when compared with intra-operative tumor rupture only, and therefore adjuvant chemotherapy is recommended even in early stages of disease (Shu et al., 2015).

This case is novel in that spontaneous rupture of a clear cell ovarian tumor had occurred, and the patient presented with peritoneal signs and an acute abdomen, which is a surgical emergency. Gynecologists often see patients with ovarian malignancies presenting subacutely with constitutional and abdominal and pelvic signs and symptoms in an outpatient setting. However, epithelial ovarian carcinomas, and in particular ovarian clear cell cancer, ought to remain in the differential

diagnosis in patients presenting with an acute abdomen with imaging suspicious for malignancy.

#### Conflict of interest statement

The authors declare that there are no conflicts of interest.

#### Acknowledgements

The authors would like to acknowledge Dr. James Koutras, the attending radiologist, for his assistance in reading and providing the imaging slides.

#### References

- Bastu, E., Akhan, S.E., Karamustafaoglu, B., Gungor-Ugurlucan, F., Sozen, H., Iyibozkurt, A.C., 2013. Hemoperitoneum and acute abdomen caused by the rupture of ovarian granulosa cell tumor: a case report. *Eur. J. Gynaecol. Oncol.* 34 (3), 263–264.
- del Carmen, M.G., Birrer, M., Schorge, J.O., 2012. Clear cell carcinoma of the ovary: a review of the literature. *Gynecol. Oncol.* 126 (3), 481–490.
- Lim, M.C., Lee, D.O., Kang, S., Seo, S.S., Lee, B.Y., Park, S.Y., 2009. Clinical manifestations in patients with ovarian clear cell carcinoma with or without co-existing endometriosis. *Gynecol. Endocrinol.* 25 (7), 435–440.
- Miyamoto, M., Takano, M., Goto, T., Kato, M., Sasaki, N., Tsuda, H., et al., 2013. Clear cell histology as a poor prognostic factor for advanced epithelial ovarian cancer: a single

- institutional case series through central pathologic review. *J. Gynecol. Oncol.* 24 (1), 37–43.
- Oge, T., Ozalp, S.S., Yalcin, O.T., Kabukcuoglu, S., Arslan, E., 2012. Ruptured granulosa cell tumor of the ovary as a cause of acute abdomen in postmenopausal woman. *Case reports in oncological medicine*. 2012, p. 451631.
- Shu, C.A., Zhou, Q., Jotwani, A.R., Iasonos, A., Leitao Jr., M.M., Konner, J.A., et al., 2015. Ovarian clear cell carcinoma, outcomes by stage: the MSK experience. *Gynecol. Oncol.*
- Tan, D.S., Kaye, S., 2007. Ovarian clear cell adenocarcinoma: a continuing enigma. *J. Clin. Pathol.* 60 (4), 355–360.
- Temelkov, S., Paskalev, G., 1976. Clear cell mesonephrotic ovarian tumor in a 5-year-old child complicated by rupture and hemorrhage with a course of acute surgical abdomen. *Khirurgiia* 29 (6), 510–511.