

Case Report

Syu Jhang, Allen W. Chiu*

An infertile female delivered a baby after removal of primary renal carcinoid tumor

<https://doi.org/10.1515/med-2020-0408>

received May 28, 2019; accepted December 28, 2019

Abstract: Primary renal carcinoid tumors are exceedingly rare. We report a 37-year-old woman with primary infertility, who was found to have a primary renal carcinoid tumor. She became pregnant and gave birth to a baby after removal of the tumor. This is the first case in the English literature of primary renal carcinoid tumor related with primary infertility.

Keywords: carcinoid tumor, infertility, neuroendocrine tumor, primary carcinoid tumor of the kidney, renal carcinoid tumor

1 Introduction

Carcinoid tumors are neoplasms arising from neuroendocrine cells. Approximately 100 cases of primary renal carcinoid tumors have been documented in the English literature [1,2]. We report the first case of primary renal carcinoid tumor associated with primary infertility.

2 Case report

A woman aged 37 years was referred to our department after being diagnosed incidentally with a 3.3 cm left renal tumor on abdominal sonography. She had been married for 4

years. She failed to conceive with regular unprotected sexual intercourse for 3 years. She visited the clinic of obstetrics and gynecology for infertility without effect 1 year ago.

She had no other symptoms except palpitation, intermittent facial flushing and sweating for 8 years. These symptoms became more frequent in recent 6 months. Laboratory tests including T3, T4, TSH, prolactin, FSH, LH, estradiol and DHEA-S were within normal range. The semen analysis of her husband revealed no abnormality. Hysterosalpingography showed bilateral patent fallopian tubes. Transvaginal ultrasound revealed mild polycystic ovary disease. Abdominal computed tomography revealed a 3.8 × 3.8 × 3.2 cm endophytic renal mass with mild contrast enhancement in the dorsal interpolar region of the left kidney. There was another 1.3 × 1.0 × 0.5 cm exophytic renal mass (Figure 1).

Given the uncertain nature of the tumors, we first excised the exophytic renal tumor and checked the tumor nature with intraoperative frozen section for tissue proof. As there was no evidence of malignancy of the frozen section, we then performed enucleation of the main endophytic tumor instead of radical nephrectomy (Figure 2). Microscopic finding revealed the tumor having uniform and hyperchromatic nuclei, growing in a gyriform and ribbon-like pattern without a well-formed capsule (Figure 3). Immunohistologically, the tumor cells expressed neuroendocrine markers including CK, vimentin, neuron-specific enolase, synaptophysin and chromogranin. The final diagnosis is a well-differentiated, grade 1, neuroendocrine tumor (NET), also known as a carcinoid tumor.

After the surgery, the symptoms including palpitation, facial flushing and sweating disappeared. Six months after the surgery, the patient received intrauterine insemination. She became pregnant and delivered a healthy baby.

Ethics approval and consent to participate: We state that all human subjects provided written informed consent with guarantees of confidentiality. The ethics approval is not applicable.

Consent for publication: We state that the patient has given her written informed consent for publication.

* **Corresponding author: Allen W. Chiu**, Department of Urology, MacKay Memorial Hospital, No. 92, Sec. 2, Zhongshan N. Rd., 10449, Taipei, Taiwan; School of Medicine, Mackay Medical College, No. 92, Sec. 2, Zhongshan N. Rd., 10449, Sanzhi, Taiwan; Division of Urology, Department of Surgery, Taipei City Hospital, No. 92, Sec. 2, Zhongshan N. Rd., 10449, Taipei, Taiwan; School of Medicine, National Yang-Ming University, No. 92, Sec. 2, Zhongshan N. Rd., 10449, Taipei, Taiwan, e-mail: whchiu1216@gmail.com, tel: +886-2-2543-3535, fax: +886-2-2543-3642

Syu Jhang: Department of Urology, MacKay Memorial Hospital, No. 92, Sec. 2, Zhongshan N. Rd., 10449, Taipei, Taiwan

Syu Jhang: School of Medicine, Mackay Medical College, No. 92, Sec. 2, Zhongshan N. Rd., 10449, Sanzhi, Taiwan

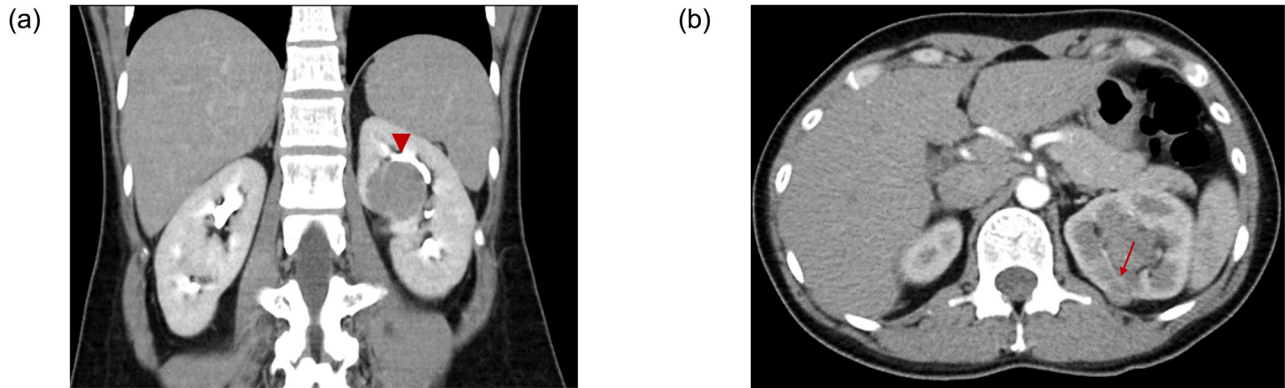


Figure 1: Abdominal CT revealed (a) the main endophytic tumor (arrow head) in the dorsal interpolar region of left kidney and (b) another exophytic tumor (arrow).

3 Discussion

Carcinoid tumors, one of NETs, are neoplasms usually originating in the gastrointestinal tract [3,4]. Primary carcinoid tumors of the kidneys are extremely rare. We conducted a PubMed search to find published research in August 2018, using the keywords: “primary carcinoid tumor” and “kidney.” There has been about 100 cases reported in the English literature [1,2].

A total of 25–30% of primary renal carcinoid tumors are found incidentally [2]. In symptomatic patients, the most commonly reported symptom was abdominal or flank pain [4,5]. Only 12.7% of patients with primary renal carcinoid tumors present with carcinoid syndrome, characterized by flushing, generalized edema, nausea, vomiting and diarrhea [5]. Our patient belonged to the

symptomatic group. The symptoms subsided after the surgery. Interestingly, she became pregnant 6 months after the surgery and gave birth to a healthy baby, which may be related with the removal of primary renal carcinoid tumor. Swelstad et al. reported a case of incidentally identified NET of the appendix, which was associated with the primary infertility [6]. However, they did not report whether the female patient became pregnant.

To our knowledge, this is the first such case. Despite reports in women with primary carcinoid tumor in the kidney [7] and in other locations [8,9] still achieving spontaneous pregnancy, we cannot assume that carcinoid tumors have no negative impact on conception. Although the

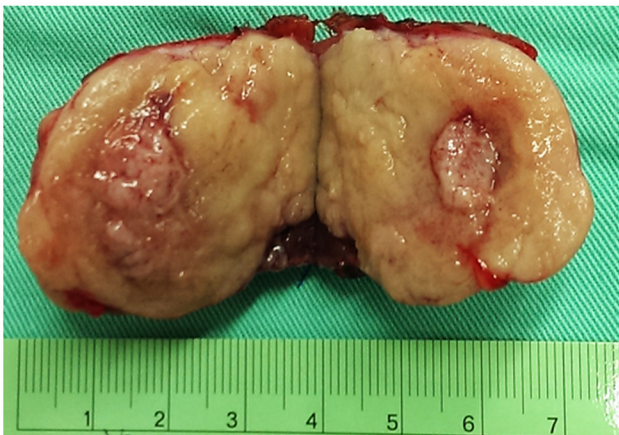


Figure 2: The specimen of the main renal tumor.

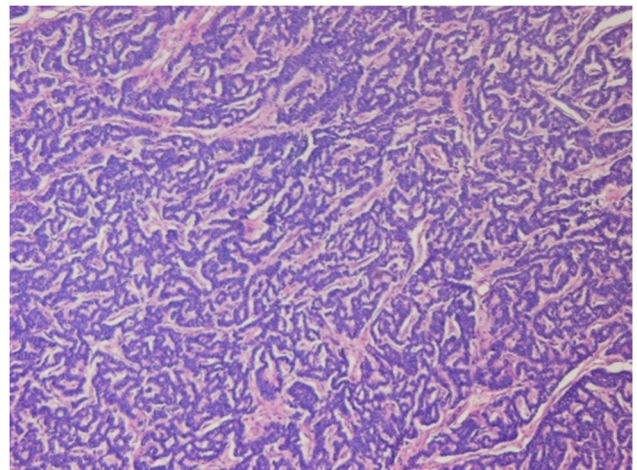


Figure 3: Microscopic findings of H&E staining showed that the tumor grew in a gyriform pattern with hyperchromatic nuclei. NET, neuroendocrine tumor.

mechanisms of how NETs influence the conception are still unknown, an endocrinologic rationale for infertility in NETs has been proposed. Serotonin, considered as the cause of carcinoid syndrome, has shown to reduce the uterine blood flow and affect fetal nutrition to cause fetal death in animal studies [7]. Selective serotonin reuptake inhibitors, which elevate the level of serotonin, typically prescribed as antidepressants, have been shown to increase the risk of spontaneous abortion during pregnancy [10].

In conclusion, we present the first case of an infertile female delivering a baby after removal of primary renal carcinoid tumor. Further investigation is needed to know the mechanisms of how NETs influence the conception.

Acknowledgements: The authors would like to thank all colleagues who contributed to this study and Taipei City Hospital for permission to use the material and data collection. Syu Jhang analyzed the data and drafted the manuscript. Allen W. Chiu revised it critically for important intellectual content and gave final approval of the version to be published.

Conflict of interest: None of the contributing authors have any conflict of interest, including specific financial interests or relationships and affiliations relevant to the subject matter or materials discussed in the manuscript.

References

- [1] Tanaka T, Yamamoto H, Imai A, Shingo H, Yoneyama T, Koie T, et al. A case of primary renal carcinoid tumor. *Case Rep Urol*. 2015;2015:736213.
- [2] Linke CS, Shie S. An asymptomatic primary renal carcinoid tumor: a case report. *Urol Case Rep*. 2016;7:70–1.
- [3] Lin C, Wu J, Gao Z, Qu G, Wang W, Yu G. Primary carcinoid tumor of the kidney with estrogen and progesterone receptor expression. *Oncol Lett*. 2015;10(1):449–52.
- [4] Omiyale AO, Venyo AK. Primary carcinoid tumour of the kidney: a review of the literature. *Adv Urol*. 2013;2013:579396.
- [5] Romero FR, Rais-Bahrami S, Permpongkosol S, Fine SW, Kohanim S, Jarrett TW. Primary carcinoid tumors of the kidney. *J Urol*. 2006;176(6 Pt 1):2359–66.
- [6] Swelstad BB, Brezina PR, Johnson CT, Resetkova N, Woo I, Kolp L. Primary infertility associated with neuroendocrine tumor (Carcinoid) of the appendix. *Asian Pac J Reprod*. 2012;1(2):152–4.
- [7] Zak F, Jindrak K, Capozzi F. Carcinoidal tumor of the kidney. *Ultrastruct Pathol*. 1983;4(1):51–9.
- [8] Pitiakoudis M, Kirmanidis M, Tsaroucha A, Christianakis E, Filippou D, Sivridis E, et al. Carcinoid tumor of the appendix during pregnancy. A rare case and a review of the literature. *J Buon*. 2008;13(2):271–5.
- [9] Yamaguchi M, Tashiro H, Motohara K-I, Ohba T, Katabuchi H. . Primary strumal carcinoid tumor of the ovary: a pregnant patient exhibiting severe constipation and CEA elevation. *Gynecologic Oncol Case Rep*. 2013;4:9–12.
- [10] Nikfar S, Rahimi R, Hendoiee N, Abdollahi M. Increasing the risk of spontaneous abortion and major malformations in newborns following use of serotonin reuptake inhibitors during pregnancy: a systematic review and updated meta-analysis. *DARU J Pharm Sci*. 2012;20(1):1.