



Case Report

Foreign body granuloma reaction after endovascular therapy of an unruptured right frontal arteriovenous malformation

Jaime Lopez-Calle¹, Roberto Colasanti^{2,3}, Cesar Chian⁴,
Joham Choque-Velasquez⁵

¹Department of Surgery-Neurosurgery, Arzobispo Loayza National Hospital, Lima, Peru

²Department of Neurosurgery, Umberto I General Hospital, Università Politecnica delle Marche, Ancona, Italy

³Department of Neurosurgery, Ospedali Riuniti Marche Nord, Pesaro, Italy

⁴Department of Pathology, Alberto Hurtado School of Medicine, Universidad Peruana Cayetano Heredia, Lima, Peru

⁵Department of Neurosurgery, Helsinki University Hospital, University of Helsinki, Helsinki, Finland

J Cerebrovasc Endovasc Neurosurg.
2020 December;22(4):267-272

Received: 20 August 2019

Revised: 21 June 2020

Accepted: 6 July 2020

Correspondence to

Joham Choque-Velasquez

Department of Neurosurgery,
Helsinki University Hospital,
Topeliuksenkatu 5, Helsinki, Finland

Tel +358-09-471-87383

Fax +358-09-471-87383

E-mail johchove@hotmail.com

ORCID <http://orcid.org/0000-0001-5220-1216>

Foreign body reactions after endovascular procedures for brain arteriovenous malformations are extremely rare. We report the case of a cerebral foreign body granuloma reaction after embolization of a frontal arteriovenous malformation with Onyx. A previously treated 36-year-old man underwent re-embolization of a residual and recurrent unruptured right frontal vascular malformation with Onyx. The post-procedural imaging revealed a right frontotemporal heterogeneously enhancing expansive lesion associated with a residual malformation. Following microsurgical resection, the histopathological examination of the expansive lesion revealed basophilic foreign body like deposits adjacent to multi-nucleated giant cells, highly compatible with cerebral foreign body granulomas reaction to Onyx. The clinical and radiological follow-up of the patient was favorable after complete resection of the lesions.

Keywords Brain arteriovenous malformation, Embolization, Endovascular therapy, Foreign body granuloma, Onyx

INTRODUCTION

Brain arteriovenous malformations (AVMs) are complex vascular lesions with different clinical presentations. Current treatment options include: conservative management, microneurosurgery, endovascular therapy, radiosurgery or a combination of these modalities.¹⁻³⁾

Numerous reports illustrate the pros and cons of endovascular treatments for brain

This is an Open Access article distributed under the terms of the Creative Commons Attribution Non-Commercial License (<http://creativecommons.org/licenses/by-nc/3.0/>) which permits unrestricted noncommercial use, distribution, and reproduction in any medium, provided the original work is properly cited.

AVMs, as well as the potential complications.⁷⁾⁽¹¹⁻¹³⁾ However, foreign body reactions to the embolizing agents are rarely reported. Only one case report on a suspected cerebral foreign body granuloma reaction to Onyx was found in the literature.⁶⁾

Here, we report the occurrence of a cerebral foreign body granuloma in a patient who underwent embolization of an unruptured right frontal AVM. The histopathological findings were highly compatible with a cerebral foreign body granuloma reaction to Onyx.

CASE REPORT

A 36-year-old man with a history of pulmonary tu-

berculosis (successfully treated sixteen years prior), was referred to our clinic with a residual right frontal AVM and a heterogeneous expansive intracranial lesion. Few days before, the patient presented epileptic seizures that required a double-drug management with valproic acid and levetiracetam.

The AVM, originally a Spetzler Martin grade II with its blood supply coming from both the internal and external carotid arteries (precisely from multiples frontal branches of the right middle cerebral artery (MCA), and a single feeding artery coming from the middle meningeal artery, respectively), and a single draining vein to the superior sagittal sinus, was embolized with N-butyl-2-cyanoacrylate (N-BCA) eight years prior (Fig. 1).

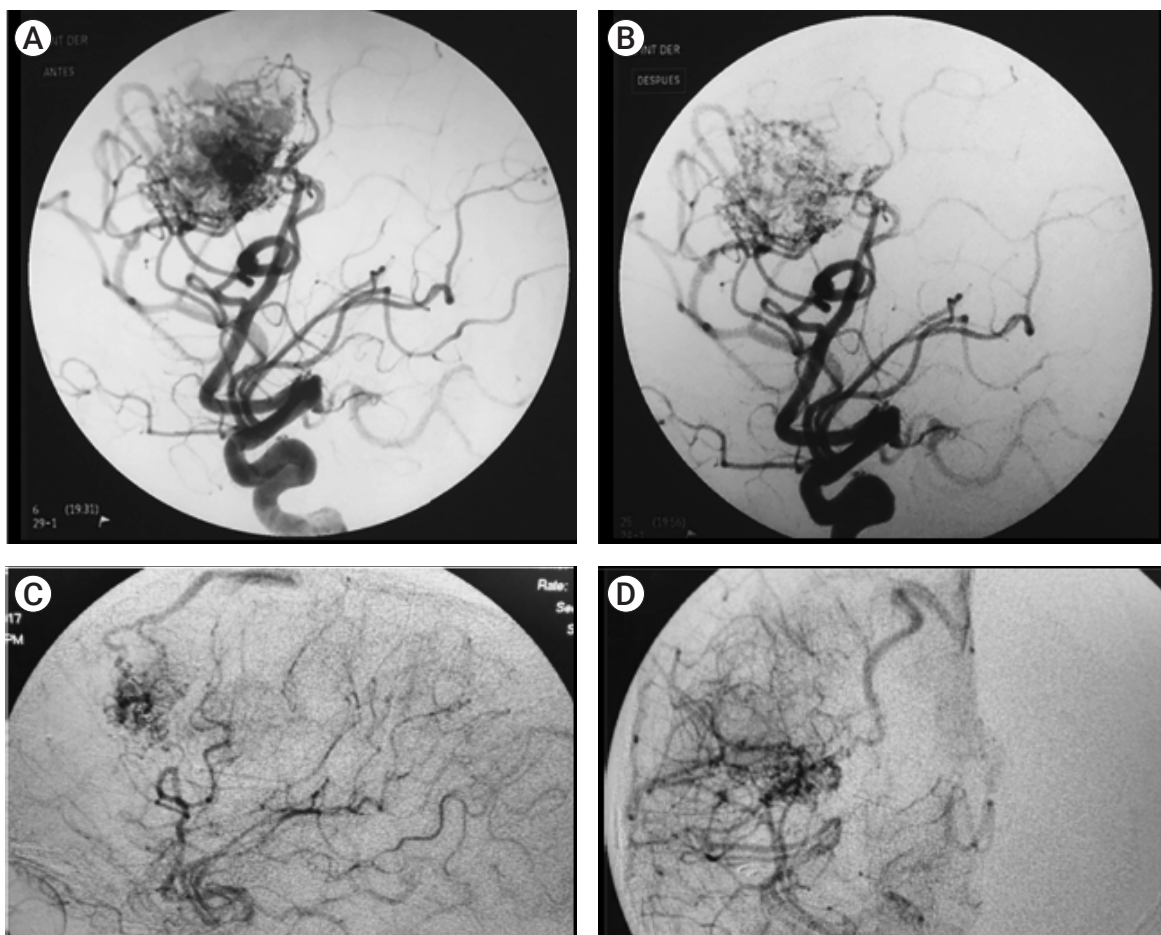


Fig. 1. (A) Cerebral angiography of a right frontal AVM (4×3 cm) fed by multiples frontal branches of the right middle cerebral artery. (B) Post-embolization cerebral angiography after initial treatment. (C) and (D) Last pre-operative cerebral angiography after the last embolization where a single draining vein to the superior sagittal sinus is observed. AVM, arteriovenous malformation.

A new embolization was performed with ethylene-vinyl alcohol copolymer (Onyx; ev3, Irvine, CA, USA) through the MCA, and with N-BCA through a small dural fistula from a branch of the external carotid artery. Postoperatively, no complication was observed except for an unspecific cellulitis in the frontal region of the head of the patient, who received empiric antibiotic therapy. However, the lesion ulcerated, and a subcutaneous collection appeared few days later. Samples collected by needle aspiration were positive for *Pseudomonas*

spp., and the patient underwent specific antibiotic treatment. Within two weeks, the magnetic resonance imaging (MRI) studies revealed a suspected residual AVM, and a right frontotemporal heterogeneously enhancing expansive lesion with perilesional edema, which was diagnosed as brain abscess (Fig. 2). The patient worsened clinically with intense headache, nausea and vomiting. Hence, the patient underwent a right frontotemporal craniotomy and microsurgical resection of the lesions. Intraoperatively, severe leptomeningeal adhesions with

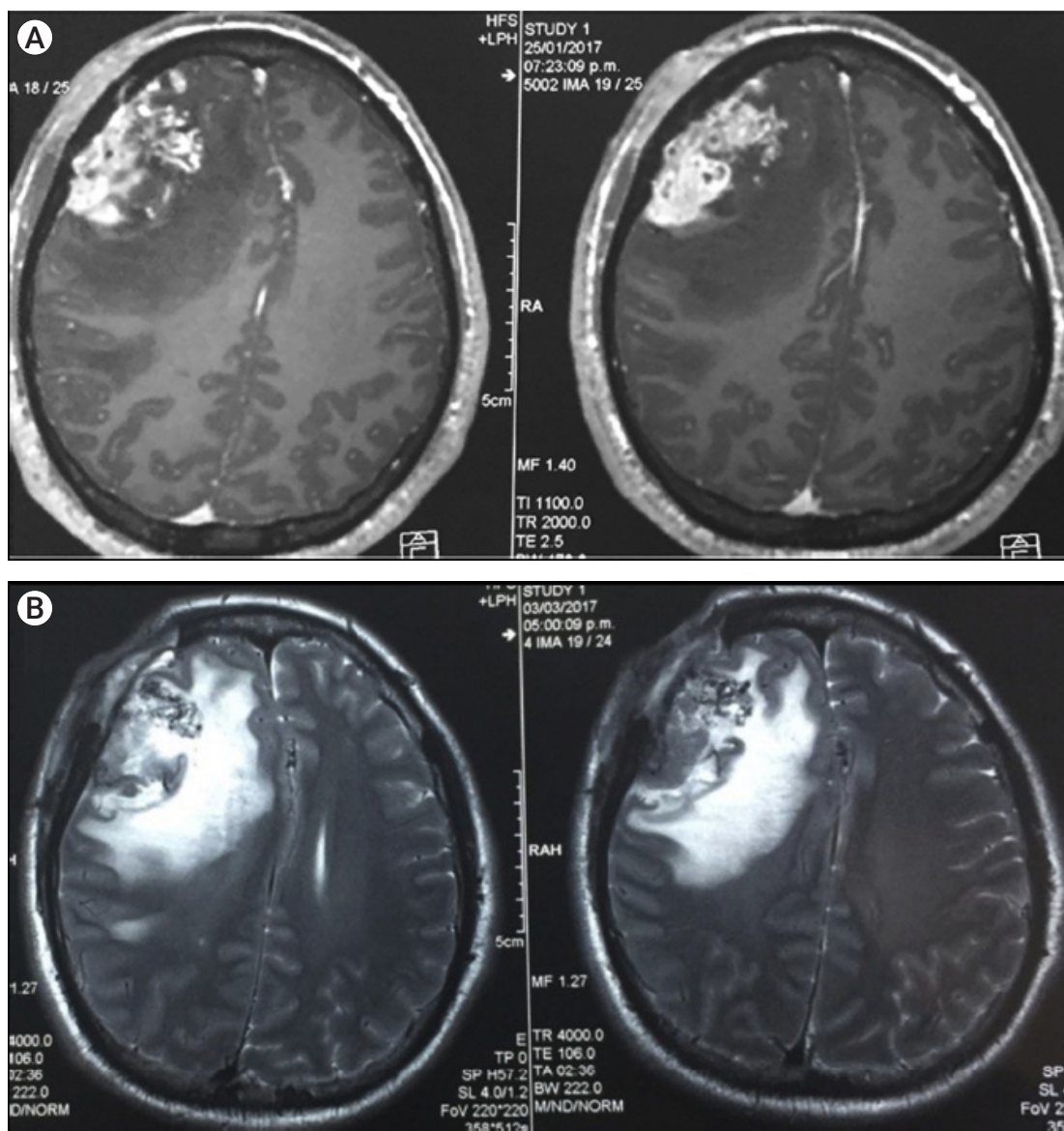


Fig. 2. Cerebral T1WI MRI sequences after contrast administration (A) and T2WI MRI sequences (B) revealing a right frontotemporal heterogeneously enhancing expansive lesion with perilesional edema and a residual AVM. MRI, magnetic resonance imaging; AVM, arteriovenous malformation.

a poorly vascularized frontotemporal expansive lesion were evident. The lesion was next to the partially embolized right frontal AVM, and contained a thick liquid similar to the caseum in its frontal part. Initially, careful microsurgical dissection with complete removal of the granuloma was performed. Careful hemostasis of the surgical site was followed by the microsurgical resection of the residual AVM. The small feeding arteries from the MCA were coagulated and cut. Finally, the single draining vein was coagulated and cut as well. Postoperatively, the symptoms of the patient gradually improved, and

anticonvulsants were progressively reduced.

A careful histopathological examination revealed multinucleated giant cells containing randomly scattered nuclei inside a large cytoplasmic space, and basophilic foreign body like deposits adjacent to the giant cells (Fig. 3). Both polymerase chain reaction and culture were negative for *Mycobacterium tuberculosis*.

A postoperative cerebral angiography revealed no residual AVM. Follow-up brain MRI confirmed the gross total resection of the foreign body granulomatous lesion as well (Fig. 4).

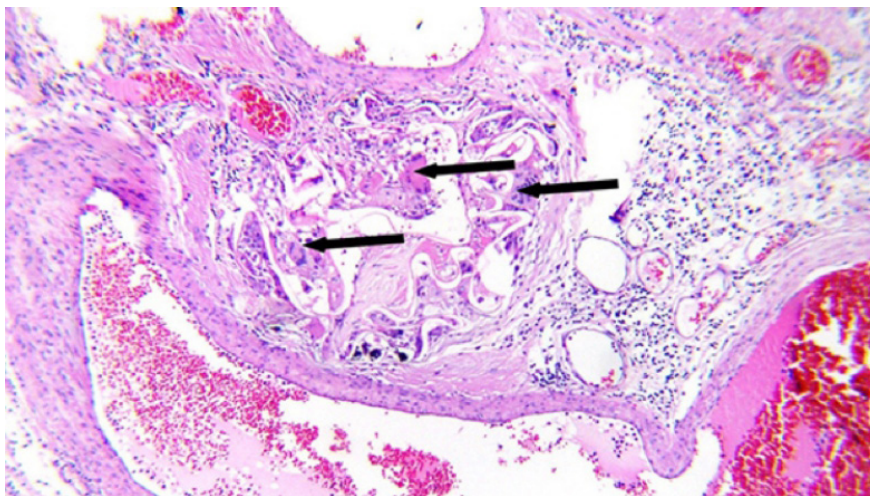


Fig. 3. Photomicrograph of the surgical specimen showing a foreign body granuloma with basophilic Onyx-like deposits associated with multinucleated giant cells (arrows).

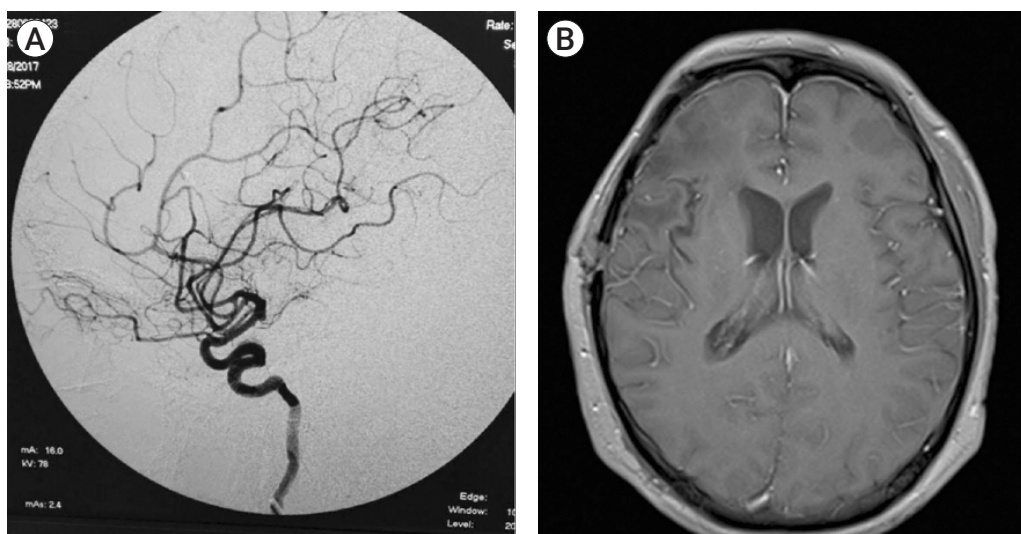


Fig. 4. Postoperative cerebral angiography (A) and follow-up MRI (B) confirming the gross total resection of the fronto-temporal granulomatous lesion, as well as of the residual right frontal AVM. MRI, magnetic resonance imaging; AVM, arteriovenous malformation.

DISCUSSION

Here, we present a histologically confirmed intracranial foreign body granuloma reaction after endovascular therapy of an unruptured right frontal AVM. The histopathological findings were highly compatible with cerebral foreign body granuloma reaction to Onyx.

Since its introduction into the market more than a decade ago, Onyx has shown superiority over other embolic substances due to its non-adhesiveness and better penetration.^{5,7)} On the other hand, various Onyx embolization-related complications have been reported.^{7,11-13)} Foreign body granulomas to the embolizing agents are very rare.^{4,6,8)} Only one case report on a cerebral foreign body granuloma reaction to Onyx was found in the literature.⁶⁾

Murayama et al. conducted a histopathological study in swine rete mirabile before Onyx introduction into the market. They demonstrated that Onyx generates a perivascular inflammatory reaction in subacute (18 days) and chronic (one to six months) stages with a granulomatous response characterized by the presence of epithelioid and multinucleated foreign body giant cells.⁹⁾

Natarajan et al. reported some changes in brain AVMs after embolization in 22 patients treated with Onyx. The vessels wall integrity was maintained in all embolized vessels without perivascular extravasation of the embolic material. The histological analysis evidenced vascular or perivascular inflammation in 20 cases (91%). Chronic foreign-body giant cells were seen in 12 cases (55%); angionecrosis of the embolized vessel was observed in 13 (59%) specimens; and recanalization in Onyx embolized vessels was observed in four (18%) cases. They concluded that the occurrence of chronic foreign-body giant cells and recanalization after Onyx embolization shows a long-standing reaction to Onyx.¹⁰⁾

Gunawat et al.⁶⁾ reported about the occurrence of a parieto-occipital foreign body granulomatous reaction in a patient who had undergone embolization and four radiosurgery sessions for an AVM. Multinucleated foreign body giant cells were predominant at the histopathological examination. However, Langhans giant cells typical of mycobacterium infection were also present. In this

patient, Onyx and two more different embolic substances were used, thus making more difficult a precise definition of the etiopathogenesis.⁶⁾

A foreign body granuloma reaction to Onyx embolization for a congenital orbito-facial vascular malformation was also reported. The histopathological findings of this extracranial AVM included Onyx particles partially impacted in small vessels and numerous multinucleated giant cells that had phagocytosed the Onyx particles.⁸⁾

The diagnosis of the present case is based on the basophilic Onyx-like deposits associated with the type of multinucleated giant cells present in the histological study of the granuloma. The definitive diagnosis of a foreign body reaction includes the identification of the foreign body in the histological study. However, this identification might be challenging after normal processing of the samples since some liposoluble substance such as Onyx could disappear during conventional histopathological processing.^{4,6,8)} On the other hand, a tuberculoma diagnosis requires the identification of the mycobacterium tuberculosis in the samples. Whether both the foreign body and the mycobacterium are not disclosed, the major criteria for the diagnosis is the type of giant cells present in the study. Tuberculomas are mostly associated with the specific type of Langhans giant cells.⁶⁾

Although the definitive differentiation between a tuberculoma and an Onyx-reaction granuloma might still be demanding, a concomitant history of tuberculosis, as in our case and in the report by Gunawat et al.,⁶⁾ could enhance the Onyx-reaction and stimulate the development of a granuloma as an inflammatory lesion.

Dinesh described a foreign body granulomatous reaction mimicking an oligodendroglioma in a patient who had undergone an embolization of a frontal AVM 10 years earlier with N-BCA. The histopathological examination revealed cystic structures with dense fibrous tissue and multinucleated giant cells, without the identification of any foreign material. Stains for tuberculosis, fungi, or malignancy remained negative.⁴⁾

As above mentioned, in our case a small dural fistula was embolized with N-BCA. Thus, the possibility of a

reaction to this last component might still exist. However, some aspects make less probable this hypothesis: A. the patient underwent initially a partial embolization with N-BCA eight years prior, without any post-procedural complication; B. the N-BCA was used in small amounts through the dural feeder, while Onyx was applied more massively through the MCA feeders for the AVM embolization; and C. the histopathological examination of the case did not reveal N-BCA or cystic components, but Onyx-like deposits, which associated with the multinucleated giant cells represent features commonly related with a foreign body reaction to Onyx.⁶⁸⁾

CONCLUSIONS

We report the rare case of a cerebral foreign body granuloma reaction after AVM embolization, very probably due to a reaction to Onyx, as suggested by histological findings. A history of tuberculosis might enhance the development of a foreign body granuloma as an inflammatory lesion, even if further research should be performed in this regard.

Disclosure

The authors report no conflict of interest concerning the materials or methods used in this study or the findings specified in this paper.

REFERENCES

1. Brown RD Jr, Wiebers DO, Forbes G, O'Fallon WM, Piepgras DG, Marsh WR, et al. The natural history of unruptured intracranial arteriovenous malformations. *J Neurosurg.* 1988 Mar;68(3):352-7.
2. Brown RD Jr, Wiebers DO, Torner JC, O'Fallon WM. Frequency of intracranial hemorrhage as a presenting symptom and subtype analysis: a population-based study of intracranial vascular malformations in Olmsted County, Minnesota. *J Neurosurg.* 1996 Jul;85(1):29-32.
3. Choque-Velasquez J, Kozyrev DA, Colasanti R, Thiarawat P, Intarakhao P, Jahromi BR, et al. The open access video collection project "Hernesniemi's 1001 and more microsurgical videos of Neurosurgery": A legacy for educational purposes. *Surg Neurol Int.* 2017 Aug;8:188.
4. Dinesh SK, Lee SY, Thomas J. A case of mistaken identity: intracranial foreign body reaction after AVM embolisation mimicking a glioma. *J Clin Neurosci.* 2008 Apr;15(4):463-5.
5. Duffner F, Ritz R, Bornemann A, Freudenstein D, Wiendl H, Siekmann R. Combined therapy of cerebral arteriovenous malformations: histological differences between a non-adhesive liquid embolic agent and n-butyl 2-cyanoacrylate (NBCA). *Clin Neuropathol.* 2002 Jan-Feb;21(1):13-7.
6. Gunawat P, Shaikh ST, Karmarkar V, Deopujari C. Symptomatic granuloma secondary to embolic agent: A case report. *J Clin Diagn Res.* 2016 Nov;10(11):PD15-6.
7. Jahan R, Murayama Y, Gobin YP, Duckwiler GR, Vinters HV, Viñuela F. Embolization of arteriovenous malformations with Onyx: clinicopathological experience in 23 patients. *Neurosurgery.* 2001 May;48(5):984-95; discussion 995-7.
8. Liu CY, Yonkers MA, Liu TS, Minckler DS, Tao JP. Vascular steal syndrome, optic neuropathy, and foreign body granuloma reaction to Onyx-18 embolization for congenital orbito-facial vascular malformation. *Ocul Oncol Pathol.* 2016 Apr;2(3):185-9.
9. Murayama Y, Viñuela F, Ulhoa A, Akiba Y, Duckwiler GR, Gobin YP, et al. Nonadhesive liquid embolic agent for cerebral arteriovenous malformations: preliminary histopathological studies in swine rete mirabile. *Neurosurgery* 1998 Nov;43(5):1164-75.
10. Natarajan SK, Born D, Ghodke B, Britz GW, Sekhar LN. Histopathological changes in brain arteriovenous malformations after embolization using Onyx or N-butyl cyanoacrylate. Laboratory investigation. *J Neurosurg.* 2009 Jul;111(1):105-13.
11. Panagiotopoulos V, Gizewski E, Asgari S, Regel J, Forsting M, Wanke I. Embolization of intracranial arteriovenous malformations with ethylene-vinyl alcohol copolymer (Onyx). *AJNR Am J Neuroradiol.* 2009 Jan;30(1):99-106.
12. van Rooij WJ, Sluzewski M, Beute GN. Brain AVM embolization with Onyx. *AJNR Am J Neuroradiol.* 2007 Jan;28(1):172-7; discussion 178.
13. Singla A, Fargen KM, Hoh B. Onyx extrusion through the scalp after embolization of dural arteriovenous fistula. *J Neurointerv Surg.* 2016 Sep;8(9):e38.