

Case Report

Two cases of iodixanol-induced pancreatitis

Mufaddal F. Kheda and Harold M. Szerlip

Section of Nephrology, Medical College of Georgia, Augusta, GA 30912, USA

Keywords: adverse events; hemodialysis; pancreatitis; radio-contrast agents

Introduction

Because of the escalating number of patients on dialysis and the increased use of vascular access surveillance, more and more hemodialysis patients are undergoing angiographic procedures for angioplasty and thrombectomy of their vascular access. Such procedures expose these patients to radiographic contrast agents (RCAs). Even though, newer low-osmolar and iso-osmolar nonionic RCAs, which are associated with fewer adverse effects, are increasingly used, these agents can still cause complications. We report two cases of pancreatitis in end-stage renal disease (ESRD) patients, associated with intravenous use of the iodixanol. Although RCAs have been reported to exacerbate experimentally induced pancreatitis in animals [1] and possibly prolong the clinical course of acute pancreatitis in humans [3,4], there are no documented cases of intravascular RCA inducing pancreatitis in humans.

In the cases below, the RCAs used are iodixanol-320 (iso-osmolar, nonionic dimer with iodine concentration 320 mg/ml) and iohexol-300 (low-osmolar nonionic monomer with iodine concentration 300 mg/ml). The amount of RCA used during the angiogram and thrombectomy of a dialysis access is between 90 and 110 cc per study. The amount of RCA used for the contrast-enhanced computed tomography (CECT) is 140–150 cc per study.

Case report

Case 1

A 50-year-old woman with a history of ESRD secondary to polycystic kidney disease presented with acute onset of severe nausea, vomiting and abdominal pain of a 1-day duration. Symptoms began 2 h after she received iodixanol during thrombectomy of her arteriovenous dialysis

graft. There was no history of abdominal trauma, alcohol abuse, hepatobiliary disease, hypertriglyceridemia or intake of medications known to cause pancreatitis. It was noted that during previous declotting procedures using iodixanol she would develop symptoms of 'stomach upset', which resolved spontaneously in 1–2 days.

On presentation, the patient was afebrile, blood pressure was 124/78 mm Hg and pulse 109 beats/min. She appeared lethargic and in mild distress due to the abdominal pain. The remainder of the physical exam was significant only for epigastric tenderness with mild guarding. Laboratory evaluation showed a white blood cell count of 13 200/ μ L with 88% neutrophils. Serum lipase and amylase were 6423 U/L (normal 18–53 U/L) and 5332 U/L (normal 22–120 U/L), respectively. Liver transaminases, total bilirubin and serum triglycerides were in the normal range. Pancreatic protocol CECT with iohexol RCA was suggestive of necrotizing pancreatitis. The patient was managed with empiric antibiotics, intravenous fluids and nutritional support. During the hospitalization, because of recurrent thromboses of her vascular access, she underwent another thrombectomy with iodixanol and subsequently had worsening of the pancreatitis (Figure 1a). At discharge, she was asymptomatic with lipase and amylase 201 U/L and 168 U/L. No etiology could be established for the acute pancreatitis.

Two months later, because of recurrent access thromboses, an angiographic procedure using iodixanol was performed. The following day she was readmitted with nausea and abdominal pain. Lipase and amylase were elevated to 2009 U/L and 2203 U/L, respectively, and she was managed for acute pancreatitis. Her condition improved rapidly. However, on day 3 of this hospitalization, she again needed another angiogram for thrombosed dialysis access. It was now apparent that her pancreatitis was associated with the use of iodixanol. Because previous CECT using iohexol had not worsened her pancreatitis, thrombectomy was performed using iohexol. Her serum lipase and amylase remained stable (Figure 1b). Thus iodixanol appeared to be the etiology of acute pancreatitis in our patient.

Case 2

A 35-year-old man presented with acute onset of severe nausea and abdominal pain. His medical history was significant for hypertension and ESRD. Six hours prior to the onset of

Correspondence and offprint requests to: Harold M. Szerlip, BI 5072, 1120 15th Street, Augusta, GA 30912, USA. Tel: +1-706-721-2055; Fax: +1-706-721-8631; E-mail: hszerlip@mcg.edu

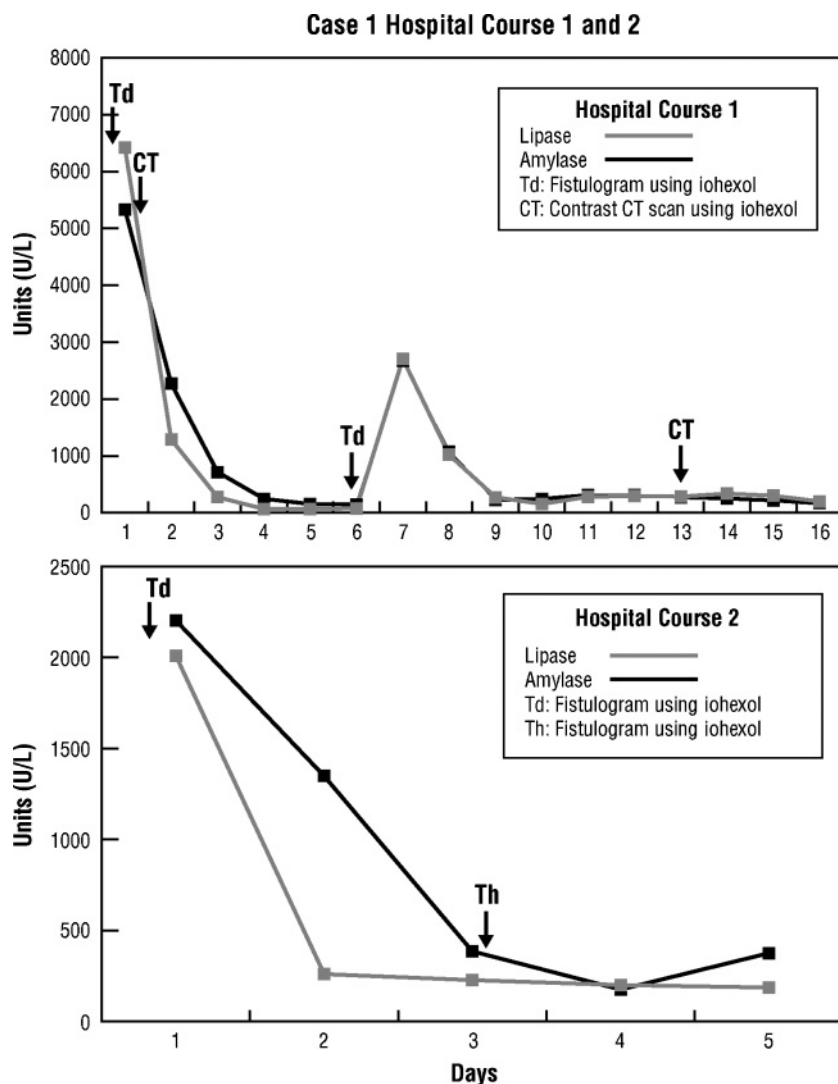


Fig. 1. Graph showing the changes in serum lipase (gray line) and amylase (black line) during the two hospital courses for the patient in case 1. Note the elevation in these pancreatic enzymes following thrombectomy using iodixanol but not iohexol. Abbreviations: Td, thrombectomy using iodixanol; CT, contrast-enhanced CT scan using iodixanol; Th, thrombectomy using iohexol.

symptoms he had received iodixanol during thrombectomy of his dialysis arterio-venous fistula. He denied abdominal trauma or alcohol use. None of his outpatient medications were known to cause pancreatitis. Past medical history was remarkable for a previous case of pancreatitis. On further questioning it was determined that the previous episode followed declotting of his dialysis fistula.

On admission, his temperature was 37.4°C, blood pressure 119/84 mm Hg and pulse 92 bpm. He was in no distress. The remainder of his examination was significant for diffuse abdominal tenderness without guarding or rebound. His white blood cell count was 8100/ μ L. Serum lipase and amylase were 4096 U/L (normal 18–53 U/L) and 1889 U/L (normal 22–120 U/L), respectively. Liver transaminases, total bilirubin and serum triglycerides were all in the normal range. Acute pancreatitis was confirmed with CECT scan with iohexol RCA. No etiology was found. The patient was managed with empiric antibiotics, intravenous fluids and

nutrition support. His pancreatitis resolved. On hospital day 4, his dialysis fistula rethrombosed. From our previous experiences we suspected that iodixanol was probably the cause of his pancreatitis. Therefore, iohexol was used as the RCA for thrombectomy. There was no exacerbation of pancreatitis post-procedure (Figure 2).

Discussion

Pancreatitis is associated with high morbidity and mortality. While gallstone disease and alcoholism account for 80% of all cases of acute pancreatitis, the remaining cases are caused by a variety of factors including drugs, toxins or ischemia [5]. ESRD patients appear to have a higher incidence of pancreatitis than the general population [6]. On post-mortem examination these patients have more pancreatic abnormalities, including fibrosis, cystic changes

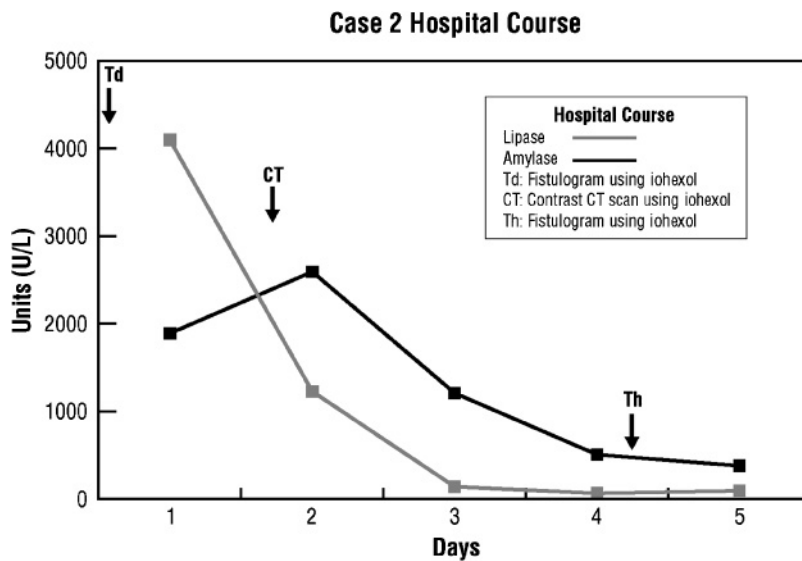


Fig. 2. Graph showing the changes in serum lipase (gray line) and amylase (black line) during the hospital course for the patient in case 2. Note the elevation in these pancreatic enzymes following thrombectomy using iodixanol but not iohexol. Abbreviations: Td, thrombectomy using iodixanol; CT, contrast-enhanced CT scan using iohexol; Th, thrombectomy using iohexol.

and calcifications [7]. Renal failure increases the levels of various gastrointestinal hormones, which increase the secretion of trypsin [8,9]. It is postulated that this excess trypsin secretion damages ductal architecture. Such underlying pathology might put patients with ESRD at greater risk for pancreatitis when exposed to agents that interfere with the pancreatic microcirculation.

In an animal model, intravenous RCA disrupted the pancreatic microcirculation and accentuated the severity of acute pancreatitis [1,2]. In humans, RCA exposures have been shown to significantly prolong the hospital stay [3] and worsen the clinical course [4] in patients admitted with acute pancreatitis. These studies highlight that intravenous RCA exposure is associated with adverse outcomes in subjects with established pancreatitis. However, there are no data on intravenous RCA administration as an etiology of pancreatitis in humans.

These two cases are the first to show that RCAs can precipitate necrotizing pancreatitis. They also show that iodixanol causes pancreatitis while iohexol appears to be safer. This difference might be related to the dissimilarities in viscosity and/or osmolality. We hypothesize that ischemia could be contributing to the development of pancreatic necrosis. At room temperature, the viscosity of iodixanol-320 and iohexol-300 are 11.8 and 6.3 cp, respectively (for comparison, human plasma viscosity at hematocrit 0.43 is 1.72 cp). This relatively higher viscosity of iodixanol compared to other RCAs is shown to exhibit significant reduction in tissue perfusion [10] and has been postulated as a major cause for contrast-induced nephropathy [11,12]. The intravascular use of iodixanol thus increases plasma viscosity and decreases blood flow velocity that can potentially cause ischemia to the pancreas leading to necrosis. We postulate, however, that iohexol, because of its hyperosmolality (844 mosm/kg), increases the intravascular oncotic pressures. This potentially causes intravascular fluid expansion

and maintains perfusion, thus preventing ischemic injury to the pancreas. In animal models, isovolemic hemodilution with dextrans prevented the impairment of the pancreatic microcirculation caused by RCAs [13]. In humans, however, isovolemic hemodilution is impractical and hemodilution with volume expansion can be problematic in ESRD patients.

These cases satisfy Koch's postulates and suggest that intravenous iodixanol can lead to acute pancreatitis in ESRD patients undergoing angiographic procedures. Iohexol appears to be safer. Further studies are warranted to establish the safety profile of different contrast agents, with regard to causing pancreatitis in ESRD patients. We would recommend avoiding the use of iodixanol until better safety data can be obtained.

Conflict of interest statement. None declared.

References

1. Foitzik T, Bassi D, Schmidt J *et al.* Intravenous contrast medium accentuates the severity of acute necrotizing pancreatitis in the rat. *Gastroenterology* 1994; 106: 207–214
2. Schmidt J, Hotz H, Foitzik T *et al.* Intravenous contrast medium aggravates the impairment of pancreatic microcirculation in necrotizing pancreatitis in the rat. *Ann Surg* 1995; 221: 257–264
3. Frederick F, Frank F, Benjamin K *et al.* Abdominal CT prolongs length of stay and is frequently unnecessary in the evaluation of acute pancreatitis. *Am J Med Sc* 2003; 325: 251–255
4. Carmona-Sanchez R, Uscanga L, Bezaury-Rivas P *et al.* Potential harmful effect of iodinated intravenous contrast medium on the clinical course of mild acute pancreatitis. *Arch Surg* 2000; 135: 1280–1284
5. Steinberg W, Tenner S. Acute pancreatitis. *N Engl J Med* 1994; 330: 1198–1210
6. Dyke J, Rutsky E, Stanley R. Acute pancreatitis associated with end-stage renal disease. *Radiology* 1986; 160: 403–405

7. Vaziri ND, Dure-Smith B, Miller R *et al.* Pancreatic pathology in chronic dialysis patients—an autopsy study of 78 cases. *Nephron* 1987; 46: 347–349
8. Owyang C, Miller LJ, DiMagno EP *et al.* Gastrointestinal hormone profile in renal insufficiency. *Mayo Clin Proc* 1979; 54: 769–73.
9. Owyang C, Miller LJ, DiMagno EP *et al.* Pancreatic exocrine function in severe human chronic renal failure. *Gut* 1982; 23: 357–361
10. Spitzer S, Munster W, Sternitzky R *et al.* Influence of iodixanol-270 and iopentol-150 on the microcirculation in man: influence of viscosity on capillary perfusion. *Clin Hemorheol Microcirc* 1999; 20: 49–55
11. Aspelin P, Aubry P, Fransson S-G *et al.* Nephrotoxic effects in high-risk patients undergoing angiography. *N Engl J Med* 2003; 348: 491–499
12. Seeligner E, Flemming B, Wronski T *et al.* Viscosity of contrast media perturbs renal hemodynamics. *J Am Soc Nephrol* 2007; 18: 2912–2920
13. Hotz HG, Schmidt J, Ryschich EW *et al.* Isovolemic hemodilution with dextran prevents contrast medium induced impairment of pancreatic microcirculation in necrotizing pancreatitis of the rat. *Am J Surg* 1995; 169: 161–166

Received for publication: 30.4.08

Accepted in revised form: 10.5.08