

# Injection of Bupivacaine into Disc Space to Detect Painful Nonunion after Anterior Lumbar Interbody Fusion (ALIF) Surgery in Patients with Discogenic Low Back Pain

Seiji Kimura, Seiji Ohtori, Sumihisa Orita, Gen Inoue, Yawara Eguchi, Masashi Takaso, Nobuyasu Ochiai, Kazuki Kuniyoshi, Yasuchika Aoki, Tetsuhiro Ishikawa, Masayuki Miyagi, Hiroto Kamoda, Miyako Suzuki, Yoshihiro Sakuma, Gou Kubota, Yasuhiro Oikawa, Kazuhide Inage, Takeshi Sainoh, Kazuyo Yamauchi, Tomoaki Toyone, Junichi Nakamura, Shunji Kishida, Jun Sato, and Kazuhisa Takahashi

Department of Orthopaedic Surgery, Graduate School of Medicine, Chiba University, Chiba, Japan.

Received: May 9, 2013

Revised: June 27, 2013

Accepted: August 8, 2013

Corresponding author: Dr. Seiji Ohtori,  
Department of Orthopaedic Surgery,  
Graduate School of Medicine,  
Chiba University, 1-8-1 Inohana,  
Chuo-ku, Chiba 260-8670, Japan.  
Tel: 81-43-226-2117, Fax: 81-43-226-2116  
E-mail: sohtori@faculty.chiba-u.jp

The authors have no financial conflicts of interest.

**Purpose:** Bupivacaine is commonly used for the treatment of back pain and the diagnosis of its origin. Nonunion is sometimes observed after spinal fusion surgery; however, whether the nonunion causes pain is controversial. In the current study, we aimed to detect painful nonunion by injecting bupivacaine into the disc space of patients with nonunion after anterior lumbar interbody fusion (ALIF) surgery for discogenic low back pain. **Materials and Methods:** From 52 patients with low back pain, we selected 42 who showed disc degeneration at only one level (L4-L5 or L5-S1) on magnetic resonance imaging and were diagnosed by pain provocation on discography and pain relief by discoblock (the injection of bupivacaine). They underwent ALIF surgery. If the patients showed low back pain and nonunion 2 years after surgery, we injected bupivacaine into the nonunion disc space. Patients showing pain relief after injection of bupivacaine underwent additional posterior fixation using pedicle screws. These patients were followed up 2 years after the revision surgery. **Results:** Of the 42 patient subjects, 7 showed nonunion. Four of them did not show low back pain; whereas 3 showed moderate or severe low back pain. These 3 patients showed pain reduction after injection of bupivacaine into their nonunion disc space and underwent additional posterior fixation. They showed bony union and pain relief 2 years after the revision surgery. **Conclusion:** Injection of bupivacaine into the nonunion disc space after ALIF surgery for discogenic low back pain is useful for diagnosis of the origin of pain.

**Key Words:** Lumbar, spine, bupivacaine, pain, intervertebral disc

## © Copyright:

Yonsei University College of Medicine 2014

This is an Open Access article distributed under the terms of the Creative Commons Attribution Non-Commercial License (<http://creativecommons.org/licenses/by-nc/3.0>) which permits unrestricted non-commercial use, distribution, and reproduction in any medium, provided the original work is properly cited.

## INTRODUCTION

Low back pain (LBP) is a common clinical problem and is of considerable socio-

economic importance. However, there is currently little information on the pathogenesis of this disease. Although any of the spinal structures (intervertebral discs, facet joints, vertebral bodies, ligaments, or muscles) could be a source of LBP, the most likely cause is a lumbar intervertebral disc.<sup>1-3</sup>

For surgical treatment, the method of diagnosis of discogenic LBP is important. Generally, diagnosis of discogenic LBP is determined by observation of a “black disc” on magnetic resonance imaging (MRI) and pain provocation by discography.<sup>4,5</sup> However, the reliability of discography has been controversial.<sup>6,7</sup> A randomized controlled trial showed that, compared with discography, pain relief after injection of a small amount of bupivacaine into the painful disc is a useful tool for the diagnosis of discogenic LBP, and diagnosis by discoblock improved surgical results.<sup>8,9</sup>

Generally, diagnosis of discogenic LBP is difficult and requires several methods. Therefore, if patients show both continuous LBP and nonunion after fusion surgery, the situation is even more complex. Indeed, several randomized trials have compared surgical to nonsurgical treatment of chronic LBP and arrived at conflicting conclusions.<sup>10</sup> For these reasons, it is unclear whether the continuous pain originates from a misdiagnosis of primary discogenic pain or nonunion. Furthermore, some authors have reported a discrepancy between bone union and clinical results in patients with spinal stenosis associated with degenerative lumbar spondylolisthesis, and good results in nonunion cases.<sup>11,12</sup> In patients with lumbar spinal stenosis, LBP can originate from intervertebral discs, facet joints, and spinal nerve roots. Decompression is effective for postoperative LBP, therefore, it is difficult to directly compare postsurgical LBP between a union and nonunion group.

There have been a few reports of discography or discoblock at fused levels to detect postoperative back pain. Ploumis, et al.<sup>13</sup> have reported a case of chronic back pain following two-level interbody and posterolateral fusion in the lumbar spine that was evaluated with bupivacaine injection into the nonunion space. Bupivacaine injection into an apparently fused disc space with an interbody device may be helpful in patients with persistent postsurgical back pain caused by nonunion.

In the current study, we focused on patients with discogenic LBP, but without radicular back pain or leg pain, because the LBP was thought to originate only from discs. We aimed to examine whether injection of bupivacaine

into the disc space can detect painful nonunion after anterior lumbar interbody fusion (ALIF) surgery in patients with discogenic LBP.

## MATERIALS AND METHODS

The ethics committee of our institution approved the protocol for the human procedures used in this study and informed written consent was obtained from each subject.

### Patients

Fifty-two patients with LBP only, continuing for at least 3 years, with no accompanying radicular pain were investigated. Patients showed only one level of disc degeneration on MRI. Patients who had severe spondylolysis on disc degeneration with two or more level lesions were excluded. Patients who had previously undergone spinal surgery were also excluded.

### Discography or discoblock for the diagnosis of discogenic LBP before first surgery

Discography or discoblock at one intervertebral disc level was performed using a standard posterolateral approach with a 22-gauge needle (Becton Dickinson, Franklin Lakes, NJ, USA) in all 52 patients. For discography, the needle was inserted into the center of the disc under fluoroscopic control. Isovist 240 (range, 0.4-3.2 mL; Schering, Berlin, Germany) was injected into each disc until severe pain was provoked or until contrast medium was seen to leak out of the disc into the spinal canal. For discoblock, 0.75 mL of 0.5% bupivacaine was injected into the disc. We defined the treatment as “effective” if patients indicated a Visual Analogue Scale (VAS) pain score at 2 hours that was less than 50% of their initial VAS score before injection.

When pain was both provoked during the discography and decreased after the discoblock, we confirmed a diagnosis of discogenic LBP.

### Surgery

Forty-two patients diagnosed with discogenic pain showing 1) one level disc degeneration on MRI, 2) pain provocation on discography, and 3) pain relief after discoblock, underwent anterior discectomy and fusion surgery. We first performed the discectomy, then cut the endplate at a thickness of 2 mm on both sides, and performed interbody fusion using iliac bone.

### Radiographic and clinical evaluation

Radiography was used to evaluate bone union 2 years after surgery. X-ray images of profile views at flexion and extension positions were obtained. CT was performed to evaluate bone union. Evaluation of bone union was blinded and conducted by 3 surgeons. Fusion was used to define bone union if at least 2 of the observers concurred.

### Pain score

We evaluated the change in LBP before and after surgery. To evaluate pain, a VAS score (0, no pain; 10, worst pain) and the Oswestry Disability Index (ODI) for LBP were recorded before, 2 years after first surgery, and 2 years after revision surgery, and they were compared.

### Revision surgery

Of the 52 patients in the study, 42 underwent ALIF surgery, and some of them showed both nonunion and LBP. We evaluated whether the pain originated from the nonunion site or not, and repeated the discography and discoblock. For discography, Isovist 240 (range, 0.4-1.0 mL; Schering) was injected into the nonunion disc space until severe pain was provoked or until contrast medium was seen to leak out of the disc into the spinal canal. For discoblock, 0.4 mL of 0.5% bupivacaine was injected into the nonunion site. When pain was both provoked during the discography and decreased after the discoblock, we confirmed a diagnosis of pain from the nonunion site. These patients underwent posterior fusion surgery at one level. The single-level posterior fusion was performed using pedicle screws and an iliac bone graft on the lamina. Bilateral facet fusion was performed in all patients. We did not use other osteoconductive products for spinal fusion. We finally evaluated their pain score 2 years after the revision surgery.

### Statistical analysis

Data were compared using an unpaired t-test,  $\chi^2$  test, and one-way analysis of variance for repeated measurements.  $p < 0.05$  was considered statistically significant.

**Table 2. Surgical Results 2 Years after 1st Surgery**

	Union group	Non-union group	Statistical analysis
Number of patients	35	7	$p=0.015$
Sex	Male: 26, Female: 9	Male: 4, Female: 3	
Age, mean±SEM (range), yrs	36±5 (18-48)	35±6 (16-44)	$p=0.50$
Pain score			
Visual Analogue Scale low back pain	2.0±1.9	3.8±2.0	$p=0.45$
Oswestry Disability Index	16±7	22±6	$p=0.43$

## RESULTS

Table 1 shows the demographic characteristics of the 52 patient subjects before ALIF surgery. Of these 52 patients, 42 were diagnosed with discogenic LBP because pain was both provoked during the discography and decreased after the discoblock. These 42 patients underwent ALIF revision surgery. No patient had dropped out at 2 years after surgery. Thirty-five patients (83%) showed union and 7 (17%) showed nonunion 2 years after the first surgery (Table 2). Table 2 shows characteristics of the union and nonunion groups. Pain scores in the two groups significantly improved 2 years after the first surgery (Table 1 and 2). VAS score and ODI in the union group were significantly better than those in the nonunion group 2 years after the first surgery (Table 2).

Table 3 shows characteristics of the 7 patients in the nonunion group. Of these 7 patients, 3 showed LBP and 4 did not. The VAS score and ODI in the LBP group were significantly worse than those in the group without LBP before revision surgery (Table 2).

Table 4 shows results of discography, discoblock, and revision surgery for LBP in the 3 patients in the nonunion group. These 3 patients had pain provocation after discography and relief after discoblock. They underwent posterior fixation surgery and their pain scores significantly improved 2 years after this revision surgery (Figs. 1 and 2).

**Table 1. Demographic Characteristics**

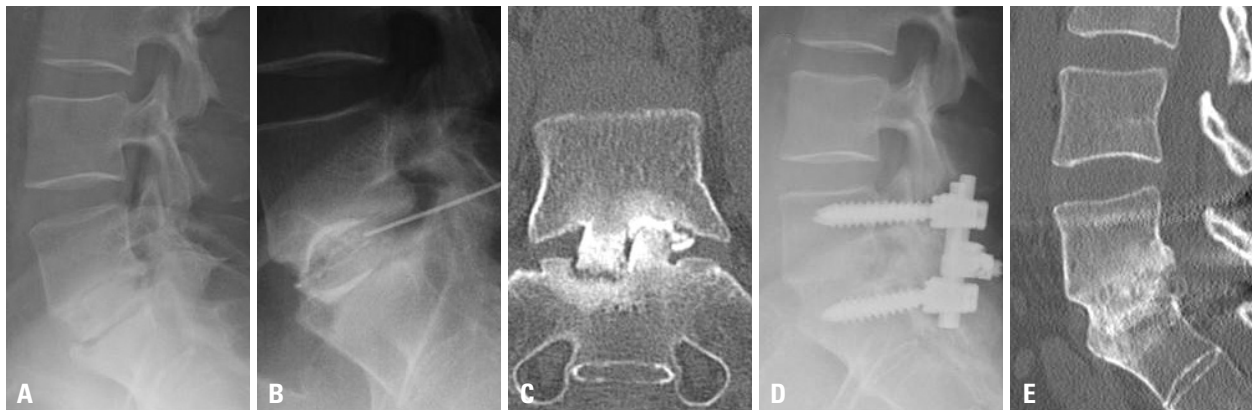
Number of patients	52
Sex	Male: 35, Female: 17
Age, mean±SEM (range), yrs	36±6 (16-48)
Symptom duration, mean (range), yrs	7 (4-20)
Follow-up, mean (range), yrs	3.5 (2-5)
MRI findings	
Level	L2/3: 3 L4/5: 29 L5/S1: 20
Pain score	
Visual Analogue Scale low back pain	8.5±2.3
Oswestry Disability Index	52±10

**Table 3.** Detail of Non-Fusion Group

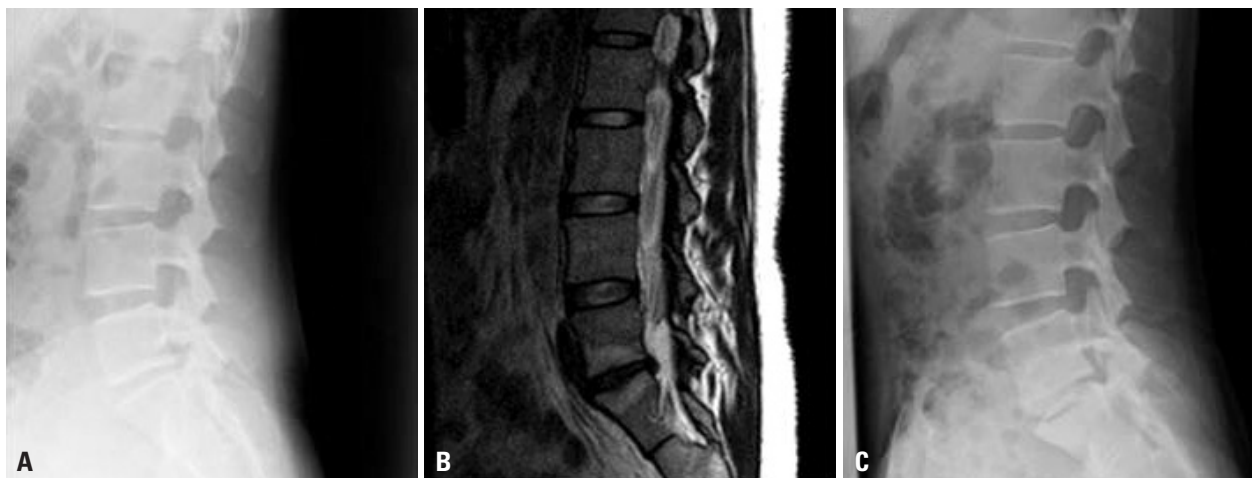
	Low back pain (+)	Low back pain (-)	Statistical analysis
Number of patients	3	4	$p=0.25$
Sex	Male: 2, Female: 1	Male: 2, Female: 2	
Age, mean $\pm$ SEM (range), yrs	34 $\pm$ 5 (16-44)	36 $\pm$ 6 (20-42)	$p=0.50$
Pain score			
Visual Analogue Scale low back pain	6.5 $\pm$ 2.0	1.8 $\pm$ 2.0	$p=0.033$
Oswestry Disability Index	48 $\pm$ 7	10 $\pm$ 6	$p=0.03$

**Table 4.** Results of Discoblock and Revision Surgery in Low Back Pain (+) of Non-Union Group

			Statistical analysis
Number of patients	3		
Pain provocation after discography	3		
Pain reduction after discoblock	3		
Pain score			
Visual Analogue Scale low back pain	6.5 $\pm$ 2.0 (before revision surgery)	2.0 $\pm$ 2.2 (2 yrs after revision surgery)	$p=0.02$
Oswestry Disability Index	48 $\pm$ 7 (before revision surgery)	18 $\pm$ 8 (2 yrs after revision surgery)	$p=0.04$



**Fig. 1.** A 35-year-old man with LBP and nonunion after ALIF surgery at L5/S1 level (A). The patient showed LBP. Pain was both provoked during the discography and decreased after the discoblock (B: X-ray film, and C: CT). 2 years after revision surgery, complete union was achieved and the patient did not show pain (D: X-ray film, and E: CT). LBP, low back pain; ALIF, anterior lumbar interbody fusion.



**Fig. 2.** A 28-year-old woman without LBP and nonunion after ALIF surgery. (A and B) Before surgery at L5-S1. (C) Nonunion after ALIF surgery at L5-S1. LBP, low back pain; ALIF, anterior lumbar interbody fusion.

## DISCUSSION

In the current study, 17% of patients (7) with discogenic LBP showed nonunion after ALIF surgery. Of these 7 patients, 3 showed LBP and pain relief after injection of bupivacaine into their disc space, and good results after revision surgery. We concluded that injection of bupivacaine into the disc space of patients with nonunion after ALIF surgery and discogenic LBP is useful for diagnosis of the origin of their pain.

In the current study, VAS score and ODI in the union group were significantly better than those in the nonunion group 2 years after their first surgery. Some authors have reported better surgical results for back pain in patients with union compared with nonunion.<sup>8,9,14</sup> By contrast, however, others have reported a discrepancy between bone union and clinical results.<sup>11,12</sup>

Fischgrund, et al.<sup>11</sup> reported that there was no association with successful fusion and surgical outcome after surgery of degenerative lumbar spondylolisthesis. Fifty patients who had degenerative lumbar spondylolisthesis underwent fusion surgery. Thirty-six % of patients showed non-union after surgery. However, they showed better clinical results compared decompressive laminectomy alone.<sup>12</sup>

In patients with lumbar spinal stenosis, LBP may originate from the intervertebral disc, facet joints, or spinal nerve roots. Therefore, it is difficult to compare postsurgical LBP between the union and nonunion groups. In the current study, the patient subjects only had discogenic LBP, and this LBP was thought to originate only from intervertebral discs. The current findings led us to conclude that union leads to superior surgical results in discogenic LBP patients, because other sites of back pain origin were excluded.

Ploumis, et al.<sup>13</sup> have reported a case of chronic back pain following two-level interbody and posterolateral fusion in the lumbar spine. They injected 5 mL of the contrast agent iohexol (240 mg/mL), followed by 2 mL of 0.5% bupivacaine into the L4-L5 interspace where there was uncertain radiographic fusion, and the patient noticed, essentially, complete resolution of his pain for the duration of the anesthesia. The patient underwent revision surgery, and subsequently achieved pain relief. These investigators concluded that injection of bupivacaine into the disc space could be used for diagnosis in cases of previous anterior interbody fusion with a cage, continuing back pain, and uncertain ra-

diographic fusion. In the current study, 3 patients showed LBP after ALIF surgery where there was nonunion. They showed pain relief after injection of bupivacaine into the disc space, and good results after revision surgery. We concluded that injection of bupivacaine into the disc space of patients with discogenic LBP and nonunion after ALIF surgery is useful for diagnosing the origin of their pain.

However, bupivacaine has been found to be chondrotoxic *in vitro* and several studies have suggested a dose and time-dependent chondrotoxicity of bupivacaine.<sup>15-17</sup> Furthermore, an apparently toxic effect of 0.5% bupivacaine on disc cells and articular chondrocytes *in vitro* has been reported.<sup>18</sup> These reports indicated that 0.5% bupivacaine had an apparently toxic effect on disc cells and articular chondrocytes of animals and humans *in vitro*.<sup>15-19</sup> An effect of 0.5% bupivacaine on articular chondrocytes in an *in vivo* model has been reported; however, the effect was somewhat different from the effects obtained *in vitro*.<sup>20</sup> Rats receiving 0.5% bupivacaine into the knee joint were observed for 6 months. The articular surfaces of joints injected with bupivacaine remained intact on gross and histological evaluation. It has been reported that radiological and MRI findings did not show acceleration of intervertebral disc degeneration within 5 years of a single injection of bupivacaine into human discs.<sup>21</sup> Therefore, we conclude that there is a difference in the effect of bupivacaine on discs *in vitro* and clinically, and that injection of bupivacaine into the disc space is safe for patients with discogenic LBP.

This study has several limitations. First, we examined only a limited number of patients. Second, 3 patients showed LBP and pain relief after injection of bupivacaine into their disc space, and good results after revision surgery; however, the number of patients is quite small, and is probably not sufficient to make the current conclusions. Third, the effect of single or multiple injections of bupivacaine, the volume of bupivacaine, and its concentration were not examined in the current study. Fourth, there was no control group in the current study. It is desirable to perform posterior fusion in patients with painful pseudoarthrosis without bupivacaine injection. Thus, larger numbers of patients, a control group, and the effects of bupivacaine administration need to be evaluated to strengthen the current findings.

In conclusion, it is difficult to detect whether pseudoarthrosis is painful. Injection of bupivacaine into the disc space of patients with discogenic LBP and nonunion after ALIF surgery is useful for diagnosing the origin of their pain.

## REFERENCES

1. Nachemson AL. The lumbar spine, an orthopaedic challenge. *Spine* 1976;1:59-71.
2. Mooney V. Presidential address. International Society for the Study of the Lumbar Spine. Dallas, 1986. Where is the pain coming from? *Spine (Phila Pa 1976)* 1987;12:754-9.
3. Deyo RA, Weinstein JN. Low back pain. *N Engl J Med* 2001;344:363-70.
4. Pauza KJ, Howell S, Dreyfuss P, Peloza JH, Dawson K, Bogduk N. A randomized, placebo-controlled trial of intradiscal electrothermal therapy for the treatment of discogenic low back pain. *Spine J* 2004;4:27-35.
5. Shuff C, An HS. Artificial disc replacement: the new solution for discogenic low back pain? *Am J Orthop (Belle Mead NJ)* 2005;34:8-12.
6. Buenaventura RM, Shah RV, Patel V, Benyamin R, Singh V. Systematic review of discography as a diagnostic test for spinal pain: an update. *Pain Physician* 2007;10:147-64.
7. Carragee EJ, Lincoln T, Parmar VS, Alamin T. A gold standard evaluation of the "discogenic pain" diagnosis as determined by provocative discography. *Spine (Phila Pa 1976)* 2006;31:2115-23.
8. Ohtori S, Kinoshita T, Yamashita M, Inoue G, Yamauchi K, Koshi T, et al. Results of surgery for discogenic low back pain: a randomized study using discography versus discoblock for diagnosis. *Spine (Phila Pa 1976)* 2009;34:1345-8.
9. Ohtori S, Koshi T, Yamashita M, Yamauchi K, Inoue G, Suzuki M, et al. Surgical versus nonsurgical treatment of selected patients with discogenic low back pain: a small-sized randomized trial. *Spine (Phila Pa 1976)* 2011;36:347-54.
10. Mirza SK, Deyo RA. Systematic review of randomized trials comparing lumbar fusion surgery to nonoperative care for treatment of chronic back pain. *Spine (Phila Pa 1976)* 2007;32:816-23.
11. Fischgrund JS, Mackay M, Herkowitz HN, Brower R, Montgomery DM, Kurz LT. 1997 Volvo Award winner in clinical studies. Degenerative lumbar spondylolisthesis with spinal stenosis: a prospective, randomized study comparing decompressive laminectomy and arthrodesis with and without spinal instrumentation. *Spine (Phila Pa 1976)* 1997;22:2807-12.
12. Herkowitz HN, Kurz LT. Degenerative lumbar spondylolisthesis with spinal stenosis. A prospective study comparing decompression with decompression and intertransverse process arthrodesis. *J Bone Joint Surg Am* 1991;73:802-8.
13. Ploumis A, Pinto MR, Schellhas KP. Disc space injection with marcaine as a method to evaluate painful nonunion of an interbody fusion device: a case report. *Spine J* 2007;7:74-8.
14. Vamvanij V, Fredrickson BE, Thorpe JM, Stadnick ME, Yuan HA. Surgical treatment of internal disc disruption: an outcome study of four fusion techniques. *J Spinal Disord* 1998;11:375-82.
15. Chu CR, Izzo NJ, Papas NE, Fu FH. In vitro exposure to 0.5% bupivacaine is cytotoxic to bovine articular chondrocytes. *Arthroscopy* 2006;22:693-9.
16. Dogan N, Erdem AF, Erman Z, Kizilkaya M. The effects of bupivacaine and neostigmine on articular cartilage and synovium in the rabbit knee joint. *J Int Med Res* 2004;32:513-9.
17. Gomoll AH, Kang RW, Williams JM, Bach BR, Cole BJ. Chondrolysis after continuous intra-articular bupivacaine infusion: an experimental model investigating chondrotoxicity in the rabbit shoulder. *Arthroscopy* 2006;22:813-9.
18. Lee H, Sowa G, Vo N, Vadala G, O'Connell S, Studer R, et al. Effect of bupivacaine on intervertebral disc cell viability. *Spine J* 2010;10:159-66.
19. Wang D, Vo NV, Sowa GA, Hartman RA, Ngo K, Choe SR, et al. Bupivacaine decreases cell viability and matrix protein synthesis in an intervertebral disc organ model system. *Spine J* 2011;11:139-46.
20. Chu CR, Coyle CH, Chu CT, Szczodry M, Seshadri V, Karpie JC, et al. In vivo effects of single intra-articular injection of 0.5% bupivacaine on articular cartilage. *J Bone Joint Surg Am* 2010;92:599-608.
21. Ohtori S, Inoue G, Orita S, Eguchi Y, Ochiai N, Kishida S, et al. No acceleration of intervertebral disc degeneration after a single injection of bupivacaine in young age group with follow-up of 5 years. *Asian Spine J* 2013;7:212-7.