

Received: 2020.05.11

Accepted: 2020.08.19

Available online: 2020.09.09

Published: 2020.10.17

Rare Human Epidermal Growth Factor Receptor 2 (HER-2)-Positive Neuroendocrine Carcinoma of the Breast: A Case Report with 9-Year Follow-up

Authors' Contribution:

Study Design A
Data Collection B
Statistical Analysis C
Data Interpretation D
Manuscript Preparation E
Literature Search F
Funds Collection G

ACD 1 **Inga Marijanović**
DEF 1 **Marija Kraljević**
DEF 1 **Teo Buhovac**
CD 2 **Dragana Karan Križanac**

1 Department of Oncology, University Clinical Hospital Mostar, Mostar, Bosnia and Herzegovina
2 Department of Pathology, Cytology and Forensic Medicine, University Clinical Hospital Mostar, Mostar, Bosnia and Herzegovina

Corresponding Author: Marija Kraljević, e-mail: marija.kraljevic91@gmail.com
Conflict of interest: None declared

Patient: Female, 70-year-old
Final Diagnosis: Neuroendocrine carcinoma of the breast
Symptoms: None
Medication: —
Clinical Procedure: —
Specialty: Oncology





Objective: Rare disease
Background: Neuroendocrine carcinoma of the breast (NECB) is very rare, accounting for 0.1% of all breast tumors and less than 1% of all neuroendocrine tumors. Most NECBs are hormone receptor-positive and human epidermal growth factor receptor 2 (HER-2)-negative and more than 50% are the luminal B subtype. Because prospective studies of NECB are lacking, treatment is the same as for other breast tumors.

Case Report: A 70-year-old woman was diagnosed with NECB in February 2011. She underwent radical right mastectomy and right axillary node dissection. Final histopathological examination revealed NECB with positive axillary nodes (N1). The tumor cells were 100% positive for estrogen receptors and 10% positive for progesterone receptors. The HER-2 status was 3+. According to the Tumor, Node, Metastasis (TNM) Classification of Malignant Tumors, the pathologic stage was IIB - pT2pN1cM0. The histologic grade was 2 and the Ki-67 proliferation index was 5.7%. The patient received adjuvant chemotherapy, radiation therapy, IV trastuzumab, and endocrine therapy. After 9 years of follow-up, she remains disease-free.

Conclusions: As far as we know, this is only the second report describing treatment of HER-2-positive NECB with trastuzumab. A literature review shows that it is the first report of treatment of HER-2-positive primary NECB with adjuvant trastuzumab. In similar cases, long-term follow-up is recommended because of the potential for multiple metastases of NECB even years after completion of adjuvant therapy.

MeSH Keywords: Breast Neoplasms • Carcinoma, Neuroendocrine • Receptor, erbB-2

Full-text PDF: <https://www.amjcaserep.com/abstract/index/idArt/925895>

 1265   2  10



Background

Neuroendocrine carcinoma of the breast (NECB) is rare, accounting for 0.1% of all breast tumors and less than 1% of all neuroendocrine tumors [1]. It can present histologically as another subtype of breast cancer or as primary breast cancer if immunohistochemical neuroendocrine markers are positive in more than 50% of tumor cells [2]. Most NECBs are hormone receptor-positive, human epidermal growth factor receptor 2 (HER-2) status is almost always negative, and more than 50% of the tumors are of the luminal B subtype [3]. The clinical presentation of NECB is no different than that of a typical breast tumor. Because of a lack of prospective studies about NECB, treatment for it is the same as is typical for other breast tumors. Here, we present a case report of HER-2-positive NECB in a 70-year-old woman with 9-year follow-up.

Case Report

A 70-year-old woman was diagnosed with NECB in February 2011. On screening mammography, a well-defined lesion was detected in the upper inner quadrant of the right breast. No microcalcifications were identified. Ultrasound showed a hypoechogenic mass measuring 30 mm in its greatest diameter. No carcinoid-associated syndrome was present. Results of laboratory tests, including for the tumor markers carcinoembryonic antigen and CA 15-3, were within the reference range. Further examination, including bone scintigraphy, chest X-ray, and abdominal ultrasound, showed no signs of metastatic disease. After discussion between the patient and the surgeon, a tumorectomy-excisional biopsy was performed and the specimen was sent for intraoperative analysis. When the pathology confirmed that it was a malignant tumor, a right-sided radical mastectomy and right axillary dissection were performed. No sentinel lymph node biopsy was performed because it was not possible in our institution at that time.

Before surgery, the patient did not undergo core biopsy. Macroscopically, the resected tumor measured 3×2×2 cm (pT2). One of 8 axillary lymph nodes were positive (pN1). Microscopically, the tumor cells contained polymorphic vesicular nuclei and prominent nucleoli. Rosette-like spaces also were evident. Histopathological examination revealed NECB (well-differentiated neuroendocrine tumor of the breast, according to the World Health Organization [WHO] 2012 classification). The histologic grade of the tumor was 2. Immunohistochemical analysis showed that the tumor cells were positive for chromogranin A (CgA) (Figure 1) and also for neuron-specific enolase (NSE). Immunohistochemical staining for synaptophysin was non-specific. Testing for additional immunohistochemical markers showed that the tumor cells were negative for thyroid transcription factor 1, napsin A, and CDX2, which excluded metastatic carcinoma.

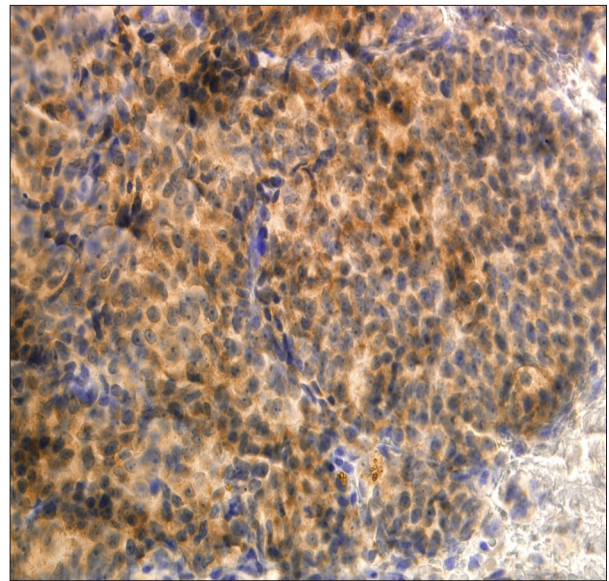


Figure 1. Immunohistochemical staining with anti-chromogranin A (CgA) antibody. More than 50% of the tumor cells were positive for CgA (×400).

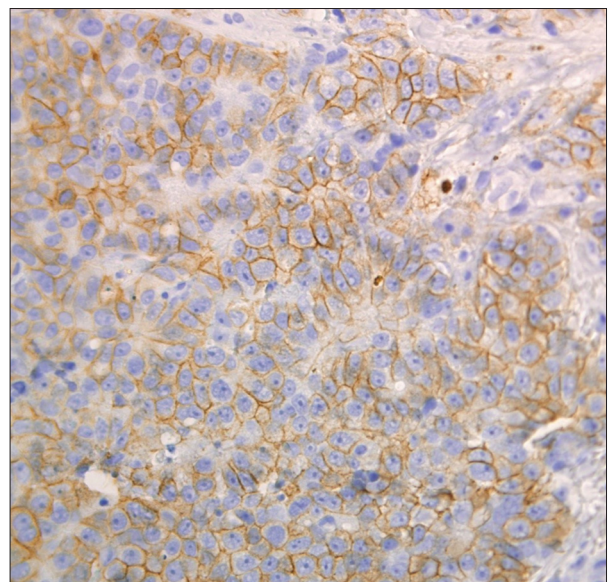


Figure 2. Immunohistochemical staining with anti-HER2/neu antibody. The HER-2 status was 3+ with strong membranous positivity (×400).

The tumor cells were 100% estrogen receptor (ER)-positive and 10% progesterone receptor (PR)-positive. The HER-2 status was 3+ (Figure 2). Because immunohistochemical staining for HER2 was positive in more than 30% of tumor cells, corresponding to a score of 3, *in situ* hybridization was not performed. According to the Tumor, Node, Metastasis (TNM) Classification of Malignant Tumors, the pathologic stage of the tumor was IIB – pT2pN1cM0. The Ki-67 proliferation index was 5.7%.

Following surgery, the patient received adjuvant chemotherapy with FAC (5-fluorouracil [500 mg/m²] plus doxorubicin [50 mg/m²] plus cyclophosphamide [500 mg/m²]) on Day 1 every 3 weeks for 6 cycles. The plan for treatment thereafter was adjuvant radiation to the chest wall and regional lymphatics plus IV trastuzumab (loading dose of 8 mg/kg then 6 mg/kg every 3 weeks for up to 1 year) plus endocrine treatment with an aromatase inhibitor (letrozole 2.5 mg once daily for 5 years). The patient completed the adjuvant endocrine treatment in September 2017. She tolerated therapy well, with no adverse or unanticipated events. She is still being monitored clinically and has had no local recurrence or distant metastasis after 9 years of surveillance.

Discussion

NECB is extremely rare and the incidence is believed to range from less than 1% to 5% of breast carcinomas, accounting for less than 1% of all neuroendocrine tumors [1,3].

In 2012, the WHO classified neuroendocrine breast neoplasms into 3 categories: well-differentiated neuroendocrine tumors; poorly-differentiated/small cell carcinomas; and invasive breast carcinomas with neuroendocrine differentiation [4]. Because specific immunohistochemical neuroendocrine markers are not commonly used to diagnose breast cancer, the real incidence of NECB is hard to estimate [3].

The most sensitive and specific neuroendocrine markers for NECB are CgA and chromogranin B and synaptophysin [5]; sometimes NSE also can be found [3]. Most NECBs are positive for ER and PR receptors, whereas HER-2 receptors are almost always only sporadically expressed and the proliferation index is often high (Ki-67 >14%) [3]. The immunophenotype of our patient's tumor (ER+; PR+; Ki-67 5.7%, HER-2-positive) corresponded to the luminal B-like (HER-2 positive) molecular subtype.

Although the age of occurrence of NECB has been reported to range from 20 to 83 years [6], it is more often diagnosed in women in their 60s and 70s [3]. Our patient was diagnosed with NECB when she was 70 years old.

Primary NECB does not differ from various other types of breast cancer in clinical presentation. It is commonly seen as a solitary breast mass with positive or negative axillary lymph node status. There are also no specific radiological characteristics of primary NECB [3].

An accurate and definitive diagnosis of NECB can only be made with surgery or with core needle biopsy because the tumor's cytological characteristics after fine-needle aspiration cytology

are almost identical to those of invasive ductal carcinoma (IDC) and intraductal papilloma [6,7].

There is no established conventional treatment protocol for patients with NECB because of the rarity of the disease. Surgery plays an important role in treatment of early NECB, and the choice of procedure depends on the tumor position and the clinical stage of the disease [8].

Chemotherapy can be used as adjuvant or as neoadjuvant therapy. Patients who are at increased risk of relapse should be treated with adjuvant chemotherapy. Those with locally advanced or inoperable NECB should be treated with neoadjuvant chemotherapy. Adjuvant endocrine therapy is appropriate for patients with NECB that is hormone receptor-positive [6]. Because treatment the same as for IDC of the breast has been suggested for patients with NECB, if chemotherapy is indicated, a protocol containing anthracyclines and/or taxanes should be selected [3].

The role of anti-HER-2 therapy for NECB is unclear because of lack of data on and expression of this receptor in the disease. However, it is presumed that it is the same as in other invasive breast carcinomas, therefore, anti-HER-2 therapy also should be considered for HER-2-positive NECB [3].

A literature review shows that ours is the first description of use of adjuvant trastuzumab to treat HER-2-positive primary NECB. In 2012, Yavas et al. reported on a case of HER-2-positive NECB in which the patient rejected any treatment other than surgery, and therefore, did not receive adjuvant trastuzumab [9]. In 2016, Gevorgyan et al. reported a case of HER-2-positive NECB with bone metastasis, which was the first description of use of trastuzumab to treat the disease [10]. In that case, trastuzumab was used in proven metastatic HER-2-positive NECB, not in the adjuvant setting.

The prognosis for NECB is no different than for other invasive breast carcinomas and it seems to be correlated with the stage of disease [2]. In the present case, the patient had 2 poor prognostic factors: lymph node involvement and HER-2 positivity. Long-term follow-up of patients with NECB is recommended because multiple metastases are possible even years after adjuvant treatment [3].

Conclusions

As far as we know, this is the second case of HER-2 positive NECB treated with trastuzumab to be described. According to a literature review, it is the first case report of treatment with the drug in the adjuvant setting for HER-2-positive primary NECB. After 9 years of follow-up, our patient is still free of the disease.

Conflict of interest

None.

References:

1. Ogawa H, Nishio A, Satake H et al: Neuroendocrine tumor in the breast. *Radiat Med*, 2008; 26: 28–32
2. Marinova L, Malinova D, Vicheva S: Primary neuroendocrine carcinoma of the breast: Histopathological criteria, prognostic factors, and review of the literature. *Case Rep Pathol*, 2016; 2016: 6762085
3. Inno A, Bogina G, Turazza M et al: Neuroendocrine carcinoma of the breast: Current evidence and future perspectives. *Oncologist*, 2016; 21: 28–32
4. Tan PH, Schnitt SJ, van de Vijver MJ et al: Papillary and neuroendocrine breast lesions: The WHO stance. *Histopathology*, 2015; 66: 761–70
5. Righi L, Sapino A, Marchiò C et al: Neuroendocrine differentiation in breast cancer: Established facts and unresolved problems. *Semin Diagn Pathol*, 2010; 27: 69–76
6. Angarita FA, Rodríguez JL, Meek E et al: Locally-advanced primary neuroendocrine carcinoma of the breast: Case report and review of the literature. *World J Surg Oncol*, 2013; 11: 128–38
7. Zhu Y, Li Q, Gao J et al: Clinical features and treatment response of solid neuroendocrine breast carcinoma to adjuvant chemotherapy and endocrine therapy. *Breast J*, 2013; 19: 382–87
8. Jablon LK, Somers RG, Kim PY: Carcinoid tumor of the breast: Treatment with breast conservation in three patients. *Ann Surg Oncol*, 1998; 5: 261–64
9. Yavas G, Karabagli P, Araz M et al: HER-2 positive primary solid neuroendocrine carcinoma of the breast: A case report and review of the literature. *Breast Cancer*, 2015; 22(4): 432–36
10. Gevorgyan A, Bregni G, Galli G et al: HER2-positive neuroendocrine breast cancer: Case report and review of literature. *Breast Care*, 2016; 11: 424–26