

## CASE REPORT

## Epidermoid cyst localized in the palatine tonsil

**Keles Erol, Kaplama Mehmet Erkan, Dolen Tolga, Cobanoglu Bengu<sup>1</sup>**

*Departments of Otorhinolaryngology and <sup>1</sup>Pathology, Firat University, Medical Faculty, Elazig, Turkey*

**Address for correspondence:**

*Dr. Kaplama Mehmet Erkan,  
Department of Otorhinolaryngology, Firat  
University, Medical Faculty, Elazig, Turkey.  
E-mail: drmehmeterkan@yahoo.com*

**ABSTRACT**

Epidermoid and dermoid cysts are benign, developmental lesions that can be encountered anywhere in the body. Our literature search did not result in a finding of any report of an epidermoid cyst located in the palatine tonsils. This is a report of a 42-year-old female patient who underwent a tonsillectomy for diagnostic purposes because of an epidermoid cyst arising from the tonsil which was confirmed by histology.

**Key words:** Dermoid cyst, epidermoid cyst, palatine tonsil

**INTRODUCTION**

Epidermoid and dermoid cysts are benign lesions developing from abnormal epithelial components of ectodermal tissue formed during the fetal period, or implanted epithelium arising after trauma or surgery.<sup>[1]</sup> These lesions, which can be seen anywhere in the body, occur in the head and neck area in approximately 7% of cases.<sup>[2,3]</sup> Those in the oral cavity are mostly in the floor of the mouth (in the sublingual, submental or submandibular areas) and in various other localizations including the labial, lingual or buccal mucosa.<sup>[4]</sup> Their incidence in the oral cavity makes up for 1.6% of the total occurrences and they constitute less than 0.01% of all the cystic lesions of the oral cavity.<sup>[5]</sup>

These cysts are termed “epidermoid” if they are enclosed in epithelium only, “dermoid” if they comprise skin appendages and “teratoid” if they include other tissues like muscle, cartilage or bone.<sup>[6]</sup> They are generally asymptomatic and grow slowly. Surgical excision is sufficient for cure.<sup>[7]</sup>

Even though reports of epidermoid cysts in the head and neck, especially those in the floor of the mouth, soft palate, lips, or the lingual and buccal epithelium can be found in the literature, but there is no report of an intratonsillar epidermoid cyst. We intend to report the case of a patient who underwent tonsillectomy for diagnostic purposes because of an epidermoid cyst arising from the tonsil and confirmed by histology.

**CASE REPORT**

A 42-year-old female came to our clinic for sore throat and difficulty in swallowing. ENT examination showed marked hypertrophy of the right tonsil in comparison with the contralateral one, and a smooth-surfaced mass near the upper pole of the tonsil [Figure 1]. No neck lymph nodes were palpable. A magnetic resonance imaging (MRI) examination was performed, which evidenced a protrusion of the clearly hypertrophic tonsil into the nasopharynx [Figure 2]. Contrast effects to suggest a malignancy were not found. Whole abdomen ultrasound examination yielded no pathological results. A right tonsillectomy was performed for diagnostic purposes after having obtained the patient's informed consent. The excised material was examined by light microscopy following hematoxylin and eosin staining. The tonsillar tissue, which included microscopic reactive follicles, showed occasional cystic cavities. It was interesting to note that these cavities contained keratin in a lamellar arrangement and their epithelium was of a squamous character [Figure 3]. These findings justified a diagnosis of epidermoid cyst localized in the tonsil. The patient was discharged on the first post-operative day in excellent condition; her follow-up, reaching 10 months, was entirely uneventful.

**DISCUSSION**

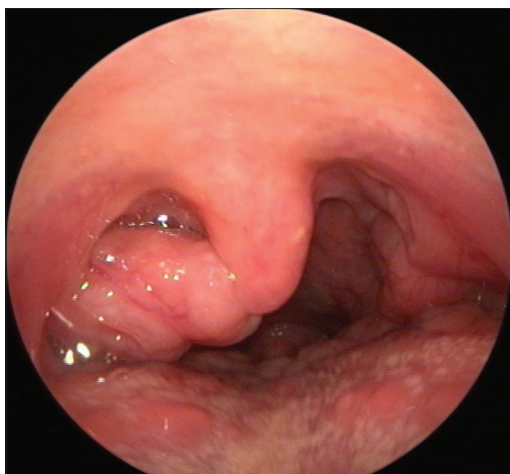
Epidermoid cysts are benign lesions that can develop anywhere in the body. They generally appear in areas where embryogenic elements fuse.<sup>[8]</sup> They can be classified as being either congenital or acquired. There is no developmental or histologic difference between the two.<sup>[9]</sup> Dermoid cysts have been classified by Meyer in 1955 as true dermoid cysts, epidermoid cysts and teratoid cysts.<sup>[10]</sup> A true dermoid cyst is lined with keratinized epithelium and contains skin appendages that could be described as hair follicles or sebaceous glands. An epidermoid cyst, on the other hand, is lined with simple squamous epithelium and its wall does not contain fibrous

**Access this article online****Quick Response Code:****Website:**

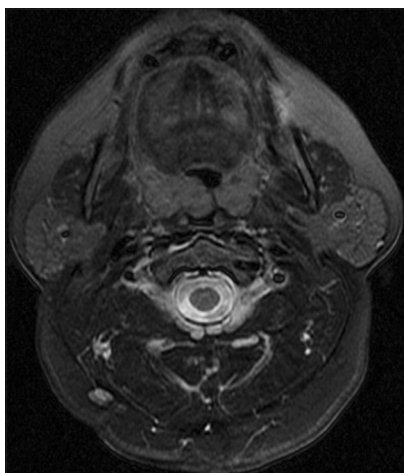
www.jomfp.in

**DOI:**

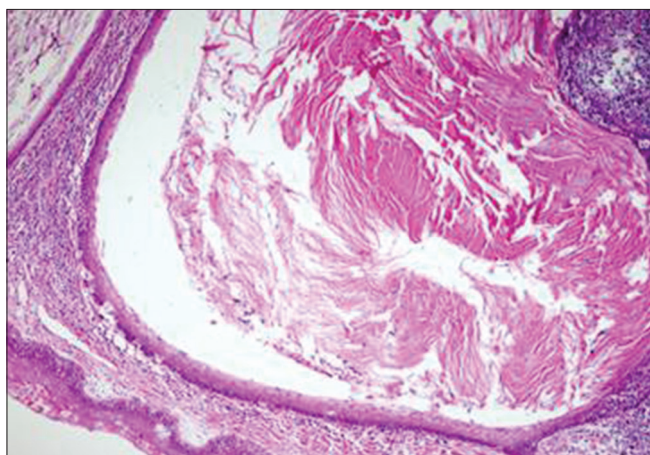
10.4103/0973-029X.110729



**Figure 1:** View of the asymmetrical hypertrophy of the right tonsil with a mass arising in its upper pole



**Figure 2:** View of the hypertrophic right palatine tonsil in T2-weighted MRI



**Figure 3:** Cystic cavity within the tonsillar tissue lined with keratinized epithelium. H and E, ×100

structures or skin appendages. A teratoid cyst may contain tissues ranging from simple squamous epithelium to ciliated cylindrical respiratory epithelium; its contents may be of ectodermal, mesodermal or endodermal in origin.<sup>[11,12]</sup>

A theory widely accepted today on the etiology of these lesions is their development from the epithelial remnants remaining isolated during the closure of the first and second branchial arches in the midline. Another theory is the development of cysts from abnormal inclusion of cells during surgery or trauma.<sup>[4]</sup> Even though the fact that our patient was aged 42 years would seem to favor the latter mechanism, she presented no history of surgery or trauma.

Epidermoid and dermoid cysts can be in any location of the body. A study on 1495 cases by New and Erich shows that their location is most frequently anal (44.5%) and ovarian (42.1%).<sup>[12]</sup> Cases of cysts in the head and neck area are only 7% of the total body.<sup>[2,3]</sup> In a study of 103 patients with diagnosis of epidermoid and dermoid cyst of the head and neck, 46.6% of these were orbital, 23.3% buccal and submental, 12.3% nasal, 10.7% cervical and 2.9% labial.<sup>[1]</sup> Various publications also report epidermoid cysts of the oral cavity in the soft palate, the uvula and the sublingual area.<sup>[1,9,13]</sup> However, we could not find a report of epidermoid cyst in a tonsil.

The male/female ratio of the patients with a diagnosis of epidermoid cyst is 3/13 and the age range of the large majority is 10-35 years.<sup>[13]</sup> Especially the latter fact leads to the thought that cyst formation could be stimulated by hormonal influence during puberty.<sup>[11]</sup> The fact that our patient was a 42-year-old female would also support such an idea.

The appearance of epidermoid cysts on MRI is variable according to their fluid contents and protein density. Often, though, they exhibit a low signal intensity with T1A sequences and a high signal intensity with T2A sequences.<sup>[14]</sup> The MRI performed in our patient showed a marked hypertrophy of the right tonsil, which was protruding into the nasopharynx. No contrast pattern suggestive of malignancy was seen. The fact that the appearance of the cyst in the MRI examination was not cystic could be due to the high protein density of its contents.

Treatment for these lesions is surgical excision of the cyst. It should be excised without opening because its contents could have an irritating effect on the surrounding fibrovascular tissue.<sup>[15]</sup> Recurrence after surgery is rare. A malignant evolution has only been seen in the teratoid type and was reported to have an incidence of 0.5%.<sup>[16,17]</sup> A tonsillectomy was performed in our patient; the cyst was excised within its capsule and the follow-up during 10 months was entirely uneventful.

While the expansion of lymphoid follicles within the tonsil is the most frequent cause of their hypertrophy, asymmetric hypertrophy must lead to the suspicion of diseases like tonsillar tumor, atypical infection, granulomatous disease or tumors of the parapharyngeal area. In a series of 49 patients with asymmetrical tonsils with normal neck examination

and normal overlying mucosa, only two (4.8%) cases were diagnosed with cancer.<sup>[18]</sup> A diagnostic tonsillectomy is indicated as asymmetrical tonsillar hypertrophy carries a potential risk of neoplastic transformation.<sup>[19]</sup> Our patient also had an asymmetrical appearance of the tonsils. Also, the mass covered by normal mucosa and arising from the upper pole was suspicious for the presence of tumor and the patient was subjected to diagnostic tonsillectomy.

In conclusion, epidermoid cysts, a rare occurrence in the head and neck area, can also be found inside the palatine tonsils and cause asymmetrical hypertrophy.

## REFERENCES

1. Kenichiro S, Kyotaro M, Takeshi U, Nobuo T, Takahiko S. Congenital epidermoid cyst arising in soft palate near uvula: A case report. *Bull Tokyo Dent Coll* 2010;51:207-11.
2. Turetschek K, Hospodka H, Steiner E. Case report: Epidermoid cyst of the floor of the mouth: Diagnostic imaging by sonography, computed tomography and magnetic resonance imaging. *Br J Radiol* 1995;68:205-7.
3. Jhams BC, Duraes GV, Jhams AC, Santos CR. Epidermoid cyst of the floor of the mouth: A case report. *J Can Dent Assoc* 2007;73:525-8.
4. Som PM, Curtin HD. *Head and Neck Imaging*. 3<sup>rd</sup> ed. Vol. 1. St. Louis: Mosby; 1996. p. 500-1.
5. Rajayogeswaran V, Eveson JW. Epidermoid cyst of the buccal mucosa. *Oral Surg Oral Med Oral Pathol* 1989;67:181-4.
6. Calderon S, Kaplan I. Concomitant sublingual and submental epidermoid cysts: A case report. *J Oral Maxillofac Surg* 1993;51:790-2.
7. Tsirevelou P, Papamantios M, Chlopsidis P, Zourou I, Skoulakis C. Epidermoid cyst of the floor of the mouth: Two case reports. *Cases J* 2009;2:9360:1-5.
8. Koca H, Seckin T, Sipahi A, Kaznac A. Epidermoid cyst in the floor of the mouth: Report of a case. *Quintessence Int* 2007;38:473-7.
9. Kandogan T, Koc M, Vardar E, Selek E, Sezgin O. Sublingual epidermoid cyst: A case report. *J Med Case Rep* 2007;1:87.
10. MEYER I. Dermoid cysts (dermoids) of the floor of the mouth. *Oral Surg Oral Med Oral Pathol* 1955;8:1149-64.
11. Vargas Fernandez JL, Lorenzo Rojas J, Aneiros Fernandez J, Sainz Quevedo M. Dermoid cyst of the floor of the mouth. *Acta Otorhinolaryngol Esp* 2007;58:31-3.
12. New GB, Erich JB. Dermoid cysts of the head and neck. *Surg Gynecol Obstet* 1937;65:48-55.
13. Lima SM, Chrcanovic BR, de Paula AM, Freire-Maia B, de Souza LN. Dermoid cyst of the floor of the mouth. *Sci World J* 2003;3:156-62.
14. Grossman RI, Yousem DM. *Neuroradiology The Requisites*. St. Louis: Mosby; 1994. p. 442-5.
15. Gnepp DR. *Diagnostic Surgical Pathology of The Head and Neck*, 2<sup>nd</sup> ed. Philadelphia Elsevier; 2009. p. 226-7.
16. Pancholi A, Raniga S, Vohra PA, Vaidya V. Midline submental epidermoid cyst: A Rare Case. *Internet J Otorhinolaryngol* 2006;4:2.
17. Damle MV, Irani DK, Hiranandani NL. Epidermoid cyst of the floor of the mouth: case report. *Bombay Hosp J* 2002;44.
18. Syms MJ, Birkmire-Peters DP, Holtel MR. Incidence of carcinoma in incidental tonsil asymmetry. *Laryngoscope* 2000;110:1807-10.
19. Kornblut AD. Non-neoplastic diseases of the tonsils and adenoids. In: Paparella MD, Shumrick DA, Gluckman JL, Meyerhoff WL, editors. *Otolaryngology*. 3<sup>rd</sup> ed, Vol. 3. Head and Neck. Philadelphia: WB Saunders Company; 1991. p. 2129-47.

**How to cite this article:** Erol K, Erkan KM, Tolga D, Bengu C. Epidermoid cyst localized in the palatine tonsil. *J Oral Maxillofac Pathol* 2013;17:148.

**Source of Support:** Nil. **Conflict of Interest:** None declared.