

## ONCOLOGY

# Surgical management of lip cancer

## *Il trattamento chirurgico dei tumori del labbro*

A. MORETTI, F. VITULLO, A. AUGURIO, A. PACELLA, A. CROCE

ENT Clinic, Department of Surgical, Experimental and Clinical Sciences, "G. D'Annunzio" University of Chieti-Pescara, Italy

## SUMMARY

Lip cancer is the most frequent malignant neoplasm of the oral cavity. The study reported herewith refers to the clinico-pathological features and surgical treatment of lip cancer. The most frequent tumour related to the lips is squamous cell carcinoma, with the lower lip more commonly involved than the upper lip. Typically, squamous cell carcinoma originates in the red lip, whereas basal cell carcinoma involves the white lip. The management of lip cancer involves the control not only of the primary tumours with oncologically appropriate margins and subsequent reconstruction to allow oral competence during the oral phase of swallowing, but also the possible metastatic spread to the neck. Reconstruction is a surgical challenge especially for advanced and extended lesions. A successful reconstruction depends on careful pre-operative planning, knowledge of the anatomy and use of the various surgical techniques. Lymph node neck metastases significantly reduce long-term survival. Although the management of the neck is controversial in lip cancer, particularly with respect to the neck, elective or curative supra-omohyoid neck dissection is the best choice for occult or evident loco-regional metastases. Early stage tumours have good prognostic, aesthetic and functional results after surgery compared to the treatment of advanced lesions, which alter the appearance and functionality of the lip. The Authors report their experience in the treatment of lip tumours at the primary site, considering reconstructive problems, together with management of neck metastases.

KEY WORDS: Lip • Malignant tumours • Surgical treatment • Reconstruction • Neck dissection

## RIASSUNTO

*I tumori del labbro rappresentano le neoplasie orali più frequenti. Si tratta in prevalenza di carcinomi spinocellulari localizzati nella maggior parte dei casi al labbro rosso inferiore mentre sono più rari quelli basocellulari che si possono osservare a livello del labbro bianco superiore. Le metastasi cervicali si riscontrano in meno del 20% dei pazienti. Il trattamento chirurgico dei tumori del labbro deve pertanto considerare non solo il controllo della lesione primitiva con le conseguenti problematiche ricostruttive ma anche la possibile diffusione metastatica cervicale. I tumori in stadio iniziale non creano particolari problemi nella fase ricostruttiva rispetto a quelli avanzati ed estesi che richiedono una accurata ricostruzione per ripristinare al meglio forma, estetica e funzione. La ricostruzione di piccoli difetti dopo escissione a cuneo si ottiene per chiusura diretta con "restitutio ad integrum" mentre perdite di sostanza più grandi richiedono l'uso di lembi locali preferibilmente dal labbro residuo o da quello opposto oppure da tessuti limitrofi, specie quelli genieni. Quando la chirurgia comporta oltre all'exeresi completa del labbro, solitamente quello inferiore, anche l'asportazione di tessuti limitrofi come l'osso mandibolare, la cute del mento, la guancia o il pavimento orale anteriore, la ricostruzione richiede l'impiego di lembi loco-regionali peduncolati, cutanei o miocutanei, o di lembi liberi rivascularizzati. Uno dei problemi più importanti nella stadiazione dei tumori del labbro è correlato alla presenza di metastasi cervicali, occulte o clinicamente evidenti. Uno svuotamento sopra-omioideo (livelli I-III) con intenti elettivi e di stadiazione o con approccio curativo rappresenta, nella maggior parte dei casi, un trattamento adeguato e sufficiente per il controllo della diffusione metastatica cervicale. Gli Autori riportano la loro esperienza nel trattamento dei tumori del labbro considerando le problematiche ricostruttive, con la necessità di preservare ed alterare il meno possibile l'aspetto, la forma e la funzionalità labiale, insieme alla gestione delle non frequenti ma possibili metastasi cervicali.*

PAROLE CHIAVE: Labbro • Tumori maligni • Terapia chirurgica • Ricostruzione • Svuotamento collo

Acta Otorhinolaryngol Ital 2011;31:5-10

## Introduction

While the incidence of lip cancers is low (1-2%)<sup>1-4</sup>, they are extremely important from a clinical and surgical point of view because of the morphological and functional changes involved. Over 90% of these tumours consist of squamous cell carcinomas (SCCs) and, in lesser numbers, basal-cell tumours (BCCs); however, some adenocarcinomas deriving from the minor salivary glands can be ob-

served and, even more rarely, melanomas, sarcomas and lymphomas. BCCs generally occur in the upper lip and do not usually present lymph node metastases<sup>3,5</sup>. In contrast, SCCs develop most often in the lower lip, with a possibility of neck metastases. Lip carcinomas frequently appear on top of pre-cancerous lesions, such as radiodermatitis, chronic cheilitis and xeroderma pigmentosum. The diagnosis and treatment of these pre-cancerous lesions,

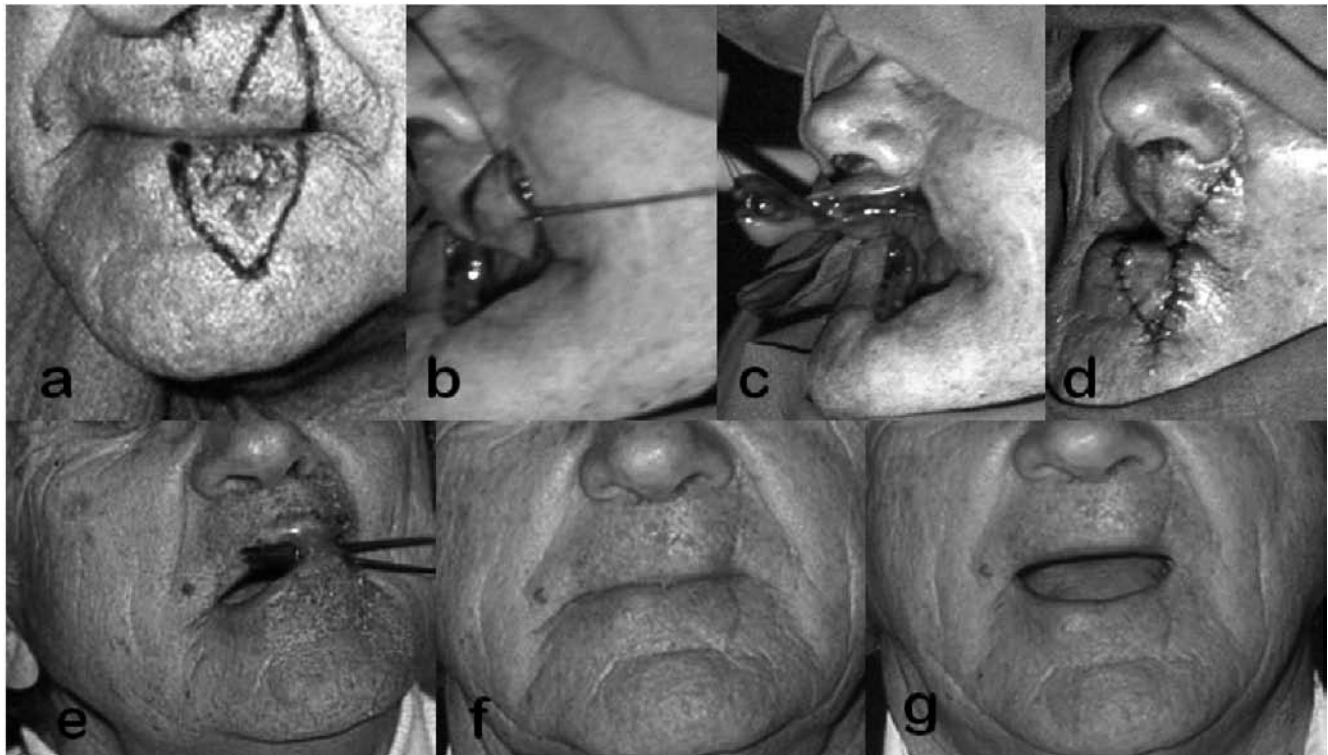
facilitated by a direct view of the lesions, is, therefore, crucially important in order to avoid their evolving into actual tumours. The subjects most at risk of this type of tumour are fair-skinned elderly people who work in the open air. Men are more at risk than women, probably because the latter use lipstick or lip-salve<sup>1-6-8</sup>. Other risk factors, related to the development of the tumours are pipe-smoking, tobacco-chewing and chronic alcohol consumption. Exposure to viral oncogenes has also been held responsible, especially in immune-depressed subjects<sup>9-10</sup>. The tumour, in its initial phase, usually appears as a papule or a plate which tends to progress into a vegetative or ulcerative form. In these cases, a biopsy is indispensable to confirm the diagnosis of carcinoma. Although in the case of T1 or T2 lesions, the percentage of patients with lymph node metastases, at the time of diagnosis is 8%, this figure increases considerably in advanced-stage tumours, making it necessary to search for possible cervical metastatic adenopathies<sup>2</sup>. The diagnostic routine is completed with ultrasonography (US), computed tomography (CT) scan and/or magnetic resonance (MR) to define the extent of the lesion and confirm any spreading to the main loco-regional lymph nodes.

Treatment by means of surgery or radiotherapy is planned, as appropriate, on the basis of the characteristics of the tumour. Surgery for lip cancer needs to be organized bearing in mind the site and extent of the incision, in order to allow the best possible reconstruction, avoiding scarring

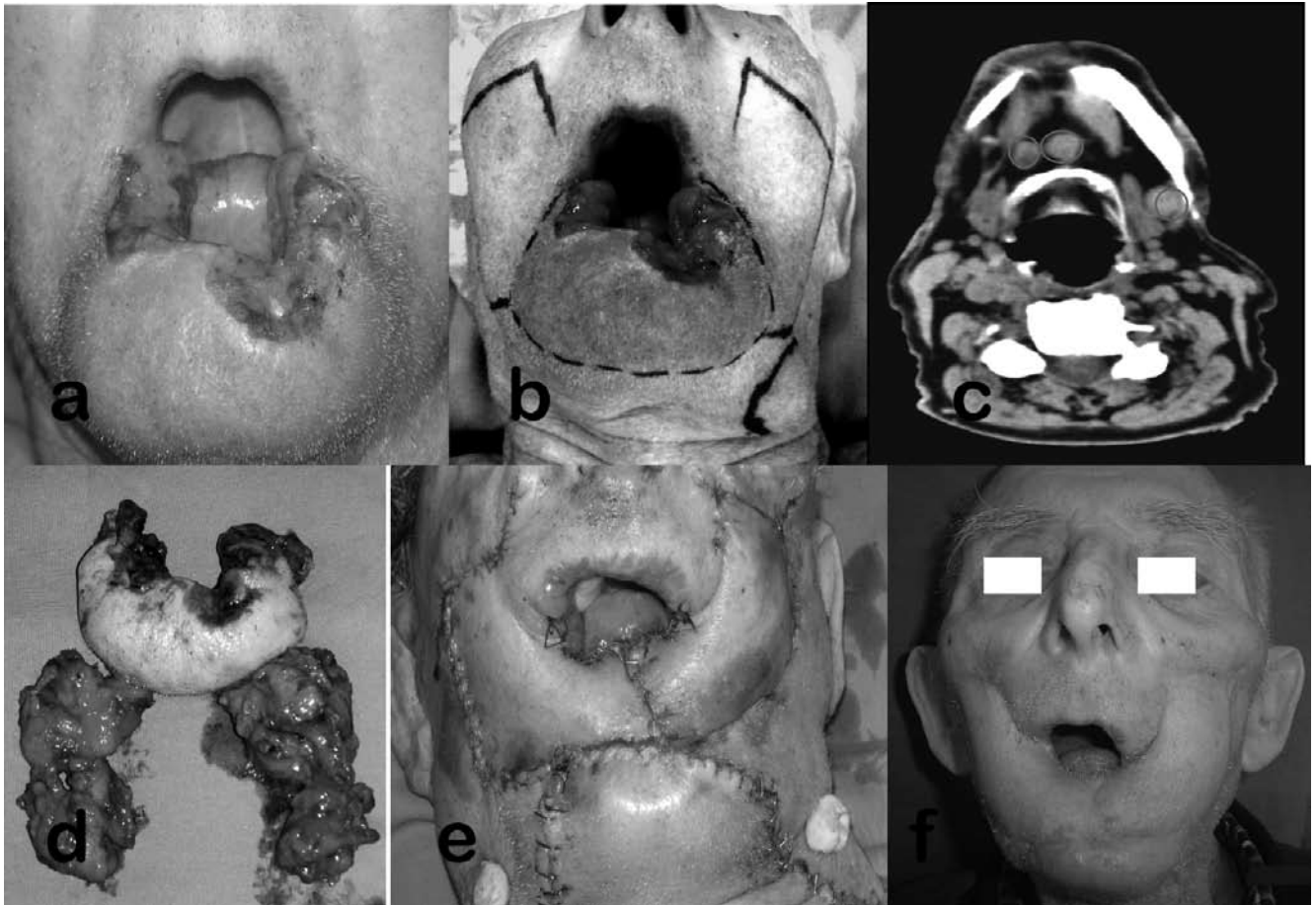
that could lead to undesired morphological and functional damage. Numerous techniques have been developed for lip reconstruction; the choice depends on the position of the lesion, its extension and the presence of any metastases to lymph nodes. Curative or elective supra-omohyoid neck dissection (SOHND) is advisable to control evident or occult neck metastases, especially in patients with deep and peri-neural infiltration, commissure involvement and undifferentiated and relapsing tumours<sup>3</sup>. Radiotherapy is indicated for early stage (brachytherapy) or advanced tumours, for palliative reasons, or for the treatment of cervical lymph nodes, either as an alternative to surgery or post-operatively. This report refers to personal experience concerning the observation and treatment of some patients presenting with malignant tumours of the lip.

### Patients and methods

Over the last five years, 32 patients (29 male, 3 female), aged 54-84 years (mean age 71), underwent reconstructive surgery for lip cancer. SCCs were the most common tumours (28 patients) with mostly well-differentiated forms, followed by BCCs (3 cases) and one sebaceous carcinoma. The lesions were all primary except in one patient with an advanced relapsing lesion of the lower lip extending to the mandibular bone. In 4 cases, they involved exclusively the upper lip (3 BCCs of the white lip and one SCC). In the other 28 patients, the tumour was located in the lower lip, in 20 cases, exclusively in the vermil-



**Fig. 1.** Male patient (57 years old) with squamous cell carcinoma of the lower lip. Surgical defect was repaired with Sabattini-Abbé flap: a) pre-operative view; b-d) intra-operative view; e) post-operative view after 3 weeks, before the resection of the vermillion bridge; f-g) post-operative view after 4 months.



**Fig. 2.** The oldest patient (84 years old) with an advanced carcinoma of the lower lip spreading to the soft tissues of the chin with lymph node metastases at first levels: a-b) pre-operative view; c) CT scan; d) surgical specimen; e) reconstruction of the defect with double modified “fan-flap”; f) post-operative view after 3 months.

lion (Fig. 1a), in 5 extending to the commissure (left in 3 patients and right in 2) and involving only the white lip in the last three. In the relapsing case (rT4aN0M0), which was treated repeatedly with surgery and radiotherapy, the tumour occupied the entire lower lip, extending to the vestibular and alveolar surface and spreading to the mandibular symphysis. Another elderly patient presented an advanced tumour of the lower lip spreading to the soft tissues of the chin (Fig. 2a). In 2 patients, the tumour was simultaneously associated with another lesion of the facial skin, of the same type; one tumour involved the skin of the right cheek adjacent to the nose (SCCs), the other, the soft tissues of the nasal dorsum (BCCs). At the time of diagnosis, no cases presented loco-regional metastatic adenopathies, except one patient with left commissure involvement and the patient with the tumour extending to the chin and with bilateral neck metastases at levels I and IIa. The TNM classification (UICC-2007) was as follows: 13T1N0M0, 12T2N0M0, 4T3N0M0, 1T3N1M0, 1T4aN2cM0, 1rT4aN0M0 (Table I). During the excision phase, surgery was adapted, in every case, in relation to the site, size and stage of the tumours; 13 removals were

performed with a wedge or “W” shaped excision followed by direct closure, while 18 were carried out, as required, according to tumour extent, followed by repair performed primarily with the use of loco-regional flaps (Table II). Only in the patient with recurrent tumour (rT4aN0Mx) was the reconstruction achieved by distant flaps. In the 18 patients, the local flaps used to restore the continuity of the lip were as follows: 4 Sabattini-Abbé flaps (Fig. 1b-c), 6 naso-labial flaps performed in patients with white upper and lower lip involvement, 5 Estlander flaps in cancer of the commissure, one upper lip reconstruction using Burow’s procedure, one unilateral modified fan-flap

**Table I.** TNM classification of the patients (UICC-2007).

Stage	Patients
Stage I T1N0M0	13
Stage II T2N0M0	12
Stage III T3N0M0	4
T3N1M0	1
Stage IV T4aN2cM0	1
rT4aN0M0	1



**Table II.** Surgical treatment of the tumour: reconstructive phase.

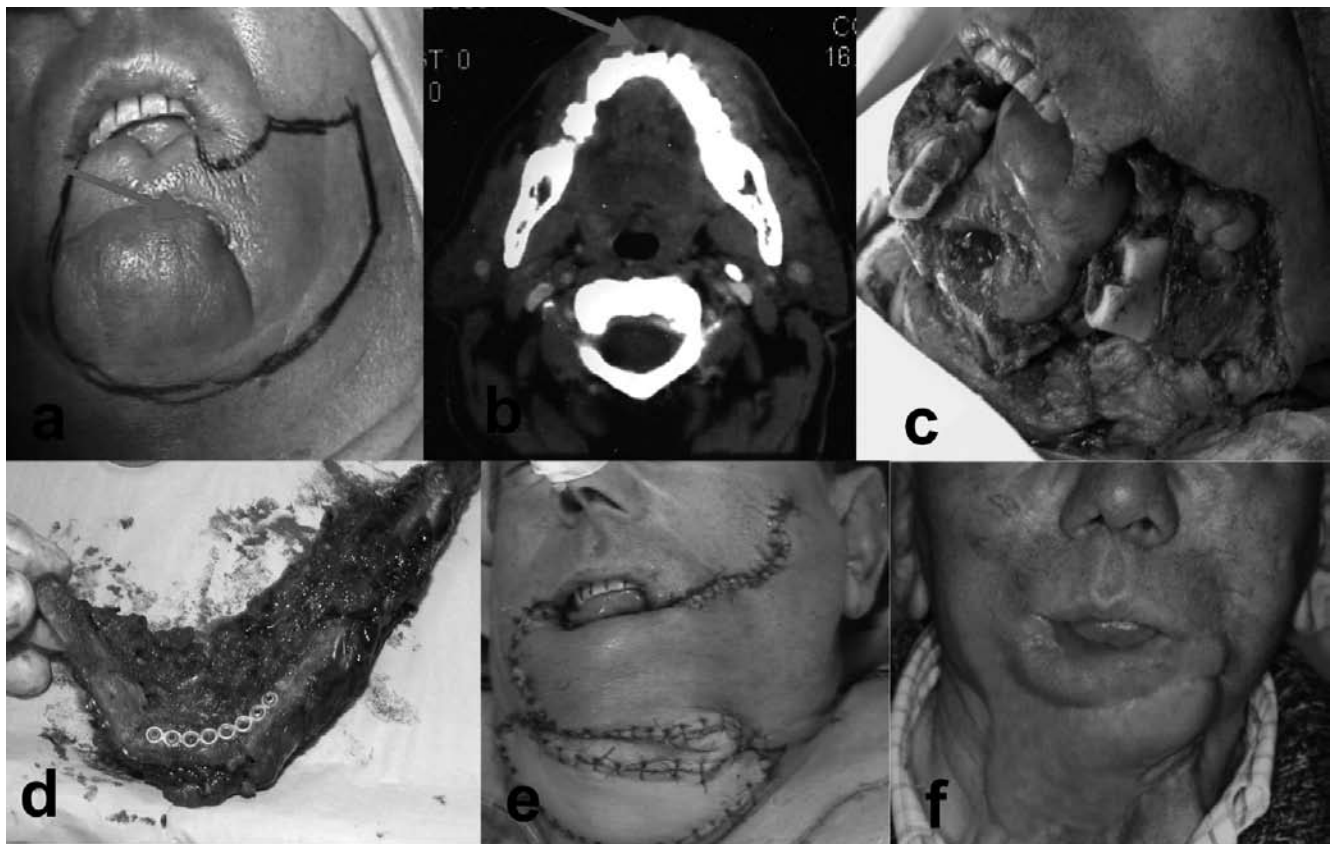
Surgical techniques (reconstructive phase)	Patients
Sabattini - Abbé	4
Nasolabial flaps	6
Estlander flaps	5
Burow's procedure	1
Modified fan - flap	1
Double modified fan - flap	1
Fibula osteocutaneous free flap + <i>latissimus dorsi</i> and cutaneous cervical flaps	1
Wedge or "W" shaped excision + direct closure	13

and one double modified fan-flap with bilateral neck dissection in the case with spread to the chin and evident metastases (T4aN2cM0) (Fig. 2a-d). The patient with the rT4a tumour underwent extensively devastating surgery and then reconstruction with the simultaneous combined use of a free re-vascularized flap and two pedicled flaps; this consisted of removal of the mandibular symphysis in one piece with the outer soft tissues of the chin and left cheek, with reconstruction using a fibula osteo-cutaneous free flap to restore the continuity of the jaw and anterior

oral floor in combination with a myo-cutaneous pedicled *latissimus dorsi* flap and cutaneous cervical transposition flap, to cover the bone and reshape the soft tissues (Fig. 3). Neck dissection was performed only in 8 patients: SOHND in 7 cases, with an elective and staging intent in 6 (unilateral in 5 patients with commissure involvement and bilateral in rT4aN0M0 lesion) and as a curative approach in one (T3N1M0). Therapeutic bilateral Modified Radical Neck Dissection type III (MRND) was performed in the T4aN2cM0 patient (Fig. 2c, d).

**Results**

The patients with early stage tumours recovered within 3 weeks after surgery, with good short- and long-term aesthetic and functional results. In contrast, the patients with more advanced tumours of the lower lip (T3 and T4 lesions) presented complications related to post-operative "incontinence" and "incompetence", including drooling, vocalization and chewing disorders (Fig. 2f). These functional problems decreased considerably over the months after the operation following several courses of rehabilitation therapy. The greatest difficulties obviously occurred in the case of complete removal of the lip (T4aN2cM0)



**Fig. 3.** Patient with relapsing carcinoma treated repeatedly with surgery and radiotherapy. The tumour occupied the entire lower lip, extending to the vestibular and alveolar surface and spreading to the mandibular symphysis: a) pre-operative view; b) CT scan; c) intra-operative view after the tumour resection; d) modelling of the fibula free flap to restore the continuity of the jaw; e) patient at the end of the operation with myocutaneous pedicled *latissimus dorsi* flap to cover the fibula bone and reshape soft tissues; f) post-operative view after a series of reconstructive and re-shaping plastic surgery interventions.

(Fig. 2) also with mandibular symphysis in the rT4aNOM0 patient (Fig. 3) because, although reconstruction with bilateral modified fan-flap, in one case, and with revascularized and two pedicled flaps, in the other, provided effective repair, there was a lack of mobility, flexibility and holding ability. The latter patient underwent a series of reconstructive and re-shaping plastic surgery interventions (Fig. 3f) to improve the new lower lip aesthetically and functionally. At follow-up after at least one year, no cases presented local recurrence of the tumour. Some of the more elderly patients died from other causes.

## Discussion

Approximately 25% of all oral tumours are carcinomas of the lip, although some reports claim a tendency of this percentage to decrease<sup>1-4,8</sup>. Lip carcinomas are most frequent in subjects aged 60-70 years, especially among white caucasians. Coloured people are probably protected against UV rays by their natural skin pigment<sup>7</sup>. As is well-known, carcinomas of the lower lip most frequently occur in male smokers working in the open air, such as sailors, fishermen and farmers. Several reports emphasize the aetiopathogenetic role of some viral factors, i.e., HPV16 and HPV24, HSV1 and HSV2. In particular, the association of HSV2, exposure to UV rays and chemical factors can considerably increase the risk of these tumours<sup>8</sup>. The lower lip is affected in a percentage of cases varying from 90-95%<sup>2,5,12-17</sup> and SCCs, mostly well-differentiated, are by far the most frequent in these patients, with a percentage ranging from 94 to 98%<sup>3,17,18</sup>. The more rare BCCs, by contrast, are almost always located on the skin of the upper lip. Lymph node metastasis of the neck is a problem that is encountered in less than 20% of patients with lip cancer. Metastases appear to be less frequent in well-differentiated, than in undifferentiated carcinomas (5% compared to 20%)<sup>8</sup>. Surgical removal of the tumours, at a not very advanced stage, does not create particular problems during the reconstruction. The reconstruction of the lip, to correct the more important defects, requires the utmost care in order to preserve as much as possible, its natural form and functions. In fact, it should be remembered that the lips are an extremely important part of the face, not only from an aesthetic point of view but also regarding some major functions; they play a basic role in feeding, speaking and facial expression. For these reasons, when reconstructing the lip, all three layers: skin, muscle and mucosa, must be taken into consideration. The commissure is crucially important to avoid the leaking of saliva and for correct ingestion of food; it is thus essential to rebuild the structure in the areas of more severe damage. Regarding the minor flaws, it may be sufficient to achieve a direct closure after making a wedge-shaped excision. Another simple technique is the forward sliding of the internal portion of the mucosa in the case of superficial le-

sions. In the area with the greatest defect the challenge of reconstruction is using flaps to restore a complete lip structure, especially local and regional flaps that provide an excellent match in terms of texture, colour and thickness. Reconstruction can be difficult and complex also when the lip is involved due to nearby lesions, recurs or when the tumour presents in association with similar lesions of the facial skin, simultaneously or following neoplasms that have been already treated. To compensate for the loss of tissue due to surgery involving the entire thickness of the lip, flaps need to be created from the remaining, or opposite, lip or adjacent areas, particularly the cheek. In an ideal surgical treatment, it is essential to consider reconstruction of the sphincter ring using all three layers at the same time as the excision. Reconstruction should provide an adequate oral opening and sufficient mucosa adjacent to the commissure to avoid contracture<sup>11,20</sup>. Numerous reconstructive techniques have been devised by various Authors, over the years, to deal with major defects, but among the methods most employed, at present, it would appear to be the so-called "cross-flap" developed by Abbé and Estlander<sup>11,14</sup>, using the opposite lip with the various modifications suggested<sup>8,19</sup>, and the method by Karapandzic<sup>10</sup>, which provides the great advantage of preserving the nerves and blood-vessels of the flap itself, allowing a good sphincteric function to be maintained<sup>16,18</sup>. Bernard-Burow's method and the various versions of the so-called fan-flap procedure are also particularly useful in cases with greater or complete lip loss<sup>13</sup>. When surgery of the lip, usually the lower one, involves removal of the whole organ together with the jaw-bone and nearby soft tissues (chin, cheeks, anterior floor of the mouth), reconstruction necessarily includes the creation of free vascularized flaps (the only kind allowing successful transfer of bone tissue), possibly associated with flaps from neighbouring tissues (cutaneous or myocutaneous). Unfortunately, such drastic intervention and complex reconstruction, although providing good results regarding the tumour, are extremely problematic from an aesthetic and functional point of view, presenting, in particular, lip incontinence, continuous drooling and difficulty in chewing and swallowing. Regarding follow-up, results are, on the whole, satisfactory, probably because early diagnosis is possible since these tumours develop in clearly visible areas, allowing accurate histological identification (biopsy) and prompt treatment. The prognosis of a 5-year survival is worse for tumours of the upper lip and commissure than for those of the lower lip<sup>16</sup>. One of the most important problems, in lip cancer surgery, is the management of evident or occult neck metastases. SOHND is an adequate elective method in patients without evident neck metastases with staging purpose, especially in patients with large and deep tumours, in cases with commissure involvement and perineural infiltration, or in relapsing lesions. Also in a therapeutic approach, neck dissection of the first three levels is

sufficient and curative because a nearby total absence of metastases, at IV and V levels, is observed in non-treated patients and in comprehensive neck dissection<sup>2</sup>. The probability of survival up to 5 years is lower in cases with involvement of the lymph nodes; the rate is 50% for N+ and 25% in the presence of capsular breakage or bone infiltration<sup>3</sup>, which require radical neck dissection.

## Conclusions

In conclusion, it should be clearly emphasized that good prognostic, aesthetic and functional results are obtained in lip cancer, especially for the early-stage lesions, and that,

in the choice of the most appropriate surgical approach to adopt, the ideal option should always be aimed at maintaining, or altering as little as possible, the functionality and appearance of the lip using, when possible, the remaining or opposite lip. But the most important problems, in lip cancer surgery, have to be faced when repairing greater loss of tissues. In these cases, there are reconstructive problems, with unsatisfactory aesthetic and functional outcomes. For the neck, we hope, in the near future, to be able to adopt a super-selective neck dissection aided, also in this field, by methods of precise and early metastases identification, such as sentinel lymph node, PET/CT scan or characterization of prognostic markers and predictive factors.

## References

- 1 Baker SR. *Current management of cancer of the lip*. *Oncology* 1990;4:107-20.
- 2 Vartanian JG, Carvalho AL, Araujo Filho, et al. *Predictive factors and distribution of lymph node metastasis in lip cancer patients and their implications on the treatment of the neck*. *Oral Oncology* 2004;40:223-7.
- 3 Zitsch RP, Lee BW, Smith RB. *Cervical lymph node metastases and squamous cell carcinoma of the lip*. *Head Neck* 1999;21:447-53.
- 4 Moore SR, Johnson NW, Pierce AM, et al. *The epidemiology of lip cancer: a review of global incidence and aetiology*. *Oral Dis* 1999;5:185-95.
- 5 Khuder SA. *Etiologic clues to lip cancer from epidemiologic studies on farmers*. *Scand J Work Environ Health* 1999;25:125-30.
- 6 Stucker FJ, Lian S. *Management of cancer of the lip*. *Operative Techniques in Otolaryngology - Head Neck* 2004;15:226-33.
- 7 Papadopoulos O, Konofaos P, Tsantoulas Z, et al. *Lip defects due to tumor excision: Apropos of 899 cases*. *Oral Oncology* 2007;43:204-12.
- 8 Zitsch RP. *Carcinoma of the lip*. *Otolaryngol Clin North Am* 1993;26:265-77.
- 9 Galyon SW, Frodel JL. *Lip and perioral defects*. *Otolaryngol Clin North Am* 2001;34:647-66.
- 10 Karapandzic M. *Reconstruction of lip defects by local arterial flaps*. *Br J Plast Surg* 1974;27:93-7.
- 11 Abbé RA. *A new plastic operation for the relief of deformity due to double hairlip*. *Med Rec* 1889;53:447.
- 12 Sabattini P. *Cenno storico dell'origine e progressi della rino-plastica e cheiloplastica*. Bologna: Tipografia delle Belle Arti; 1838.
- 13 Bernard C. *Cancer de la levre inferieure operé par un procedé nouveau*. *Bull Soc Chir* 1853;3:357-63.
- 14 Estlander JA. *Eine Methods ans der einen Lippe substanzverluste der anderen zu ersetzen*. *Arch Klin Chir* 1872;14: 622.
- 15 Baker SR, Krause CJ. *Carcinoma of the lip*. *Laryngoscope* 1980;90:19-27.
- 16 Zitsch RP, Park CW, Renner GJ, et al. *Outcome analysis for lip carcinoma*. *Otolaryngol Head Neck Surg* 1995;113:589-96.
- 17 De Visscher JGAM, van den Elsaker K, Grond AJK, et al. *Surgical treatment of squamous cell carcinoma of the lower lip: evaluation of long-term results and prognostic factors – A retrospective analysis of 184 patients*. *J Oral Maxillofac Surg* 1998;56:814-20.
- 18 Gooris PJJ, Vermey A, de Visscher JGAM, et al. *Supraomohyoid neck dissection in the management of cervical lymph node metastases of squamous cell carcinoma of the lower lip*. *Head Neck* 2002;24:678-83.
- 19 Bucur A, Stefanescu L. *Management of patients with squamous cell carcinoma of the lower lip and N<sub>0</sub>-neck*. *J Craniomaxillofac Surg* 2004;32:16-21.
- 20 Vukadinovic M, Jezdic Z, Petrovic M, et al. *Surgical management of squamous cell carcinoma of the lip: analysis of a 10-year experience in 223 patients*. *J Oral Maxillofac Surg* 2007;65:675-9.

Received: November 16, 2009 - Accepted: January 15, 2011

Address for correspondence: Dr. A. Moretti, Clinica ORL, Università "G. D'Annunzio" Chieti - Pescara, Ospedale "SS Annunziata", via dei Vestini, 66013 Chieti Scalo (CH), Italy. Fax: +39 0871 552033. E-mail: amoretti@orl.unich.it