

Received: 2017.12.13  
Accepted: 2018.02.02  
Published: 2018.03.03

# Management of Severe Lower Cervical Facet Dislocation without Vertebral Body Fracture Using Skull Traction and an Anterior Approach

Authors' Contribution:  
Study Design A  
Data Collection B  
Statistical Analysis C  
Data Interpretation D  
Manuscript Preparation E  
Literature Search F  
Funds Collection G

AG **De-Chao Miao**  
BC **Can Qi**  
CF **Feng Wang**  
CF **Kuan Lu**  
AG **Yong Shen**

Department of Spine Surgery, The Third Hospital of Hebei Medical University, Shijiazhuang, Hebei, P.R. China

**Corresponding Author:** Yong Shen, e-mail: 18630159778@163.com  
**Source of support:** Departmental sources

**Background:** Cervical facet dislocation is the anterior displacement of one cervical vertebral body on another. The aim of this study was to evaluate the clinical efficacy of skull traction through an anterior cervical approach in the treatment of severe lower cervical facet dislocation without vertebral body fracture.

**Material/Methods:** Forty subjects with severe lower cervical facet dislocation, without vertebral body fracture, were treated between February 2010 and December 2013. Road traffic accident was the primary cause of injury. Patients presented with dislocated segments in C3–C4 (n=4), C4–C5 (n=4), C5–C6 (n=12), and C6–C7 (n=20). Twenty-six patients had unilateral facet dislocation, and 14 patients had bilateral facet dislocation. Spinal injuries were graded according to the American Spinal Injury Association (ASIA) impairment scale and included grade A (eight cases), grade B (six cases), grade C (six cases), grade D (12 cases), and grade E (eight cases). The mean follow-up time was 4.2 years.

**Results:** All procedures were completed successfully, with no major complications. Postoperative X-rays showed satisfactory height for the cervical intervertebral space and recovery of the vertebral sequence. Bone fusion was completed within four to six months after surgery. Surgery significantly improved neurological function in all patients.

**Conclusions:** Skull traction and an anterior approach can be used to successfully treat severe lower cervical facet dislocation, obtaining complete decompression, good reduction, and maintenance of intervertebral height with retention of the physiological curvature of the cervical spine.

**MeSH Keywords:** **Dislocations • Fracture Fixation • Spinal Cord Injuries • Spinal Fractures**

**Abbreviations:** **ASIA** – American Spinal Injury Association; **RTA** – road traffic accidents; **JOA** – Japanese Orthopaedic Association; **CCI** – cervical curvature index; **SCEP** – spinal cord evoked potentials

**Full-text PDF:** <https://www.medscimonit.com/abstract/index/idArt/908515>

 2588

 4

 2

 29



## Background

Cervical facet dislocation is the anterior displacement of one cervical vertebral body on another; two facet joints are located posterior to each cervical vertebral level. The lower cervical vertebral injury is the most common type injury to the cervical spine, with lower cervical facet dislocation accounting for between 6-15% of lower cervical vertebral injuries [1]. This type of injury mainly involves excessive flexion-distraction (seat-belt injury) or flexion-rotation, causing one or both of the inferior facets of the superior vertebra to shift anteriorly to the superior facet of the vertebra below.

Severe lower cervical facet dislocations are usually accompanied by a disruption to the anterior or posterior elements, such as the longitudinal ligaments, ligamentum flavum, apophyseal joint ligaments, the annulus fibrosus, and the interspinous ligaments [2]. Complete or incomplete spinal cord and nerve root injuries are also common. To optimize the chance of neurological recovery, the current consensus for patient management is that patients should be treated with decompression, reduction, and stabilization. However, current treatment for severe lower cervical facet dislocations has not been standardized, and there remain several unanswered questions with regard to treatment, including whether all patients should be treated with closed reduction, whether a combined anterior and posterior approach is more effective than an anterior-only approach, or whether early reduction is beneficial to the recovery of neurological function.

Because of these remaining unresolved questions, the aim of this study was to evaluate the clinical efficacy of skull traction through an anterior cervical approach in the treatment of severe lower cervical facet dislocation without vertebral body fracture, to begin to provide evidence to support future treatment recommendations.

## Material and Methods

### Compliance with ethical standards

This study was approved by the Institutional Review Board of the Third Hospital of Hebei Medical University, China. Informed consent was obtained from all patients who participated in the study. All experimental protocols in this research were approved by The Third Hospital of Hebei Medical University Ethics Committee. The methods and surgical procedures were carried out in accordance with the relevant surgical procedural guidelines.

### Patients

A cohort of 40 patients was enrolled in the study (24 men, 16 women) from February 2010 to December 2013. All patients

were diagnosed with severe lower cervical facet dislocation without vertebral body fracture. Previously, four patients were excluded from the study who underwent posterior fixation only, two patients had another type of injury, and two patients were lost to follow-up. The patient ages ranged from 21–73 years, with a mean age of 41.3 years. The etiology of trauma included road traffic accidents (24 patients), falls from a height (12 patients), and other causes (four patients). From injury to surgery, the average length of time was 79.2 hours (range, 2–7 days). Eight patients presented with intact neurological function, eight patients had complete spinal cord injury, four patients presented with nerve root syndromes, and 20 patients with incomplete spinal cord injury.

The classification and grading system of the American Spinal Injury Association (ASIA) impairment scale was used, with complete injury (grade A) to normal (grade E). In this study, eight cases were grade A, six cases were grade B, six cases were grade C, 12 cases were grade D, and eight cases were grade E. All patients were imaged using cervical X-rays, computed tomography (CT) scanning with coronal and sagittal reconstruction, and magnetic resonance imaging (MRI) of the cervical spine. Plain radiography and CT showed facet dislocations at C3–C4 (four patients), C4–C5 (four patients), C5–C6 (12 patients), and C6–C7 (20 patients). Twenty-six cases presented with unilateral facet dislocation and 14 cases with bilateral facet dislocation (Table 1).

### Surgical technique

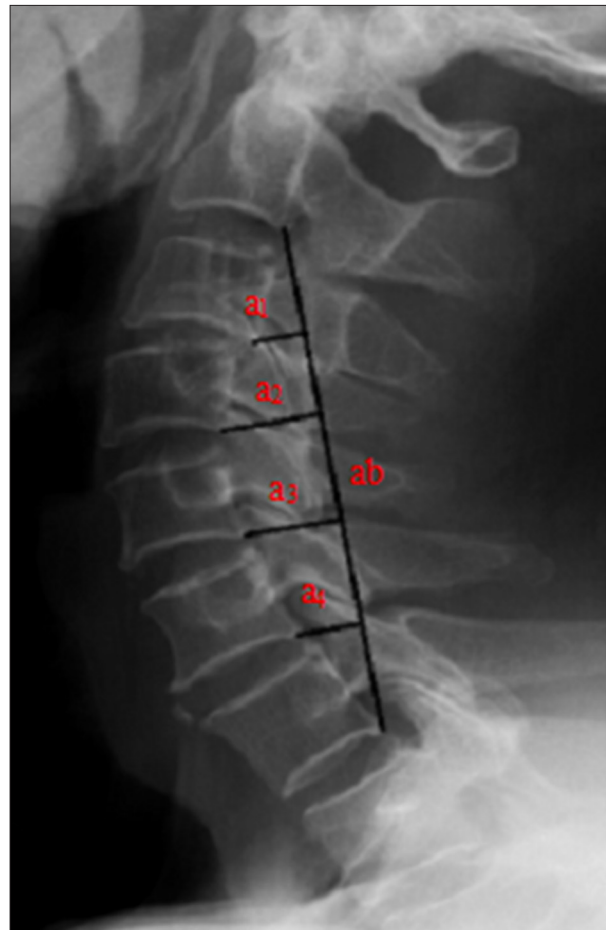
Before surgery, patients were in the supine position with a neck collar. Following general anesthesia, the neck collar was removed, and patients were moved into a position of mild cervical flexion. Skull traction was performed using 5 kg weights, with the weight increased at a rate of 1 kg every ten minutes. Measurement of spinal cord evoked potentials (SCEPs) after spinal cord stimulation was used to monitor the neurological function of each patient during surgical reduction. Intraoperative X-ray fluoroscopy was used to observe the reduction process. The unilateral facet dislocation was unlocked by slight stretching of the head of the patient, allowing the inferior articular process of the dislocated vertebra to cross the superior process of the lower vertebra. Slight rotation of the neck toward the dislocated side allowed the bilateral facet dislocation to be reset. The traction weight was then gradually reduced to 5 kg after reduction. Traction was stopped in cases where the traction weight exceeded 15 kg, the dislocation was unable to be reset, or neurological deterioration was observed through SCEP monitoring. Decompression and fixation through an anterior approach were performed after closed traction.

Plates with screw fixation were used and inter-body cages were used for fusion. For patients who failed closed reduction,

**Table 1.** Demographic and clinical data of patients included in the study.

Variable	Number/range	Mean
Total cases	40	
Sex		
Male	24 (60%)	
Female	16 (40%)	
Age (year)	21–73	41.3
Cause of injury		
Traffic accidents	24 (60%)	
High falls	12 (30%)	
Others	4 (32.7%)	
Duration from injury to surgery (day)	2–7	3.3
Spinal cord function		
Complete spinal cord injury	8 (20%)	
Incomplete spinal cord injury	20 (50%)	
Intact neurological function	8 (20%)	
Nerve root syndromes	4 (10%)	
Injured segment		
C3–4	4 (10%)	
C4–5	4 (10%)	
C5–6	12 (30%)	
C6–7	20 (50%)	
Type of fracture dislocation		
Unilateral facet locking	26 (65%)	
Bilateral facet locking	14 (35%)	
Traction weight(kg)	7–15	11.35
Time of reduction(min)	20–100	63.5
Follow-up (years)	3–6	4.2

a Caspar cervical distractor was used to distract the intervertebral space after discectomy, followed by the use of a thin distractor for insertion to achieve reduction. In patients with unilateral facet dislocation, the Caspar distractor was then used to expand the intervertebral space to twice that of its normal height. A suitable blunted instrument (such as a curette or a laminar spreader) was then placed on the locking side of the posterior third of the endplate of the lower vertebrae to act as a lever after discectomy. The bilateral facet dislocation could be reset by pushing on the blunted instrument



**Figure 1.** Calculation of the cervical curvature index (CCI). “ab” is the line connecting the inferior posterior edge of the C2 and C7 vertebral body. “a1” to “a4,” respectively represent the vertical distance from the inferior posterior edge of the C3–C6 to “ab”. Cervical curvature index (CCI)=[(a1+a2+a3+a4)/ab]×x100%.

in a caudal direction, while simultaneously exerting pressure on the anterolisthetic (spondylolisthetic) upper vertebra in a dorsal direction. A neck collar was used for 1.5–2 months post-operatively. All patients were graded before and after surgery according to the Japanese Orthopaedic Association (JOA) score and the Cervical Curvature Index (CCI) (Figure 1) to evaluate the stability of the cervical spine.

### Statistical analysis

SPSS version 22.0 statistical software (IBM, Armonk, NY, USA) was used for statistical analysis. Data were recorded as the mean ± standard deviation (SD), and was compared by using a t-test. The Wilcoxon rank test was applied to analyze ASIA grades that were recorded preoperatively and at the last follow-up visit. A P-value <0.05 was considered to be statistically significant.

**Table 2.** Pre-operative and postoperative American Spinal Injury Association (ASIA) grade.

ASIA grade	Pre-op cases	The final follow up ASIA grade				
		A	B	C	D	E
A	8	2	6			
B	6			3	3	
C	6			1	5	
D	12				4	8
E	8					8

**Table 3.** Pre-operative and postoperative Japanese Orthopaedic Association (JOA) score, cervical curvature index (CCI), and American Spinal Injury Association (ASIA) grade.

	Preoperative	Final follow-up	Statistic value	p-Value	Improvement rate of JOA score (%)
JOA score	10.30±5.19	13.55±4.47	-3.536	<0.001	50.54±40.07
CCI	18.90±0.91	10.60±0.43	-3.921	0.000	
ASIA grade			-3.448	<0.01	

## Results

The aim of this study was to evaluate the clinical efficacy of skull traction through an anterior cervical approach in the treatment of severe lower cervical facet dislocation without vertebral body fracture in 40 patients. The findings were that no severe complications were noted for any of the patients who were treated in this study. The skull traction weight ranged from 7–15 kg, with a mean of 11.35 kg. Thirty-eight patients underwent complete cervical facet reduction; two patients did not achieve a complete reduction.

In this study, reduction was achieved after between 20–100 minutes of traction (mean, 63.5 minutes). The mean duration of the surgical procedure was 95.83±13.57 minutes, and the mean amount of blood loss was 139.00±34.01 ml. All patients were followed-up for between 3–6 years (mean, 4.2 years). Bone fusion was completed within 4–6 months after surgery. None of the patients showed plate fracture, screw loosening, cage prolapse, or pseudarthrosis at follow-up. X-ray examination showed satisfactory recovery of the cervical intervertebral height space and vertebral sequence restoration of the normal cervical spine sequence and intervertebral height.

The results of this clinical surgical study showed that neurological function was also significantly improved at the final follow-up when compared with preoperative values, by analysis of the American Spinal Injury Association (ASIA) grades that were recorded preoperatively and postoperatively (Tables 2, 3). The degree of functional paralysis for patients with complete

spinal cord injury did not increase after surgery. Neurological function in patients with incomplete spinal cord injury was restored to varying degrees, but symptoms of nerve root irritation disappeared. The postoperative Japanese Orthopaedic Association (JOA) scores showed significant improvement when compared with preoperative scores (Table 3). Statistical analysis for improvement for patients showed that the surgical effect was independent of age, gender, type of spinal cord injury, and type of facet dislocation (Table 4). Figure 2 shows the imaging data of a typical case from this study.

## Discussion

Lower cervical facet dislocation is the anterior displacement of one cervical vertebral body on another, and cervical facet injuries can have a significant impact on neurological function and can be life-threatening [3]. Facet dislocation injuries can lead to cervical spine abnormalities and instability and are always accompanied by vertebral disc injury or herniation. Cervical facet dislocation most commonly involves the C5–C6 and C6–C7 levels, and often includes excessive flexion-distraction or flexion-rotation, causing one or both of the inferior facets of the superior vertebra to be displaced anteriorly toward the superior facet of the vertebra below [4]. Previously published studies have indicated that the potential for translation and dislocation arises because of a smaller diameter and lower height of the superior articular process combined with a more horizontally oriented inferior articular process [5].

**Table 4.** Statistics analysis of relevant factors in the improvement rate of the Japanese Orthopaedic Association (JOA) grade.

	n	Improvement rate of JOA score (%)	Statistic value	p-Value
Age (years)				
<40	11	50.01±40.78	-0.502	0.616
>40	9	40.07±40.31		
Sex (Male/Female)				
Male	12	52.72±46.57	-0.118	0.906
Female	8	47.27±30.50		
Type of spinal cord injury				
Complete	4	16.76±4.24	-1.539	0.124
Incomplete	16	58.98±40.62		
Type of facet dislocation				
Unilateral	13	54.81±44.41	-0.484	0.628
Bilateral	7	42.59±32.04		

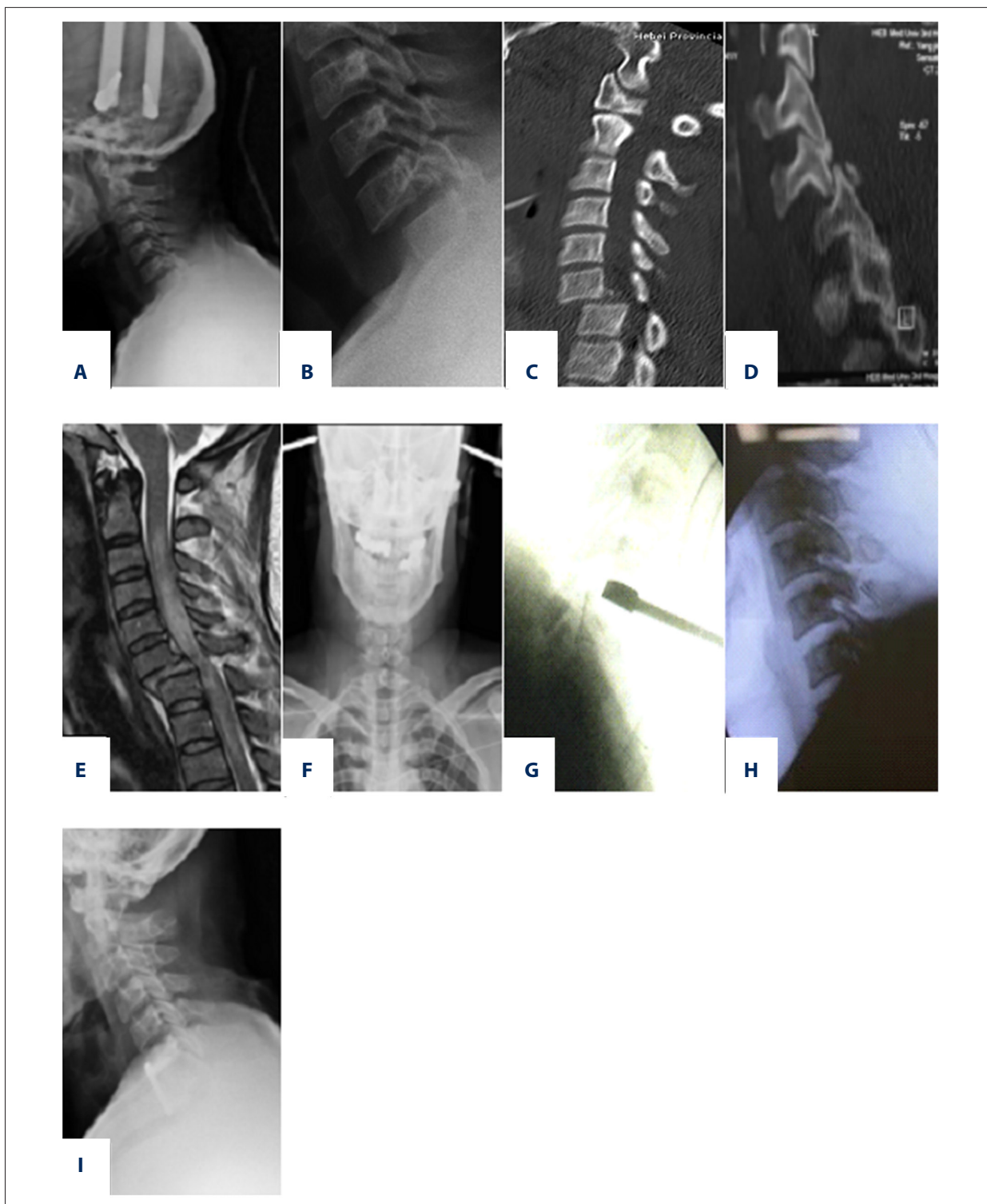
Severe lower cervical facet dislocation is always accompanied by complex vertebral ligament injury and herniation or rupture of the intervertebral disc. The goal of treatment is to restore the normal architecture of the cervical spine, recover the anatomical and functional integrity of the spinal cord and nerve root, completely decompress and restore the intervertebral height and physiological curvature, and avoid delayed or secondary neurological injury for the immediate and long-term stability of the cervical spine [6–9].

The closed reduction of the cervical facets has been previously described and is now a recognized procedure [10]. However, the safety of closed reduction has been the focus of debate for some time, as some surgeons have suggested that closed reduction can cause secondary neurological injury if the ruptured disc is displaced into the spinal canal [11–13]. However, in 2007, Yu and colleagues reported a success rate of 88% for patients treated with unilateral facet dislocation and 15.4% for bilateral facet dislocation with skull traction [14]. In 2009, Lee and colleagues reported that transient injury to the cervical spinal cord occurred in between 2–4% of people, while the incidence of permanent neurological injury was 1% [15].

In terms of skull traction, although all of the cervical intervertebral joints are under tension, deformation occurs mainly to the dislocated facet. The total drafting distance of the cervical spine should be the sum of the joint height above the dislocation plane and the slight extension deformation between the vertebrae. While the extensibility of the spinal cord is between 10–12%, and it can be displaced axially to lateral for

several millimeters, the total drafting distance of the cervical spine should always be within the physiological deformation range of the spine, to avoid excessive tension to the cervical spinal cord and secondary neurological injury [16–18]. The findings of this study showed that, when all patients who were subjected to skull traction were supervised with spinal cord evoked potential (SCEP) monitoring, which ensured the safety of the closed traction procedure. Therefore, despite the risks associated with closed traction, the method described in this study was shown to be safe as long as the described surgical procedures are followed

The open reduction can be achieved through an anterior approach alone, a posterior approach alone, or a combined anterior and posterior approach as the surgical approach is not standardized [19]. The increased use of an anterior approach has meant that this indication is no longer limited to injuries of anterior structures, with posterior injuries, such as facet dislocations, which are also treatable. Anterior surgery can restore the stability of the cervical spine, relieve compression, and retain or restore neurological function, where possible. In support of the findings of the present study, the clinical efficacy of the anterior surgical approach has been confirmed by previous studies [20–22]. Compared with other surgical methods, surgery through an anterior approach is simple, requires fewer changes in position, can decompress the region directly and completely to restore physiological curvature of the spine, and is associated with fewer fusion segments and a lower incidence of postoperative neck pain, all of which improve the recovery of the patient [9,22–24].



**Figure 2.** Case 14. Imaging findings, including lateral radiographs, sagittal computed tomography (CT), and sagittal magnetic resonance imaging (MRI) of the facets of the lower cervical vertebrae. **(A, B)** Lateral view of radiographs demonstrate bilateral facet dislocation of C6–C7. **(C, D)** Sagittal computed tomography (CT) images show bilateral facet dislocation. **(E)** Sagittal magnetic resonance imaging (MRI) shows thecal sac compression. **(F)** Skull traction was performed after general anesthesia. **(G, H)** The inferior vertebra was probed to unlock the facet dislocation (reduction by leverage). **(I)** Lateral X-ray view of the cervical spine performed postoperatively.

The adequate and appropriate reduction is the key to surgery for cervical facet dislocation, and anterior open reduction can be performed using several stages. In patients with unilateral facet dislocation, the distraction nail should be placed on the inner edge of the longus colli of the dislocated side. After discectomy, the Caspar distractor is recommended for use to expand the intervertebral space to twice that of its normal height. A suitable blunted instrument (such as a curette or a laminar spreader) should then be placed on the locking side of the posterior third of the endplate of the lower vertebrae to act as a lever. The present study has shown that bilateral facet dislocation can be reset by pushing on the blunted instrument in a caudal direction while simultaneously exerting pressure on the anterolisthetic upper vertebra in a dorsal direction, an approach that has been previously reported [25]. In the present study, through the combination of preoperative skull traction and anterior open reduction, successful reduction was achieved in all patients.

The timing of the surgery is another controversial aspect of the surgical treatment of cervical facet dislocation. In 1999, Mirza and colleagues advocated that surgical intervention should occur in the early phase in patients following acute cervical spinal cord injury, and showed that decompression and stabilization within 72 hours following injury, not only promoted the recovery of early neurological function, but also reduced further complications attributed to the delay in such neurological recovery [26]. In contrast, in 1997, Vaccaro and colleagues showed that a delay in surgery allowed for better preoperative preparation, and that decompression was safer after the edema subsided [27]. However, most studies now accept, that surgery should be performed within 72 hours after injury, or earlier, if the patient's condition allows, for the best chance of recovering neurological function. From the findings of the present study, we recommend that surgery for cervical facet dislocation should be performed within 72 hours of injury if the patient's condition permits this, which improves the likelihood of recovery of neurological function.

## References:

1. Maiman DJ, Barolat G, Larson SJ: Management of bilateral locked facets of the cervical spine. *Neurosurgery*, 1986; 18: 542-47
2. Ivancic PC, Pearson AM, Tominaga Y et al: Mechanism of cervical spinal cord injury during bilateral facet dislocation. *Spine*, 2007; 32: 2467-73
3. Nassr A, Lee JY, Dvorak MF et al: Variations in surgical treatment of cervical facet dislocations. *Spine*, 2008; 33: E188-93
4. Hadley MN, Fitzpatrick BC, Sonntag VK, Browner CM: Facet fracture-dislocation injuries of the cervical spine. *Neurosurgery*, 1992; 30: 661-66
5. Ebraheim NA, Patil V, Liu J et al: Morphometric analyses of the cervical superior facets and implications for facet dislocation. *Int Orthop*, 2008; 32: 97-101
6. Fehlings MG, Sekhon LH, Tator C: The role and timing of decompression in acute spinal cord injury: What do we know? What should we do? *Spine*, 2001; 26: S101-10
7. Zhang Z, Liu C, Mu Z et al: Anterior facetectomy for reduction of cervical facet dislocation. *Spine*, 2016; 41: E403-9
8. Del Curto D, Tamaoki MJ, Martins DE et al: Surgical approaches for cervical spine facet dislocations in adults. *Cochrane Database Syst Rev*, 2014; (10): CD008129
9. Ordonez BJ, Benzel EC, Naderi S, Weller SJ: Cervical facet dislocation: Techniques for ventral reduction and stabilization. *J Neurosurg*, 2000; 92: 18-23
10. Cloward RB: Reduction of traumatic dislocation of the cervical spine with locked facets. Technical note. *J Neurosurg*, 1973; 38: 527-31
11. Treatment of subaxial cervical spinal injuries. *Neurosurgery*, 2002; 50: S156-65
12. Feng G, Hong Y, Li L et al: Anterior decompression and nonstructural bone grafting and posterior fixation for cervical facet dislocation with traumatic disc herniation. *Spine*, 2012; 37: 2082-88

In this study, the Cervical Curvature Index (CCI) was measured, as previously described by Ishihara [28] (Figure 2), to evaluate the stability of the cervical spine., and this study has shown that anterior surgery can restore the normal curvature and stability of the cervical spine. However, Brodke and colleagues found no significant difference in neurological recovery, stability, or rate of pseudarthrosis formation between patients treated via an anterior approach versus those treated through a posterior approach [20]. However, Du and colleagues have suggested that reconstruction of cervical lordosis and strengthening of cervical stability can reduce the incidence of axial symptoms [29]. Therefore, the use of the CCI is an important measure for evaluating the efficacy of surgery for Cervical facet dislocation.

This study had several limitations, including the small study sample size, and the performance of the study in a single center and was not controlled. Future larger, multicenter, controlled, randomized studies will be required to help standardize the best procedure for the surgical treatment of severe lower cervical facet dislocation.

## Conclusions

Complete decompression, good reduction, and recovery of the intervertebral height and curvature of the spine can be achieved through skull traction and an anterior approach for patients with severe lower cervical facet dislocation. Immediate stabilization of the cervical spine can prevent secondary injury to the spinal cord and aid in the recovery of neurological function.

## Conflict of interest

None.

13. Hart RA: Cervical facet dislocation: when is magnetic resonance imaging indicated? *Spine*, 2002; 27: 116–17
14. Yu JS, Yue JJ, Wei F et al: Treatment of cervical dislocation with locked facets. *Chin Med J (Engl)*, 2007; 120: 216–18
15. Lee JY, Nassr A, Eck JC, Vaccaro AR: Controversies in the treatment of cervical spine dislocations. *Spine J*, 2009; 9: 418–23
16. Miller LS, Cotler HB, De Lucia FA et al: Biomechanical analysis of cervical distraction. *Spine*, 1987; 12: 831–37
17. Onan OA, Heggeness MH, Hipp JA: A motion analysis of the cervical facet. *Spine*, 1998; 23: 430–39
18. Vital JM, Gille O, Sénégas J, Pointillart V: Reduction technique for uni- and biarticular dislocations of the lower cervical spine. *Spine*, 1998; 23: 949–54
19. Hussain M, Nasir S, Murtaza G et al: Magnetic resonance imaging in cervical facet dislocation: a third world perspective. *Asian Spine J*, 2012; 6: 29–33
20. Brodke DS, Anderson PA, Newell DW et al: Comparison of anterior and posterior approaches in cervical spinal cord injuries. *J Spinal Disord Tech*, 2003; 16: 229–35
21. Do KY, Lim TH, Won YJ et al: A biomechanical comparison of modern anterior and posterior plate fixation of the cervical spine. *Spine*, 2001; 26: 15–21
22. Lifeso RM, Colucci MA: Anterior fusion for rotationally unstable cervical spine fractures. *Spine*, 2000; 25: 2028–34
23. Dvorak MF, Fisher CG, Aarabi B et al: Clinical outcomes of 90 isolated unilateral facet fractures, subluxations, and dislocations treated surgically and nonoperatively. *Spine*, 2007; 32: 3007–13
24. Kalayci M, Cağavi F, Açıköz B: Unilateral cervical facet fracture: presentation of two cases and literature review. *Spinal Cord*, 2004; 42: 466–72
25. Du W, Wang C, Tan J et al: Management of subaxial cervical facet dislocation through anterior approach monitored by spinal cord evoked potential. *Spine*, 2014; 39: 48–52
26. Mirza SK, Krengel WF, Chapman JR et al: Early versus delayed surgery for acute cervical spinal cord injury. *Clin Orthop Relat Res* 1999; (359): 104–14
27. Vaccaro AR, Daugherty RJ, Sheehan TP et al: Neurologic outcome of early versus late surgery for cervical spinal cord injury. *Spine*, 1997; 22: 2609–13
28. Takeshita K, Murakami M, Kobayashi A, Nakamura C: Relationship between cervical curvature index (Ishihara) and cervical spine angle (C2–7). *J Orthop Sci*, 2001; 6: 223–26
29. Du W, Wang L, Shen Y et al: Long-term impacts of different posterior operations on curvature, neurological recovery and axial symptoms for multilevel cervical degenerative myelopathy. *Eur Spine J*, 2013; 22: 1594–602