

Case Report

Benign course after acute high dose levothyroxine intoxication in a 3-year-old boy

Stan Hartman¹, Kees Noordam², Machiel Maseland³, and Petra van Setten¹

¹*Rijnstate Hospital, Department of Pediatrics, Arnhem, The Netherlands*

²*Department of Pediatric Endocrinology, Radboud University Medical Centre, Nijmegen, The Netherlands*

³*Department of Clinical Pharmacy, Rijnstate Hospital, Arnhem, The Netherlands*

Abstract. Acute ingestion of thyroid hormone preparations is a common intoxication, with 181 cases in children <12 yr in 2009 in the Netherlands, but generally has a mild course. However, some reports show that even low dosages may cause serious events such as seizures, thyroid storm and coma. We report a 3 yr old boy case with an acute intoxication with high dose levothyroxine (0.5 mg/kg). We describe the proper management of levothyroxine intoxication in children. A 3-year-old boy with no notable medical history ingested sixty tablets of levothyroxine 150 µg. His vital-signs were normal and the only symptom during admission was a tachycardia the following day. Laboratory data showed elevated T3, fT3 and fT4 levels; and decrease TSH levels. He was treated prophylactically and therapeutically with activated charcoal and propranolol. Despite very high levels, his clinical symptoms were relatively mild. After clinical follow-up for 3 d he was discharged. We propose that children with thyroid hormone intoxication with either a levothyroxine dose >0.1 g/kg, a short interval since ingestion, symptomatic presentation, and/or a fT4 >100 pmol/l should be monitored in the hospital during at least 48–72 h post-ingestion and on an outpatient basis for 14 d.

Key words: thyroxine, intoxication, overdose, side-effects

Introduction

Acute ingestion of excess thyroid hormone preparations is a common intoxication reported to poisoning control centres. According to the 2014 American Association of Poison Control Centres Annual Report 9,301 exposures to

thyroid hormone preparations were documented in poison control centres in United States of America. Of these, 4,444 (47.8%) occurred in children younger than 6 yr, 722 (7.8%) in persons aged 6–19 yr and 3,597 (38.7%) in persons aged older than 19 yr (1). In the Netherlands 181 cases of levothyroxine intoxications in children younger than 12 yr were reported in 2009. Although levothyroxine intoxication in children generally has a mild course (2, 3), some reports show that even low dosages of levothyroxine may cause serious events such as seizures, thyroid storm and even coma (4). In this paper, we describe the clinical and pharmacological course of a 3 yr old boy who ingested a high dose levothyroxine (total amount of 9 mg corresponding to 0.5 mg/

Received: July 28, 2016

Accepted: February 25, 2017

Corresponding author: Petra van Setten, MD, PhD, Rijnstate Hospital Arnhem, Wagnerlaan 55, 6800 TA Arnhem, The Netherlands

E-mail: pvansetten@rijnstate.nl

This is an open-access article distributed under the terms of the Creative Commons Attribution Non-Commercial No Derivatives (by-nc-nd) License <<http://creativecommons.org/licenses/by-nc-nd/4.0/>>.

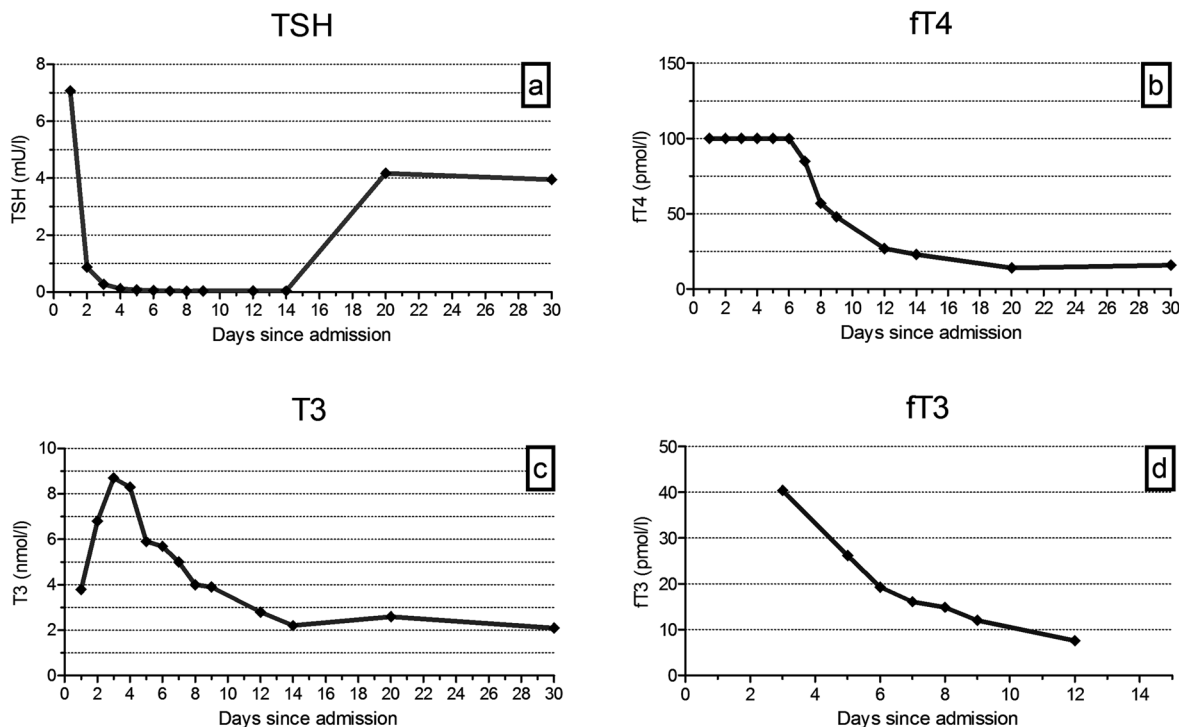


Fig. 1. The change of the TSH, fT4, T3 and fT3 values post-ingestion. a: TSH levels decreased to 0.87 mU/l on d 2, and remained < 0.3 mU/l until d 14; TSH levels returned to normal afterwards. b: fT4 levels increased to > 100 pmol/l from d 1 to d 6, and decreased thereafter, reaching normal levels on d 14. c: T3 levels increased on d 1 of illness to (3.8 nmol/l), reaching its maximum on d 3 (8.7 nmol/l); thereafter T3 levels gradually decreased to normal on d 14. d: fT3 levels were increased at d 3 and gradually decreased to normal level on d 12.

kg, 100 times the normal dose). Despite high levels of fT4 and T3, he had a relatively benign clinical course.

Case Report

Clinical history and past history

A 3-yr-old boy with no notable medical history, weighing 17 kilograms presumably ingested up to a maximum of sixty tablets (150 µg each) of his mother's levothyroxine prescription. The mother had a prescription filled out for 90 tablets and took about 10 tablets until the day of the ingestion. After ingestion of the tablets 20 remaining pills were counted. The ingestion was not witnessed and the missing pills went undiscovered. Besides the levothyroxine tablets, he ingested about 10 tablets of Rennie Deflatine®

(each tablet consists of calcium carbonate 680 mg, magnesium carbonate 80 mg, simethicone 25 mg and saccharose 475 mg). His parents took him to the emergency department about three hours after ingestion. He was asymptomatic with no fever or illness, alert and cooperative.

Physical examination and laboratory findings on admission

The child's vital signs were as follows: respiration rate 20/min, pulse 100/min, blood pressure 107/74 mmHg and temperature 36.9°C. Physical and neurological examination were normal. The levels of free T4, TSH and total T3 were measured for the first time approximately 4 h after ingestion: fT4 >100 pmol/l (ref. 11–25), TSH 7.07 mU/l (ref. 0.30–4.0), total T3 3.8 nmol/l (ref. 1.3–2.6) as shown in Fig. 1.

Clinical course

Because of the high amount of levothyroxine ingested (about 9000 µg, corresponding with approximately 0.5 mg/kg), he was admitted to the hospital and closely monitored. One dose of activated charcoal of 1 g/kg was administered. Prophylactic propranolol (1.8 mg/kg/day) was started after an electrocardiogram showed no abnormalities.

On the second day the boy developed a tachycardia of 130/min during daytime, without diarrhoea, vomiting, temperature instability, insomnia, hyperkinesia or other neurological symptoms. Laboratory findings showed a suppression of TSH (0.87 mU/l) and elevated levels of fT4 (>100 pmol/l), T3 (6.8 pmol/l) and fT3 (40.3 pmol/l). The dosage of propranolol was raised to 3.5 mg/kg/day. Subsequently, the heart rate decreased. On the seventh day after ingestion, the heart rate normalized (approximately 90/min); propranolol dosage was reduced to 1.8 mg/kg/day. Thyroid function tests from day 1–30 are depicted in Fig. 1A–D. The peak concentration of T3 was reached at day 3 (40.38 pmol/l). TSH levels were maximally depressed from day 5 to 14.

The child was discharged from the hospital on the eighth day after ingestion. Physical examination on discharge showed a normal heart rate of 95/min and no further abnormalities. Laboratory findings showed a suppression of TSH (0.04 mU/l) and elevated levels of fT4 (48 pmol/l), T3 (3.9 pmol/l) and fT3 (12.1 pmol/l). Since then he was monitored in the outpatient clinic. The propranolol was stopped at day 12. Since then he had normal vital signs and his thyroid function tests were completely normal at d 30 (Fig. 1).

Discussion

Acute ingestion of thyroid hormone preparations in the paediatric population is commonly reported to poison control centres. In our case a particularly high dose of levothyroxine

was ingested. The subsequent clinical and pharmacological time course is described.

Pharmacokinetics of thyroid hormones

From pharmacological studies is well known that levothyroxine is a thyroxine (T4) analogue, which is the predominant circulating form of thyroid hormone. In the peripheral tissues, T4 is partially converted to liothyronine (T3), a more biologically active thyroid hormone. Since T4 is pharmacologically inactive, T3 is the substance responsible for development of toxicological symptoms. It is clear that if any symptoms appear, they are delayed in onset. Reason for this is that levothyroxine must achieve peripheral conversion to T3.

Pharmacological data also show that T_{max} of levothyroxine is reached at 5–6 hours after oral intake. Elimination half life (T_{1/2}) is 7 d for T4 and 0.8 d for T3. Exogenously administered thyroid hormone indirectly suppresses the thyroid gland activity, in our patient shown by a decreased TSH level. In our opinion his initially slightly elevated TSH is the result of emotional stress at admission.

Lewander *et al.* (2) specifically studied the pharmacokinetics of T4 and T3 in acute T4 intoxication in 7 patients. Their findings indicate a mean T_{1/2} for T4 of 2.8 d, which is shorter than the T_{1/2} observed in physiologic concentrations (7 d in children) and a T_{1/2} for T3 of 6 d, which is almost 5 times longer than in physiologic concentrations. Furthermore the peak concentration of T3 is reached at more than 24 h after the ingestion. This favours the conclusion that delay in onset of symptoms and duration of toxicity is due to the conversion from levothyroxine to T3 and prolonged elimination time of T3 in acute overdose. In our patient, the peak concentration of T3 was on d 3 with T3 reaching normal values after 8 d. This indeed explains the occurrence of symptoms on the second day after levothyroxine overdose.

The usual dose of levothyroxine in hypothyroid paediatric patients is 5–7 µg/kg/d

in one dose. Our patient ingested 530 ug/kg, 100 times the normal dose. His fT4, T3 and fT3 blood levels were increased, at least four times (respectively >100 pmol/l, 8.7 nmol/l and 40.38 pmol/l). T3 reached a peak concentration of 8.7 nmol/l after 3 days. Despite his high dose of ingested levothyroxine and very high thyroid hormone levels, he only showed mild clinical symptoms, limited to a tachycardia and a relatively high blood pressure.

Children seem tolerant to large overdoses of levothyroxine when compared with adults, but not immune to the development of moderate to severe toxicity following acute levothyroxine ingestions. It is suggested that a greater production of reverse T3 (rT3) is responsible for the decreased risk of a thyroid storm after a levothyroxine overdose. rT3 is an isomere T3 which is also derived from T4 deionisation. It binds to the thyroid hormone receptors and thereby blocks the action of T3. (5) The Rennie Deflatine® might have protected our patient unintentionally by binding levothyroxine to cations and thereby decreasing absorption (6).

Comparison of the clinical course with previously reported cases

The majority of previously reported studies report mild symptoms in acute levothyroxine overdose, despite high amounts of levothyroxine taken (dosages up to 18 mg levothyroxine) (2–4,7). Symptoms include tachycardia, fever, irritability, hyperactivity, diarrhoea, abdominal pain and hypertension. Tunget *et al.* (7) even suggested that acute ingestions of levothyroxine less than 5 mg T4 equivalent require no decontamination or aggressive management, since only mild symptoms occur sporadically in this range. However, Tsutaoka *et al.* (4) reported a case of a tonic-clonic seizure in a 3.5 yr old boy on the third day after ingestion of a maximum of 3.6 mg levothyroxine (about 0.22 mg/kg). Rarely, massive thyroid hormone overdose has led to grand mal seizures (4), thyroid storm, and even coma (8), particularly in adults. Overall,

previous reports suggest that there is no dose-response relationship between the occurrence or severity of symptoms and amount levothyroxine ingested. Even patients with a relatively low dose of levothyroxine potentially develop seizures and it is not possible to predict which patients will become symptomatic.

Treatment for the overdose of levothyroxine

Administration of activated charcoal and prophylactic administration of propranolol (potent beta-adrenergic blocker) should be recommended as the initial treatment. As such, we treated our patient with activated charcoal to stimulate decontamination. Thereafter, we started with propranolol to prevent possible complications of the levothyroxine intoxication, such as tachycardia and hypertension. Second reason for using propranolol in these cases is its effect on decreasing plasma T3 and effect on increasing plasma rT3 in a dose-dependent manner. Other treatments such as propylthiouracil, steroids, iopanoic acid, cholestyramine, sodium idopate and hemoperfusion lacks in evidence (2–4, 7, 8). For the management of children at risk, monitoring of vital signs and laboratory data is most important. Reviewing the scarce literature and national and international databases (www.toxbase.org and Poisindex (Micromedex)) we propose close monitoring of clinical course during 48–72 h post ingestion in those children who ingested >0.1 mg levothyroxine/kg, children with a short interval since ingestion, symptomatic presentation and/or a fT4 > 100 pmol/l. Monitoring of vital signs until 14 d post-ingestion is recommended based on elimination half-life of fT4 and the fact that two weeks were needed in this case to normalize levels of TSH, fT3 and fT4.

We believe that children who do not fulfil these criteria can be safely discharged after informing the parents/caregivers about possible (delayed onset of) symptoms and complications. As such, we think both high and low risk children with levothyroxine intoxication will be safely paid attention to prevent serious symptoms.

Conclusion

We propose that children with thyroid hormone intoxication with either a levothyroxine dose > 0.1 g/kg, a short interval since ingestion, symptomatic presentation, and/or a fT4 >100 pmol/l should be closely monitored in the hospital during at least 48–72 h post-ingestion. Based on the period needed for normalisation of thyroid hormones in our case, approximately two weeks of follow-up is recommended after the episode of overdosing

References

1. Mowry JB, Spyker DA, Brooks DE, McMillan N, Schauben JL. 2014 Annual Report of the American Association of Poison Control Centers National Poison Data System (NPDS): 32nd Annual Report. *Clin Toxicol (Phila)* 2015;53: 962–1147. [[Medline](#)] [[CrossRef](#)]
2. Lewander WJ, Lacouture PG, Silva JE, Lovejoy FH. Acute thyroxine ingestion in pediatric patients. *Pediatrics* 1989;84: 262–5. [[Medline](#)]
3. Litovitz TL, White JD. Levothyroxine ingestions in children: an analysis of 78 cases. *Am J Emerg Med* 1985;3: 297–300. [[Medline](#)] [[CrossRef](#)]
4. Tsutaoka BT, Kim S, Santucci S. Seizure in a child after an acute ingestion of levothyroxine. *Pediatr Emerg Care* 2005;21: 857–9. [[Medline](#)] [[CrossRef](#)]
5. Desai M, Irani AJ, Patil K, Pandya CS. The importance of reverse triiodothyronine in hypothyroid children on replacement treatment. *Arch Dis Child* 1984;59: 30–5. [[Medline](#)] [[CrossRef](#)]
6. Singh N, Singh PN, Hershman JM. Effect of calcium carbonate on the absorption of levothyroxine. *JAMA* 2000;283: 2822–5. [[Medline](#)] [[CrossRef](#)]
7. Tunget CL, Clark RF, Turchen SG, Manoguerra AS. Raising the decontamination level for thyroid hormone ingestions. *Am J Emerg Med* 1995;13: 9–13. [[Medline](#)] [[CrossRef](#)]
8. Kreisner E, Lutzky M, Gross JL. Charcoal hemoperfusion in the treatment of levothyroxine intoxication. *Thyroid* 2010;20: 209–12. [[Medline](#)] [[CrossRef](#)]