

Meigs' Syndrome with Elevated Serum CA125: Case Report and Review of the Literature

Mongkol Benjapibal Suthi Sangkarat
Somsak Laiwejpithaya Boonlert Viriyapak
Pattama Chaopotong Atthapon Jaishuen

Department of Obstetrics and Gynecology, Faculty of Medicine Siriraj Hospital,
Mahidol University, Bangkok, Thailand

Key Words

Meigs' syndrome · Ascites · Pleural effusion · Serum CA125

Abstract

An elevated serum CA125 level in association with a pelvic mass, pleural effusion, and massive ascites usually signifies a dismal prognosis in a postmenopausal woman. However, surgery and histopathological examination are required for the correct diagnosis and treatment, since an elevated CA125 level can be falsely positive for ovarian malignancy. We present a case of Meigs' syndrome due to right ovarian fibroma with elevated CA125 level in a postmenopausal woman.

Introduction

The importance of ovarian cancer stems not from the fact that it is the sixth most common cancer in women worldwide, but from the fact that it is the most lethal gynecologic malignancy in Western Europe and North America, killing more women than uterine and cervical cancer combined. It is predominantly a disease of postmenopausal women, with a median age at diagnosis of 60 years [1]. Elevated serum CA125 levels in postmenopausal women with solid adnexal masses, ascites, and pleural effusion are highly suggestive for malignant ovarian tumor. However, surgery and histological confirmation of the preoperative diagnosis are mandatory, since a minority of patients with these findings have a benign condition, commonly known as Meigs' syndrome. This condition disappears after removal of the pelvic tumor. We report a case of Meigs' syndrome caused by right ovarian fibroma with elevated serum CA125 level in a postmenopausal woman.

Case Report

A 56-year-old Thai woman was admitted to another hospital because of progressive dyspnea, abdominal distention and weight loss for 8 months. Her obstetric history included 3 uncomplicated deliveries. She had a history of diabetes mellitus since the age of 46 and her menopause occurred at the age of 52 years. The patient did not complain of any pain or changes in micturition or bowel habits. Her mother had died from endometrial cancer and her sister had a history of breast cancer. Marked right pleural effusion, ascites, and a large abdominal mass were found. Thoracocentesis was done to relieve her dyspnea. The cytology revealed atypical cells suggestive of malignancy. The patient was then referred to our hospital.

On physical examination, there was dullness to percussion with decreased breath sounds in the half of the right lung field. Abdominal examination revealed shifting dullness and a palpable mass reaching to the umbilicus. On pelvic examination, a hard nodular 14 × 12 cm mass was palpated; a separate uterus could not be discerned.

Ultrasonography of the abdomen and pelvis confirmed a moderate amount of ascites, the uterus appeared normal and a right adnexal solid mass of 14 × 12 cm was found. A chest X-ray revealed the presence of a massive right-sided and a minimal left-sided pleural effusion. Repeat thoracocentesis of right lung yielded 1,500 ml of fluid containing reactive mesothelial cells without evidence of malignancy noted on cytology review. Gram stain and acid fast stains also were reported as negative. Pleural biopsy was done and revealed non-specific chronic pleurisy. Blood chemistry was within normal limits except for a serum CA125 level of 1,064 U/ml (normal range 0–35 U/ml).

Due to clinical suspicion of malignant ovarian tumor, the patient was submitted to exploratory laparotomy which revealed 2,500 ml of serous ascites. After aspiration of the ascitic fluid, a 13 × 10 × 10-cm lobulated right adnexal solid mass without excrescences was found ([fig. 1](#)). The uterus and left adnexa appeared normal. Frozen section of the right adnexal mass was read as benign ovarian fibroma. There was no palpable pelvic or periaortic adenopathy; the liver, diaphragm, bowel, and omentum were grossly free of disease. The patient subsequently underwent a total abdominal hysterectomy with bilateral salpingo-oophorectomy. Pathological examination of the specimen showed a benign fibroma of the right ovary.

The postoperative period was uneventful and the patient was discharged on the seventh postoperative day. The serum CA125 level on the sixth postoperative day was 22 U/ml. Six weeks postoperatively, she was followed on an outpatient basis without further complaints. The pleural effusion was resolved completely on repeat chest X-ray. The patient was asymptomatic with a normal serum CA125 level 6 months after the operation.

Discussion

In 1934, Salmon described the association of pleural effusion with benign pelvic tumors. It was not until the report by Meigs and Cass in 1937 that widespread attention of the medical profession was drawn to the significance of pleural effusion and ascites in benign ovarian fibroma [2]. Meigs' syndrome is defined as the triad of benign ovarian tumor with ascites and pleural effusion that resolves after resection of the tumor. Although Meigs' syndrome mimics a malignant condition, it is a benign disease and has a very good prognosis if properly managed. Life expectancy after surgical removal of the tumor mirrors that of the general population.

Ovarian fibroma is found in 2–5% of surgically removed ovarian tumors [3], and Meigs' syndrome is observed in about 1% [4]. Ascites is present in 10–15% of those with ovarian fibroma and pleural effusion in 1%, especially with large lesion [5, 6].

The pathophysiology of ascites in Meigs' syndrome is subject to debate and remains unclear. Meigs suggested that irritation of the peritoneal surfaces by a hard, solid ovarian tumor could stimulate the production of peritoneal fluid [7]. Other proposed mechanisms are direct pressure on surrounding lymphatics or vessels, hormonal stimulation, or release of mediators from the tumor, leading to increased capillary permeability [5, 8, 9].

The etiology of pleural effusion is unclear. It is thought that the occurrence of pleural effusion is secondary to the passage of ascitic fluid to the pleural space through the diaphragm or diaphragmatic lymph vessels which are more common on the right side [10]. The size of the pleural effusion is largely independent of the amount of ascites. The connection between the pelvic tumor and ascites is confirmed by the rapid resolution of abdominal and pleural fluid after removal of the tumor.

CA125 antigen is a glycoprotein with a high molecular weight and is recognized by a monoclonal antibody (OC-125). It is expressed in the amnion and embryonic coelomic epithelium [11]. The antigen can also appear in many adult tissues such as the epithelium of the fallopian tubes, endometrium, endocervix, and ovaries [12]. In addition, it is found in mesothelial cells of the pleura, pericardium and peritoneum. Therefore, some normal body tissues can produce a certain and low level of circulatory or serum CA125. This tumor marker is found elevated during menstruation or pregnancy and in some benign conditions such as endometriosis, peritonitis or cirrhosis, particularly with ascites [13, 14]. It is also increased in vascular invasion, tissue destruction and inflammation associated with malignant disease. In a series by O'Connell et al. [15], the predictive value of a CA125 level greater than 35 U/ml was 60% for ovarian cancer and 84% for some type of malignancy. The authors also reported three patients with ovarian fibroma and elevated serum CA125 levels (above 35 U/ml) in their series. No details were given whether these patients also had Meigs' syndrome.

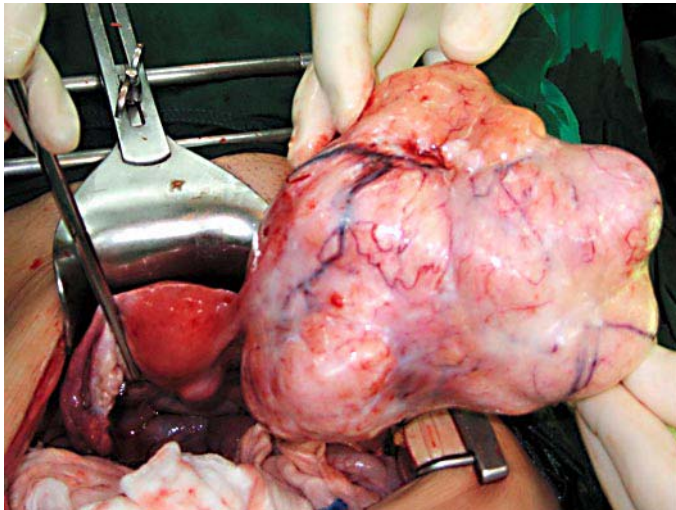
The coincidence of Meigs' syndrome with elevation of serum CA125 levels has been described in the published literature in only 28 cases (table 1). The histological types reported have been fibroma (15 cases), cellular fibroma (4 cases), thecoma (4 cases), fibroma thecoma (3 cases), granulosa cell tumor (1 case), and benign Brenner tumor (1 case). Serum CA125 levels above 1,000 U/ml are exceptional, and only 6 cases with this feature have been reported previous to the present study.

The immunohistochemical study for CA125 suggested that serum elevation of CA125 antigen in patients with Meigs' syndrome is caused by mesothelial expression of CA125 rather than by fibroma [22, 25]. The precise mechanism remains unclear, but a biomedical factor, mechanical irritation from a large tumor, or an increase in intraperitoneal pressure from a large volume of ascites might be primary factors in this process.

The association of massive abdominal ascites, pleural effusion, and a large pelvic mass with an elevated serum CA125 level portends a poor prognosis. However, it is paramount to remember that this combination of findings does not always predict an ominous diagnosis. This case illustrates the importance of appropriate surgery to obtain histopathological confirmation of Meigs' syndrome, as a small percentage of patients will have a benign etiology even in the presence of an elevated serum CA125 level.

Table 1. Summary of reported cases of Meigs' syndrome with elevated serum CA125 level

Author	Year	No. of cases	Age	Histopathology	CA125 U/ml
Jones and Surwit [16]	1989	1	70	Fibroma/thecoma	226
Hoffman [17]	1989	1	39	Thecoma	498
Martin et al. [18]	1990	1	NR	Granulosa cell tumor	307
Walker et al. [19]	1990	2	52, 67	Cellular fibroma	>5,000, 104
Le Bouedec et al. [20]	1992	2	66, 76	Fibroma/thecoma	645, 286
Williams et al. [21]	1992	1	74	Luteinized thecoma	329
Lin et al. [22]	1992	2	74, 72	Fibroma	2,120, 7,000
Turan et al. [23]	1993	1	63	Thecoma	744
Siddiqui and Toub [24]	1995	1	73	Cellular fibroma	1,780
Timmerman et al. [25]	1995	2	71, 73	Fibroma	484.5, 42.3
Abad et al. [5]	1997	1	51	Cellular fibroma	577
Chan et al. [6]	2000	1	13	Fibroma	970
Patsner [26]	2000	6	62, 57, 52, 60, 72, 58	Fibroma	185, 850, 520, 64, 1,200, 80
Buttin et al. [27]	2001	1	67	Brenner tumor	759
López et al. [28]	2002	2	78, 68	Fibroma	498, 265
Vieira et al. [29]	2003	1	65	Thecoma	319
Móran-Mendoza et al. [30]	2004	1	46	Fibroma	1,808
Current report	2007	1	56	Fibroma	1,064

Fig. 1. Right ovarian fibroma measuring 13 × 10 × 10 cm and weighing 690 g.

References

- 1 Parkin DM, Bray F, Ferlay J, Pisani P: Global cancer statistics, 2002. *CA Cancer J Clin* 2005;55:74–108.
- 2 Meigs JV, Cass JW: Fibroma of the ovary with ascites and hydrothorax: a report of 7 cases. *Am J Obstet Gynecol* 1937;33:249–267.
- 3 Scully RE: Ovarian tumors: a review. *Am J Pathol* 1977;87:686–720.
- 4 Young RH, Scully RE: Ovarian sex cord-stromal tumors. Problems in differential diagnosis. *Pathol Annu* 1988;23:237–296.
- 5 Abad A, Cazorla E, Ruiz F, Aznar I, Asins E, Llixiona J: Meigs' syndrome with elevated CA125: case report and review of the literature. *Eur J Obstet Gynecol Reprod Biol* 1999;82:97–99.
- 6 Chan CY, Chan SM, Liauw L: A large abdominal mass in a young girl. *Br J Radiol* 2000;73:913–914.
- 7 Meigs JV: Fibroma of the ovary with ascites and hydrothorax; Meigs' syndrome. *Am J Obstet Gynecol* 1954;67:962–985.
- 8 Samanth KK, Black WC 3rd: Benign ovarian stromal tumors associated with free peritoneal fluid. *Am J Obstet Gynecol* 1970;107:538–545.
- 9 Terada S, Suzuki N, Uchide K, Akasofu K: Uterine leiomyoma associated with ascites and hydrothorax. *Gynecol Obstet Invest* 1992;33:54–58.
- 10 Agranoff D, May D, Jameson C, Knowles GK: Pleural effusion and a pelvic mass. *Postgrad Med J* 1998;74:265–267.
- 11 Bast RC Jr, Feeney M, Lazarus H, Nadler LM, Colvin RB, Knapp RC: Reactivity of a monoclonal antibody with human ovarian carcinoma. *J Clin Invest* 1981;68:1331–1337.
- 12 Kabawat SE, Bast RC Jr, Bhan AK, Welch WR, Knapp RC, Colvin RB: Tissue distribution of a coelomic-epithelium-related antigen recognized by the monoclonal antibody OC125. *Int J Gynecol Pathol* 1983;2:275–285.
- 13 Jacobs I, Bast RC Jr: The CA 125 tumour-associated antigen: a review of the literature. *Hum Reprod* 1989;4:1–12.
- 14 Kudlacek S, Schieder K, Kölbl H, et al: Use of CA 125 monoclonal antibody to monitor patients with ovarian cancer. *Gynecol Oncol* 1989;35:323–329.
- 15 O'Connell GJ, Ryan E, Murphy KJ, Prefontaine M: Predictive value of CA 125 for ovarian carcinoma in patients presenting with pelvic masses. *Obstet Gynecol* 1987;70:930–932.
- 16 Jones OW 3rd, Surwit EA: Meigs' syndrome and elevated CA 125. *Obstet Gynecol* 1989;73:520–521.
- 17 Hoffman MS: Peritoneal tuberculosis, large ovarian thecoma and an elevated serum CA 125 level mimicking ovarian cancer. *J Fla Med Assoc* 1989;76:388–389.
- 18 Martin F, Brouche S, Haidar A: A prop d'un cas avec tumeur ovarienne de la granulose. *Rev Pneumol Clin* 1990;46:123–124.
- 19 Walker JL, Manetta A, Mannel RS, Liao SY: Cellular fibroma masquerading as ovarian carcinoma. *Obstet Gynecol* 1990;76:530–531.
- 20 Le Bouedec G, Glowaczower E, de Latour M, Fondrinier E, Kauffmann P, Dauplat J: Le syndrome de Demons-Meigs. A propos d'un fibrothecoma et d'un fibrome ovariens. *J Gynecol Obstet Biol Reprod* 1992;21:651–654.
- 21 Williams LL, Fleischer AC, Jones HW 3rd: Transvaginal color Doppler sonography and CA-125 elevation in a patient with ovarian thecoma and ascites. *Gynecol Oncol* 1992;46:115–118.
- 22 Lin JY, Angel C, Sickel JZ: Meigs syndrome with elevated serum CA 125. *Obstet Gynecol* 1992;80:563–566.
- 23 Turan YH, Demirel LC, Ortaç F: Elevated CA 125 in Meigs syndrome. *Int J Gynaecol Obstet* 1993;43:64–65.
- 24 Siddiqui M, Toub DB: Cellular fibroma of the ovary with Meigs' syndrome and elevated CA-125: a case report. *J Reprod Med* 1995;40:817–819.
- 25 Timmerman D, Moerman P, Vergote I: Meigs' syndrome with elevated serum CA 125 levels: two case reports and review of the literature. *Gynecol Oncol* 1995;59:405–408.

- 26 Patsner B: Meigs syndrome and ‘false positive’ preoperative serum CA-125 levels: analysis of ten cases. *Eur J Gynaecol Oncol* 2000;21:362–363.
- 27 Buttin BM, Cohn DE, Herzog TJ: Meigs’ syndrome with an elevated CA 125 from benign Brenner tumors. *Obstet Gynecol* 2001;98:980–982.
- 28 López SP, Laforga J, Torregrosa P, García EJM, Rius JJ: Síndrome de Meigs: presentación de dos casos. *Prog Obstet Ginecol* 2002;45:403–407.
- 29 Vieira SC, Pimentel LH, Ribeiro JC, de Andrade Neto AF, de Santana JO: Meigs’ syndrome with elevated CA 125: case report. *Sao Paulo Med J* 2003;121:210–212.
- 30 Mórán-Mendoza A, Alvarado-Luna G, Calderillo-Ruiz G, Serrano-Olvera A, López-Graniel CM, Gallardo-Rincón D: Elevated CA125 level associated with Meigs’ syndrome: case report and review of the literature. *Int J Gynecol Cancer* 2006;16(suppl 1):315–318.