

Mismatch repair genes expression defects & association with clinicopathological characteristics in colorectal carcinoma

Gurjeet Kaur^{a,b}, Abdelhafid Masoud^b, N. Raihan^c, M. Radzi^d, W. Khamizar^e & Lee Suk Kam^f

^aInstitute for Research in Molecular Medicine, Universiti Sains Malaysia, Penang, ^bAdvanced Medical & Dental Institute, Universiti Sains Malaysia, Penang, ^cDepartment of Pathology, Hospital Sultanah Bahiyah, Alor Star, Kedah, ^dDepartment of Internal Medicine, Hospital Sultanah Bahiyah, Alor Star, Kedah, ^eDepartment of Surgery, Hospital Sultanah Bahiyah, Alor Star, Kedah & ^fDepartment of Pathology, Hospital Pulau Pinang, Penang, Malaysia

Received January 28, 2010

Background & objectives: DNA mismatch repair gene (*MMR*) abnormalities are seen in 95 per cent of hereditary nonpolyposis colorectal cancer (HNPCC) and 10-15 per cent of sporadic colorectal cancers. There are no data on *MMR* abnormalities in Malaysian colorectal cancer patients. This study was aimed to determine the frequency of abnormal *MMR* gene protein expression in colorectal carcinoma in Northern Peninsular Malaysia using immunohistochemistry.

Methods: Clinicopathological information was obtained from 148 patients' records who underwent bowel resection for colorectal cancer (CRC) at the three hospitals in Malaysia. Immunohistochemistry for MLH1, MSH2, MSH6 and PMS2 proteins were performed on paraffin embedded tissue containing carcinoma.

Results: A total of 148 subjects and 150 colorectal carcinomas of sporadic and hereditary types were assessed. Three patients had synchronous tumours. Twenty eight cancers (18.6%) from 26 subjects (17.6%) had absent immunohistochemical expression of any one of the *MMR* gene proteins. This comprised absent MLH1 only – 3 cancers, absent MSH2 only – 3, absent MSH6 only – 2, absent PMS2 only – 3, absent MLH1 and PMS2 – 14, absent MSH2 and MSH6 – 2 and absent MLH1, MSH6 and PMS2 – 1. There was significant association between abnormal *MMR* gene protein expression and proximal colon cancers, mucinous, signet ring and poorly differentiated morphology.

Interpretation & conclusions: Cancers with abnormal *MMR* gene expression were associated with microsatellite instability-high (MSI-H) phenotype. About 15 per cent demonstrated absent MSH2, MSH6 and PMS2 protein expression in isolation or in combination with other *MMR* genes, which often predicts a germline mutation, synonymous with a diagnosis of HNPCC. This appears to be high frequency compared to reported data.

Key words Colorectal carcinoma - Malaysia - mismatch repair gene protein

Colorectal cancer is the most predominant cancer among males and ranked third among females in Malaysia¹. Majority of colorectal cancers (CRC)

are sporadic and develop through the chromosomal instability pathway. However, in more than 90 per cent of hereditary non-polyposis colorectal cancer

(HNPCC) and 10-15 per cent of sporadic CRC, microsatellite instability (MSI) is the underlying mechanism for carcinogenesis. Microsatellite instability is characterized by a defect in any of the mismatch repair (*MMR*) genes (*MLH1*, *MSH2*, *PMS1*, *PMS2*, *GTBP/MSH6*) that leads to incapacity to recognise and repair errors that occur during DNA replication. The loss of DNA MMR activity accelerates the rate of accumulation of mutations in other genes involved in apoptosis and growth control that predispose to a more rapid adenoma-to-carcinoma transition, as seen in HNPCC^{2,3}. In HNPCC, a germline mutation in any of the *MMR* genes (usually in *hMLH1* or *hMSH2*) is accompanied by another event, usually allelic loss that inactivates the MMR gene^{2,4,6}. On the other hand, an epigenetic event involving hypermethylation of the promoter region of *MLH1* gene causes transcriptional silencing of gene⁶⁻⁸.

Colorectal cancers showing MSI-H (MSI-high) have certain characteristic histopathological features compared to cancers with normal *MMR* gene expression. The MSI-H tumours are seen in females, arise in proximal (right) colon, and are poorly differentiated or mucinous type tumours with presence of intra-epithelial lymphocytic infiltration^{3,4,8-12}. Clinically, these are associated with a less aggressive clinical course, present at a lower stage and appear to have increased responsiveness to certain adjuvant chemotherapy.

Proteins associated with the *MMR* genes can be detected by immunohistochemistry (IHC) in tumour tissue sections whereby expression is lost (absent staining) in adenocarcinoma which is associated with loss or inactivation of the relevant mismatch repair gene. Immunohistochemistry performed on paraffin embedded tissue sections has been shown to be a sensitive (77-100%) and specific (98-100%) method for the detection of mismatch repair gene proteins as compared to molecular MSI testing^{3,4,12-17}. Immunohistochemistry has been suggested as the screening method of choice prior to mutation analysis of the *MMR* genes^{15,18-20}.

There are no data available on the prevalence of *MMR* gene defects in patients with colorectal cancers in Malaysia. The incidence of HNPCC is also unknown. Before embarking on a molecular analysis profile for clinically suspected HNPCC probands, we sought to firstly determine the frequency of *MMR* gene protein expression defects in consecutive patients with colorectal carcinoma using immunohistochemistry. The association of abnormal MMR protein expression

and clinicopathological characteristics of colorectal carcinoma was also studied.

Material & Methods

This retrospective study included colorectal cancer cases from 2004 to 2007. Sample size was calculated using 'Sample size calculator for estimations' program²¹. Setting the confidence level at 95 per cent, the expected proportion at 0.15 (proportion of positive results by immunohistochemistry¹⁷ and using the precision level of 0.058, the final minimum sample size required was 146.

Pathology records of consecutive colorectal cancer cases having bowel resection from three government hospitals (Advanced Medical and Dental Institute, Penang; Penang Hospital, Penang; and Hospital Sultanah Bahiyah, Kedah) were reviewed. Information was obtained on patients' demographics, tumour site, histopathological features and Duke's stage.

Immunohistochemistry: One paraffin embedded tissue block from each resected bowel specimen containing carcinoma and preferably adjacent non-neoplastic colon were selected. Four µm thick tissue sections were cut, dewaxed in xylene and rehydrated in graded alcohol concentrations to distilled water. Slides were placed in Tris-EDTA buffer at pH 9.0 in a pressure chamber for antigen retrieval for 2 min at 123°C. Peroxidase blocking reagent (DakoCytomation, Denmark) was used to block endogenous peroxidase activity. Slides were incubated with 150-200 µl of the following primary monoclonal mouse antibodies: MLH1 antibody (BD Biosciences Pharmingen, USA, Cat. No.550838) at 1/50 dilution, MSH2 antibody (BD Biosciences Pharmingen, USA, Cat. No.556349) at 1/200 dilution, MSH6 antibody (BD Biosciences Transduction Laboratories, USA, Cat. No.610919) at 1/50 dilution and PMS2 ((BD Biosciences Pharmingen, USA, Cat. No. 556415) at 1/500 dilution. Horseradish-peroxidase (HRP) labelled polymer, conjugated to secondary antibody and thereafter DAB substrate chromogen (DAKO Envision detection kit, peroxidase/DAB, Rabbit/Mouse, Denmark) were applied. Slides were counterstained with haematoxylin.

Normal expression of protein was defined as presence of nuclear staining in colon cancer cells. Loss of staining in carcinoma with concurrent positive staining in nuclei of normal colon epithelial cells indicated protein inactivation. Adjacent non-neoplastic colon and stromal inflammatory cells served as internal positive control. External positive control was

normal colon, taken from normal resected margins of colectomy specimens.

The results were analysed using STATA version 8 (STATA Inc. USA). If Pearson Chi Square assumption was not satisfied, Fisher's Exact Test was used, $P < 0.05$ was considered significant.

Results

Clinicopathological characteristics: A total of 148 consecutive patients who underwent large bowel resection for colorectal carcinoma were included into the study. They were from three government hospitals, namely Advanced Medical and Dental Institute, Penang; Penang Hospital, Penang; and Hospital Sultanah Bahiyah, Kedah. There were 77 males and 71 females with male:female ratio of 1.08:1. Subjects', age ranged from 21 - 94 yr (mean age 59.8, median 61.0 yr). Majority of patients ($n=116$; 78.4%) were above 50 yr. The distribution of ethnic groups were Malay 56.8 per cent (84/148), Chinese 33.7 per cent (50/148), Indian 8.1 per cent (12/148) and 2 of other ethnic groups. Three patients had two synchronous tumours each. Two of these cases were analysed separately for pathological parameters and *MMR* gene expression status, hence a total of 150 colorectal carcinomas were analysed. In the third case only the larger tumour was studied.

Rectum was the most common site of cancer (70/150, 46.7%) followed in decreasing frequency by sigmoid colon (30/150, 20.0%), caecum (15/150, 10.0%), ascending colon (14/150, 9.3%), descending colon (12/150, 8.0%) and transverse colon (9/150, 6.0%). Left side colon cancers made up 119 (79.3%) of total cancers. In the cases of synchronous tumours, one subject had two carcinomas arising in the transverse colon. Only the larger tumour was analysed. Another patient had synchronous tumours in the rectum and caecum while the third had tumours in the ascending and descending colon.

Majority of carcinomas were histologically typed as classical adenocarcinoma (134/150 cases, 89.3%). The others constituted 11 cases of mucinous carcinoma, 3 signet ring carcinomas and 2 neuroendocrine carcinomas. Histological differentiation of carcinomas was analysed in 137 cases. Results showed 109 (72.7%) of moderately differentiated cancers, 20 (13.3%) well differentiated and 8 (5.3%) poorly differentiated.

Immunohistochemical studies: Protein expression for MLH1, MSH2, MSH6 and PMS2 antigens were evaluated in 150 colorectal cancer tissue samples. Normal expression of the respective antigen was reported when there was nuclear staining in normal and cancer colon epithelium. Abnormal gene expression resulted in absent nuclear staining in cancer epithelium. Staining was successful in all cases though MLH1 staining was often of a heterogeneous pattern whereby many tumour cells nuclei were positively stained and admixed with unstained tumour nuclei. MSH2 and PMS2 produced good nuclear staining, while MSH6 tended to show strong nuclear stain as well as weak cytoplasmic stain. Normal colon and stromal inflammatory cells were internal controls. One patient did not have enough cancer tissue for MSH6 and PMS2 staining.

Twenty eight (18.7%) colorectal cancers from 26 subjects demonstrated absence of any one of the *MMR* gene proteins expression. Three showed absent MLH1 protein expression only, 3 showed absent MSH2 only, two absent MSH6 only and three with absent PMS2 only. MLH1 and PMS2 proteins were absent in 14 cases while MSH2 and MSH6 were absent in 2 cases. One case showed absence of MLH1, MSH6 and PMS2 expression. Clinicopathological variables of subjects and associated abnormal *MMR* gene expression proteins are shown in the Table. Representative images of normal and absent (abnormal) *MMR* gene protein expression are shown in the Fig.

Statistical analysis using Fisher's Exact test showed that abnormal *MMR* protein expression was associated with tumour site (Fisher's Exact < 0.001), side of colon with cancer (chi square $P < 0.001$), histological type of cancer (Fisher's Exact = 0.002) and histological differentiation (Fisher's Exact = 0.048). There was no association between abnormal *MMR* gene protein expression and patient age, gender or ethnic group (Table).

Abnormal *MMR* protein expression appeared to be associated with right sided colon cancers which had abnormal *MMR* protein expression in 45.0 per cent (14/31 cases) compared to 11.8 per cent (14/119) of left sided colon cancers. Eight of 14 (57.1%) cancers in the ascending colon and 6 of 15 (40.0%) caecal cancers showed absent *MMR* protein expression compared to 4 of 70 (5.7%) rectal cancers and 5 of 30 (16.7%) sigmoid colon cancers (Table).

Table. The relationship between clinicopathological variables and *MMR* gene protein expression

	n	Normal expression Freq (%)	Abnormal expression Freq (%)	χ^2 statistic (df)	P value
<i>Tumour site:</i>					
Caecum	15	9 (60.0)	6 (40.0)	-	<0.001*
Ascending colon	14	6 (42.8)	8 (57.2)		
Transverse colon	9	7 (77.8)	2 (22.2)		
Descending colon	12	9 (75.0)	3 (25.0)		
Sigmoid colon	30	25 (83.3)	5 (16.7)		
Rectum	70	66 (94.3)	4 (5.7)		
<i>Side of colon:</i>					
Right side	31	17 (54.8)	14 (45.2)	18.067 (1)	<0.001**
Left side	119	105 (88.2)	14 (11.8)		
<i>Type of tumour:</i>					
NOS	134	114 (85.0)	20 (15.0)	-	0.002*
Mucinous	11	5 (45.4)	6 (54.6)		
Signet ring	3	1 (33.3)	2 (66.7)		
Others	2	2 (100.0)	0		
<i>Tumour grade:</i>					
Well differentiated	20	17 (85.0)	3 (15.0)	-	0.048*
Moderately differentiated	109	94 (86.2)	15 (13.8)		
Poorly differentiated	8	4 (50.0)	4 (50.0)		

*Fisher's Exact test; **Chi square test for Independence

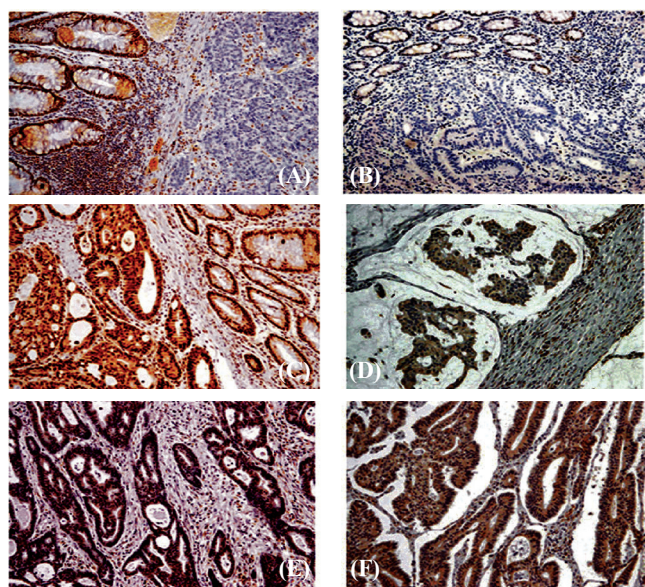


Fig. Immunohistochemical staining of *MMR* gene proteins, x 200 magnification. **(A)** Positive nucleus staining for MLH1 protein in normal colon (left) and absent staining in colon cancer (right). **(B)** Positive nucleus staining for PMS2 protein in normal colon (upper) and absent staining in colon cancer (lower). **(C)** Positive nucleus staining for MSH2 protein in normal colon (right) and colon cancer (left). **(D)** Absent nucleus staining for MSH2 protein in mucinous carcinoma (left) and positive staining in fibrous stromal cells, as internal control (right). **(E)** Scattered positive nucleus staining for MSH6 in colon cancer. **(F)** Absent nucleus staining and weak cytoplasm staining for MSH6 in colon cancer.

There was significant association between abnormal MMR protein expression and histological type of cancer (Fisher's Exact = 0.002). Two of 3 (66.7%) signet ring carcinomas and 6 of 11 (54.5%) mucinous carcinomas showed absent MMR protein while 14.9 per cent (20/134) cases of classical adenocarcinoma demonstrated absent expression. Both neuroendocrine cancers showed normal MMR expression.

Abnormal MMR protein expression was also significantly associated with histological differentiation of cancers (Fisher's Exact = 0.048). Fifty per cent (4/8 cases) of poorly differentiated cancers showed absent MMR protein expression compared to 13.8 per cent (15/109) of moderately differentiated tumours and 15.0 per cent (3/20) of well differentiated tumours.

A case of synchronous tumours in ascending and descending colon showed absence of MLH1, PMS2 and MSH6 while another case of synchronous cancers (caecum and rectum) in a 48 yr old male showed absence of MSH2 and MSH6 protein.

Discussion

This pilot study provided data on the prevalence of MMR gene defects in colorectal cancers and to

extrapolate the frequency of cases suggestive of HNPCC in Malaysia. Immunohistochemistry was used to evaluate abnormal MMR gene protein expression as it has been shown to have a high specificity and sensitivity in predicting microsatellite instability status^{3,4,12-17}. It also has several advantages over microsatellite instability testing as a first-line screening tool for identifying HNPCC. It is easily available as part of a routine technique used in pathology laboratories, is inexpensive¹³, rapid and is performed on paraffin embedded tissue sampled at time of colectomy. It also aids in identification of which particular *MMR* gene may be defective and therefore, enables more efficient mutation analysis. The sensitivity of immunohistochemistry is enhanced with all four antibodies as part of the antibody panel.

The study sample comprised a mixture of both sporadic and hereditary colorectal cancers. In general, about 85 per cent of sporadic colorectal cancers possess normal MMR function, whereas 15 per cent have defective MMR function. The cancer in this group is often associated with hypermethylation of the promoter region of the *MLH1* gene resulting in transcriptional silencing of *MLH1* gene and absent protein expression^{7,8}. In the present study, three subjects had isolated absent *MLH1* expression, a characteristic of sporadic CRC.

HNPCC accounts for 2-5 per cent of all colorectal cancers, in which there is a germline mutation in one of the MMR genes, usually *MLH1* (40-45% of cases), *MSH2* (40-45%), *MSH6* (5-10%) and *PMS2* (1%)²². The loss of expression of *MSH2*, *MSH6* or *PMS2* in isolation or in combination, provides reasonably strong evidence of a germline mutation in the respective gene and therefore, highly suggestive of HNPCC^{8,11,22}. The presence of synchronous or metachronous colorectal or other HNPCC-associated tumours is a criterion for MSI testing⁴. In our study two subjects showed synchronous tumours associated with absence of at least two *MMR* gene proteins expression, thus reflecting a high probability of HNPCC.

About 15 per cent subjects in this study did not show *MSH2*, *MSH6* and *PMS2* protein expression in isolation or in combination with other *MMR* genes. This appears to be a rather high frequency of subjects likely to have MMR germline mutation and hence HNPCC. This may be due to the use of a panel of four antibodies against *MLH1*, *MSH2*, *MSH6* and *PMS2* instead of

the usual two *i.e.*, *MLH1* and *MSH2* used in screening. Though the majority of germline mutations in HNPCC occur in *MLH1* or *MSH2* genes, the additional screening of *PMS2* and *MSH6* proteins is able to identify more such cases¹⁷.

The formation of heterodimers between *MLH1* and *PMS2* proteins accounts for the frequent absence of these proteins in combination in immunohistochemistry. Since *MLH1* often produces weak and heterogeneous immunohistochemical staining pattern, the addition of *PMS2* antibody improves the predictive value of germline mutation^{2,13,15,17,23}. Fourteen subjects in the current study had loss of *MLH1* and *PMS2* proteins in contrast to only 3 subjects with loss of *MLH1* staining alone. In a similar manner, there is often a concurrent loss of *MSH2* and *MSH6* proteins, though our study did not show a significant increase in number of case detection using these two antibodies.

Fifteen of the 26 subjects with absence of *MMR* gene protein expression fulfilled at least one of the Modified Bethesda Guidelines²² *i.e.*, being diagnosed with colorectal cancer below the age of 50 yr (6 subjects), having synchronous colorectal cancers (2 subjects) or histological features of microsatellite instability tumours which include mucinous (6 cases), signet ring (2 cases) or poorly differentiated carcinoma (4 cases).

In concordance with other studies, our results showed that abnormal *MMR* gene protein expression was associated with MSI-H histopathological features which include right sided tumours, mucinous, signet ring and poorly differentiated morphology^{4,8-10}. Though it is almost impossible to distinguish sporadic and HNPCC tumours by histology, presence of tumour-infiltrating lymphocytes appears to be more evident in HNPCC while mucinous histology, poor differentiation and co-existing serrated polyps are features suggestive of sporadic cancer^{8,22}. In the current study, only data on tumour differentiation and existence of colorectal polyps were obtained from the pathology reports.

Our results did not show any significant association between abnormal MMR protein expression and patients' age, gender or ethnic group. This was expected as there were no specific selection criteria for subjects other than having a diagnosis of colorectal cancer. Therefore, the majority of cancers would be of the sporadic type, with 78.4 per cent of subjects in this study being older than 50 yr. The male to female ratio was comparable to the Malaysian cancer

statistics of 1.1: 1¹. However, it was interesting to note a higher incidence of colorectal cancer in Malays compared to Chinese and Indians in the present study, unlike the national cancer statistics which quoted the highest incidence in the Chinese community¹. A major limitation is that our study was confined to specific regions of Peninsular Malaysia and hence not reflective of the true ethnic ratio.

Age at onset of colorectal cancer, family history and tumour morphology are important data that aid in distinguishing sporadic CRC and HNPCC⁸. In clinically suspected HNPCC patients, immunohistochemistry is often used as the first line screening tool which is followed up by microsatellite instability testing if there is no immunohistochemical abnormality. Patients with cancers showing lack of any *MMR* gene proteins will be confirmed by the germline mutation studies for that specific gene^{14,20}. Sporadic CRC is associated with a lower frequency of *APC* and *K-ras* mutation, and higher frequency of *BRAF* mutation and DNA methylation^{8,11,22}.

In conclusion, there appears to be a high frequency of abnormal *MMR* gene protein expression in this heterogenous population of colorectal cancers in Malaysia. These patients need to be further evaluated in terms of clinical and family history, and a diagnosis of HNPCC confirmed by germline mutation analysis in clinically suspected cases. It is essential that appropriate clinical management and genetic counselling are in place for patients and their families.

Acknowledgment

Authors thank Ms Mariam Azmi for technical expertise in conducting the immunohistochemistry experiments. This study was approved by the university's Research and Ethics Committee and supported by Universiti Sains Malaysia short term grant 304/CIPPT/637080.

References

1. Lim GCC, Rampal S, Halimah Y, editors. In: *Second report of the National Cancer Registry*, Cancer Incidence in Malaysia 2003. Kuala Lumpur: National Cancer Registry; 2008.
2. Boland CR, Koi M, Chang DK, Carethers JM. The biochemical basis of microsatellite instability and abnormal immunohistochemistry and clinical behavior in Lynch syndrome: from bench to bedside. *Fam Cancer* 2008; 7 : 41-52.
3. Lindor NM, Burgart LJ, Leontovich O, Goldberg RM, Cunningham JM, Sargent DJ, *et al.* Immunohistochemistry versus microsatellite instability testing in phenotyping colorectal tumors. *J Clin Oncol* 2002; 20 : 1043-8.
4. Boland CR, Thibodeau SN, Hamilton SR, Sidransky D, Eshleman JR, Burt RW, *et al.* A National Cancer Institute Workshop on Microsatellite Instability for cancer detection and familial predisposition: development of international criteria for the determination of microsatellite instability in colorectal cancer. *Cancer Res* 1998; 58 : 5248-57.
5. Wheeler JM, Bodmer WF, Mortensen NJ. DNA mismatch repair genes and colorectal cancer. *Gut* 2000; 47 : 148-53.
6. Grady WM. Genomic instability and colon cancer. *Cancer Metastasis Rev* 2004; 23 : 11-27.
7. Yang B. Epigenetics: DNA hypermethylation in cancer. In: Tubbs RR, Stoler MH, editors. *Cell and tissue based molecular pathology*. Philadelphia, PA: Churchill Livingstone, Elsevier; 2009. p. 84-90.
8. Jass JR. HNPCC and sporadic MSI-H colorectal cancer: a review of the morphological similarities and differences. *Fam Cancer* 2004; 3 : 93-100.
9. Kim H, Jen J, Vogelstein B, Hamilton SR. Clinical and pathological characteristics of sporadic colorectal carcinomas with DNA replication errors in microsatellite sequences. *Am J Pathol* 1994; 145 : 148-56.
10. Jass JR, Do KA, Simms LA, Lino H, Wynter C, Pillay SP, *et al.* Morphology of sporadic colorectal cancer with DNA replication errors. *Gut* 1998; 42 : 673-9.
11. Jass JR, Walsh MD, Barker M, Simms LA, Young J, Leggett BA. Distinction between familial and sporadic forms of colorectal cancer showing DNA microsatellite instability. *Eur J Cancer* 2002; 38 : 858-66.
12. Ruzkiewicz A, Bennett G, Moore J, Manavis J, Rudzki B, Shen L, *et al.* Correlation of mismatch repair genes immunohistochemistry and microsatellite instability status in HNPCC-associated tumours. *Pathology* 2002; 34 : 541-7.
13. Shia J. Immunohistochemistry versus microsatellite instability testing for screening colorectal cancer patients at risk for hereditary nonpolyposis colorectal cancer syndrome. Part I. The utility of immunohistochemistry. *J Mol Diagn* 2008; 10 : 293-300.
14. Shia J, Ellis NA, Klimstra DS. The utility of immunohistochemical detection of DNA mismatch repair gene proteins. *Virchows Arch* 2004; 445 : 431-41.
15. Shia J, Klimstra DS, Nafa K, Offit K, Guillem JG, Markowitz AJ, *et al.* Value of immunohistochemical detection of DNA mismatch repair proteins in predicting germline mutation in hereditary colorectal neoplasms. *Am J Surg Pathol* 2005; 29 : 96-104.
16. Southey MC, Jenkins MA, Mead L, Whitty J, Trivett M, Tesoriero AA, *et al.* Use of molecular tumor characteristics to prioritize mismatch repair gene testing in early-onset colorectal cancer. *J Clin Oncol* 2005; 23 : 6524-32.
17. Stone JG, Robertson D, Houlston RS. Immunohistochemistry for MSH2 and MHL1: a method for identifying mismatch repair deficient colorectal cancer. *J Clin Pathol* 2001; 54 : 484-7.
18. Marcus VA, Madlensky L, Gryfe R, Kim H, So K, Millar A, *et al.* Immunohistochemistry for hMLH1 and hMSH2: a practical test for DNA mismatch repair-deficient tumors. *Am J Surg Pathol* 1999; 23 : 1248-55.

19. Paraf F, Gilquin M, Longy M, Gilbert B, Gorry P, Petit B, *et al.* MLH1 and MSH2 protein immunohistochemistry is useful for detection of hereditary non-polyposis colorectal cancer in young patients. *Histopathology* 2001; 39 : 250-8.
20. Christensen M, Katballe N, Wikman F, Primdahl H, Sorensen FB, Laurberg S, *et al.* Antibody-based screening for hereditary nonpolyposis colorectal carcinoma compared with microsatellite analysis and sequencing. *Cancer* 2002; 95 : 2422-30.
21. Naing L, Winn T, Rusli BN. Sample size calculator for estimations, Version 1.0.03. Available at: http://www.kck.usm.my/ppsg/stats_resources.htm, accessed on December 20, 2009.
22. Pai RK, Wilcox R, Hart J. Molecular gastrointestinal, liver, and pancreatic pathology. In: Tubbs RR, Stole MH, editors. *Cell and tissue based molecular pathology*. Philadelphia, PA: Churchill Livingstone; 2009. p. 269-93.
23. Muller W, Burgart LJ, Krause-Paulus R, Thibodeau SN, Almeida M, Edmonston TB, *et al.* The reliability of immunohistochemistry as a prescreening method for the diagnosis of hereditary nonpolyposis colorectal cancer (HNPCC) – results of an international collaborative study. *Fam Cancer* 2001; 1 : 87-92.

Reprint requests: Dr Gurjeet Kaur, Institute for Research in Molecular Medicine (INFORMM), Universiti Sains Malaysia, Minden, 11800 Penang, Malaysia
e-mail: gurjeet@usm.my