

Basic Study

Cytotoxic CD8+ T cells and tissue resident memory cells in colorectal cancer based on microsatellite instability and BRAF status

James Wei Tatt Toh, Angela L Ferguson, Kevin J Spring, Hema Mahajan, Umaimainthan Palendira

ORCID number: James Wei Tatt Toh 0000-0002-0110-2629; Angela L Ferguson 0000-0001-5974-0423; Kevin J Spring 0000-0003-0601-924X; Hema Mahajan 0000-0001-7200-9328; Umaimainthan Palendira 0000-0002-1113-3306.

Author contributions: Toh JWT and Ferguson A are co-first authors; Toh JWT, Ferguson A and Palendira U conceptualized and designed the study experimental and analytical methods; Toh JWT wrote the manuscript; Palendira U and Spring KJ supervised the project; Toh JWT, Ferguson A, Palendira U, Spring KJ and Mahajan H were involved in critical revisions of the manuscript.

Institutional review board

statement: This study was reviewed and approved by the Executive Ethical Review Panel of the Sydney Local Health District - CRGH Human Research Ethics Committee.

Conflict-of-interest statement: The authors declare no conflicts of interest and have no financial disclosures.

Data sharing statement: Data supporting the results in the paper available on request.

James Wei Tatt Toh, Division of Surgery and Anaesthesia, Department of Colorectal Surgery, Westmead Hospital, Westmead Clinical School, The University of Sydney, Ingham Institute for Applied Medical Research, Westmead 2145, NSW, Australia

Angela L Ferguson, Department of Infectious Diseases and Immunology, School of Medical Sciences, Faculty of Medicine and Health, Human Viral & Cancer Immunology, Centenary Institute, Charles Perkin Centre, The University of Sydney, Sydney 2000, NSW, Australia

Kevin J Spring, Medical Oncology Group, Ingham Institute for Applied Medical Research, Liverpool Hospital, Liverpool Clinical School, University of Western Sydney, South Western Clinical School UNSW, Liverpool 2170, NSW, Australia

Hema Mahajan, Department of Anatomical Pathology, ICPMR, Westmead Hospital, Westmead 2145, NSW, Australia

Umaimainthan Palendira, Department of Immunology and Infectious Diseases, School of Medical Sciences, Faculty of Medicine and Health, The University of Sydney, Sydney 2000, NSW, Australia

Corresponding author: James Wei Tatt Toh, BSc, MBBS, Senior Lecturer, Surgeon, Division of Surgery and Anaesthesia, Department of Colorectal Surgery, Westmead Hospital, Cnr Hawkesbury and Darcy Rd, Westmead 2145, NSW, Australia. james.toh@sydney.edu.au

Abstract

BACKGROUND

Recent studies in non-colorectal malignancy have associated T resident memory (T_{RM}) cells with improved patient survival. It is unknown if T_{RM} plays a role in colorectal cancer (CRC).

AIM

To examine the potential role of T_{RM} cells in providing immunogenicity in CRC stratified by microsatellite instability (MSI) and BRAF status.

METHODS

Patients with known MSI and BRAF mutation status were eligible for inclusion in this study. CRC tumour sections stained with haematoxylin and eosin were

Open-Access: This article is an open-access article that was selected by an in-house editor and fully peer-reviewed by external reviewers. It is distributed in accordance with the Creative Commons Attribution NonCommercial (CC BY-NC 4.0) license, which permits others to distribute, remix, adapt, build upon this work non-commercially, and license their derivative works on different terms, provided the original work is properly cited and the use is non-commercial. See: <http://creativecommons.org/licenses/by-nc/4.0/>

Manuscript source: Invited manuscript

Specialty type: Oncology

Country/Territory of origin: Australia

Peer-review report's scientific quality classification

Grade A (Excellent): 0
Grade B (Very good): 0
Grade C (Good): C
Grade D (Fair): 0
Grade E (Poor): 0

Received: January 14, 2021

Peer-review started: January 14, 2021

First decision: February 15, 2021

Revised: March 14, 2021

Accepted: April 5, 2021

Article in press: April 5, 2021

Published online: April 24, 2021

P-Reviewer: Taira K

S-Editor: Gao CC

L-Editor: A

P-Editor: Wang LL



microscopically reviewed and the images scanned prior to assessment for location of invading edge and core of tumour. Sequential sections were prepared for quantitative multiplex immunohistochemistry (IHC) staining. Opal Multiplex IHC staining was performed with appropriate positive and negative controls and imaged using a standard fluorescent microscope fitted with a spectral scanning camera (Mantra) in conjunction with Mantra snap software. Images were unmixed and annotated in inForm 2.2.0. Statistical analysis was performed using Graphpad Prism Version 7 and Stata Version 15.

RESULTS

Seventy-two patients with known MSI and BRAF status were included in the study. All patients were assessed for MSI by IHC and high resolution capillary electrophoresis testing and 44 of these patients successfully underwent quantitative multiplex IHC staining. Overall, there was a statistically significant increase in CD8+ T_{RM} cells in the MSI (BRAF mutant and wild type) group over the microsatellite stable (MSS) group. There was a statistically significant difference in CD8+ T_{RM} between high level MSI (MSI-H):BRAF mutant [22.57, 95% confidence interval (CI): 14.31-30.84] *vs* MSS [8.031 (95% CI: 4.698-11.36)], *P* = 0.0076 and MSI-H:BRAF wild type [16.18 (95% CI: 10.44-21.93)] *vs* MSS [8.031 (95% CI: 4.698-11.36)], *P* = 0.0279. There was no statistically significant difference in CD8 T cells (both CD8+CD103- and CD8+CD103+T_{RM}) between MSI-H: BRAF mutant and wild type CRC.

CONCLUSION

This study has shown that CD8+ T_{RM} are found in greater abundance in MSI-H CRC, both BRAF mutant and MSI-H:BRAF wild type, when compared with their MSS counterpart. CD8+ T_{RM} may play a role in the immunogenicity in MSI-H CRC (BRAF mutant and BRAF wild type). Further studies should focus on the potential immunogenic qualities of T_{RM} cells and investigate potential immunotherapeutic approaches to improve treatment and survival associated with CRC.

Key Words: Tissue resident memory cells; Resident memory T cells; Colorectal cancer; Microsatellite instability; BRAF; DNA mismatch repair; Immunotherapy; Prognosis

©The Author(s) 2021. Published by Baishideng Publishing Group Inc. All rights reserved.

Core Tip: Prior to this study, whether T resident memory (T_{RM}) cells exist in colorectal cancer (CRC) was poorly understood. This study has identified and characterize T_{RM} cells within human CRC. CD8+ TRM cells are found in greater abundance in both high microsatellite instability (MSI-H) BRAF mutant and MSI-H:BRAF wild type CRC when compared with their microsatellite stable counterpart. CD8+ TRM may play a role in the immunogenicity in both BRAF mutant and BRAF wild type MSI-H CRC. Further studies should focus on the potential immunogenic qualities of TRM cells and investigate potential immunotherapeutic approaches to improve treatment and survival associated with CRC based on TRM.

Citation: Toh JWT, Ferguson AL, Spring KJ, Mahajan H, Palendira U. Cytotoxic CD8+ T cells and tissue resident memory cells in colorectal cancer based on microsatellite instability and BRAF status. *World J Clin Oncol* 2021; 12(4): 238-248

URL: <https://www.wjgnet.com/2218-4333/full/v12/i4/238.htm>

DOI: <https://dx.doi.org/10.5306/wjco.v12.i4.238>

INTRODUCTION

Colorectal cancer (CRC) may be divided into microsatellite stable (MSS) and high microsatellite unstable (MSI-H) CRC. Approximately 15% of CRC are MSI-H and are more likely to be immunogenic with abundant tumour infiltrating lymphocytes (TILs)^[1-3]. On the other hand, MSS CRC are less likely to be immunogenic, with

sparse/limited TILs. Abundance of TILs has been associated improved survival^[4-14] and is widely believed to provide MSI-H CRC with a favourable prognosis^[15,16] despite the higher grade features also associated with MSI-H CRC, such as larger diameter, poorly differentiated, mucinous tumours.

However, while it is widely known that MSI-H CRC is associated with TILs, there is significant debate as to the composition of TILs within CRC and which component of TILs is most important. Various reports have suggested that within TILs, CD8+, CD4+, CD3+, FOXP3+ and CD45RO+ regulatory cells have important roles in immunosurveillance. There has been no consensus in recent studies. Noshio *et al*^[17] reported on the benefits of CD45RO+ cells, Guidoboni *et al*^[18] on cytotoxic CD3+ and CD8+ cells, Salama *et al*^[19] reported that FOXP3+ cells were associated with favourable prognosis respectively. Potentially, the interaction of all of these cells may provide benefit as these cells have different profiles and roles within an intricate orchestrated immune response. It has been believed for decades that T cells are recruited in response to cancer, and constantly recirculate in the blood and lymphatic system. The benefit of these TILs in CRC has been reported and has been subject to recent reviews^[20,21].

More recently a new lineage of T cells has been discovered which is believed to provide immunity to solid tumours^[22-24]. Tissue resident memory (T_{RM}) cells, particularly CD8+ T_{RM} , have been identified in non-colorectal malignancies and its presence has already been shown to be associated with better survival outcomes in lung cancer^[25], ovarian cancer^[26], breast cancer^[27-29] and melanoma^[24,30], particularly CD8+ T_{RM} ^[24-27,31-36]. The difference between CD8+ T_{RM} and conventional cytotoxic CD8+ T cells is that T_{RM} cells, by definition, do not recirculate—rather they remain in peripheral tissue. This is because T_{RM} cells are not just a continuous circulation of T cells, but cells committed to their tissue of residence including tumour tissue, thereby providing immediate and long-term protection against invaders. T_{RM} cells are believed to produce interferon-gamma, granzyme B and perforin^[30].

T_{RM} cells at epithelial surfaces develop from precursor cells through a process that relies on transcription factors and cytokines^[37] and can be identified by the expression of CD103 (and CD69). Both CD103 and CD69 contribute to the retention of these cells within epithelia and prevent these cells from exiting their resident tissue. CD103 is the alpha chain of integrin, which binds to E-Cadherin which is an epithelial adhesion molecule. Furthermore, T_{RM} cells express checkpoint receptors such as programmed death 1 (PD-1), CTLA4 and Tim-3, potential targets for current immunotherapy strategies. If present in CRC, T_{RM} may represent an avenue for improving survival in CRC.

In this study, we have chosen CD103 status to identify T_{RM} cells. CD39, CD69 and CD103 have been associated with T_{RM} ^[36,37], with CD103 reported to strongly correlate with a favourable prognosis in cancer patients^[38]. While there are studies which have suggested the importance of CD4+ T_{RM} cells^[39], the majority of studies have associated improved survival with CD8+ T_{RM} cells^[24-26,31-36] and for this reason the main outcome measure chosen for this study was the abundance of CD8+ T_{RM} in the CRC tumour microenvironment. Secondary outcomes included assessing the presence of CD8+ T_{RM} and cytotoxic CD8+ non- T_{RM} cells. Results of the above outcome measures were pooled by microsatellite instability (MSI) and BRAF status.

MSI status was chosen because it is a biomarker widely considered to influence immunogenicity. BRAF status was also chosen because in CRC it has been shown that presence of BRAFV600E mutation nearly always excludes Lynch syndrome and absence of BRAF mutation (BRAF wild type) may be associated with Lynch syndrome (although 30%-40% of MSI-H:BRAF wild type may be sporadic)^[40]. Thus this study examined the potential role of T_{RM} cells in providing immunogenicity in CRC stratified by MSI and BRAF status, with CRC divided into three groups: MSS, MSI-H:BRAF mutant (representing sporadic MSI-H, usually associated with epigenetic silencing of MLH-1) and MSI-H:BRAF wild type (approximately 60%-70% associated with Lynch syndrome)^[40].

MATERIALS AND METHODS

Patient

Seventy-two patients with known MSI and BRAF status confirmed by immunohistochemistry (IHC) and high resolution capillary electrophoresis were eligible for inclusion in this study. These patients also had detailed clinical, operative, pathological, adjuvant treatment and follow-up data from a cancer database which

was analyzed retrospectively. Institutional board approval was obtained, and patients had provided written consent for the use of their information for research (CH62/62011-136 HREC/11/CRGH206).

Histopathology

Histopathology slides prepared with haematoxylin and eosin were reviewed using an Olympus BX53 microscope to find a representative slide which shows the tumour invading edge and core. These slides were then scanned electronically and the scanned images were reexamined by a pathologist to mark out the invading edge and core. From these blocks, representative slides were recut using a microtome in preparation for quantitative multiplex IHC staining.

Of the 72 original patient tumour specimens prepared on representative slides, 44 formalin fixed paraffin embedded (FFPE) tumour sections were successfully stained with quantitative multiplex IHC staining. All IHC staining was performed on 4- μ m-thick sections and stained using an Opal Multiplex IHC assay kit (PerkinElmer, Waltham, MA, United States) and optimised in-house. Briefly, FFPE tissue sections were deparaffinized and rehydrated prior to antigen retrieval by boiling in basic (10 mmol/L Tris base, 1 mmol/L EDTA, 0.05% Tween 20, pH 9.0) buffer. The sections were then incubated with 3% hydrogen peroxide for 20 min at room temperature before washing and blocking with Perkin Elmer Antibody diluent/Block buffer. Sections were then incubated with a single unconjugated primary antibody for 35 min, washed and then incubated with Opal Polymer HRP (Akoya Biosciences, United States) for 10 min. After washing, sections were incubated with Opal fluorochromes at a 1:100 dilution made up in tyramide signal amplification reagent (PerkinElmer, Waltham, MA, United States) for 10 min. The antigen retrieval step was repeated, and tissue was stained for subsequent antibodies as described above. Finally, sections were stained with DAPI (cell signalling technologies) for 5 min and then mounted using Prolong Diamond (Life Technologies). Slides were stored in the dark until imaging was complete. The following antibodies were used; CD8 (ab4055 clone; Abcam), CD103 [EPR4116(2) clone; Abcam] PD1 (NAT105 clone, Cell Marque). The Mantra imaging platform (PerkinElmer) was used for imaging in combination with Mantra snap software for data acquisition. For all quantitative analysis up to 10 randomly selected regions of interest per section were analyzed. InForm advanced image analysis software (PerkinElmer, MA, United States) (PerkinElmer) was used to process and analyze images, with each tissue manually segmented into tissue regions.

Statistical analysis

Statistical analysis was performed using Graphpad Prism Version 7 and Stata Version 15.

RESULTS

T_{RM} T cells are significantly increased in tumours with defective DNA mismatch repair

Seventy-two patients with known MSI and BRAF status met the eligibility criteria for this study, and of these 44 patient tumour specimens were successfully stained by quantitative multiplex IHC staining (Figure 1). The percentage and densities of total CD8+ T cells, T_{RM} T cells, and non-T_{RM} CD8+ T cells were calculated for MSS, MSI-H:BRAF mutant and MSI-H:BRAF wild type subgroups. An unpaired student *t* test was used to compare the mean % T_{RM}/non-T_{RM} cells/total cells between the three groups for each outcome measure. Where there were significant outliers, the median was used instead of mean, and a Mann Whitney *U* test was performed to compare the median between the three groups. This showed that compared to healthy control all three groups had a statistically greater abundance of CD8+ T cells (Figure 1).

There was a significant difference in the proportion of CD8+ T cells between MSI-H:BRAF mutant and MSS subgroups with 17.24% [95% confidence interval (CI): 9.334-25.15] of nucleated cells in MSS compared to 28.14% (95%CI: 20.38-35.89) in MSI-H:BRAF mutant and 22.82 (95%CI: 16.02-29.62) in MSI-H:BRAF wild type subgroups. On Mann Whitney *U* analysis, there was a statistically significant difference between MSI-H:BRAF mutant and MSS subgroups (*P* = 0.0417). Although there was a greater percentage of CD8+ T cells in the MSI-H:BRAF wild type subgroup when compared to MSS, this did not reach statistical significance [22.82 (95%CI: 16.02-29.62) *vs* 17% (95%CI: 9.334-25.15), *P* = 0.2841].

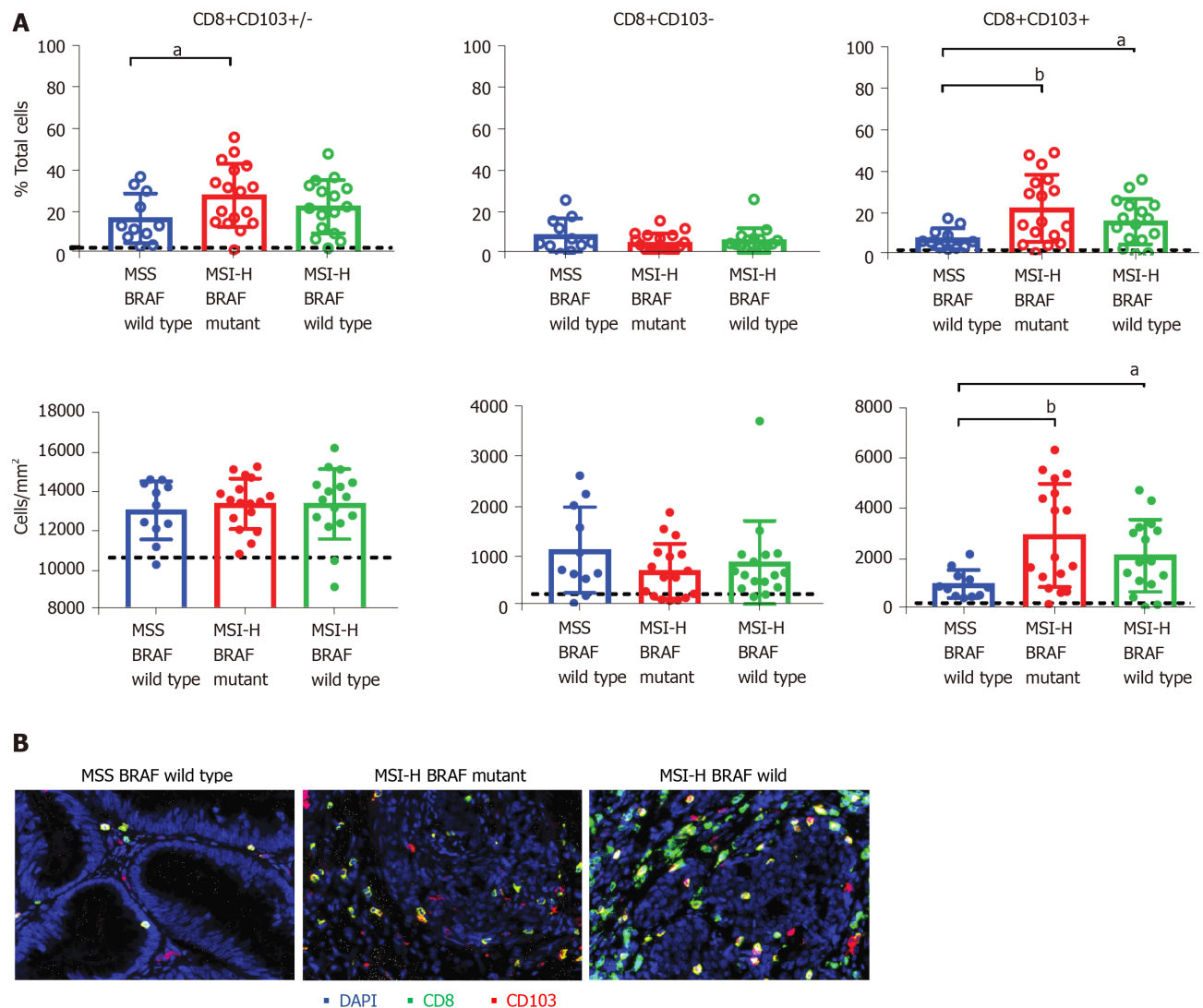


Figure 1 Tissue resident memory T cells are significantly increased in microsatellite instability high tumours. A: Quantitative immunohistochemistry staining of tumour specimen show the proportion (top panels) and densities (bottom panels) of total CD8+ T cells (left panels), CD103-CD8+ (non- T_{RM}) T cells (middle panels) and CD103+CD8+ resident memory (T_{RM}) T cells (right panels) in CRC tumours with microsatellite stable BRAF wildtype and microsatellite instability (MSI) high BRAF mutants and MSI high BRAF wildtype groups. Figure shows the mean and SD of $n = 11-17$ samples and the statistical differences were calculated using unpaired and non-parametric Mann-Whitney test ($^aP < 0.05$; $^bP < 0.001$). Black line shows the levels determined from normal healthy colorectal tissues ($n = 1$); B: Representative tissue staining shows the staining for CD8 (green) and CD103 (red) and DAPI (blue) in the three groups of patients. MSS: Microsatellite stable; MSI-H: High microsatellite instability.

Importantly, there were significant differences in the proportions of CD8+ T_{RM} cells between the three subgroups of CRC. Compared to MSS, the MSI-H:BRAF mutant subgroup had a significantly higher proportion of CD8+ T_{RM} cells (Figure 1) with 22.5% (95% CI: 14.31-30.84) in MSI-H:BRAF mutant subgroup and 8.0% in MSS subgroup (95% CI: 4.698-11.36, $P = 0.0076$). Similarly, the MSI-H:BRAF wild type subgroup had significantly higher CD8+ T_{RM} (16.18%, 95% CI: 10.44-21.93) when compared to MSS (8%, 95% CI: 4.698-11.36 and $P = 0.0279$). The difference in abundance of T_{RM} between MSI-H: BRAF mutant and MSI-H:BRAF wild type subgroups was not significant (Figure 1). There was no statistically significant difference in non- T_{RM} CD8+ cells between the three subgroups.

PD-1 expression on CD8+ T cells is not impacted by MSI status

We next sought to determine whether the expression of checkpoint receptor, PD-1 was impacted by MSI status or BRAF mutation. We enumerated the proportion of T cells expressing PD-1 in all three subgroups. PD-1 expression was present in both T_{RM} T cells and non- T_{RM} T cell populations, although the proportion of non- T_{RM} T cells expressing PD-1 was slightly higher than that of the T_{RM} T cell population (Figure 2). While there was a trend to increased PD-1+ expression in the T_{RM} T cell population in MSI-H:BRAF wild type compared to MSI-H:BRAF mutant and MSS subgroups, there

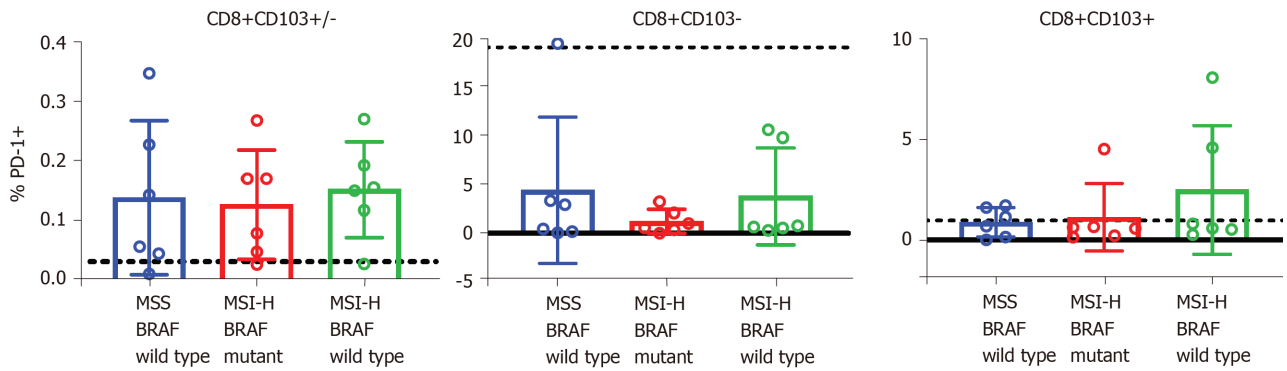


Figure 2 Programmed cell death protein-1 expression on CD8+ T cells is not impacted by microsatellite instability or BRAF status. Quantitative immunohistochemistry staining was used to determine the expression of programmed cell death protein-1 (PD-1) on CD8+ T cell populations. Figure shows the proportion of total CD8+ T cells (CD8+CD103+/-) (left panel), CD103-CD8+ (non- T_{RM}) T cells (middle panel) and CD103+CD8+ T_{RM} cells (right panel) expressing PD-1. Figure shows the mean and SD for 5-6 samples/group. PD-1: Programmed death 1; MSS: Microsatellite stable; MSI-H: High microsatellite instability.

was, however, no statistically significant differences in the proportion of T cells expressing PD-1 between the three groups.

DISCUSSION

Characteristics of TILs within CRC have been poorly defined to date, and there is a paucity of information on T_{RM} T cells in CRC. In humans, within the circulation, two types of memory T cells exist – central memory (TCM) and effector memory (TEM). For decades, it was thought that T lymphocyte populations in peripheral tissues including TILs were largely maintained by the continuous circulation of these memory T cells as well as other circulatory cells. Recent studies have challenged this concept and provided evidence for the existence of another subset of CD8+ T cells – tissue- T_{RM} T cells. These cells are permanently resident (*i.e.*, do not recirculate) in both lymphoid and non-lymphoid tissues and represent a distinct subset to circulatory TEM or TCM.

Prior to this study the existence of T_{RM} cells in CRC was poorly understood and the aim of this study was to identify and characterize T_{RM} cells within human CRC. If present, T_{RM} cells may be important in the protection against recurrence, dissemination and metastasis. A favourable prognosis associated with the presence of T_{RM} cells has already been reported in studies of high-grade serous ovarian cancer patients, non-small cell lung carcinoma patients and breast cancer^[41]. In lung cancer, although only a small proportion of CD8+ T cells were reported to be T_{RM} , the majority of T_{RM} cells were tumour-reactive. Studies in melanoma have also shown an association between T_{RM} and favourable prognosis^[30,42].

This present study showed that T_{RM} cells exist in MSS, MSI-H:BRAF mutant and MSI-H:BRAF wild type CRC. However, they are in greater abundance in MSI-H than MSS CRC. This is supported by the findings of a recent study by de Vries *et al*^[21] on 35 CRC tissues which demonstrated that CD103+ T_{RM} cells were most abundant in MSI-H CRC. In that study 13 MSI-H CRC were included and BRAF status was not considered. Our study had 42 MSI-H CRC patients which were all subject to immunoscore, of which 33 went on to have multiplex IHC staining to look for presence of T_{RM} cells and of these 17 were BRAF mutant and 16 were BRAF wild type. Of the 30 MSS CRC patients, 11 went on to have multiplex IHC staining to look for presence of T_{RM} cells. Our study showed that both MSI-H:BRAF mutant and BRAF wild type subgroups had significantly greater abundance of T_{RM} cells when compared to the MSS subgroup. There was no statistically significant difference between MSI-H:BRAF mutant and BRAF wild type subgroups.

There was a trend to increased PD-1+ in the T_{RM} T cell population in MSI-H:BRAF wild type compared to MSI-H:BRAF mutant and MSS subgroups, but this was not statistically significant. This is an important finding as in advanced CRC this T cell subpopulation amongst other PD-1+ immune cells may be exhausted by PD-1/PD-1 ligand binding, a mechanism of escaping immunosurveillance by tumours. Reactivation of exhausted PD-1+ T_{RM} cells may provide therapeutic opportunities that may be exploited in MSI-H:BRAF wild type CRC. PD-1 expression has been reported to be more prominent in cells with a T_{RM} phenotype^[25,43], and in the case of CRC it may

be their numbers that impacts the outcome.

The potential ways which CD8+ T_{RM} cells can be harnessed to improve the success of immunotherapeutic targets has already been the focus of several general reviews^[38,44-46] as well as in breast cancer^[31] and melanoma^[47,48], with Edwards *et al*^[42] reporting that CD8+ T_{RM} cells being prognostic in metastatic melanoma and potentially initiating response to immunotherapy with anti-PD-1. Therefore, the role of T_{RM} cells could have important implications for checkpoint-inhibition therapy in CRC^[49].

The mechanisms by which T_{RM} cells confer immunity remains unclear. Recent studies by Park *et al*^[24] have demonstrated that depletion of T_{RM} cells in melanoma triggered tumour outgrowth of mice with occult melanoma, demonstrating that T_{RM} cells have an important role in cancer surveillance and equilibrium and may keep cancer cells dormant^[50]. This effect may be long term as T_{RM} cell populations are able to persist in barrier tissues for a prolonged period of time^[51]. Menares *et al*^[52] suggest that the mechanism by which T_{RM} cells provide immunity is *via* cross-talk with dendritic cells to trigger the spread of cytotoxic CD8+ T cells in response to tumour.

Limitations

The use of a single marker (CD103) to define T_{RM} cells is a limitation. However, many studies have consistently shown that CD103+CD8+ T cells have the hallmark of T_{RM} T cells^[24,53]. Further, the study sample size was small ($n = 72$) and we were only able to successfully perform quantitative multiplex IHC staining and imaging on 44 samples. Nonetheless, this is to date the largest study on T_{RM} cells in CRC.

CONCLUSION

This study has shown that in CRC a significant fraction of TILs is made up of T_{RM} cells and are found in greater abundance in MSI-H: BRAF mutant and MSI-H: BRAF wild type compared with MSS CRC tumours. Acknowledging that there is a complex interaction of factors at play in influencing the prognosis in CRC, the abundance of T_{RM} cells may contribute to the favourable prognosis observed in MSI-H CRC when compared to MSS^[15,16]. This is because MSS CRC has significantly less T_{RM} cells when compared to MSI-H CRC. The abundance of T_{RM} cells in MSI-H CRC may also explain the reduced likelihood of metastases in patients with MSI-H CRC^[54] and also the difference in response to immunotherapy between MSI-H CRC and MSS CRC^[20]. It is important to understand that while T_{RM} cells can provide immunity in solid organ tumours, the immunity conferred is by no means absolute and cancers still arise and continue to disseminate despite the presence of T_{RM} cells. Further studies should focus on the potential immunogenic qualities of T_{RM} cells and investigate potential immunotherapeutic approaches to improve treatment and survival associated with CRC.

ARTICLE HIGHLIGHTS

Research background

The presence of resident memory T (T_{RM}) cells has already been reported in studies of high-grade serous ovarian cancer patients, non-small cell lung carcinoma patients and breast cancer, but there has been limited evidence on T_{RM} cells in the scientific literature in colorectal cancer (CRC). This is a landmark study on T_{RM} cells in CRC.

Research motivation

With T_{RM} cells showing promise in several solid organ tumour studies, the premise of this study was to evaluate if T_{RM} cells are present in CRC and thus potentially be a target for immunotherapy/novel target therapy in the future.

Research objectives

The objective of this study was to examine the potential role of T_{RM} cells in providing immunogenicity in CRC stratified by microsatellite instability (MSI) and BRAF status.

Research methods

Formalin fixed paraffin embedded tumour sections were successfully stained using quantitative multiplex IHC staining. All IHC staining was performed using an Opal Multiplex immunohistochemistry (IHC) assay kit (PerkinElmer, Waltham, MA, United

States) and optimised in-house.

Research results

This study has shown that CD8+ T_{RM} are found in greater abundance in both high level MSI (MSI-H):BRAF mutant and MSI-H:BRAF wild type CRC when compared with their microsatellite stable (MSS) counterpart. CD8+ T_{RM} may play a role in the immuno-genicity in both BRAF mutant and BRAF wild type MSI-H CRC. The abundance of T_{RM} cells may contribute to the favourable prognosis observed in MSI-H CRC when compared to MSS CRC.

Research conclusions

T_{RM} cells are found in greater abundance and contributes to the immunogenicity of MSI-H CRCs.

Research perspectives

T_{RM} cells may be a target for immunotherapy/novel target therapy in MSI-H CRCs, and future research should focus on the potential value of T_{RM} cells, as well as therapeutic agents that may stimulate T_{RM} activity or adoptive cell transfer aimed at harvesting and utilizing the patients' own immune cells such as specially altered T-cells to precisely and specifically target cancer cells.

ACKNOWLEDGEMENTS

The authors thank Chapuis P who maintains the Colorectal Cancer Resection Database and advises on entry of clinical and follow up data as to occurrence, date and cause of death. The authors thank Cancer Council NSW (RG18-08) and Bio-Connect from the University of Sydney.

REFERENCES

- 1 Le DT, Uram JN, Wang H, Bartlett BR, Kemberling H, Eyring AD, Skora AD, Luber BS, Azad NS, Laheru D, Biedrzycki B, Donehower RC, Zaheer A, Fisher GA, Crocenzi TS, Lee JJ, Duffy SM, Goldberg RM, de la Chapelle A, Koshiji M, Bhajee F, Huebner T, Hruban RH, Wood LD, Cuka N, Pardoll DM, Papadopoulos N, Kinzler KW, Zhou S, Cornish TC, Taube JM, Anders RA, Eshleman JR, Vogelstein B, Diaz LA Jr. PD-1 Blockade in Tumors with Mismatch-Repair Deficiency. *N Engl J Med* 2015; **372**: 2509-2520 [PMID: 26028255 DOI: 10.1056/NEJMoa1500596]
- 2 Gatalica Z, Snyder C, Maney T, Ghazalpour A, Holterman DA, Xiao N, Overberg P, Rose I, Basu GD, Vranic S, Lynch HT, Von Hoff DD, Hamid O. Programmed cell death 1 (PD-1) and its ligand (PD-L1) in common cancers and their correlation with molecular cancer type. *Cancer Epidemiol Biomarkers Prev* 2014; **23**: 2965-2970 [PMID: 25392179 DOI: 10.1158/1055-9965.EPI-14-0654]
- 3 Topalian SL, Hodi FS, Brahmer JR, Gettinger SN, Smith DC, McDermott DF, Powderly JD, Carvajal RD, Sosman JA, Atkins MB, Leming PD, Spigel DR, Antonia SJ, Horn L, Drake CG, Pardoll DM, Chen L, Sharfman WH, Anders RA, Taube JM, McMiller TL, Xu H, Korman AJ, Jure-Kunkel M, Agrawal S, McDonald D, Kollia GD, Gupta A, Wigginton JM, Sznol M. Safety, activity, and immune correlates of anti-PD-1 antibody in cancer. *N Engl J Med* 2012; **366**: 2443-2454 [PMID: 22658127 DOI: 10.1056/NEJMoa1200690]
- 4 Pagès F, Berger A, Camus M, Sanchez-Cabo F, Costes A, Molitor R, Mlecnik B, Kirilovsky A, Nilsson M, Damotte D, Meatchi T, Bruneval P, Cugnenc PH, Trajanoski Z, Fridman WH, Galon J. Effector memory T cells, early metastasis, and survival in colorectal cancer. *N Engl J Med* 2005; **353**: 2654-2666 [PMID: 16371631 DOI: 10.1056/NEJMoa051424]
- 5 Mlecnik B, Tosolini M, Kirilovsky A, Berger A, Bindea G, Meatchi T, Bruneval P, Trajanoski Z, Fridman WH, Pagès F, Galon J. Histopathologic-based prognostic factors of colorectal cancers are associated with the state of the local immune reaction. *J Clin Oncol* 2011; **29**: 610-618 [PMID: 21245428 DOI: 10.1200/JCO.2010.30.5425]
- 6 Ling A, Edin S, Wikberg ML, Öberg Å, Palmqvist R. The intratumoural subsite and relation of CD8(+) and FOXP3(+) T lymphocytes in colorectal cancer provide important prognostic clues. *Br J Cancer* 2014; **110**: 2551-2559 [PMID: 24675384 DOI: 10.1038/bjc.2014.161]
- 7 Michael-Robinson JM, Biemer-Hüttmann A, Purdie DM, Walsh MD, Simms LA, Biden KG, Young JP, Leggett BA, Jass JR, Radford-Smith GL. Tumour infiltrating lymphocytes and apoptosis are independent features in colorectal cancer stratified according to microsatellite instability status. *Gut* 2001; **48**: 360-366 [PMID: 11171826 DOI: 10.1136/gut.48.3.360]
- 8 Svennevig JL, Lunde OC, Holter J, Bjørgevik D. Lymphoid infiltration and prognosis in colorectal carcinoma. *Br J Cancer* 1984; **49**: 375-377 [PMID: 6704315 DOI: 10.1038/bjc.1984.60]

- 9 **Jass JR.** Lymphocytic infiltration and survival in rectal cancer. *J Clin Pathol* 1986; **39**: 585-589 [PMID: [3722412](#) DOI: [10.1136/jcp.39.6.585](#)]
- 10 **Shunyakov L, Ryan CK, Sahasrabudhe DM, Khorana AA.** The influence of host response on colorectal cancer prognosis. *Clin Colorectal Cancer* 2004; **4**: 38-45 [PMID: [15207019](#) DOI: [10.3816/cc.2004.n.008](#)]
- 11 **Dahlin AM, Henriksson ML, Van Guelpen B, Stenling R, Oberg A, Rutegård J, Palmqvist R.** Colorectal cancer prognosis depends on T-cell infiltration and molecular characteristics of the tumor. *Mod Pathol* 2011; **24**: 671-682 [PMID: [21240258](#) DOI: [10.1038/modpathol.2010.234](#)]
- 12 **Chiba T, Ohtani H, Mizoi T, Naito Y, Sato E, Nagura H, Ohuchi A, Ohuchi K, Shiiba K, Kurokawa Y, Satomi S.** Intraepithelial CD8+ T-cell-count becomes a prognostic factor after a longer follow-up period in human colorectal carcinoma: possible association with suppression of micrometastasis. *Br J Cancer* 2004; **91**: 1711-1717 [PMID: [15494715](#) DOI: [10.1038/sj.bjc.6602201](#)]
- 13 **Zlobec I, Lugli A, Baker K, Roth S, Minoo P, Hayashi S, Terracciano L, Jass JR.** Role of APAF-1, E-cadherin and peritumoral lymphocytic infiltration in tumour budding in colorectal cancer. *J Pathol* 2007; **212**: 260-268 [PMID: [17516584](#) DOI: [10.1002/path.2164](#)]
- 14 **Prall F, Dührkop T, Weirich V, Ostwald C, Lenz P, Nizze H, Barten M.** Prognostic role of CD8+ tumor-infiltrating lymphocytes in stage III colorectal cancer with and without microsatellite instability. *Hum Pathol* 2004; **35**: 808-816 [PMID: [15257543](#) DOI: [10.1016/j.humpath.2004.01.022](#)]
- 15 **Popat S, Hubner R, Houlston RS.** Systematic review of microsatellite instability and colorectal cancer prognosis. *J Clin Oncol* 2005; **23**: 609-618 [PMID: [15659508](#) DOI: [10.1200/jco.2005.01.086](#)]
- 16 **Guastadisegni C, Colafranceschi M, Ottini L, Dogliotti E.** Microsatellite instability as a marker of prognosis and response to therapy: a meta-analysis of colorectal cancer survival data. *Eur J Cancer* 2010; **46**: 2788-2798 [PMID: [20627535](#) DOI: [10.1016/j.ejca.2010.05.009](#)]
- 17 **Nosho K, Baba Y, Tanaka N, Shima K, Hayashi M, Meyerhardt JA, Giovannucci E, Dranoff G, Fuchs CS, Ogino S.** Tumour-infiltrating T-cell subsets, molecular changes in colorectal cancer, and prognosis: cohort study and literature review. *J Pathol* 2010; **222**: 350-366 [PMID: [20927778](#) DOI: [10.1002/path.2774](#)]
- 18 **Guidoboni M, Gafà R, Viel A, Doglioni C, Russo A, Santini A, Del Tin L, Macri E, Lanza G, Boiocchi M, Dolcetti R.** Microsatellite instability and high content of activated cytotoxic lymphocytes identify colon cancer patients with a favorable prognosis. *Am J Pathol* 2001; **159**: 297-304 [PMID: [11438476](#) DOI: [10.1016/s0002-9440\(10\)61695-1](#)]
- 19 **Salama P, Phillips M, Griew F, Morris M, Zeps N, Joseph D, Platell C, Iacopetta B.** Tumor-infiltrating FOXP3+ T regulatory cells show strong prognostic significance in colorectal cancer. *J Clin Oncol* 2009; **27**: 186-192 [PMID: [19064967](#) DOI: [10.1200/JCO.2008.18.7229](#)]
- 20 **Toh JWT, de Souza P, Lim SH, Singh P, Chua W, Ng W, Spring KJ.** The Potential Value of Immunotherapy in Colorectal Cancers: Review of the Evidence for Programmed Death-1 Inhibitor Therapy. *Clin Colorectal Cancer* 2016; **15**: 285-291 [PMID: [27553906](#) DOI: [10.1016/j.clcc.2016.07.007](#)]
- 21 **de Vries NL, van Unen V, Ijsselstein ME, Abdelaal T, van der Breggen R, Farina Sarasqueta A, Mahfouz A, Peeters KCMJ, Höllt T, Lelieveldt BPF, Koning F, de Miranda NFCC.** High-dimensional cytometric analysis of colorectal cancer reveals novel mediators of antitumour immunity. *Gut* 2020; **69**: 691-703 [PMID: [31270164](#) DOI: [10.1136/gutjnl-2019-318672](#)]
- 22 **Dadi S, Li MO.** Tissue-resident lymphocytes: sentinel of the transformed tissue. *J Immunother Cancer* 2017; **5**: 41 [PMID: [28515941](#) DOI: [10.1186/s40425-017-0244-3](#)]
- 23 **Dadi S, Chhangawala S, Whitlock BM, Franklin RA, Luo CT, Oh SA, Toure A, Pritykin Y, Huse M, Leslie CS, Li MO.** Cancer Immunosurveillance by Tissue-Resident Innate Lymphoid Cells and Innate-like T Cells. *Cell* 2016; **164**: 365-377 [PMID: [26806130](#) DOI: [10.1016/j.cell.2016.01.002](#)]
- 24 **Park SL, Buzzai A, Rautela J, Hor JL, Hochheiser K, Effern M, McBain N, Wagner T, Edwards J, McConville R, Wilmott JS, Scolyer RA, Tüting T, Palendira U, Gyorki D, Mueller SN, Huntington ND, Bedoui S, Hölzel M, Mackay LK, Waithman J, Gebhardt T.** Tissue-resident memory CD8⁺ T cells promote melanoma-immune equilibrium in skin. *Nature* 2019; **565**: 366-371 [PMID: [30598548](#) DOI: [10.1038/s41586-018-0812-9](#)]
- 25 **Djenidi F, Adam J, Goubar A, Durgeau A, Meurice G, de Montpréville V, Validire P, Besse B, Mami-Chouaib F.** CD8+CD103+ tumor-infiltrating lymphocytes are tumor-specific tissue-resident memory T cells and a prognostic factor for survival in lung cancer patients. *J Immunol* 2015; **194**: 3475-3486 [PMID: [25725111](#) DOI: [10.4049/jimmunol.1402711](#)]
- 26 **Webb JR, Milne K, Watson P, Deleeuw RJ, Nelson BH.** Tumor-infiltrating lymphocytes expressing the tissue resident memory marker CD103 are associated with increased survival in high-grade serous ovarian cancer. *Clin Cancer Res* 2014; **20**: 434-444 [PMID: [24190978](#) DOI: [10.1158/1078-0432.CCR-13-1877](#)]
- 27 **Egelston CA, Avalos C, Tu TY, Rosario A, Wang R, Solomon S, Srinivasan G, Nelson MS, Huang Y, Lim MH, Simons DL, He TF, Yim JH, Kruper L, Mortimer J, Yost S, Guo W, Ruel C, Frankel PH, Yuan Y, Lee PP.** Resident memory CD8+ T cells within cancer islands mediate survival in breast cancer patients. *JCI Insight* 2019; **4** [PMID: [31465302](#) DOI: [10.1172/jci.insight.130000](#)]
- 28 **Schalck A, Bernatchez C, Navin N.** Resident Breast T Cells: The Troops Are Already There. *Trends Mol Med* 2018; **24**: 821-822 [PMID: [30077643](#) DOI: [10.1016/j.molmed.2018.07.006](#)]
- 29 **Savas P, Virasamy B, Ye C, Salim A, Mintoff CP, Caramia R, Byrne DJ, Teo ZL, Dushyanthen S, Byrne A, Wein L, Luen SJ, Poliness C, Nightingale SS, Skandarajah AS, Gyorki DE, Thornton CM, Beavis PA, Fox SB; Kathleen Cuninghame Foundation Consortium for Research into**

- Familial Breast Cancer (kConFab), Darcy PK, Speed TP, Mackay LK, Neeson PJ, Loi S. Single-cell profiling of breast cancer T cells reveals a tissue-resident memory subset associated with improved prognosis. *Nat Med* 2018; **24**: 986-993 [PMID: [29942092](#) DOI: [10.1038/s41591-018-0078-7](#)]
- 30 **Khalil S**, Bardawil T, Kurban M, Abbas O. Tissue-resident memory T cells in the skin. *Inflamm Res* 2020; **69**: 245-254 [PMID: [31989191](#) DOI: [10.1007/s00011-020-01320-6](#)]
- 31 **Byrne A**, Savas P, Sant S, Li R, Virassamy B, Luen SJ, Beavis PA, Mackay LK, Neeson PJ, Loi S. Tissue-resident memory T cells in breast cancer control and immunotherapy responses. *Nat Rev Clin Oncol* 2020; **17**: 341-348 [PMID: [32112054](#) DOI: [10.1038/s41571-020-0333-y](#)]
- 32 **Yang R**, Cheng S, Luo N, Gao R, Yu K, Kang B, Wang L, Zhang Q, Fang Q, Zhang L, Li C, He A, Hu X, Peng J, Ren X, Zhang Z. Distinct epigenetic features of tumor-reactive CD8⁺ T cells in colorectal cancer patients revealed by genome-wide DNA methylation analysis. *Genome Biol* 2019; **21**: 2 [PMID: [31892342](#) DOI: [10.1186/s13059-019-1921-y](#)]
- 33 **Hochheiser K**, Aw Yeang HX, Wagner T, Tutuka C, Behren A, Waithman J, Angel C, Neeson PJ, Gebhardt T, Gyorki DE. Accumulation of CD103⁺ CD8⁺ T cells in a cutaneous melanoma micrometastasis. *Clin Transl Immunology* 2019; **8**: e1100 [PMID: [31885869](#) DOI: [10.1002/cti2.1100](#)]
- 34 **Wu X**, Wu P, Shen Y, Jiang X, Xu F. CD8⁺ Resident Memory T Cells and Viral Infection. *Front Immunol* 2018; **9**: 2093 [PMID: [30283442](#) DOI: [10.3389/fimmu.2018.02093](#)]
- 35 **Molodtsov A**, Turk MJ. Tissue Resident CD8 Memory T Cell Responses in Cancer and Autoimmunity. *Front Immunol* 2018; **9**: 2810 [PMID: [30555481](#) DOI: [10.3389/fimmu.2018.02810](#)]
- 36 **Corgnac S**, Boutet M, Kfoury M, Naltet C, Mami-Chouaib F. The Emerging Role of CD8⁺ Tissue Resident Memory T (T_{RM}) Cells in Antitumor Immunity: A Unique Functional Contribution of the CD103 Integrin. *Front Immunol* 2018; **9**: 1904 [PMID: [30158938](#) DOI: [10.3389/fimmu.2018.01904](#)]
- 37 **Duhen T**, Duhen R, Montler R, Moses J, Moudgil T, de Miranda NF, Goodall CP, Blair TC, Fox BA, McDermott JE, Chang SC, Grunkemeier G, Leidner R, Bell RB, Weinberg AD. Co-expression of CD39 and CD103 identifies tumor-reactive CD8 T cells in human solid tumors. *Nat Commun* 2018; **9**: 2724 [PMID: [30006565](#) DOI: [10.1038/s41467-018-05072-0](#)]
- 38 **Dumauthioz N**, Labiano S, Romero P. Tumor Resident Memory T Cells: New Players in Immune Surveillance and Therapy. *Front Immunol* 2018; **9**: 2076 [PMID: [30258445](#) DOI: [10.3389/fimmu.2018.02076](#)]
- 39 **Nguyen QP**, Deng TZ, Witherden DA, Goldrath AW. Origins of CD4⁺ circulating and tissue-resident memory T-cells. *Immunology* 2019; **157**: 3-12 [PMID: [30897205](#) DOI: [10.1111/imm.13059](#)]
- 40 **Newton K**, Jorgensen NM, Wallace AJ, Buchanan DD, Lalloo F, McMahon RF, Hill J, Evans DG. Tumour MLH1 promoter region methylation testing is an effective prescreen for Lynch Syndrome (HNPCC). *J Med Genet* 2014; **51**: 789-796 [PMID: [25280751](#) DOI: [10.1136/jmedgenet-2014-102552](#)]
- 41 **Guo L**, Cao C, Goswami S, Huang X, Ma L, Guo Y, Yang B, Li T, Chi Y, Zhang X, Wu J. Tumoral PD-1hiCD8⁺ T cells are partially exhausted and predict favorable outcome in triple-negative breast cancer. *Clin Sci (Lond)* 2020; **134**: 711-726 [PMID: [32202617](#) DOI: [10.1042/CS20191261](#)]
- 42 **Edwards J**, Wilmott JS, Madore J, Gide TN, Quek C, Tasker A, Ferguson A, Chen J, Hewavisenti R, Hersey P, Gebhardt T, Weninger W, Britton WJ, Saw RPM, Thompson JF, Menzies AM, Long GV, Scolyer RA, Palendira U. CD103⁺ Tumor-Resident CD8⁺ T Cells Are Associated with Improved Survival in Immunotherapy-Naïve Melanoma Patients and Expand Significantly During Anti-PD-1 Treatment. *Clin Cancer Res* 2018; **24**: 3036-3045 [PMID: [29599411](#) DOI: [10.1158/1078-0432.CCR-17-2257](#)]
- 43 **Boddupalli CS**, Bar N, Kadaveru K, Krauthammer M, Pornputtapong N, Mai Z, Ariyan S, Narayan D, Kluger H, Deng Y, Verma R, Das R, Bacchiocchi A, Halaban R, Sznol M, Dhodapkar MV, Dhodapkar KM. Interlesional diversity of T cell receptors in melanoma with immune checkpoints enriched in tissue-resident memory T cells. *JCI Insight* 2016; **1**: e88955 [PMID: [28018970](#) DOI: [10.1172/jci.insight.88955](#)]
- 44 **Steinbach K**, Vincenti I, Merkler D. Resident-Memory T Cells in Tissue-Restricted Immune Responses: For Better or Worse? *Front Immunol* 2018; **9**: 2827 [PMID: [30555489](#) DOI: [10.3389/fimmu.2018.02827](#)]
- 45 **Smazynski J**, Webb JR. Resident Memory-Like Tumor-Infiltrating Lymphocytes (TIL_{RM}): Latest Players in the Immuno-Oncology Repertoire. *Front Immunol* 2018; **9**: 1741 [PMID: [30093907](#) DOI: [10.3389/fimmu.2018.01741](#)]
- 46 **Blanc C**, Hans S, Tran T, Granier C, Saldman A, Anson M, Oudard S, Tartour E. Targeting Resident Memory T Cells for Cancer Immunotherapy. *Front Immunol* 2018; **9**: 1722 [PMID: [30100906](#) DOI: [10.3389/fimmu.2018.01722](#)]
- 47 **Willemsen M**, Linkutė R, Luiten RM, Matos TR. Skin-resident memory T cells as a potential new therapeutic target in vitiligo and melanoma. *Pigment Cell Melanoma Res* 2019; **32**: 612-622 [PMID: [31230406](#) DOI: [10.1111/pcmr.12803](#)]
- 48 **Park SL**, Mackay LK, Waithman J, Gebhardt T. Tissue-resident memory T cells orchestrate tumour-immune equilibrium. *Cell Stress* 2019; **3**: 162-164 [PMID: [31225511](#) DOI: [10.15698/cst2019.05.187](#)]
- 49 **Amsen D**, van Gisbergen KPJM, Hombrink P, van Lier RAW. Tissue-resident memory T cells at the center of immunity to solid tumors. *Nat Immunol* 2018; **19**: 538-546 [PMID: [29777219](#) DOI: [10.1038/s41590-018-0114-2](#)]
- 50 **Gabriel SS**, Kallies A. Tissue-resident memory T cells keep cancer dormant. *Cell Res* 2019; **29**: 341-342 [PMID: [30874611](#) DOI: [10.1038/s41422-019-0156-5](#)]
- 51 **Takamura S**. Niches for the Long-Term Maintenance of Tissue-Resident Memory T Cells. *Front*

- Immunol* 2018; **9**: 1214 [PMID: 29904388 DOI: 10.3389/fimmu.2018.01214]
- 52 **Menares E**, Gálvez-Cancino F, Cáceres-Morgado P, Ghorani E, López E, Díaz X, Saavedra-Almarza J, Figueroa DA, Roa E, Quezada SA, Lladser A. Tissue-resident memory CD8⁺ T cells amplify anti-tumor immunity by triggering antigen spreading through dendritic cells. *Nat Commun* 2019; **10**: 4401 [PMID: 31562311 DOI: 10.1038/s41467-019-12319-x]
 - 53 **Woon HG**, Braun A, Li J, Smith C, Edwards J, Sierro F, Feng CG, Khanna R, Elliot M, Bell A, Hislop AD, Tangye SG, Rickinson AB, Gebhardt T, Britton WJ, Palendira U. Compartmentalization of Total and Virus-Specific Tissue-Resident Memory CD8⁺ T Cells in Human Lymphoid Organs. *PLoS Pathog* 2016; **12**: e1005799 [PMID: 27540722 DOI: 10.1371/journal.ppat.1005799]
 - 54 **Malesci A**, Laghi L, Bianchi P, Delconte G, Randolph A, Torri V, Carnaghi C, Doci R, Rosati R, Montorsi M, Roncalli M, Gennari L, Santoro A. Reduced likelihood of metastases in patients with microsatellite-unstable colorectal cancer. *Clin Cancer Res* 2007; **13**: 3831-3839 [PMID: 17606714 DOI: 10.1158/1078-0432.ccr-07-0366]



Published by **Baishideng Publishing Group Inc**
7041 Koll Center Parkway, Suite 160, Pleasanton, CA 94566, USA

Telephone: +1-925-3991568

E-mail: bpgoffice@wjgnet.com

Help Desk: <https://www.f6publishing.com/helpdesk>

<https://www.wjgnet.com>

