

## Inflammation and Infection

## Filariasis Orchitis—Differential for Acute Scrotum Pathology



Karmon M. Janssen<sup>a,\*</sup>, Cornelia J. Willis<sup>a</sup>, Mark Anderson<sup>a</sup>, Mary S. Gelnett<sup>b</sup>, Emily L. Wickersham<sup>b</sup>, Timothy C. Brand<sup>a</sup>

<sup>a</sup>Madigan Army Medical Center, Urology Department, Tacoma, WA 98431, USA

<sup>b</sup>Madigan Army Medical Center, Pathology Department, Tacoma, WA 98431, USA

## ARTICLE INFO

## Article history:

Received 26 March 2017

Accepted 11 April 2017

## Keywords:

Testicular mass

Granulomatous orchitis

Infection

Filariasis

## ABSTRACT

Granulomatous Orchitis secondary to lymphatic filariasis is a rare diagnosis within the United States. We report a case of a 22yo Male from Sri Lanka, with a new onset scrotal swelling and palpable right testicular mass. Ultrasound identified a 1 cm right testicular mass with signs of tunica albuginea invasion. A right inguinal radical orchiectomy was performed and pathology showed Filarial orchitis. This report describes the detailed history, physical exam, and diagnostic workup and treatment options for a rare entity for acute scrotal pathology.

Published by Elsevier Inc. This is an open access article under the CC BY-NC-ND license (<http://creativecommons.org/licenses/by-nc-nd/4.0/>).

## Introduction

Filariasis affects over 120 M people worldwide with greatest prevalence in Asia, Africa and the Western Pacific and caused by the parasitic nematode, *Wuchereria bancrofti*. It spreads from person to person through mosquito bites with no intermediate host.<sup>1</sup> Once infected, a person can harbor the parasitic roundworms for years while remaining asymptomatic. Typically, the roundworms travel to lymph vessels, mate, then the female produces millions of offspring called microfilariae, into the blood.<sup>1</sup> The adult worms typically survive for 5–7 years. This infection most commonly results in lymphedema and has rarely contributed to testicular infections.

There is a paucity of data regarding testicular filariasis, specifically granulomatous filarial orchitis.<sup>2</sup> The intent of this case report is to expand clinicians' differential diagnosis of testicular pain and swelling based on a patient's travel history and increase awareness of a rare etiology of granulomatous orchitis.

## Case report

We address a 22-year-old U.S. Army active duty male who presented with new onset scrotal swelling and a palpable right

testicular mass for four days. He denied any recent deployments, trauma, or relevant family history. He had no fevers, or urinary symptoms, and testicular tumor markers were negative. He had moved to the United States from Sri Lanka in 2012, and in 2014 he spent 6 weeks back in Sri Lanka.

Physical exam revealed a firm, minimally tender, well circumscribed right testicular mass and an asymptomatic left grade 3 varicocele. He had no scrotal edema and the remainder of his exam was benign. He underwent a scrotal ultrasound that identified a 1.0 cm right testicular mass with internal vascularity and signs of possible invasion into the tunica albuginea (Fig. 1).

CT scan identified a 4 mm right pulmonary nodule, which was not thought to represent a focus of metastatic disease; however a 3 month follow up was recommended. He was counseled and underwent a right open inguinal radical orchiectomy. Surgical pathology was negative for malignancy but rather showed granulomatous orchitis due to a degenerating filarial nematode, most consistent with *Wuchereria bancrofti*.

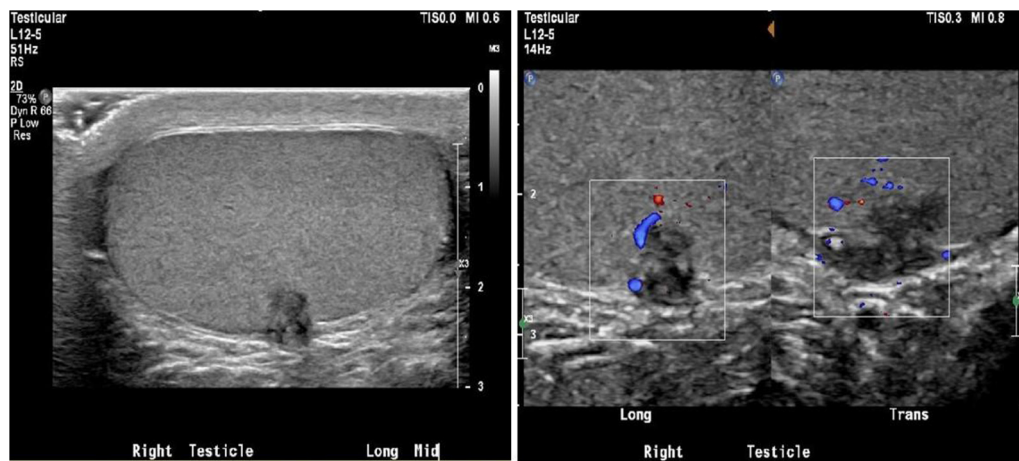
## Pathology

Grossly, bisection of the testis revealed a 0.8 × 0.6 × 0.6 cm firm, non-mobile, tan mass along the lateral aspect of the testicular parenchyma involving the tunica albuginea. The remainder of the testicular parenchyma was brown/tan with grossly normal tubules. Microscopic evaluation revealed granulomatous inflammation of the testis and tunica albuginea with abscess formation due to a degenerating filarial nematode (Fig. 2). The nematode was 150 μm in diameter, contained a gut and paired uteri filled with

Abbreviation: DEC, diethylcarbamazine citrate.

\* Corresponding author.

E-mail addresses: [karmonjanssen@gmail.com](mailto:karmonjanssen@gmail.com), [karmon.m.janssen.mil@mail.mil](mailto:karmon.m.janssen.mil@mail.mil) (K.M. Janssen).



**Figure 1.** Ultrasound demonstrating 1.0 cm right testicular mass with internal vascularity of the area of concern, and a mass which appears to be invading the tunica albuginea. There was no report of a “filarial dance.”

microfilariae, and had a finely striated cuticle, consistent with a gravid female filarial nematode (Fig. 3). *Wuchereria bancrofti* was favored due to the measured diameter of cross sections of the worm, the patient’s travel history, and male genital involvement, which is more common in Bancroftian filariasis.

In this case, diagnosis was made based on identification of the adult worm in tissue; however, filariasis is usually diagnosed based on the morphology of microfilariae seen on thick smear of peripheral blood. Subsequent peripheral blood thick smears performed on this patient failed to demonstrate microfilariae.

#### Evaluation of testicular mass

With the rare nature of filarial orchitis in the developed world, the average American practitioner is not accustomed to developing a differential for painless testicular mass that includes parasitic infection. The literature describes a unique finding associated with filariasis on ultrasound referred to as the filarial dance sign (FDS) described as “linear, echogenic, undulating structures with a persistent twirling motion”.<sup>3</sup>

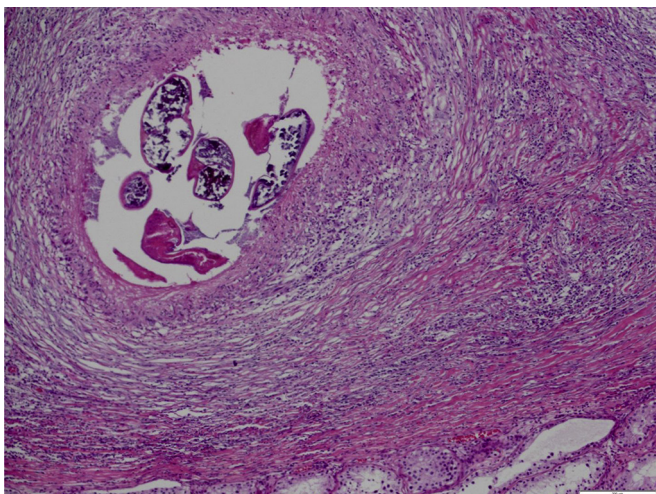
In a 2003 study, researchers followed eight patients with FDS on ultrasound – two of whom had fine needle aspiration (FNA)

biopsies and all of whom completed treatment of the filariasis with diethylcarbamazine citrate (DEC).<sup>3</sup> The study showed that on follow up ultrasound, two of the eight patients no longer had any linear structures, three had persistence of linear structures but no movement noted, one patient had diminished movement of the linear structures, one had persistent movement of the linear structures, and one patient was lost to follow up.

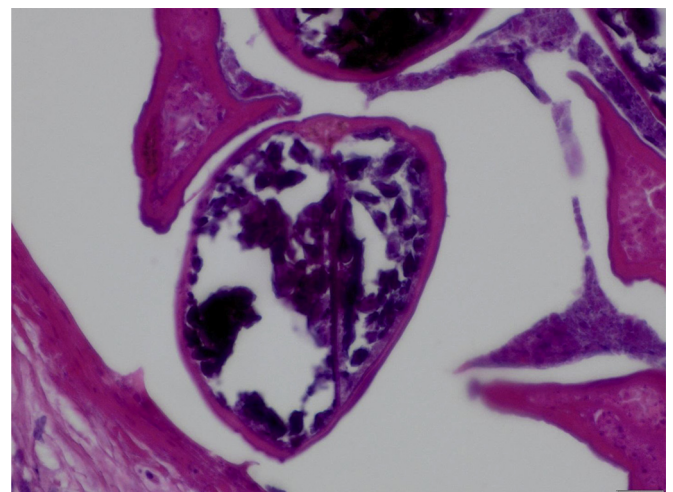
#### Recommendations for evaluation

The following recommendations are a consensus of several case reports and best practice guidelines for providers who encounter patients with an atypical testicular mass and relevant travel history.

- Perform testicular ultrasound to rule out testicular neoplasm and look for evidence of a “filarial dance”.
- Do not perform a fine needle aspiration biopsy.
- If there is suspicion for filarial infection, additional testing could include:
  - Giemsa staining and evaluation for microfilariae of a thick smear of peripheral blood collected at night



**Figure 2.** Granulomatous inflammation and abscess formation due to degenerating filarial nematode. Seminiferous tubules can be seen in the bottom right.



**Figure 3.** Paired uteri with partially calcifying microfilariae.

- Circulating filarial antigen (CFA) assays with ELISA testing, immunochromatographic techniques
- Card-based assays that can qualitatively characterize filarial disease burden
- Anti-filarial antibody serologic testing
- Other signs of filarial disease may include peripheral eosinophilia in the event of a systemic reaction, however, secondary to the known blood-testis-barrier, the testicle is a site of immune privilege and localized parasitic infections may not cause systemic inflammation.

### Management of filarial disease

Another case was described out of Malaysia whereby the patient presented with left testicular mass and underwent a radical orchiectomy when intraoperative examination showed absence of normal testicular tissue.<sup>4</sup> Histopathologic examination confirmed filariasis. Following surgery he was treated with Doxycycline.

Although doxycycline has been used for medical management of lymphatic filariasis, the United States Center for Disease Control (CDC) best practice guidelines recommend a one or 12 day course of DEC for treatment of lymphatic filariasis. This treatment requires positive confirmation of active filarial disease based on tissue or serology testing as well as signed patient consent before the CDC will approve treatment.

In our case report, the young male underwent a right inguinal orchiectomy without evidence of malignancy. He was referred to infectious disease and was treated for 12 days with DEC. His follow up serology testing was negative.

### Conclusion

Filarial disease is endemic in tropical regions, such as Sri Lanka, but is uncommon in the United States. Lymphatic filariasis with resulting pelvic lymphatic congestion and genital swelling is a well-described source of secondary orchitis.

### Conflict of interest

The views expressed are those of the author(s) and do not reflect the official policy of the Department of the Army, the Department of Defense or the U.S. Government.

### References

1. Nutman TB, Kazura J. Lymphatic Filariasis. In: Guerrant R, Walker DH, Weller PF, eds. *Tropical Infectious Diseases: Principles, Pathogens and Practice*. 3rd ed. Philadelphia: Saunders Elsevier; 2011:729.
2. Barreto SG, Rodrigues J, Pinto RGW. Filarial granuloma of the testicular tunic mimicking a testicular neoplasm: a case report. *J Med Case Rep*. 2008;2:321.
3. Chaubal NG, Pradhan GM, Chaubal JN, Ramani SK. Dance of live adult filarial worms is a reliable sign of scrotal filarial infection. *J Ultrasound Med*. 2003;22(8):765–769. quiz 770–762.
4. Ho CC, Ideris N. Testicular mass: do not forget filariasis. *Infection*. 2013;41(4):893–896.