



Observing the initial onset of retinal vasculitis as unilateral Birdshot Retinochoroiditis becomes bilateral: A case report

Natalie Huang^a, Isaac Kim^b, Bryan Rutledge^{a,c}, Dale D. Hunter^a, Robert T. Swan^{a,*}

^a Department of Ophthalmology & Visual Sciences, SUNY Upstate Medical University, 750 East Adams Street, Syracuse, NY, 13210, USA

^b Norton College of Medicine, State University of New York Upstate Medical University, 750 East Adams Street, Syracuse, NY, 13210, USA

^c Retina-Vitreous Surgeons of Central New York, PC, 200 Greenfield Parkway, Liverpool, NY, 13088, USA

ARTICLE INFO

Keywords:

Uveitis
Birdshot
Retinochoroiditis
Unilateral
Retinal vasculitis
Periphlebitis

ABSTRACT

Purpose: Birdshot Retinochoroiditis (BRC) is an uncommon but distinct form of bilateral posterior uveitis. It is generally of indolent onset, making early natural history difficult to study. Our report seeks to expand knowledge on the natural history of the onset of BRC.

Observations: Our patient presented with clinical features that were consistent with unilateral BRC, despite it being defined as a bilateral condition. Over the course of one year he developed retinal vasculitis, vitritis and fundus features of BRC in the second eye.

Conclusions and Importance: Although BRC is a bilateral disease, our case demonstrates that the onset may sometimes be sequential instead of simultaneous. Unilateral disease that is characteristic of BRC should be monitored for second-eye involvement with multi-modal imaging including fundus photography, angiography, perimetry, electroretinography, and optical coherence tomography of the macula with emphasis on the choroidal thickness.

1. Introduction

Birdshot Retinochoroiditis (BRC) is an uncommon but distinct form of posterior uveitis with a prevalence under 1 in 100,000 and accounting for 0.6–1.5% of patients referred to tertiary uveitis centers.^{1,2} When using modern polymerase chain reaction methods for detection, human leukocyte antigen (HLA)-A29 is present in nearly 100% of cases.³ 2006 and 2017 diagnostic criteria^{4,5} and 2021 classification criteria⁶ vary on certain aspects, but all require that the inflammation involve both eyes. We found two reports of unilateral choroidal lesions resembling BRC.^{7,8} Neither case had signs of inflammation or progression on long-term follow-up. We are the first to report a case that was characteristic of BRC, except for being unilateral, that later fulfilled criteria by becoming bilateral. Retinal vasculitis was the most prominent clinical feature.

2. Case report

A 67-year-old Caucasian male with no significant ocular history and medical history significant for mild early-onset Alzheimer's disease was referred to a retina specialist to evaluate new floaters and intermittent blurry vision of the left eye for the last 8 weeks. Visual acuity was 20/20 in both eyes. Intraocular pressure and pupils were normal bilaterally. Anterior segment and posterior segment examinations of the right eye were unremarkable (Fig. 1A). Anterior segment examination of the left eye was described as normal. Posterior segment examination of the left eye revealed 2+ posterior vitreous cells, 0.5+ vitreous haze, a posterior vitreous detachment, hypopigmented lesions in the inferior nasal aspect, mild peripapillary venous beading, and a small hemorrhage along the superotemporal arcade (Fig. 1B). Widefield intravenous fluorescein angiography (IVFA) of the right eye demonstrated normal perfusion without leakage or periphlebitis (Fig. 1C). Widefield IVFA of the left eye demonstrated hypofluorescence due to intraretinal hemorrhage and

Abbreviations: SUNY, State University of New York; BRC, Birdshot Retinochoroiditis; HLA, Human Leukocyte Antigen; IVFA, Intravenous Fluorescein Angiography; ICGA, Indocyanine Green Angiography; OCT, Optical Coherence Tomography; EDI, Enhanced Depth Imaging; SWAP, Short-Wavelength Automated Perimetry; ERG, Electroretinography.

* Corresponding author. Department of Ophthalmology & Visual Sciences, SUNY Upstate Medical University, 750 East Adams Street, Syracuse, NY, 13202, USA.
E-mail addresses: HuangNa@upstate.edu (N. Huang), KimI@upstate.edu (I. Kim), BRutledge@rvscny.com (B. Rutledge), HunterDa@upstate.edu (D.D. Hunter), SwanRo@upstate.edu (R.T. Swan).

<https://doi.org/10.1016/j.ajoc.2022.101593>

Received 27 March 2022; Received in revised form 15 May 2022; Accepted 18 May 2022

Available online 23 May 2022

2451-9936/© 2022 Published by Elsevier Inc. This is an open access article under the CC BY-NC-ND license (<http://creativecommons.org/licenses/by-nc-nd/4.0/>).

vitritis and hyperfluorescence of the veins from retinal vasculitis, hereafter referred to as periphlebitis (Fig. 1D). Indocyanine green angiography (ICGA) was not performed. Given the diagnostic uncertainty, the patient was referred to a uveitis specialist for evaluation and management.

Five months after his initial evaluation, the patient was seen for a uveitis evaluation at our institution. Inflammation was graded according to the 2005 Standardization of Uveitis Nomenclature scale.⁹ The right eye had no inflammation of the anterior chamber or vitreous. The left vitreous showed 2+ posterior cell and 0.5+ haze. IVFA of the right eye was normal (Fig. 2A). IVFA of the left eye revealed continued periphlebitis, hyperfluorescence of the optic nerve, and angiographic macular edema (Fig. 2F). ICGA of the right eye was normal in early and late phases (Fig. 2B). ICGA of the left eye showed numerous scattered hypofluorescent spots in the late phase extending into the periphery (Fig. 2G). Optical coherence tomography (OCT) of the right macula was normal (Supplemental Fig. 1). OCT of the left macula was notable for an epiretinal membrane. It is possible there was slight thickening of the left choroid, but enhanced depth imaging (EDI) was not performed (Supplemental Fig. 2). Baseline short-wavelength automated perimetry (SWAP) of both eyes was normal on pattern analysis (Supplemental Figs. 3 and 4). Electroretinography (ERG) was not available at our institution at the time of his presentation.

Laboratory testing was positive for HLA-A29. Negative results were obtained for HLA-B27, fluorescent treponemal antibody absorption, Lyme antibodies, interferon-gamma release assay, and angiotensin-converting enzyme. A chest radiograph demonstrated no hilar lymphadenopathy. The diagnosis of unilateral BRC was made based on the clinical findings, diagnostic imaging, and laboratory results. Treatment options were discussed, and the patient elected to be closely observed.

Three months later, the patient returned noting continued floaters. Treatment with oral mycophenolate mofetil and cyclosporine was

initiated. He returned after two months of treatment complaining of depression, anorexia, and cognitive impairment after starting the medications. Repeat IVFA showed new right optic nerve hyperfluorescence (Fig. 2C) and continued periphlebitis of the left eye (Fig. 2H). On the patient's request, medications were discontinued and, after one month of medication cessation, he reported his systemic symptoms had improved to baseline. There was then another two-month period of observation while the patient considered alternative systemic medications or intravitreal steroid implants.

Two months later, now 13 months after the initial outside presentation, the right eye had 2+ posterior vitreous cells, 0.5+ haze, and a few BRC lesions inferior nasal to the right nerve. Repeat IVFA showed new retinal periphlebitis in the right eye (Fig. 2D) and stable findings in the left eye (Fig. 2I).

After another two-month period of observation as treatment options were considered, the patient elected for intravitreal dexamethasone implants 0.7mg (Ozurdex, Allergan, Inc., Irvine, CA, USA). After bilateral implantation, there was marked improvement in the retinal vasculitis and papillitis seen on IVFA of the right and left eye, respectively (Fig. 2E & J). Unfortunately, due to his progressive cognitive decline and concern for procedural complications secondary to his mental disorientation, the patient was unable to continue intravitreal dexamethasone implantations. He was observed on subsequent visits, ultimately being lost to ophthalmologic follow-up.

3. Discussion

The natural history of the early phases of BRC is not well studied due to its rarity and the insidious onset of the condition. The time from symptom onset to diagnosis is often prolonged. Papedia et al. reported a 13.9 ± 11 month delay of diagnosis for their 14 patients.¹⁰ Kiss et al. measured 22.1 months (range, 0–108) but that measurement includes

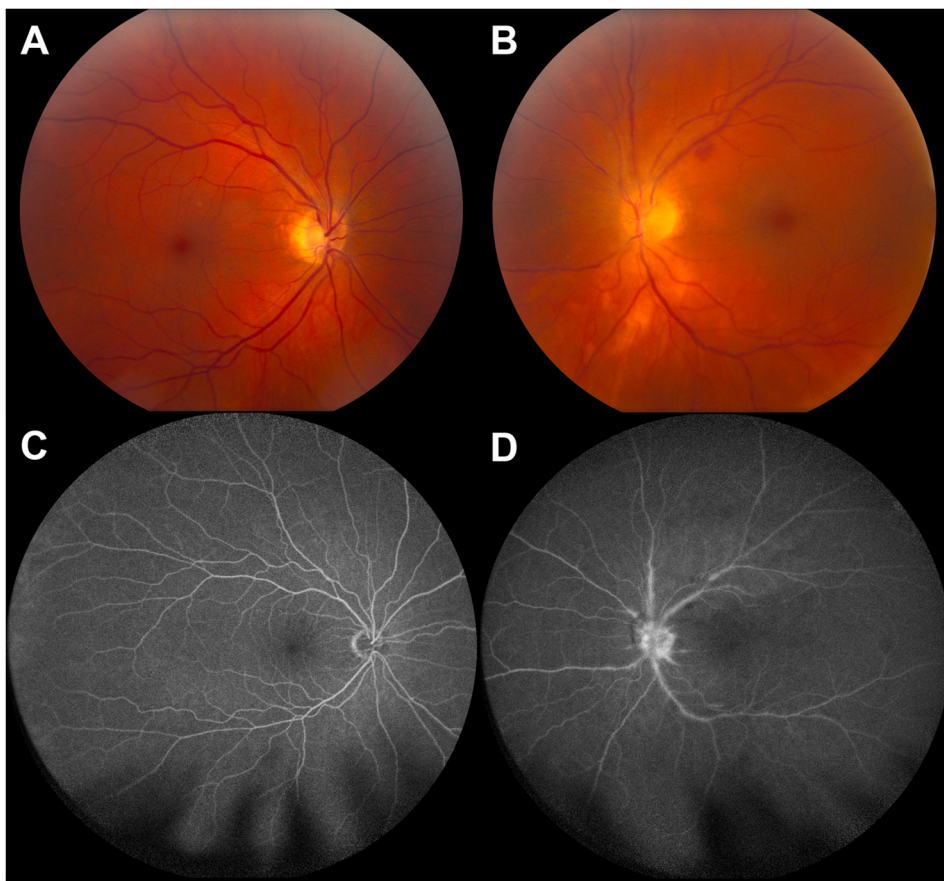


Fig. 1. Initial presentation of birdshot retinochoroiditis of the left eye eight weeks after symptom onset. A: Color fundus photo of the right eye with no visible lesions. B: Color fundus photo of the left eye demonstrating peripapillary hypopigmented lesions, peripapillary vascular sheathing, and an intraretinal hemorrhage along the superotemporal arcade. C: Intravenous fluorescein angiography (IVFA) of the right eye with normal perfusion. D: IVFA of the left eye in the arteriovenous phase, demonstrating optic nerve staining, periphlebitis, and blockage from vitreous haze. (For interpretation of the references to color in this figure legend, the reader is referred to the Web version of this article.)

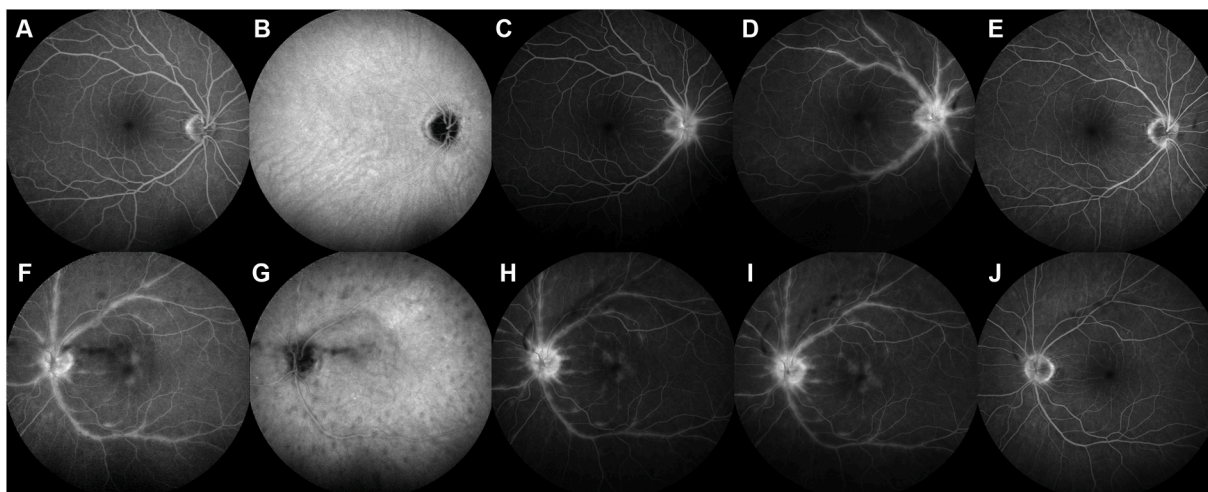


Fig. 2. Angiographic evolution of retinal periphlebitis in birdshot retinochoroiditis. A&B: Initial uveitis referral (5 months after Fig. 1). Combined intravenous fluorescein angiography (IVFA) and indocyanine green angiography (ICGA) of the right eye, late phase, showing no evidence of disease. C: 5 months later, IVFA right eye, late phase, showing hyperfluorescence of the optic nerve after 2 months of immunosuppression. D: 4 months later, IVFA right eye, late phase, showing retinal periphlebitis. E: Improvement in periphlebitis 3 months after intravitreal 0.7mg dexamethasone implant. F&G: Combined IVFA/ICGA, left eye, late phase, same date as Fig. 2A&B, showing optic nerve staining, macular leakage, and periphlebitis. Hypofluorescent spots on late-phase ICGA. H: IVFA left eye, late phase, same date as Fig. 2C, showing persistent periphlebitis despite immunosuppression. I: IVFA, left eye, late phase, same date as Fig. 2D, showing persistent periphlebitis. J: IVFA left eye, late phase, improvement in periphlebitis 6 weeks after intravitreal 0.7mg dexamethasone implant.

symptom onset to BRC diagnosis and/or referral to a uveitis specialist.¹¹

Early findings in BRC include choroidal involvement demonstrated on ICGA, retinal vasculitis seen on IVFA, and choroidal thickening seen on EDI-OCT macula.³ ICGA is especially important in the early diagnosis of BRC as it can detect subclinical disease. Choroidal lesions are visible on ICGA before the fundoscopic visualization of BRC lesions.¹² Early initiation of treatment directed at choroidal lesions prevented visible BRC lesions from forming entirely.¹³ Finally, the hypofluorescent spots visible on ICGA have been shown to be an indicator of disease activity.¹⁴ We would recommend future patients be followed closely with ICGA imaging.

Published diagnostic criteria^{4,5} and classification criteria⁶ require the presence of bilateral disease to diagnose BRC. Our patient's initial presentation was strongly suggestive of BRC, with the notable distinction of unilateral disease. We found two unilateral BRC-like cases reported in the literature. The first case reported an HLA-A29-positive 69-year-old male with hypopigmented choroidal lesions of the right eye.⁷ ICGA for this patient showed unilateral disease. This patient had not developed vitritis or retinal vasculitis on IVFA at last follow-up, three years after the lesions were first noted. The second case reported a HLA-A29-negative 64-year-old woman with unilateral choroidal lesions resembling the BRC pattern.⁸ Similar to the previous patient, ICGA showed unilateral choroidal lesions, but there was no evidence of inflammation or retinal vasculitis on IVFA despite follow-up of 30 months. Neither patient received any treatment during the period of observation.

The strength of our work is the serial IVFA images showing initial development of BRC. It is noteworthy that our patient's second-eye involvement had optic nerve staining preceding more diffuse retinal periphlebitis. Due to the extended time taken to consider treatment options, altered only by a 6-week period of immunosuppression, this case provided a unique ability to observe the natural history of BRC. Finally, our patient allows us to speculate that BRC can have an asynchronous onset between the two eyes.

Our study would have been strengthened with sequential multimodal imaging including true color fundus photography, IVFA, ICGA, and EDI-OCT choroidal imaging that would have allowed additional characterization of the natural history of BRC onset. An additional limitation, imposed by the patient's progressive dementia, was the

inability to do follow-up testing on a long-term basis.

4. Conclusion

Our patient had initial findings that were characteristic for BRC, lacking only the presence of bilateral disease. Over time his second eye developed characteristic retinal vasculitis, vitritis, and retinal lesions suggesting disease onset can be asynchronous. We recommend future patients with unilateral BRC be monitored with serial multimodal imaging including true color fundus photography, IVFA, ICGA, SWAP perimetry, ERG, and EDI-OCT choroidal imaging to better diagnose and characterize the natural history of BRC onset in the second eye.

Patient consent

Consent to publish the case report was obtained for the patient's spouse. This report does not contain any personal information that could lead to the identification of the patient.

Funding

Supported by an Unrestricted Grant from Research to Prevent Blindness to SUNY Upstate Medical University's Department of Ophthalmology & Visual Sciences: NH, DH, RS.

Statement on the order of authors and authorship eligibility

All authors attest that they meet the current ICMJE criteria for Authorship. Natalie Huang: Writing-Original draft preparation, Writing – Review and Editing, Visualization. Isaac Kim: Writing – Original Draft. Writing – Review and Editing. Bryan Rutledge: Conceptualization, Writing – Review and Editing. Dale Hunter: Writing – Review and Editing, Visualization. Robert Swan: Conceptualization, Methodology, Supervision, Writing – Original Draft, Writing – Review & Editing.

IRB approval

Exempt from IRB approval.

Disclosures

The following authors have no financial disclosures: NH, IK, BR, DH, RS.

Declaration of interests

The authors declare that they have no known competing financial interests or personal relationships that could have appeared to influence the work reported in this paper.

Acknowledgments

The authors wish to thank our ophthalmic photographers, Stefanie Palmer and Margaret Blanford. We also would like to thank Angela Barrett for assistance with figure assembly.

Appendix A. Supplementary data

Supplementary data to this article can be found online at <https://doi.org/10.1016/j.ajoc.2022.101593>.

References

- Shah KH, Levinson RD, Yu F, et al. Birdshot chorioretinopathy. *Surv Ophthalmol*. Nov-Dec 2005;50(6):519–541. <https://doi.org/10.1016/j.survophthal.2005.08.004>.
- Minos E, Barry RJ, Southworth S, et al. Birdshot chorioretinopathy: current knowledge and new concepts in pathophysiology, diagnosis, monitoring and treatment. *Orphanet J Rare Dis*. May 12 2016;11(1):61. <https://doi.org/10.1186/s13023-016-0429-8>.
- Papadia M, Pavesio C, Fardeau C, et al. HLA-A29 birdshot retinochoroiditis in its 5th decade: selected glimpses into the intellectual meanderings and progresses in the knowledge of a long-time misunderstood disease. *Diagnostics*. Jul 19 2021;(7):11. <https://doi.org/10.3390/diagnostics11071291>.
- Levinson RD, Brezin A, Rothova A, Accorinti M, Holland GN. Research criteria for the diagnosis of birdshot chorioretinopathy: results of an international consensus conference. *Am J Ophthalmol*. Jan 2006;141(1):185–187. <https://doi.org/10.1016/j.ajo.2005.08.025>.
- Herbert Jr CP, Pavesio C, LeHoang P, et al. Why birdshot retinochoroiditis should rather be called 'HLA-A29 uveitis'? *Br J Ophthalmol*. Jul 2017;101(7):851–855. <https://doi.org/10.1136/bjophthalmol-2016-309764>.
- Standardization of Uveitis Nomenclature Working G. Classification criteria for birdshot chorioretinitis. *Am J Ophthalmol*. Aug 2021;228:65–71. <https://doi.org/10.1016/j.ajo.2021.03.059>.
- Akiki RK, Statler B, Greenberg PB, Janigian RH. Unilateral birdshot chorioretinopathy in an elderly patient. *R I Med J*. Feb 1 2019;102(1):60–61.
- de la Fuente MA, Recio P. Unilateral birdshot-like choroidopathy: a case report. *Retin Cases Brief Rep Fall*. 2012;6(4):365–367. <https://doi.org/10.1097/ICB.0b013e31824f7107>.
- Jabs DA, Nussenblatt RB, Rosenbaum JT. Standardization of uveitis nomenclature working G. Standardization of uveitis nomenclature for reporting clinical data. Results of the first international workshop. *Am J Ophthalmol*. Sep 2005;140(3):509–516. <https://doi.org/10.1016/j.ajo.2005.03.057>.
- Papadia M, Jeannin B, Herbert CP. OCT findings in birdshot chorioretinitis: a glimpse into retinal disease evolution. *Ophthalmic Surg Laser Imag*. Nov-Dec 2012;43(6 Suppl):S25–S31. <https://doi.org/10.3928/15428877-20120816-01>.
- Kiss S, Ahmed M, Letko E, Foster CS. Long-term follow-up of patients with birdshot retinochoroidopathy treated with corticosteroid-sparing systemic immunomodulatory therapy. *Ophthalmology*. Jun 2005;112(6):1066–1071. <https://doi.org/10.1016/j.ophtha.2004.12.036>.
- Reddy AK, Gonzalez MA, Henry CR, Yeh S, Sobrin L, Albini TA. Diagnostic sensitivity of indocyanine green angiography for birdshot chorioretinopathy. *JAMA Ophthalmol*. Jul 2015;133(7):840–843. <https://doi.org/10.1001/jamaophthalmol.2015.0822>.
- Knecht PB, Papadia M, Herbert Jr CP. Early and sustained treatment modifies the phenotype of birdshot retinochoroiditis. *Int Ophthalmol*. Jun 2014;34(3):563–574. <https://doi.org/10.1007/s10792-013-9861-0>.
- Cao JH, Silpa-Archa S, Freitas-Neto CA, Foster CS. Birdshot chorioretinitis lesions on indocyanine green angiography as an indicator of disease activity. *Retina*. Sep 2016;36(9):1751–1757. <https://doi.org/10.1097/IAE.0000000000000967>.