

Transfemoral transcatheter aortic valve replacement for severe aortic stenosis with concomitant left ventricular diverticulum: a case report

Siyu Xi¹, Haishan Zhang¹, Xin Chen², and Liang Guo ^{1*}

¹Department of Cardiology, The First Hospital of China Medical University, 155 Nanjing North Street, Heping District, Shenyang 110001, People's Republic of China; and ²Department of Cardiovascular Ultrasound, The First Hospital of China Medical University, Shenyang 110001, People's Republic of China

Received 27 March 2022; first decision 4 May 2022; accepted 9 August 2022; online publish-ahead-of-print 11 August 2022

Background

Left ventricular diverticulum (LVD) is a rare cardiac malformation in patients with severe aortic stenosis (AS). Transcatheter aortic valve replacement (TAVR) is not recommended due to the risk of diverticulum injury. However, for patients considered inoperable or at high surgical risk, TAVR might be the only treatment option. The safety and feasibility of TAVR for severe AS with concomitant LVD are still unclear.

Case summary

An 80-year-old Asian woman complaining of shortness of breath was admitted to our hospital, whose echocardiogram showed calcified severe AS and a diverticulum in the left ventricular apex. A transfemoral 26 mm Venus-A prosthetic aortic valve was successfully implanted. Pre- and post-procedural cardiac magnetic resonance imaging revealed a remarkable volume reduction of LVD.

Discussion

Transfemoral TAVR was not preferred because the straight-tip hydrophilic wire and catheter tip could injure the fragile diverticulum wall. If we could avoid the injury of the diverticulum, TAVR would be a good option for patients at high surgical risk.

Keywords

Aortic stenosis • Left ventricular diverticulum • Transcatheter aortic valve replacement • Cardiac magnetic resonance • Case report

ESC Curriculum

2.3 Cardiac magnetic resonance • 4.2 Aortic stenosis • 4.10 Prosthetic valves • 9.1 Aortic disease

Learning points

- Transfemoral transcatheter aortic valve replacement (TAVR) could be performed safely for severe aortic stenosis with concomitant left ventricular diverticulum (LVD) in selected patients.
- Careful manipulation of wires and catheters is important to avoid the injury of LVD.
- The volume of the LVD diminished remarkably after TAVR.

* Corresponding author. Tel: +86 24 83283166, Fax: +8624-83282997, Email: lguo@cmu.edu.cn

Handling Editor: Sameh Shaheen

Peer-reviewers: Claudio Montalto; Konstantinos Stathogiannis

Compliance Editor: Gal Tsaban

Supplementary Material Editor: Gonçalo Costa

© The Author(s) 2022. Published by Oxford University Press on behalf of the European Society of Cardiology.

This is an Open Access article distributed under the terms of the Creative Commons Attribution-NonCommercial License (<https://creativecommons.org/licenses/by-nc/4.0/>), which permits non-commercial re-use, distribution, and reproduction in any medium, provided the original work is properly cited. For commercial re-use, please contact journals.permissions@oup.com.

Introduction

Left ventricular diverticulum (LVD) is a rare cardiac malformation in patients with severe aortic stenosis (AS). In this setting, surgical aortic valve replacement (SAVR) is recommended as superior to transcatheter aortic valve replacement (TAVR) according to the guidelines.^{1,2} However, for patients considered inoperable or at high surgical risk, TAVR might be the only treatment option. Here, we present a case of transfemoral TAVR with a self-expanding valve in severe AS with concomitant LVD.

Timeline

| Date | Event |
|---------|---|
| Day 1 | The patient was admitted to our institute complaining of increasing shortness of breath |
| Day 2 | Pre-procedural transthoracic echocardiography (TTE) was performed, showing severe calcified severe AS and a 10 × 12 mm diverticulum in the left ventricular apex |
| Day 3 | Pre-procedure computed tomography (CT) scan was performed |
| Day 4 | Pre-procedural cardiac magnetic resonance imaging (CMR) was performed, showing a diverticulum in the left ventricular apex with end-systolic volume (ESV) of 0.81 mL (Figure 1A) and end-diastolic volume (EDV) of 0.35 mL (Figure 1B, Supplementary material online, Video S1) |
| Day 6 | A multidisciplinary team (MDT) discussion was held. Due to a high Society of Thoracic Surgeons score (STS) for risk of mortality of 8.3%, the patient was declined for SAVR. Considering the small neck of the LVD (13.8 × 8.2 mm), if the stiff wire could be shaped into a big enough curve, the possibility of injuring the LVD by the stiff wire would be greatly diminished. Transcatheter aortic valve replacement would be a reasonable option |
| Day 8 | Transfemoral TAVR was performed. Aortography and transoesophageal echocardiography showed a well-functioned aortic valve with trivial paravalvular leakage |
| Day 10 | Patient discharge |
| Month 1 | Cardiac magnetic resonance imaging showed diminished volume of the diverticulum (0.31 mL at ESV (Figure 1C) and 0.17 mL at EDV (Figure 1D, Supplementary material online, Video S4). |

Case

An 80-year-old Asian woman was admitted to our institute complaining of increasing shortness of breath with New York Heart Association Class III heart failure symptoms. She had a history of smoking, hypertension, heart failure, and persistent atrial fibrillation. On physical examination, she had a systolic ejection murmur and an irregular rhythm. Blood tests showed no abnormalities except for plasma N-terminal pro-B-type natriuretic peptide (NT-proBNP) level was 12 143.00 pg/mL (reference level, <125 pg/mL).

Transthoracic echocardiogram showed severe calcified AS (peak velocity: 4.5–4.8 m/s, peak gradient: 81–90 mmHg, mean gradient:

50–56 mm Hg, aortic valve orifice area: 0.5 cm², left ventricular ejection fraction: 41%) and a 10 × 12 mm diverticulum in the left ventricular apex.

Cardiac magnetic resonance imaging with gadolinium demonstrated severe AS with decreased systolic function of left and right ventricles, and a diverticulum in the left ventricular apex with ESV of 0.81 mL (Figure 1A) and EDV of 0.35 mL (Figure 1B, Supplementary material online, Video S1).

Preoperative CT showed severely calcified AS, with an annular perimeter of 79.4 mm, calcium above HU 850 of 583 mm³, and adequate coronary heights of 19 mm on the right and 11.5 mm on the left. The iliofemoral arteries are suitable for transfemoral access.

A MDT discussion was held to determine the treatment option for the patient. Due to a high STS score for risk of mortality of 8.3%, the patient was declined for SAVR. Considering the small neck of the LVD (13.8 × 8.2 mm, Figure 2A and B), if the stiff wire could be shaped into a big enough curve, the possibility of injuring the LVD by the stiff wire would be greatly diminished. Transcatheter aortic valve replacement would be a reasonable option.

Transcatheter aortic valve replacement was performed under general anaesthesia and transfemoral approach. A straight-tip soft hydrophilic wire (Terumo Medical, Japan) supported by an AL1 catheter was carefully controlled to cross the aortic valve. To avoid injuring the LVD, the wire and catheter were controlled carefully not to exceed more than half of the left ventricle (see Supplementary material online, Video S2), then exchanged for a pre-shaped Lunderquist stiff wire (Cook Medical Inc., loop diameter: 29.5 × 23.5 mm, Figure 2C). After pre-dilatation with a 23-mm balloon (NuMED Inc., Hopkinton, NY, USA), a 26 mm Venus-A prosthetic valve (Venus MedTech Inc., HangZhou) was deployed successfully. Final aortography (see Supplementary material online, Video S3) and transoesophageal echocardiography showed a well-functioned valve with trivial paravalvular leakage. Cardiac magnetic resonance imaging 1 month after the procedure showed a diminished volume of the diverticulum (0.31 mL at ESV (Figure 1C) and 0.17 mL at EDV (Figure 1D, Supplementary material online, Video S4). Blood tests also showed that NT-proBNP level had been decreased to 3532.00 pg/mL.

Discussion

Left ventricular diverticulum is a rare cardiac malformation characterized by a localized outpouching from the cardiac chamber. For AS patients with concomitant apical diverticulum, the standard therapy is SAVR and LVD removal. Transapical TAVR and following excluding of the ventricle diverticulum during the same procedure, as reported by Ferrari et al.³ in 2013, is an acceptable option for patients at high surgical risk. However, the transapical approach has a risk of bleeding, myocardial injury, and the invasiveness of ventriculostomy and thoracotomy. Sometimes, patients cannot tolerate the invasiveness of this approach. Transfemoral TAVR was not preferred because the straight-tip hydrophilic wire and catheter tip could injure the fragile diverticulum wall. If we could avoid the injury of the diverticulum, TAVR would be a good option for patients at high surgical risk.

For this case, the diverticulum was located at the left ventricle apex, and we could control the wire and catheter not to exceed more than half of the left ventricle, thus not touching the diverticulum. The neck of the diverticulum was very small, not allowing the pre-shaped stiff wire to enter. So the procedure could be finished safely without any complications. During the procedure, the most important thing is the careful manipulation of the straight-tip wire and AL catheter. After exchanging to the pre-shaped wire, it is as safe as the routine TAVR procedure.

Theoretically, as left ventricular pressure declined after TAVR, the volume of the diverticulum could also decrease. In this case, we demonstrated that the volume of the diverticulum diminished remarkably after the procedure by pre- and post-procedure CMR.

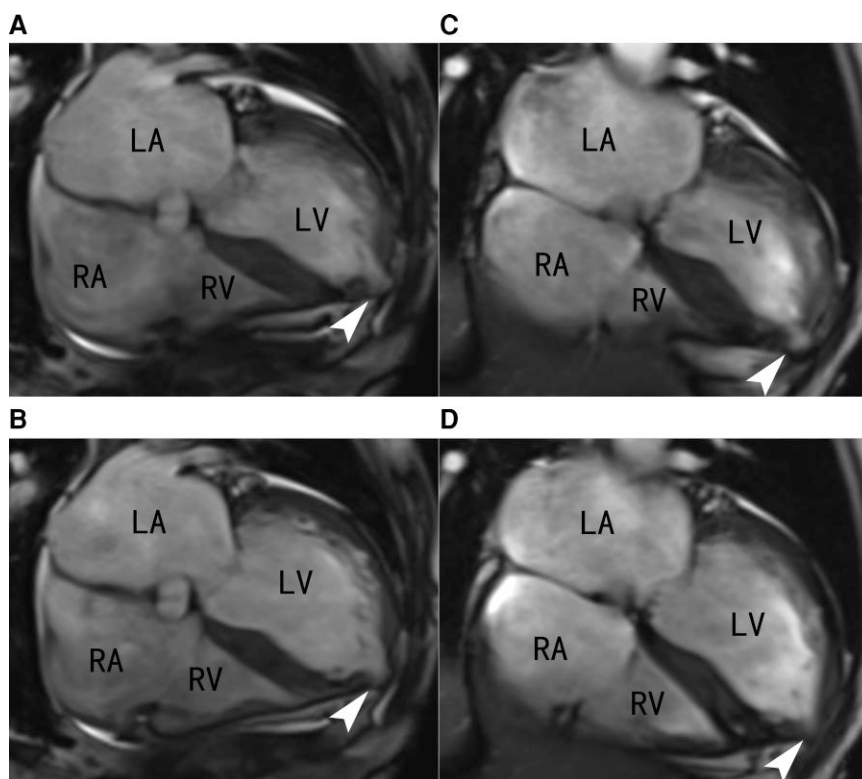


Figure 1 (A) Pre-procedural cardiac magnetic resonance imaging showing the left ventricular diverticulum (arrow) at the end of the systolic phase. (B) Pre-procedural cardiac magnetic resonance imaging showing the left ventricular diverticulum (arrow) at the end of the diastolic phase. (C) Post-procedural cardiac magnetic resonance imaging showing the left ventricular diverticulum (arrow) at the end of the systolic phase. (D) Post-procedural cardiac magnetic resonance imaging showing the left ventricular diverticulum (arrow) at the end of the diastolic phase.

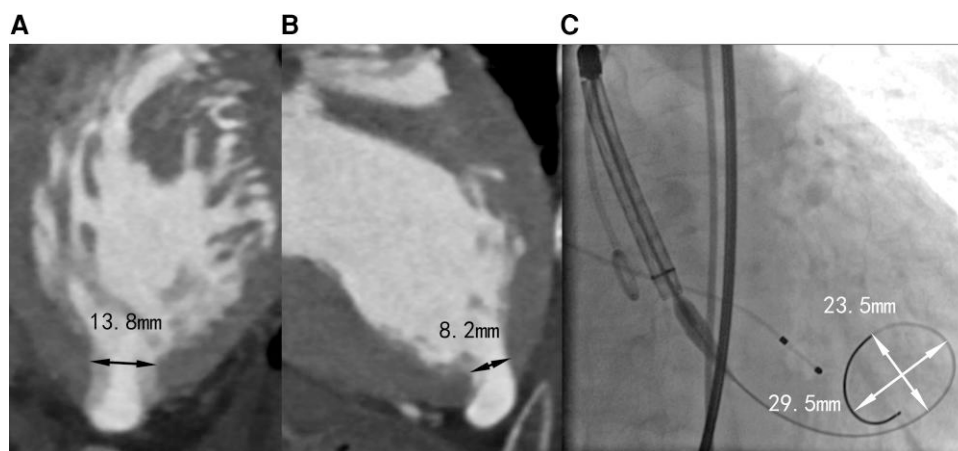



Figure 2 The maximal (A) and minimal (B) diameter of the neck of the left ventricular diverticulum. (C) The maximal and minimal diameter of the apical curve of the stiff wire.

Conclusion

This case suggests that transfemoral TAVR is safe and feasible for selected patients with severe AS and concomitant LVD.

Lead author biography



Dr Liang Guo, MD, PhD served as Associate Professor at Department of Cardiology, the First Hospital of China Medical University, Shenyang, China. He performed more 500 cases of coronary interventions and 30 cases of TAVR every year.

Supplementary material

[Supplementary material](#) is available at *European Heart Journal—Case Reports* online.

Acknowledgements

None declared.

Slide sets: A fully edited slide set detailing these cases and suitable for local presentation is available online as Supplementary data.

Consent: The authors confirm that written consent for submission and publication of this case report including imaging and associated text has been obtained from the patient in line with COPE guidance.

Conflict of interest: None declared.

Funding: None declared.

References

1. Vahanian A, Beyersdorf F, Praz F, Milojevic M, Baldus S, Bauersachs J, Capodanno D, Conradi L, De Bonis M, De Paulis R, Delgado V, Freemantle N, Gilard M, Haugaa KH, Jeppsson A, Juni P, Pierard L, Prendergast BD, Sadaba JR, Tribouilloy C, Wojakowski W, Group, Esc Eacts Scientific Document and Group, E. S. C. Scientific Document. 2021 ESC/EACTS guidelines for the management of valvular heart disease. *Eur Heart J* 2022; **43**:561–632.
2. Otto CM, Nishimura RA, Bonow RO, Carabello BA, Erwin JP III, Gentile F, Jneid H, Krieger EV, Mack M, McLeod C, O’Gara PT, Rigolin VH, Sundt TM III, Thompson A, Toly C. 2020 ACC/AHA guideline for the management of patients with valvular heart disease: a report of the American college of cardiology/American heart association joint committee on clinical practice guidelines. *J Am Coll Cardiol* 2021;**77**:e25–e197.
3. Ferrari E, Van Steenberghe M, Namasivayam J, Berdajs D, Niclauss L, von Segesser LK. Feasibility of transapical aortic valve replacement through a left ventricular apical diverticulum. *J Cardiothorac Surg* 2013;**8**:3.