



## Case report

## Atypical perifoveal exudative vascular anomalous complex (PEVAC) with multifocal and bilateral presentation



José Ignacio Fernández-Vigo<sup>a,b,\*</sup>, Bárbara Burgos-Blasco<sup>a</sup>, Rosa Dolz-Marco<sup>c</sup>,  
María Jiménez-Santos<sup>a</sup>, Lorenzo López-Guajardo<sup>a</sup>, Juan Donate-López<sup>a</sup>

<sup>a</sup> Department of Ophthalmology, Hospital Clínico San Carlos, Instituto de Investigación Sanitaria (IdISSC), Madrid, Spain

<sup>b</sup> Centro Internacional de Oftalmología Avanzada, Madrid, Spain

<sup>c</sup> Unit of Macula, Ophthalmic Clinic, Valencia, Spain

## ARTICLE INFO

## Keywords:

Cystoid macular edema  
Microaneurysm  
Optical coherence tomography angiography  
Perifoveal exudative vascular anomalous complex  
Perifoveal aneurysmal lesion  
PEVAC

## ABSTRACT

**Purpose:** To report an unusual case of multifocal and bilateral perifoveal exudative vascular anomalous complex (PEVAC) lesions in an otherwise healthy patient.

**Observations:** A 62-year-old male with complaints of long-term progressive blurred vision in both eyes. There was no history of diabetes, arterial hypertension or inflammatory disease. Best-corrected visual acuity was 75 and 80 letters in his right eye (OD) and left eye (OS) respectively. Fundus examination showed three perifoveal isolated large aneurysmal lesions in his OD and an additional one in his OS, associated with smaller microaneurysms, haemorrhages and intraretinal exudation. On optical coherence tomography PEVAC appeared as a round lesions with a hyperreflective wall and lumen containing variably reflective material, typically surrounded by intraretinal fluid. Dye-based angiography demonstrated three and one well-defined large hyperfluorescent aneurysmal lesions in his OD and OS respectively, with no leakage. The optical coherence tomography angiography images showed flow signal within the intraretinal aneurysmal lesions. No anomalous flow signal in the outer retina and choriocapillaris was present. After one bilateral anti-vascular endothelial growth factor intravitreal injection no anatomical or functional improvement was observed, and no changes in the lesions or visual acuity were observed at 6 months follow-up.

**Conclusions and importance:** We describe an atypical case of PEVAC, an uncommon and poorly known macular disorder, with bilateral presentation and multifocal lesions in one eye. To our knowledge, this is the first reported case of bilateral PEVAC lesions. Hence, PEVAC should be included in the differential diagnosis of bilateral perifoveal aneurysmal lesions with macular edema.

## 1. Introduction

Perifoveal retinal vascular abnormalities are typically associated with retinal vascular occlusive or inflammatory diseases. However, perifoveal exudative vascular anomalous complex (PEVAC) was initially described in 2011 by Querques et al. as an isolated perifoveal intraretinal vascular abnormality in otherwise healthy patients that do not fit into any other previously described macular diseases.<sup>1</sup>

On fundus examination, PEVAC is usually associated with small retinal haemorrhages and intraretinal exudation. The optical coherence tomography (OCT) scans show PEVAC lesions as round hyperreflective intraretinal structures with a dark lumen containing variably reflective material, corresponding to the perifoveal vascular alteration identified on fundus examination.<sup>1,2</sup> These lesions are commonly associated with

intraretinal fluid seen as cystic changes, being the external layers of the retina well preserved. Dye-based angiography usually demonstrates a well-defined hyperfluorescent lesion with variable leakage on fluorescein angiography (FA), but no leakage on indocyanine green angiography (ICGA). The OCT angiography (OCTA) images commonly shows flow signal which correlates with the aneurysmal lesion directly connecting to retinal capillary plexuses. However, as has been reported by other authors, PEVAC has demonstrated a wide clinical spectrum.<sup>1-8</sup>

Sacconi et al. have reported the largest series published, describing 15 cases of PEVAC from 4 retina referral centres worldwide.<sup>2</sup> In their study, PEVAC was not only identified in healthy subjects, but also in patients with concomitant age-related macular degeneration (AMD) and myopic macular degeneration, causing visual decline due to the presence of intraretinal fluid. In the three largest series published to

\* Corresponding author. Zurbano 71 Street, 28010, Madrid, Spain.

E-mail addresses: [jfvigo@hotmail.com](mailto:jfvigo@hotmail.com), [josefdezvigo@gmail.com](mailto:josefdezvigo@gmail.com) (J.I. Fernández-Vigo).

<https://doi.org/10.1016/j.ajoc.2020.100717>

Received 27 January 2020; Received in revised form 26 March 2020; Accepted 15 April 2020

Available online 21 April 2020

2451-9936/ © 2020 The Authors. Published by Elsevier Inc. This is an open access article under the CC BY-NC-ND license (<http://creativecommons.org/licenses/by-nc-nd/4.0/>).

date, no bilateral cases have been described and the maximum number of PEVAC lesions found in one eye is two.<sup>2,4,7</sup>

The purpose of this case report is to describe a patient with atypical multifocal and bilateral PEVAC-like lesions.

## 2. Case report

A 62-year-old male was referred to our department complaining with progressive blurred vision in both eyes for a long time. There was no history of diabetes, arterial hypertension, inflammatory diseases, obstructive sleep apnea syndrome, carotid artery occlusion or blood dyscrasias, confirmed in recent controls. The patient had started anticoagulation due to a mitral valve replacement for mitral regurgitation five years prior to baseline examination. The patient signed an informed consent according to good clinical practice guidelines, before proceeding with any examinations and treatments.

Best-corrected visual acuity (BCVA) was 75 letters in the Early Treatment Diabetic Retinopathy Study (ETDRS) scale in his right eye (OD) and 80 letters in his left eye (OS). He was phakic in both eyes, but not significant cataract was present. Fundus examination showed three perifoveal large aneurysmal lesions in his OD and one isolated lesion in his OS, accompanied by small haemorrhages and intraretinal exudation (Fig. 1A and B). Multicolour image and autofluorescence did not show any additional relevant findings (Fig. 1C–F). No signs of diabetic retinopathy, retinal vein occlusion or other vascular diseases were observed in the peripheral retina on FA (Fig. 1G and H).

Dye angiography (Spectralis; Heidelberg Engineering, Heidelberg, Germany) of the macula showed three large aneurysms associated with other small microaneurysms in the OD, all located in the perifoveal and parafoveal region (Fig. 2A and B). An isolated hyperfluorescent lesion was observed in the OS (Fig. 2C and D). None of the aneurysmal lesions showed leakage on FA or ICGA in early (Fig. 2A–D) or late frames (Fig. 2E–H).

On OCT (Spectralis; Heidelberg Engineering, Heidelberg, Germany) cystic changes were detected in both eyes (Fig. 3). All PEVAC lesions identified on fundus examination appeared on OCT as round intraretinal lesions with a hyperreflective wall with a variably reflective content (Fig. 3). The outer retinal layers were well preserved. Regarding the location of the lesions, PEVACs were located between the outer plexiform layer (OPL) and the ganglionar cell layer (GCL). Vitreomacular adhesion was observed in both eyes.

Using two different OCTA devices (Plex-Elite, Carl Zeiss Meditec, Inc, Dublin, CA; and Spectralis; Heidelberg Engineering, Heidelberg, Germany) the 3 × 3 and 9 × 9 mm central area were explored and showed flow signal correlating with the intraretinal aneurysmal lesions seen on the fundus and structural OCT (Fig. 4 for the OD and Fig. 5 for the OS). A focal decrease on the capillary density was observed in the perianeurysmal area. However, the choriocapillaris demonstrated a preserved appearance and no signs of anastomosis between the retinal

capillary plexuses and the choriocapillaris or collateral vessels were detected. The outer retinal layers were also preserved. PEVAC lesions were mainly located within the superficial capillary plexus but also involving the deep capillary complex.

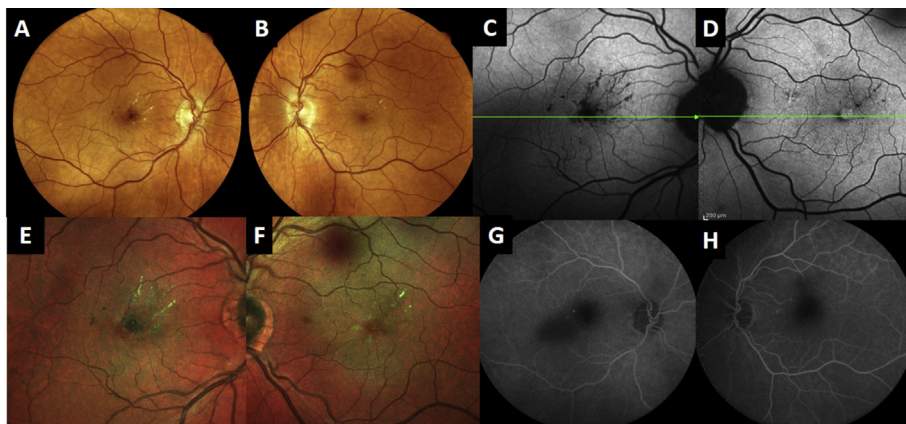
Intravitreal injection of an anti-vascular endothelial growth factor (anti-VEGF) agent, ranibizumab (Lucentis, Novartis Pharma, Basel, Switzerland), was performed in both eyes. One week and one month after the intravitreal injection, OCT and OCTA scans showed the persistence of the PEVAC lesions without any anatomical or functional improvement. Due to the lack of anatomical response and visual stability, the patient decided to discontinue anti-VEGF treatment after a thorough discussion on the pros and cons of both options: treatment versus observation unless visual decline. Also, as previous reports already described in this entity, anti-VEGF responses are variable and often not complete. However, some patients show late anti-VEGF responsiveness.<sup>1,2,7</sup> No additional changes were observed in the aneurysmal lesions after 6 months of follow-up, but subtle fluid shifts were seen (Fig. 3). Vitreomacular adhesion progressed in the OD, but no retinal or choroidal vascular abnormality was associated.

## 3. Discussion

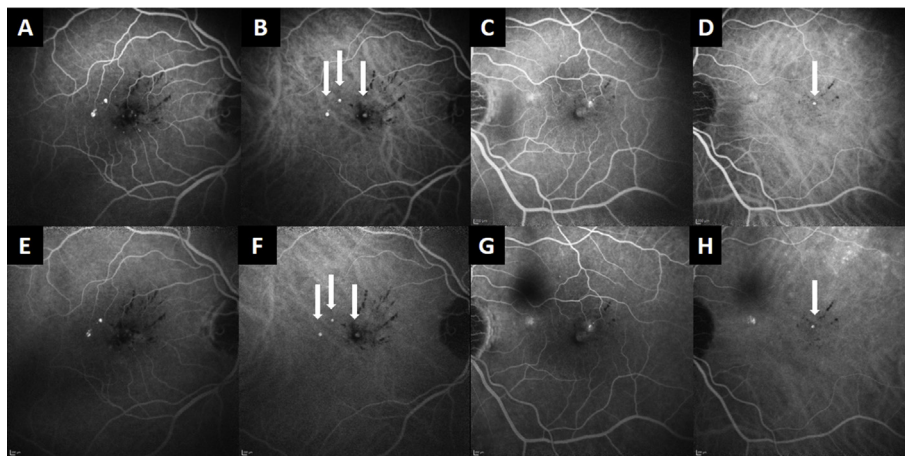
To our knowledge, this is the first report of a patient presenting with bilateral multifocal perifoveal aneurysmal lesions associated with retinal exudation and cystic changes, compatible with the clinical entity known as “perifoveal exudative vascular anomalous complex” or PEVAC.<sup>1</sup> As originally described, PEVAC lesions are characterized by an isolated and well-defined perifoveal aneurysmal abnormality in otherwise healthy eyes.<sup>1</sup> Different case reports and case series have been reported to date.<sup>1–8</sup> PEVAC typically affects patients in the AMD age range, but the response to anti-VEGF therapy of these aneurysmal abnormalities is variable with some patients achieving only late response or incomplete response.<sup>1,2,7</sup>

Sacconi et al. reported 15 eyes of 15 patients with PEVAC lesions, with a mean age  $73 \pm 13$  years, 14 patients being White and 1 Hispanic.<sup>2</sup> In their study, all PEVAC cases were unilateral and typically unifocal. However, they also disclosed 3 cases with 2 lesions in the same eye. Mrejen et al. reported a series of 8 patients (mean age  $68.6 \pm 13.7$  years) with PEVAC, with a sole lesion in 7 eyes, and only one patient presenting two lesions on the same eye.<sup>7</sup> Kim et al. recently described the characteristics of eight eyes of 8 Korean patients with a mean age of  $61.0 \pm 11.0$  years, diagnosed with PEVAC.<sup>4</sup> Similarly, we present a patient in his early sixties, White of European descent and, interestingly, we report typical PEVAC lesions with an atypical bilateral and multifocal presentation. We suggest that the possible underlying mechanisms that cause one or multiple aneurysmal dilations in one eye, may be systemic or general, and thus induce PEVAC lesions in both eyes.

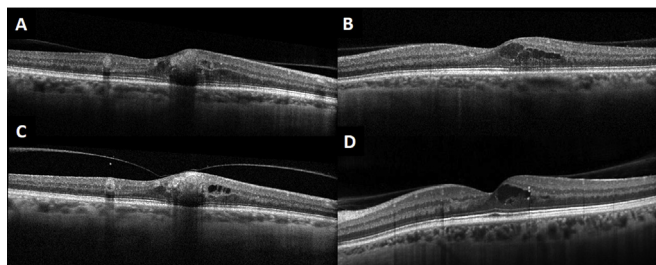
Sacconi et al. reported 6 out of 15 eyes diagnosed with coincident



**Fig. 1.** A - B) Fundus color photograph of both eyes showing a perifoveal isolated large aneurysmal lesions, accompanied by small hemorrhages and small hard exudates accumulation. (C - D) Autofluorescence did not reveal significant alteration of the retinal pigment epithelium. (E - F) Multicolour image of the macula. (G - H) Fluorescein angiography of the peripheral retina did not show any vascular abnormalities. (For interpretation of the references to colour in this figure legend, the reader is referred to the Web version of this article.)



**Fig. 2.** Both fluorescein angiography and indocyanine green angiography reveal the isolated perifoveal exudative vascular aneurysm lesions in the right (A–B) and left eye (C–D) respectively for the early and late frames (E–H), with absence of any other retinal or choroidal vascular abnormality associated.



**Fig. 3.** Optical coherence tomography (OCT) shows a cystoid macular edema in both eyes (A: right eye; B: left eye). (C–D) OCT at six months showing only a subtle fluid shift.

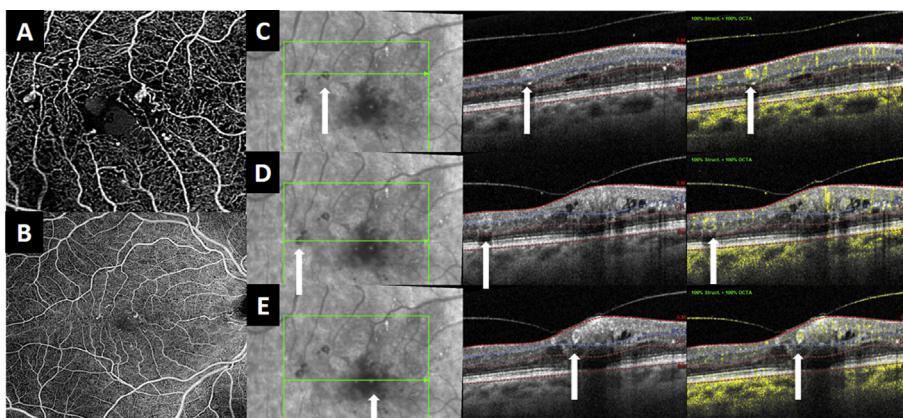
AMD,<sup>2</sup> and Kim et al. showed 2 out of 8 eyes with AMD.<sup>4</sup> However, in our patient, we did not evidence any sign of early, intermediate or advanced AMD, and no anomalous flow signal was present in the outer retina and the choriocapillaris on OCTA, ruling out the presence of macular neovascularization.

The main cause of the visual decline in PEVAC is the presence of intraretinal cystic changes, as in our case. Sacconi et al. reported no benefit of the anti-VEGF therapy, showing no differences in BCVA and central macular thickness between patients receiving anti-VEGF therapy and those without any treatment.<sup>2</sup> Kim et al. also described no improvement after anti-VEGF therapy in two patients.<sup>4</sup> Therefore, unlike exudative microangiopathies secondary to ischemia or inflammation, or type 1 idiopathic macular telangiectasia, PEVAC shows a variable response to anti-VEGF. Interestingly, as observed by Sacconi et al. spontaneous fluctuation of the associated intraretinal fluid might

act as a major confounder when assessing anti-VEGF treatment responses.<sup>2</sup> Querques et al. proposed that progressive retinal endothelial cell degeneration may be the triggering, vasogenic cellular mechanism for PEVAC, and this could explain the unresponsiveness to anti-VEGF treatments.<sup>1</sup> In Mrejen et al. study, resolution of exudation was achieved in two cases, one after 13 anti-VEGF intravitreal injections and the other after laser photocoagulation.<sup>7</sup> In our patient, bilateral anti-VEGF therapy did not show any anatomical or functional improvement after a single intravitreal injection of anti-VEGF. In this entity anti-VEGF responses may be variable, and often not achieved, while some patients show a late anti-VEGF response, suggesting that further investigations are required to better understand the prognosis and management of this rare entity.

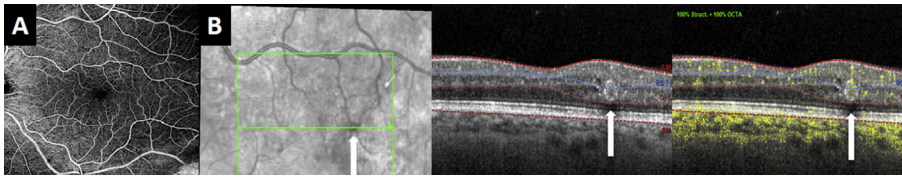
In Sacconi et al. study, there was no evidence of progression of PEVAC lesions into the RPE during follow-up in any of the 15 cases, and the lesions remained confined to the retinal layers.<sup>2</sup> Seven patients were followed for  $13.0 \pm 10.5$  months with no evidence of functional or anatomic changes. In our case, after 6 months follow-up, no anatomical nor functional worsening was observed in both eyes.

The presence of retinal microaneurysms is classically associated with diabetic retinopathy, but also present in other retinal vascular disorders such as retinal vein occlusion, inflammatory diseases, ocular ischemic syndrome, and macular telangiectasia. Our patient had no history of systemic disease other than a mitral valve replacement due to mitral valve regurgitation. No signs of any other ocular condition were observed. In cases with idiopathic macular telangiectasia type 1, also known as aneurysmal telangiectasia, patients tend to be younger and present with multiple capillary, venular and arteriolar aneurysms, with intraretinal microangiopathy. Typically, both the superficial and the



**Fig. 4.** A - B) Optical coherence tomography angiography (OCTA) shows aneurysmal lesions in the superficial capillary plexus in the  $3 \times 3$  and  $9 \times 9$  mm exploration area. (C to E) OCT shows the three typical perifoveal exudative vascular anomalous complex (PEVAC) lesions (as round hyperreflective intraretinal structures with a dark lumen containing variably reflective material) in the right eye, with flow signal correlating with the intraretinal aneurysmal lesion in the fundus and structural OCT.





**Fig. 5.** A) Optical coherence tomography angiography (OCTA) did not show any abnormality in the  $9 \times 9$  mm exploration area. (B) OCT shows the unifocal perifoveal exudative vascular anomalous complex lesion in the left eye lesions (as round hyperreflective intraretinal structures with a dark lumen containing variably reflective material) with flow signal correlating with the intraretinal aneurysmal lesion in the fundus and structural OCT.

deep capillary plexus are affected and it is associated with intraretinal cystic changes and lipid deposition.<sup>1,2</sup> A profound exudation is constantly observed and some patients show minimal, patchy nonperfusion or capillary ischemia. Furthermore, macular telangiectasia type 1 typically responds well to anti-VEGF treatment.

#### 4. Conclusion

In conclusion, we describe a case of an uncommon and poorly known macular disorder such as PEVAC, with an atypical bilateral and multifocal presentation, with multiple lesions in one eye. To our knowledge, this is the first reported case of bilateral PEVAC lesions. Hence, PEVAC should be included in the differential diagnosis of perifoveal aneurysmal abnormalities with bilateral intraretinal cystic changes. Further studies are warranted in order to investigate the origin and mechanisms associated with this entity as well as the optimal management.

#### Patient consent

Written informed consent was obtained to publish the case report.

#### Disclosures

The following authors have no financial disclosures: (JIFV, BBB, MJS, LLG, JDL).

RDM is consultant to Heidelberg Engineering, Novartis and Allergan and receives research support from Genentech/Roche and Thrombogenics.

#### Funding

No grant or financial support was received for this submission.

#### Authorship

All authors attest that they meet the current ICMJE criteria for Authorship.

#### Acknowledgements

None.

#### References

1. Querques G, Kuhn D, Massamba N, Leveziel N, Querques L, Souied EH. Perifoveal exudative vascular anomalous complex. *J Fr Ophthalmol.* 2011;34(8) 559.e1-4.
2. Sacconi R, Freund KB, Yannuzzi LA, et al. The expanded spectrum of perifoveal exudative vascular anomalous complex. *Am J Ophthalmol.* 2017;184:137-146.
3. Zhang Z, Xu L, Wu Z, Zhang J. Case report: perifoveal exudative vascular anomalous complex in a Chinese patient with diabetes mellitus. *Optom Vis Sci.* 2019;96(7):531-535.
4. Kim JH, Kim JW, Kim CG, Lee DW. Characteristics of perifoveal exudative vascular anomalous complex in Korean patients. *Semin Ophthalmol.* 2019;34(5):353-358.
5. Siedlecki J, Vounotrypidis E, Vogt D, Wolf A, Priglinger SG, Schumann RG. Lamellar hole-associated epiretinal proliferation presenting with perifoveal exudative vascular anomalous complex. *Am J Ophthalmol Case Rep.* 2019;14:112-116.
6. Venkatesh R, Yadav NK, Bavaharan B, Prabhu V, Sinha S. Multimodal imaging in perifoveal exudative vascular anomalous complex with co-existent diabetic retinopathy. *Clin Exp Optom.* 2019;102(5):528-532.
7. Mrejen S, Le HM, Nghiem-Buffer S, Tabary S, Quantel G, Cohen SY. Insights into perifoveal exudative vascular anomalous complex. *Retina.* 2020;40(1):80-86.
8. Ayachit AG, Sacconi R, Ayachit GS, Joshi S, Querques G. Perifoveal exudative vascular anomalous complex-like lesion as a complication of prepapillary arterial loops. *Ophthalmic Surg Lasers Imaging Retina.* 2018;49(12):974-978.