

Available online at [www.sciencedirect.com](http://www.sciencedirect.com)

ScienceDirect

journal homepage: [www.elsevier.com/locate/radcr](http://www.elsevier.com/locate/radcr)

## Case report

# Pulmonary cryptococcosis misdiagnosed as lung cancer in a man with normal immune function: A case report <sup>☆,☆☆</sup>

Shixiang Qiu<sup>a</sup>, Chao Chen<sup>a,b</sup>, Ya Li<sup>a,b</sup>, Chao Li<sup>a</sup>, Ziyu Tang<sup>a</sup>, Yunguo Liao<sup>a</sup>, Dan Deng<sup>a</sup>, Liming Zhong<sup>a,\*</sup>

<sup>a</sup> Department of Interventional Radiology, Central Hospital of Nanchong, The Second Clinical School of North Sichuan Medical College, Nanchong, 637000, Sichuan Province, P.R. China

<sup>b</sup> School of Medical Imaging, North Sichuan Medical College, Nanchong, 637000, Sichuan Province, P.R. China

## ARTICLE INFO

## Article history:

Received 17 December 2021

Revised 8 January 2022

Accepted 12 January 2022

## Keywords:

Pulmonary cryptococcosis, Lung cancer, CT

FDG-PET, Opportunistic infection

## ABSTRACT

Pulmonary cryptococcosis is an opportunistic infection of cryptococcus both in immunocompetent and immunocompromised patients, who suffered from HIV infection, organ transplantation, diabetes mellitus, corticosteroid or immunosuppressive therapy, and malignancy. Pulmonary cryptococcosis is the commonest location of non-central nervous system cryptococcosis and usually presents with nonspecific symptoms. It often shows shadows on the lung, which makes it difficult to distinguish it from lung cancer. Here we report a case of a 52-year-old man with pulmonary cryptococcosis, who was misdiagnosed as lung cancer. Clinicians need to consider the possibility of pulmonary cryptococcosis and the importance of lung biopsy when treating a patient with a normal immune function that has isolated pulmonary nodules. This case also indirectly illustrates the importance of percutaneous lung biopsy in patients with isolated pulmonary nodules.

© 2022 The Authors. Published by Elsevier Inc. on behalf of University of Washington.

This is an open access article under the CC BY-NC-ND license (<http://creativecommons.org/licenses/by-nc-nd/4.0/>)

## Introduction

Pulmonary cryptococcosis is commonly seen in immunocompromised patients. Immunocompromised conditions such as HIV infection, organ transplantation, diabetes mellitus, corticosteroid or immunosuppressive therapy, and malignancy are all conditions closely linked with pulmonary cryptococ-

cosis [1,2]. But it has become an emerging disease in immunocompetent patients in recent years. A 20-year clinical retrospective analysis from China revealed that 60% of pulmonary cryptococcosis cases were diagnosed as immunocompetent non-HIV patients [3]. Pulmonary cryptococcosis could manifest to isolate nodule or multiple nodules in the lung. Pulmonary cryptococcosis has often been initially misdiagnosed as lung cancer as some nodules also were positive about

<sup>☆</sup> Acknowledgments: There is no fund support for this article.

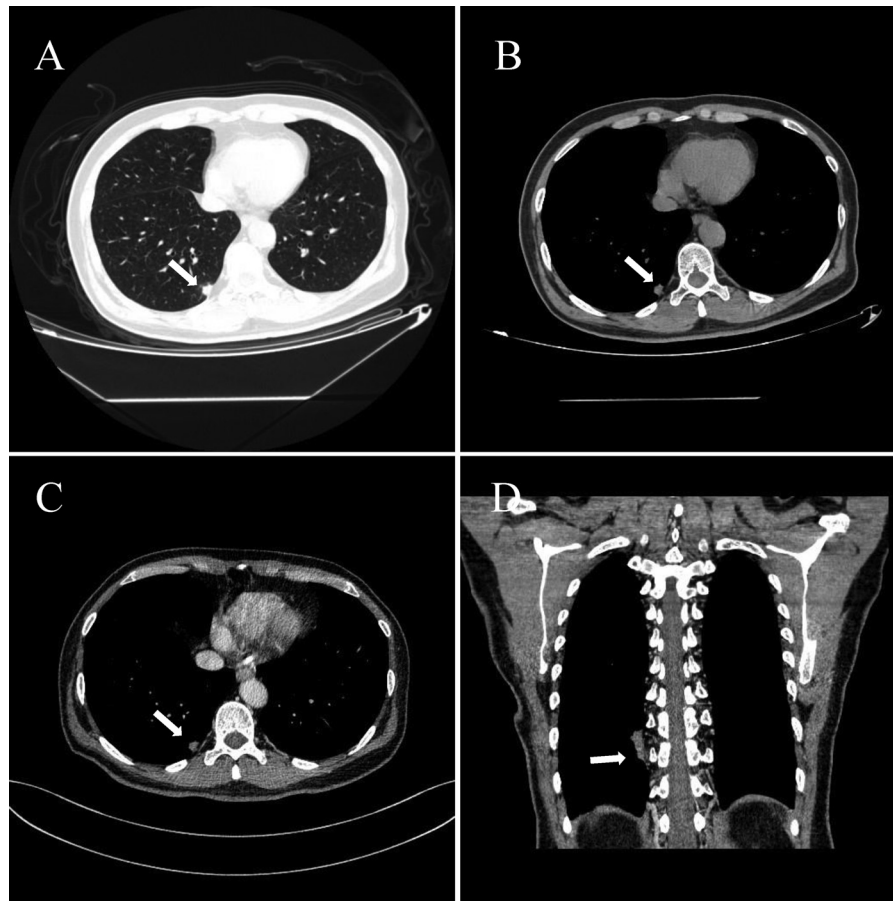
<sup>☆☆</sup> Competing interests: The authors declare that there were no conflicts of interest of this case report.

\* Corresponding author.

E-mail address: [li\\_ming\\_zhong@126.com](mailto:li_ming_zhong@126.com) (L. Zhong).

<https://doi.org/10.1016/j.radcr.2022.01.017>

1930-0433/© 2022 The Authors. Published by Elsevier Inc. on behalf of University of Washington. This is an open access article under the CC BY-NC-ND license (<http://creativecommons.org/licenses/by-nc-nd/4.0/>)



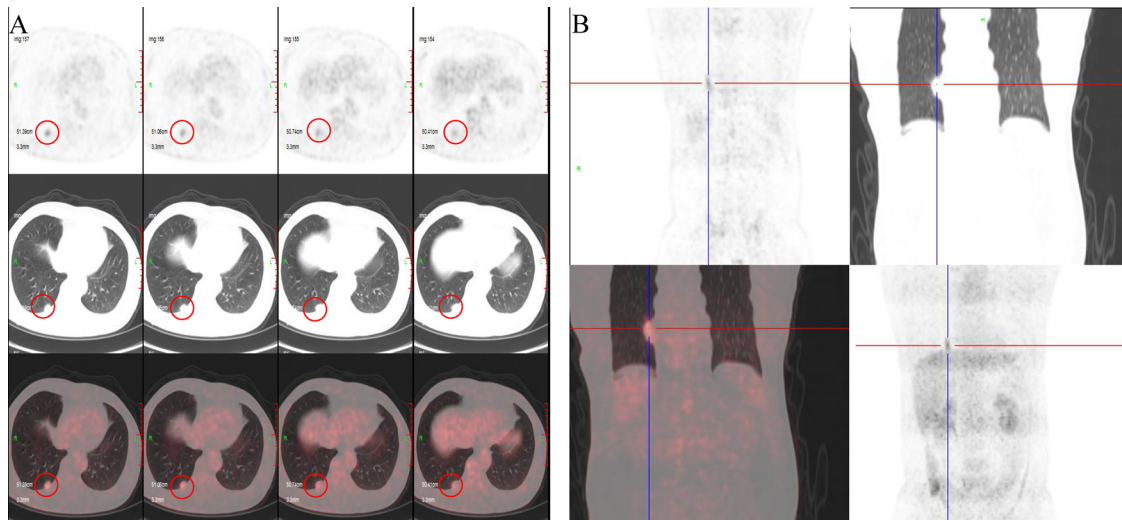
**Fig. 1 – Images of CT, an isolate shadow showed in lower lobe of right lung. (A) and (B) axial image non-enhanced CT of pulmonary window and mediastinal window, respectively; (C) axial image of enhanced CT; (D) the coronal MPR image. The white arrows showed the lesion.**

F-fluorodeoxyglucose positron emission tomography [4]. The article reported a case of isolated pulmonary cryptococcosis that was misdiagnosed as lung cancer during the Corona Virus Disease 2019 (COVID-19) pandemic.

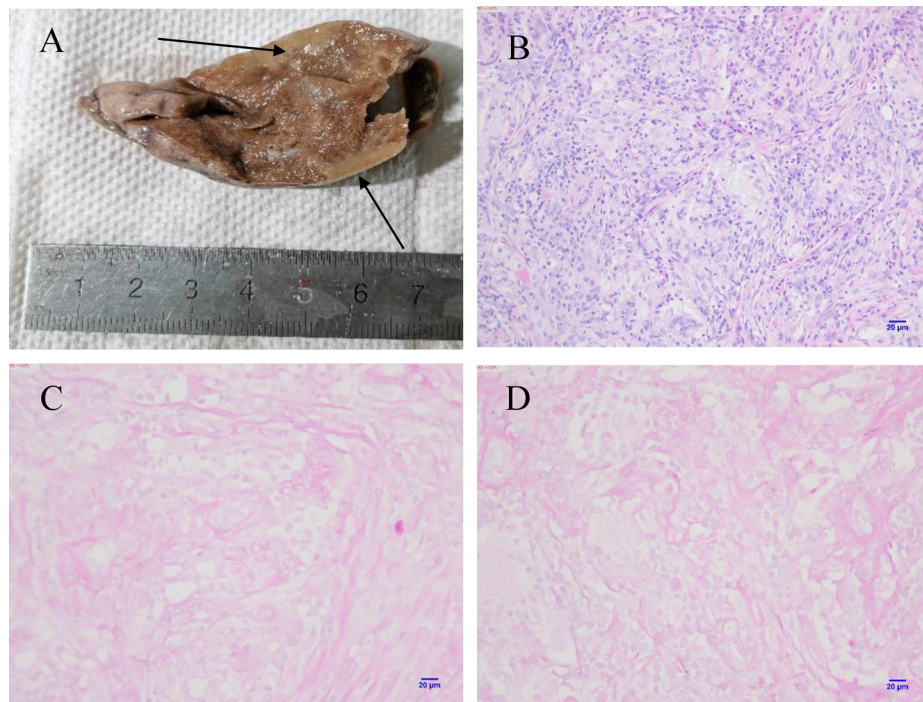
### Case report

A 52-year-old male patient came to the hospital due to cough accompanied by cough yellow phlegm, without fearless of cold, shivering, and high fever, which had lasted for one month in February 2020. The patient worked as a government official and had a history of smoking for over 30 years. A chest CT examination revealed that an 18mm irregular nodule in diameter distributed in subpleural of right lower lung and some enlarged lymph nodes in the mediastinum, the larger one was about 16 mm in diameter (Fig. 1). The radiologists suggested that both peripheral lung cancer and chronic infection can't be excluded, and a biopsy was necessary. The patient was admitted to the hospital for further examination. The results of tumor markers of lung were as follows: carcinoembryonic antigen 1.67 ng/ml (0-5.00 ng/ml), progastrin releasing peptide 56.16 pg/ml (0-68.3 pg/ml), neuron-specific enolase 13.10 ng/ml (0-15.2

ng/ml), squamous cell carcinoma antigen 1.53 ng/ml (0-1.5 ng/ml) and CYFRA21-1 3.61 ng/ml (0-3.3 ng/ml). The results of three times Mycobacterium tuberculosis cultures were negative, and tuberculosis didn't consider. The male accepted several antibacterial drugs, such as levofloxacin (500 mg ivgtt QD) and piperacillin (2 g ivgtt Q12 hours) for 14 days. After 14 days of anti-inflammatory treatment, an enhanced CT detection was performed, which showed that the lesion has no obvious change. Re-examination of serum concentrations of the lung tumor markers showed that squamous cell carcinoma antigen 2.81 ng/ml (0-1.5 ng/ml) and CYFRA21-1 3.73 ng/ml (0-3.3 ng/ml) increased more highly. A detection of 18F-fluorodeoxyglucose-positron emission tomography (18F-FDG PET/CT) was performed, and the result of 18F-FDG PET/CT revealed that higher FDG uptake, which gave a high suspicion of lung cancer (Fig. 2). A percutaneous lung biopsy was recommended, but the suggestion was be refused. Meanwhile a thoracoscopic surgery was performed. Pathologically, several spherical fungi from the necrotic substance of the tumor were confirmed positive by HE staining and periodic acid-Schiff (Fig. 3). Finally, the patient was diagnosed with isolated pulmonary cryptococcosis and received antifungal therapy with itraconazole (200 mg po BID). Up to now, the lesion has not recurred, but the quality of his life has been affected more or less according to the patient description.



**Fig. 2** – A 52-y-old man with pulmonary cryptococcosis. Axial fused PET/CT(A), MIP image(B), showed intense FDG uptake in lower lobe of right lung. The circle shows the lesion in picture A.



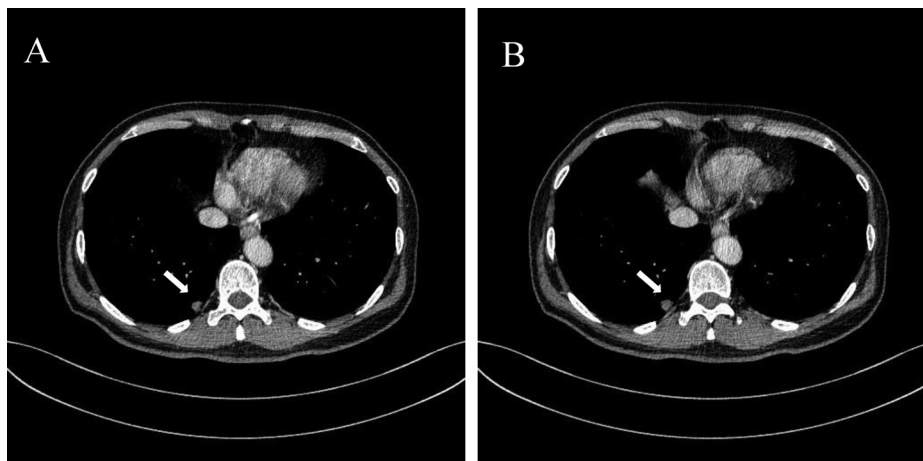
**Fig. 3** – Pathological tissue images. (A) Thoracoscopic partial lung resection of the lower lobe of the right lung revealed that the lesion was a white solid (black arrows showed). (B) Hematoxylin and eosin staining showed that the nodule was composed of necrotic substance and histiocytes, with lymphocyte infiltration (20X). (C, D) A number of spherical fungi in the necrotic substance of the nodule were confirmed positive by periodic acid-Schiff (20X).

## Discussion

As is known to us all, pulmonary cryptococcosis is an important opportunistic invasive mycosis in immunocompromised patients, especially those suffering from such as HIV infection, organ transplantation, diabetes mellitus, corticosteroid, or immunosuppressive therapy, and malignancy [5]. In Europe and

the United States about 80% of cryptococcosis cases are associated with HIV/AIDS [6]. Nonetheless, most patients with cryptococcosis are not infected with HIV in China [7]. The incidence of cryptococcosis in China is on the rise, and the fungal persistence and frequent disease relapse of cryptococcosis is the main clinical problem in the past years. Several studies suggested that the incidence of cryptococcosis in immunocompetent patients increased [8]. In this case, the patient was





**Fig. 4 – The comparison of CT before and after anti-inflammatory treatment, and the isolate shadow showed no obvious changes of lesion in lower lobe of right lung. (A) axial image non-enhanced CT before anti-inflammatory treatment; (B) axial image of enhanced CT after two-week anti-inflammatory treatment. The white arrows showed the lesion.**

immunocompetent without HIV infection or malignancy tumors. During the Corona Virus Disease 2019 outbreak, all Chinese responded to the government's call for segregation at home and did not get together, thus they often lacked exercise. Thus, the authors inferred that the main reason why the male had pulmonary cryptococcosis was the decrease of immunity and gave the chance of cryptococcus infection. A study reported that a major mental health burden of the public was heavy during the COVID-19 outbreak in China, and young people or healthcare workers were at a high risk of displaying psychological issues [9]. Psychological factors may play a certain role in the process of the patient's illness, the patient works as a government official, he needs to consider not only the safety of the people but also his family. Which may give him much pressure.

The most common means of cryptococcus causing infection in humans is via inhalation. The central nervous system and the lung are the two organs that comprise the main sites of cryptococcus infection [9,10,11]. Some rare sites infection also exists, for instance, skin, joint, muscle, liver, kidney [12]. Pulmonary cryptococcosis is the most common non-central nervous system infection in those aren't infected with HIV [13]. Pulmonary cryptococcosis usually presents with nonspecific symptoms such as cough, dyspnea, chest pain, and fever both in adults and children. The nonspecific symptoms of this disease are likely to cause delays in diagnosis and proper treatment resulting in further dissemination of cryptococcus infection, even misdiagnosis [14]. The radiological appearance of pulmonary cryptococcosis may mimic other clinical conditions such as other pulmonary infections caused by bacteria, mycobacteria, parasites, or viruses, malignancy [15]. It is difficult to distinguish cryptococcosis from cancer by computed tomography (CT). 18F-FDG PET/CT has gradually become a popular imaging modality for the differential diagnosis, staging, restaging, response evaluation, and follow-up of cancer. A study revealed that about 88% of patients, lung lesions showed high FDG uptake, thus mimicking a possible malignant condi-

tion [4]. In the present case, the patient presented a pulmonary nodule with elevated lung cancer markers and high uptake of 18F-FDG, which were difficult to distinguish from lung cancer. Furthermore, after two weeks of anti-inflammatory treatment, the CT scan showed no obvious changes of the lesion (Fig. 4) and the serum concentrations of the lung tumor markers were more highly, especially the squamous cell carcinoma antigen and CYFRA21-1. Thus, the patient was misdiagnosed with lung cancer and underwent surgical treatment. Fortunately, the patient recovered well.

The purpose of the treatment of pulmonary cryptococcosis is not only to control the symptoms and signs of the lung itself, but the most important is to prevent the spread of cryptococcal meningitis [14]. Blood culture, serum cryptococcal antigen test, and a lumbar puncture for CSF examination including measurement of the CSF opening pressure are routinely recommended, with additional investigations depending on the clinical presentation [16]. Due to the absence of prospective, randomized controlled trials or prospective cohort studies of patient outcomes, the definitive treatment recommendations of cryptococcosis are hampered. The treatment guidelines are based on retrospective case series, expert opinions [17].

The present case reminded us that shadow of the lung was a common sign in clinical work, which can attribute to many reasons, such as infections caused by bacteria, mycobacteria, parasites, fungus or viruses, malignancy, and so on. It deserves high attention and a high index of suspicion is necessary for infection of fungus. If it is difficult to identify the shadow in lung, the percutaneous lung biopsy should be performed. Both doctors and patients need to pay more attention to percutaneous lung biopsy. It suggested that clinicians should be alert to cryptococcal infection during the diagnosis of similar diseases, especially for the people with low immunity and other risk factors. Clinicians should try to determine the treatment plan after comprehensive evaluation for patients to avoid blind surgical treatment, which increases the risk of operation and patients' pain.

---

## Ethics statement

Ethics approval was not required for this study.

---

## Patient consent

The patient of this case approved the publication of his information.

---

## REFERENCES

- [1] Setianingrum F, Rautemaa-Richardson R, Denning DW. Pulmonary cryptococcosis: a review of pathobiology and clinical aspects. *Med Mycol* 2018;57:133–50.
- [2] Liu K, Ding H, Xu B, et al. Clinical analysis of non-AIDS patients pathologically diagnosed with pulmonary cryptococcosis. *J Thorac Dis* 2016;8:2813–21.
- [3] Hou X, Kou L, Han X, Zhu R, Song L, Liu T. Pulmonary cryptococcosis characteristics in immunocompetent patients—A 20-year clinical retrospective analysis in China. *Mycoses* 2019;62:937–44. doi:10.1111/myc.12966.
- [4] Si-yun Wang, Gang Chen, Dong-lan Luo, Dan Shao, En-tao Liu, Taotao Sun, et al. 18F-FDG PET/CT and contrast enhanced CT findings of pulmonary cryptococcosis. *Eur J Radiol* 2022. doi:10.1016/j.ejrad.2017.02.008.
- [5] Rajasingham Radha, Smith Rachel M, Park Benjamin J, Jarvis Joseph N, Govender Nelesh P, Chiller Tom M, et al. Global burden of disease of HIV-associated cryptococcal meningitis: an updated analysis[J]. *Lancet Infect Dis* 2017;17:873–81 .
- [6] McClelland EE, Hobbs LM, Rivera J, et al. The role of host gender in the pathogenesis of *Cryptococcus neoformans* infections. *PLoS One* 2013;8(5):e63632.
- [7] Chen M, Xu Y, Hong N, et al. Epidemiology of fungal infections in China. *Front Med* 2018;12(1):58–75.
- [8] Fang LF, Zhang PP, Wang J, et al. Clinical and microbiological characteristics of cryptococcosis at an university hospital in China from 2013 to 2017. *Braz J Infect Dis* 2020;24(1):7–12.
- [9] Zhao N, Huang Y. Chinese mental health burden during COVID-19 outbreak: a web-based cross-sectional survey. *Asian J Psychiatry* 2020. doi:10.1016/j.ajp.2020.102052.
- [10] Taniwaki Masaya, Yamasaki Masahiro, Ishikawa Nobuhisa, et al. Pulmonary cryptococcosis mimicking lung cancer. *Lancet Infect Dis* 2019;19:1033.
- [11] Shirley Rhett M, Baddley John W. Cryptococcal lung disease. *Curr Opin Pulm Med* 2009;15:254–60.
- [12] Ngoc Quan Phan Mariantonieta, Tirado Sigrid MC, et al. Cutaneous and pulmonary cryptococcosis in an immunocompetent patient[J]. *J Dtsch Dermatol Ges* 2019;17(12):1283–6.
- [13] Antinori Spinello. New insights into HIV/AIDS-associated cryptococcosis. *ISRN AIDS* 2013;2013:471363.
- [14] Diaz JH. The disease ecology, epidemiology, clinical manifestations, and management of emerging *Cryptococcus gattii* complex infections. *Wilderness Environ Med* 2020;31(1):101–9.
- [15] Wang D, Wu C, Gao J, et al. Comparative study of primary pulmonary cryptococcosis with multiple nodules or masses by CT and pathology[J]. *Exp Ther Med* 2018;16(6):4437–44.
- [16] Banshodani M, Marubayashi S, Shintaku S, et al. Isolated pulmonary cryptococcosis confused with lung tumor 5 years after kidney transplantation: a case report. *Transplant Proc* 2019;51(2):561–4.
- [17] Harris JR, Lindsley MD, Henchaichon S, et al. High prevalence of cryptococcal infection among HIV-infected patients hospitalized with pneumonia in Thailand. *Clin Infect Dis* 2012;54(5):e43–50.