



Original Article

Use of adrenalin with lidocaine in hand surgery^{☆,☆☆}



Ronaldo Antonio de Freitas Novais Junior*, Jorge Ribamar Bacelar Costa, Jose Mauricio de Morais Carmo

Pedro Ernesto University Hospital (HUPE), Universidade do Estado do Rio de Janeiro (UERJ), Rio de Janeiro, RJ, Brazil

ARTICLE INFO

Article history:

Received 12 July 2013

Accepted 2 September 2013

Available online 18 September 2014

Keywords:

Local anesthesia

Adrenalin

Surgery

Hand

Fingers

ABSTRACT

Objective: Because of the received wisdom within our setting that claims that local anesthesia should not be used with adrenalin in hand surgery; we conducted a study using lidocaine with adrenalin, to demonstrate its safety, utility and efficacy.

Methods: We conducted a prospective study in which, in wrist, hand and finger surgery performed from July 2012 onwards, we used local anesthesia comprising a 1% lidocaine solution with adrenalin at 1:100,000. We evaluated the quantity of bleeding, systemic alterations, signs of arterial deficit and complications, among other parameters. We described the infiltration techniques for specific procedures individually.

Results: We operated on 41 patients and chose to describe separately the raising of a lateral microsurgical flap on the arm, which was done without excessive bleeding and within the usual length of time. In only three cases was there excessive bleeding or use of bipolar tweezers. No systemic alterations were observed by the anesthesiologists or any complications relating to ischemia and necrosis in the wounds or in the fingers, and use of tourniquets was not necessary in any case.

Conclusions: Use of lidocaine with adrenalin in hand surgery was shown to be a safe local anesthetic technique, without complications relating to necrosis. It provided efficient exsanguination of the surgical field and made it possible to perform the surgical procedures without using a pneumatic tourniquet, thereby avoiding its risks and benefiting the patient through lower sedation.

© 2014 Sociedade Brasileira de Ortopedia e Traumatologia. Published by Elsevier Editora Ltda. Este é um artigo Open Access sob a licença de [CC BY-NC-ND](https://creativecommons.org/licenses/by-nc-nd/4.0/)

Uso da adrenalina com lidocaína em cirurgia da mão

RESUMO

Objetivo: Por causa do dogma existente em nosso meio de que não deve ser usada anestesia local com adrenalina na cirurgia da mão, fizemos um estudo com o uso de lidocaína com adrenalina para demonstrar sua segurança, utilidade e eficácia.

Palavras-chave:

Anestesia local

Adrenalina

[☆] Please cite this article as: de Freitas Novais Junior RA, Bacelar Costa JR, de Morais Carmo JM. Uso da adrenalina com lidocaína em cirurgia da mão. Rev Bras Ortop. 2014;49(5):452-60.

^{☆☆} Work developed at the Pedro Ernesto University Hospital and the Piquet Carneiro Polyclinic, Universidade do Estado do Rio de Janeiro, Rio de Janeiro, RJ, Brazil.

* Corresponding author.

E-mail: ronaldonovaisjr@gmail.com, ronaldofluzao@gmail.com (R.A. de Freitas Novais Junior).

<http://dx.doi.org/10.1016/j.rboe.2014.09.006>

2255-4971/© 2014 Sociedade Brasileira de Ortopedia e Traumatologia. Published by Elsevier Editora Ltda.

Este é um artigo Open Access sob a licença de [CC BY-NC-ND](https://creativecommons.org/licenses/by-nc-nd/4.0/)

Cirurgia
Mão
Dedos

Métodos: Fizemos um trabalho prospectivo no qual, a partir de julho de 2012, usamos como anestesia local uma solução de lidocaína 1% com adrenalina 1:100.000 nas cirurgias em punho, mão e dedos e avaliamos a quantidade de sangramento, as alterações sistêmicas, os sinais de déficit arterial e as complicações, entre outros parâmetros. Descrevemos as técnicas de infiltração de procedimentos específicos individualmente.

Resultados: Operamos 41 pacientes e optamos por descrever separadamente um levantamento de retalho microcirúrgico lateral do braço, que ocorreu sem sangramento excessivo e no tempo habitual. Em apenas três casos houve sangramento e uso de pinça bipolar excessivos. Não houve alterações sistêmicas verificadas pelos anesthesiologistas ou complicações relacionadas à isquemia e necrose nas feridas ou nos dedos e em nenhum caso foi necessário o uso do torniquete.

Conclusões: O uso de lidocaína com adrenalina na cirurgia da mão mostrou-se técnica anestésica local segura, sem complicações relacionadas à necrose, forneceu campo cirúrgico exsanguê eficiente, permitiu os procedimentos cirúrgicos sem uso do torniquete pneumático, evitou seus riscos e beneficiou os pacientes com menor sedação.

© 2014 Sociedade Brasileira de Ortopedia e Traumatologia. Publicado por Elsevier

Editora Ltda. Este é um artigo Open Access sob a licença de CC BY-NC-ND

Introduction

“Adrenaline should never be injected into the finger, because of the gangrene that frequently results.” This affirmation, which appears in Bunnell’s textbook *Surgery of the hand* (1956), serves to demonstrate the extent to which adrenaline in association with a local anesthetic has been rejected for hand surgery.¹ Despite studies showing that the true cause of digital gangrene is not adrenaline, such as the work by Thomson,² the myth revolving around the causal relationship between adrenaline and necrosis persists until today.

It is important to break down this dogma, because the method most used for maintaining the operative field free from blood (pneumatic tourniquets) may cause difficulties, given that patients can only tolerate this for short periods, of less than 30 min on average.³ Thus, greater sedation is needed and the pneumatic tourniquet has to be deflated, with a wait before inflating it again so as to avoid complications such as ischemia and muscle dysfunction, along with other possible complications.⁴

Use of adrenaline provides the advantages of a faster start and longer duration of anesthesia, a longer-lasting surgical field without blood, without interruptions, and a lower concentration of anesthesia for achieving pain control.⁵ This makes it possible to perform the surgery with a lower dosage of sedatives and also facilitates certain surgical procedures, such as tenolysis and tenorrhaphy, thus demonstrating the intraoperative efficacy of adrenaline.⁶

With the aim of demonstrating the various advantages of using lidocaine with adrenaline in hand surgery, given the lack of evidence of occurrences of digital necrosis in the literature, and also because of the impressive strength of this dogma in our setting and the scarcity of this subject in the Brazilian literature, we decided to conduct this study in order to demonstrate the safety and efficacy of this method in hand surgery.

We chose to always have an anesthetist present during our surgical procedures, which were all performed in a surgical center. Thus, our study differed from those conducted in

other countries, without an anesthetist and with procedures done in an outpatient environment, which we judged not to be applicable to our country, because of the legislation and the behavior of our patients in the light of the situation of tension that the procedures involve.

Methods

Starting on July 6, 2012, patients at our institution and in private hospitals underwent the method.

Patients undergoing surgery as a result of complications (for example, recurrence of carpal tunnel syndrome or synovial cysts), or who presented poor peripheral perfusion before the surgery, histories of vascular diseases or contraindications to anesthetics, were excluded.

The solution used was 1% lidocaine with adrenaline at 1:100,000. The standard was the solutions described by Lalonde,⁶ who used them in cases in which less than 50 mL was necessary. We used flasks of 20 mL of 1% lidocaine and added 0.2 mL of adrenaline to obtain the solution. If a greater volume is necessary, Lalonde recommends that the concentrations should be more diluted (Table 1), with a view to maintain a safety limit for lidocaine with adrenaline of less than 7 mg/kg of weight.

Table 1 – Dosage and concentration of lidocaine with adrenaline to be injected into the forearm, hand and fingers.

Volume of adrenaline and lidocaine solution needed	Adrenaline and lidocaine concentration
Less than 50 mL	1% lidocaine with adrenaline at 1:100,000
Between 50 and 100 mL	1/2% lidocaine with adrenaline at 1:200,000
Between 100 and 200 mL	1/4% lidocaine with adrenaline at 1:400,000

Reproduced from Lalonde.⁶

Initially, we infiltrated the desired area after putting the fields into place, although in a few cases we did the infiltration before placing the fields, in order to make the process more dynamic. We observed that the ideal time for starting to make the incision was at least 15 min later, when the skin had already undergone a change in coloration in the area of the incision, becoming lighter in tone (more whitish), thereby leaving the field exsanguinated and anesthetized in order to perform the planned surgical procedure. At the time of infiltration, all the patients were under sedation and were being monitored by the anesthetist. We had the substance phenolamine available, in case it was necessary to reverse any situation of severe ischemia that might develop. The dose to be used would be 1 mg in 1 mL of 0.9% physiological serum.

We developed a standardized evaluation form to cover all the cases and broach a variety of parameters, as described in [Annex 1](#).

The form began with the date and type of surgery and the patient's identification. Following this, preoperative data were evaluated.

Bleeding during the operation was addressed in accordance with a scale created by our group, graded thus: 3 – excessive bleeding (halting progress in the operation unless a tourniquet was used); 2 – moderate (making it difficult but not impossible

to continue without using a tourniquet); and 1 – minimal (bleeding similar to that of surgery with a tourniquet).

Use of bipolar tweezers: yes or no; if positive, this was graded as 1 – minimal, 2 – normal or 3 – excessive.

Use of a tourniquet was assessed in terms of situations in which the tourniquet had to be inflated during the surgery.

Intraoperative pain was assessed according to the patient, the anesthetist (in terms of alterations of vital signs, for example) and the surgeon (in terms of the patient's reactions), and graded as intense, moderate, minimal or absent.

Systemic alterations were evaluated by the anesthetist by describing alterations to vital signs, neurological signs or any clinical interferences.

The other parameters, which were self-explanatory, can be seen in [Annex 1](#).

Regarding the infiltration technique in cases of carpal tunnel syndrome, we first infiltrated about 10 mL, at around 4 cm proximal to the wrist flexion crease, in parallel with the ulnar border of the long palmar tendon, when present, under the fascia of the forearm, in order to bathe the space between the median and ulnar nerves ([Fig. 1A](#)). Around another 10 mL of the solution was injected into the incision site, advancing slowly without letting the needle go beyond 3–4 mm of the white tumescent subcutaneous tissue ([Fig. 1B and C](#)).

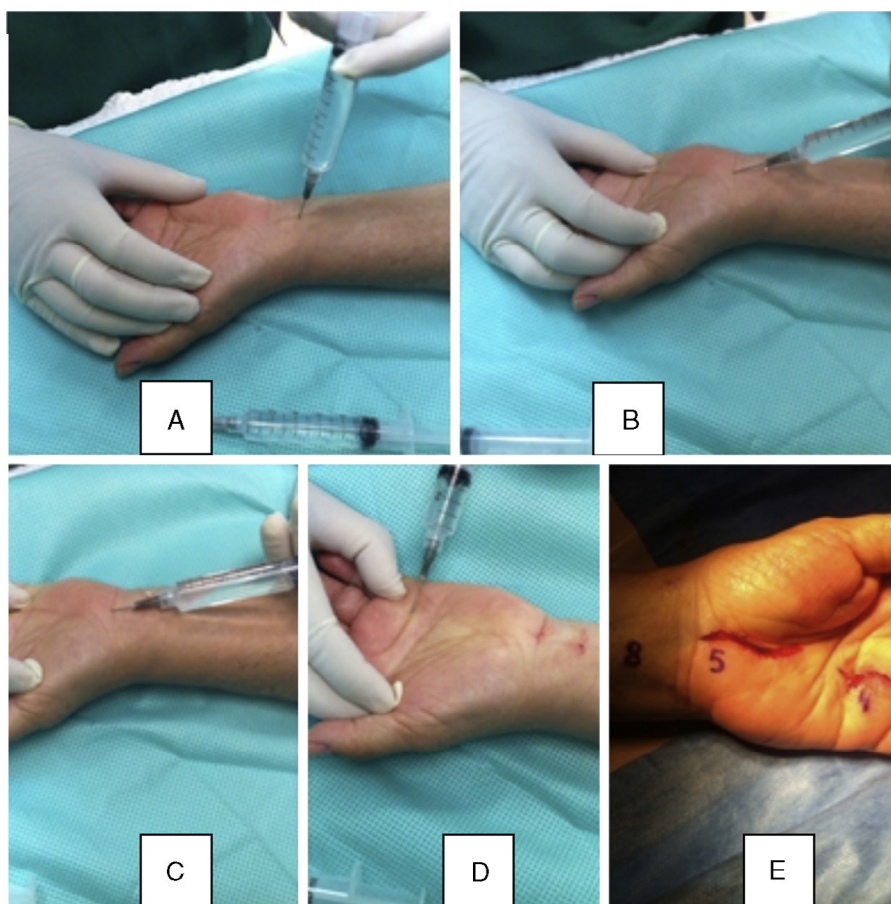


Fig. 1 – Infiltration of anesthesia in a patient who underwent surgical treatment for carpal tunnel syndrome and trigger finger. (A) Infiltration under the fascia from the ulna in the forearm to the long palmar tendon. (B) and (C) Infiltration at the site of incision for carpal tunnel syndrome. (D) Infiltration for surgical treatment to release the trigger finger, at the site of the incision. (E) Volume in mL used for each infiltration.

In cases of trigger finger, around 4 mL of the solution was injected into the fat under the center of the incision. The A1 pulley was released and the patient was able to view active finger movements that were made intraoperatively (Fig. 1D).

In the operations on fingers, anesthesia was applied at the base, on the midline and in the digital palmar crease, which could be complemented distally (Fig. 2A-C).

In cases of Quervain's tendinopathy, 10 mL of the solution was injected proximally and also into the tendon sheath (Fig. 2D and E).

In cases of Dupuytren's contracture, a greater volume (10 mL) was injected into the most proximal locality of the incision that was to be made, and then the remainder was injected into the incision site in the hand and fingers.

In the other cases, the locality of the incision was infiltrated proximally to distally. According to Lalonde,⁶ if the locality of the incision does not undergo infiltration, it will bleed more than the area infiltrated with adrenaline.

Results

We operated on 41 patients (18 men and 23 women). Of these, 18 underwent surgical treatment for carpal tunnel syndrome. In two of these cases, this was done in association with

surgical treatment for trigger finger. Six patients underwent surgical treatment for trigger finger (seven fingers). The other cases can be seen in Table 2.

There was one case that we have described separately, in which we performed an additional application of the technique. This consisted of raising a lateral microsurgical fasciocutaneous flap from the arm, with accompanying skin of dimensions 9 cm × 6 cm, which was transferred to cover an area of tumor resection on the contralateral hemiface, without using a pneumatic cuff. The patient was under general anesthetic and it was possible to raise the flap and dissect the 6 cm length of the posterior collateral radial vascular pedicle without additional difficulty and within the usual length of time for obtaining a flap. We have not placed the data on this patient with the data on the other patients because this would distort the data, given that the other surgical procedures were of much smaller proportions.

The patients' mean age was 52 years (range: 15-81); the mean waiting time between the infiltration and the incision was 15 min (range: 2-30); the mean duration of the surgery was 40 min (range: 10-150); and the mean volume of solution infiltrated was 14.6 mL (range: 4-20) for the conventional procedures and 80 mL into the lateral flap of the arm. Bipolar tweezers were not used in 12 patients, minimally used in 16, normally used in 10 and excessively used in three.

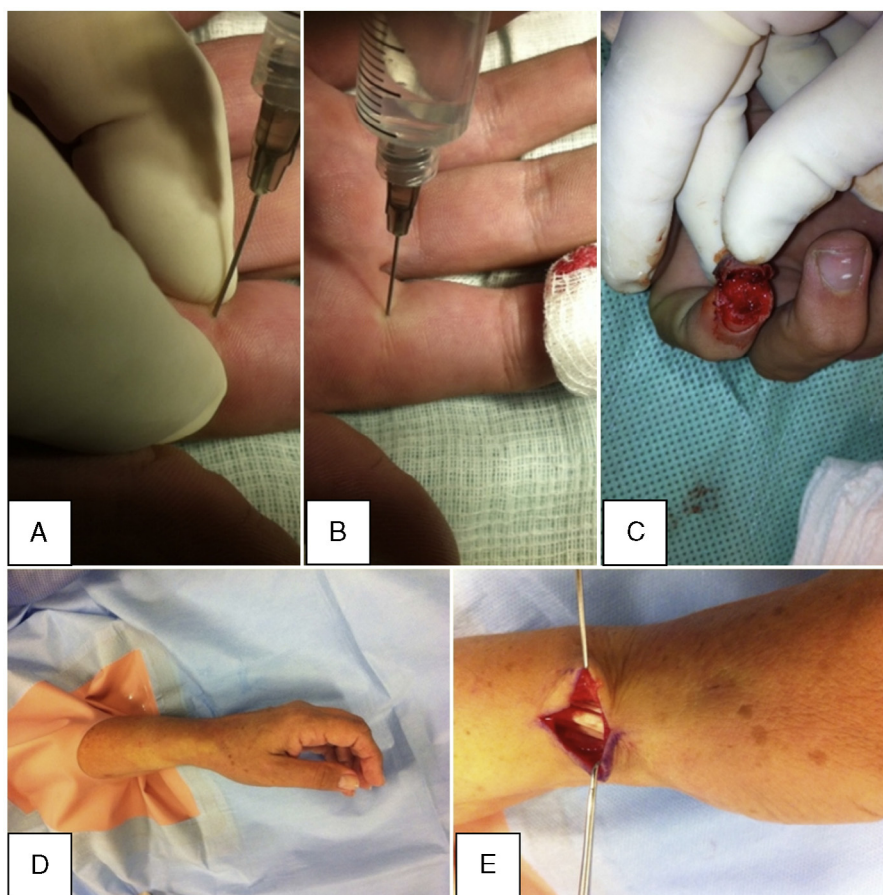


Fig. 2 – (A) and (B) Anesthesia at the base of the finger, at its midline and at the digital palmar crease, with traction by the surgeon's fingers to facilitate entry and diffusion of the anesthetic. (C) Effective ischemia in the area of the lesion, at the fingertip. (D) Whitened area at the site of infiltration of the solution for surgical treatment of Quervain's tendinopathy. (E) Effective exsanguination of the surgical field, with the first compartment of the extensor released.

Table 2 – Surgical procedures performed.

Carpal tunnel syndrome	18
Trigger finger	6 patients (7 fingers)
Tumor formation in the hand	1
Tumor formation in a finger	2
Tumor formation in the wrist	1
Quervain's tendinitis	3
Removal of Kirschner wires from the wrist	2
Removal of Kirschner wires from the hand	3
Tenorrhaphy of the long flexor of the thumb + microneurorrhaphy of the ulnar digital nerve of the thumb	1
Release of the proximal interphalangeal joint	1
Tenorrhaphy of the long extensor of the thumb	1
Tenorrhaphy of the common extensors and the index finger extensor	1
Nail bed repair	1
Release of Dupuytren's contracture	1
Osteosynthesis of fracturing of the 5th metacarpal using a plate	1

The bleeding was minimal in 32 cases, moderate in six and excessive in three. Two of these cases of excessive bleeding comprised patients with chronic kidney failure, in surgical treatments for carpal tunnel syndrome ipsilateral to the fistula.

In none of the cases was the procedure interrupted due to bleeding.

In all of the cases, the skin color had altered at the time of injecting the solution.

In none of the cases were there any signs of arterial deficit, intraoperative pain or significant systemic alterations. Nor was it necessary to introduce ischemia using a pneumatic tourniquet.

In two cases, there was a need for infiltration during the surgical procedure, at a deep level or in a cutaneous area that had not been envisaged in the initial infiltration.

As a complication, there was one case of injury to a digital nerve during fasciectomy, in surgical treatment for Dupuytren's contracture. This was treated by means of microneurorrhaphy during the same surgical procedure.

There were no cases of necrosis, hematoma or any other postoperative complication.

The data are described individually in [Table 3](#).

Discussion

Prohibition of use of local anesthetics together with adrenaline for digital blocks is a surgical tradition.⁷ Most textbooks refer to the theory that the vasoconstriction induced by adrenaline leads to ischemia and necrosis.⁸ In the book *Green's Operative Hand Surgery – 5th edition*,⁹ in relation to use of adrenaline for digital blocks, the authors write: "to avoid compromising the blood supply to the fingers, adrenaline should not be used for digital blocks". However, in the 6th edition,¹⁰ the authors of the chapter "Anesthesia for Hand Surgery" cite the prospective randomized controlled trial by Wilhelmi, on 60 patients, in which there were no complications in any patient in either of the groups, prolonged pain control was achieved and there was lower bleeding and lower need for tourniquet

use during the procedure in the group with adrenaline (with lidocaine at 1:200,000).

Fitzcharles-Boweet et al.¹¹ reported that 59 cases of accidental injection of adrenaline at 1:1000 into fingers in autoinjectors had been described in the worldwide literature and that there had not been a single case of finger necrosis. The authors also injected solutions of 1:1000, 1:10,000 and 1:100,000 into their own fingers and there were no complications. One case of accidental injection of adrenaline at 1:1000 was reversed efficiently using phentolamine.¹²

There are descriptions in the literature of 48 cases of digital gangrene associated with adrenaline use with local anesthetic, and a study analyzing each of these cases was conducted.² Among the 21 patients in whom adrenaline was used, procaine was used in 18, cocaine in two and an unknown drug in one. In the cases without adrenaline, procaine was also used most frequently (13 out of 27), while an unknown drug was used in eight cases (probably procaine, because of the date of publication), cocaine was used in four cases, screen in one case and water in one case.

Denkler⁷ also analyzed all these cases and showed that much of the information was incomplete, regarding the use and concentrations of adrenaline, use of hot immersion baths (which caused burns in 14 cases), tourniquets, tight dressings, infections (11 cases) or preexisting medical conditions. In only four of the 21 cases that involved adrenaline was the concentration of the solution described.

Lalonde et al.¹³ conducted a prospective multicenter study in which nine hand surgeons in six cities prospectively reported their consecutive cases of injection of lidocaine and adrenaline at concentrations of 1:100,000 or lower, into hands and fingers. This resulted in 3110 patients without any type of finger tissue loss. In none of these cases was phentolamine necessary for reversing the vasoconstriction of the fingers.

The study by Nodwell and Lalonde¹⁴ demonstrated that phentolamine reliably reversed the vasoconstriction in the fingers caused by adrenaline, in an average time of one hour and 25 min.

Chowdhry et al.⁸ reported a retrospective study consisting of 1111 cases of hand and finger surgery, among which 611 cases received blocks of 1% lidocaine with adrenaline (1:100,000), without any complications of necrosis.

Sönmez et al.¹⁵ published a randomized controlled study in which blood gas parameters at the fingertips were compared with and without use of adrenaline, and found that there was no statistically significant difference.

Manne and Hammert¹⁶ reported that they routinely used lidocaine with adrenaline because of its safety, given that it decreased the need to use tourniquets and sedation and reduced the costs, as well as making it possible to evaluate the range of motion in tenorrhaphy and tenolysis procedures. It also increased the duration of the analgesic effect and diminished the need for opioids after the operation.

We did not find any studies that reported the use of adrenaline and lidocaine in hand surgery in the Brazilian literature, after investigating in the *Revista Brasileira de Ortopedia* (www.rbo.org.br), SciELO Brazil (www.scielo.br) and BIREME (www.bireme.br), which further motivated us towards conducting this study and future studies on this technique.

Table 3 – Description of the results.

P	Surg proc	Age	Sex	Bleed	B	WT (min)	DT (min)	A (mL)	Comorbidities
1	Carpal tunnel syndrome	49	F	1	1	2	30	20	SAH
2	Carpal tunnel syndrome	51	M	1	2	2	15	20	SAH + DM
3	Carpal tunnel syndrome	52	F	3	3	2	20	20	SAH + DM
4	Trigger finger (4th and 5th)	68	F	1	2	12	40	15	SAH
5	Trigger finger (4th)	72	M	1	2	12	30	8	X
6	Carpal tunnel syndrome + trigger finger (3rd)	72	F	2	2	10	35	25	SAH
7	Carpal tunnel syndrome	57	F	1	1	10	25	20	Hypo-T
8	Tenorrhaphy LFT in thumb zone II + ulnar digital microneurorrhaphy	22	M	2	X	10	120	20	X
9	Carpal tunnel syndrome	44	F	1	1	15	35	20	Hypo-T
10	Carpal tunnel syndrome	50	F	1	1	15	30	20	X
11	Trigger finger (4th)	81	M	1	1	10	20	4	X
12	Carpal tunnel syndrome	57	F	3	3	15	43	20	CKF (ipsilateral to fistula)
13	Carpal tunnel syndrome	46	M	3	3	15	42	20	CKF (ipsilateral to fistula)
14	Carpal tunnel syndrome	79	F	1	2	15	30	20	X
15	Carpal tunnel syndrome	51	F	2	2	15	40	20	Rheumatoid arthritis
16	Carpal tunnel syndrome	51	F	1	1	8	30	20	X
17	IFP joint contracture release 4th finger	43	F	1	1	15	150	10	X
18	Tenorrhaphy long extensor of thumb	61	M	1	1	15	60	20	SAH
19	Dupuytren's contracture 4th finger	47	M	2	1	15	60	20	DM
20	Right trigger thumb	41	F	2	1	15	40	8	X
21	Mucous cyst resection index finger	59	F	2	2	15	60	6	SAH
22	Quervain	42	F	1	2	15	25	10	X
23	Carpal tunnel syndrome	70	F	1	X	15	30	20	SAH
24	Dorsoradial wrist tumor resection	81	M	1	2	15	60	10	X
25	K-wire removal from 4th finger	28	M	1	X	10	15	4	X
26	Carpal tunnel syndrome	66	F	1	2	15	30	16	SAH
27	Hand tumor resection	56	F	1	1	15	30	8	SAH + hypo-T
28	Carpal tunnel syndrome + trigger finger (4th)	81	F	1	X	30	90	17	X
29	Osteosynthesis of fracture of 5th metacarpal using plate	19	M	1	X	30	40	20	X
30	Carpal tunnel syndrome	77	F	1	X	30	30	16	X
31	Carpal tunnel syndrome	51	M	1	X	30	40	20	X
32	Quervain	67	F	1	X	20	18	12	X
33	K-wire removal from neck of 5th metacarpal	62	M	1	X	20	20	6	X
34	K-wire removal from middle phalanx	22	M	1	X	20	10	4	X
35	Nail bed repair index finger	15	M	1	X	30	50	4	X
36	Quervain	28	F	1	X	20	15	4	X
37	Tumor removal from 3rd finger	52	M	1	1	15	46	5	X
38	K-wire removal from wrist	46	F	1	1	15	32	7	SAH + DM
39	Carpal tunnel syndrome	65	M	1	1	15	31	10	DM
40	K-wire removal from wrist	21	M	1	1	12	12	7	X
41	Tenorrhaphy of index finger extensors	31	M	1	1	15	65	15	X

P, patient; Surg proc, surgical procedure; M: male, F: female; Bleed, bleeding; B, bipolar; WT, waiting time; DT, duration of surgery; A, quantity of anesthetic solution with adrenalin; LFT, long flexor of thumb; K-wire, Kirschner wires; SAH, systemic arterial hypertension; DM, diabetes mellitus; Hypo-T, hypothyroidism; CKF, chronic kidney failure.

In our study, there were no cases of postoperative necrosis or hematoma among the 41 procedures. In no case did we have to use phentolamine to reverse the effects of the ischemia.

In the first three cases, we waited only two minutes between the anesthesia and the incision. Although excellent ischemia was obtained in the first two of these cases, abundant bleeding occurred in the third case, which stopped at the end of the procedure. Following this case, we then established a minimum of 10 min and subsequently 15 min. As a way of maintaining a minimum waiting time so as to allow the effect of the adrenaline to begin, we started to apply the anesthetic before placing the surgical fields. Through this action, we started to achieve a better ischemic effect. The interval of 15 min was sufficient in the majority of the situations. In most cases (28), bipolar tweezers were either not used or minimally used.

One possible complication resulting from this bleeding, even if diminished, has been inadvertent sectioning of the finger nerve when performing fasciectomy in cases of Dupuytren's contracture. According to Lalonde, this surgery is one of the most difficult procedures to perform using this method, because of the close proximity of the finger's vessels.⁶

In the two cases of patients with chronic kidney failure who underwent surgical treatment for carpal tunnel syndrome ipsilateral to the fistula, there was excessive bleeding, which made the procedure difficult to perform.

Our study had some limitations. There was no control group; we still only have a small number of cases available; and no statistical analysis was performed on the data. Nonetheless, we conducted an initial prospective study and obtained good results from this series, with good ischemia and anesthesia, without any complications relating to necrosis.

Another noteworthy point was that the solution was successfully used to raise a lateral flap on one patient's arm in the absence of blood, without using a pneumatic cuff. In

the original technique, a sterile cuff is installed high on the arm, but this was not possible here because the hospital had technical difficulty in sterilizing the tourniquet. The patient underwent general anesthesia so that a malignant tumor on the opposite hemiface could be resected by a head and neck surgeon. The microsurgical anastomoses of the posterior collateral pedicle were performed on branches of the facial vessels, with a lumen of 2.5 mm, using 10.0 mononylon thread. The surgery was performed taking the normal time and using normal methods, without harm to the vascular pedicle after injection of the solution, which was distributed at deep levels around the humerus and in the subcutaneous tissue, in the area of the cutaneous and subfascial incision.

A bibliographic survey was conducted through the CAPES periodicals website (www.periodicoscapes.gov.br) and PubMed (www.pubmed.com), and we did not find any scientific studies that made specific use of adrenaline or lidocaine-adrenaline solution for replacing the pneumatic cuff in surgery of the extremities that would enable discussion.

Conclusions

Use of lidocaine with adrenaline in hand surgery, at a concentration of 1:100,000 or less, was shown to be a safe technique for local anesthesia, without complications relating to necrosis or systemic absorption. Moreover, it provided a surgical field that was efficiently exsanguinated, thereby making it possible to perform the surgical procedures without using a pneumatic tourniquet, which avoided the potential risks of tourniquets and provided the benefit to patients of less sedation.

Conflicts of interest

The authors declare no conflicts of interest.

Annex 1. Evaluation form used for all patients

Questionnaire for surgery without a cuff and with lidocaine + adrenaline 1:100.000

Date of surgery: _____

Surgical procedure: _____

Name: _____

Hospital reg. no.: _____ Polyclinic reg. no.: _____

Age: _____ Sex: _____ Weight: _____ kg

Address: _____

Telephone: _____

Comorbidities: _____

Perioperative bleeding: excessive () moderate () minimal ()

- Excessive: halts progression of the surgery unless a tourniquet is used
- Moderate: makes progression difficult without a tourniquet, but not impossible
- Minimal: bleeding similar to that of surgery with a tourniquet

Use of bipolar tweezers: no () yes () ____ (1- minimal; 2 - normal; 3 - excessive)

Use of tourniquet: no () yes ()

Intraoperative pain: intense () moderate () minimal () none ()

Systemic alterations (anesthetist): vascular system () neurological alterations () others _____

Length of time between anesthesia and incision: _____

Duration of surgery: _____

Any skin color alteration around the injection of anesthetic? (yes) (no)

Any signs of arterial deficit? (yes) (no)

Notes: _____

Quantity of anesthetic (mL): _____ Any need for intraoperative repetition? (yes) (no)

Sedation: no () yes ()

Drugs and dosage: _____

Presence of postoperative hematoma: D3 _____ D10 _____ D17 _____

Presence of postoperative necrosis: D3 _____ D10 _____ D17 _____

Other alterations: _____

REFERENCES

1. Sylaidis P, Logan A. Digital blocks with adrenaline. An old dogma refuted. *J Hand Surg Br.* 1998;23(1):17-9.
2. Thomson CJ, Lalonde DH, Denkler KA, Feicht AJ. A critical look at the evidence for and against elective epinephrine use in the finger. *Plast Reconstr Surg.* 2007;119(1):260-6.
3. Tzarnas CD, Darby PA. Carpal tunnel release without a tourniquet. *J Hand Surg Am.* 1993;18(6):1041-3.
4. Oragui E, Parsons A, White T, Longo UG, Khan WS. Tourniquet use in upper limb surgery. *Hand (N Y).* 2011;6(2):165-73.
5. Kronic AL, Wang LC, Soltani K, Weitzul S, Taylor RS. Digital anesthesia with epinephrine: an old myth revisited. *J Am Acad Dermatol.* 2004;51(5):755-9.
6. Lalonde DH. Reconstruction of the hand with wide awake surgery. *Clin Plast Surg.* 2011;38(4):761-9.
7. Denkler K. A comprehensive review of epinephrine in the finger: todo or not to do. *Plast Reconstr Surg.* 2001;108(1):114-24.
8. Chowdhry S, Seidenstricker L, Cooney DS, Hazani R, Wilhelmi BJ. Do not use epinephrine in digital blocks: myth or truth? Part II. Retrospective review of 1,111 cases. *Plast Reconstr Surg.* 2010;126(6):2031-4.
9. Ramamurthy S, Anderson D, Anesthesia, Green DP. *Green's operative hand surgery.* 5a ed. Philadelphia: Elsevier; 2005. p. 25-52.
10. Fisher L, Gordon M. Anesthesia for hand surgery. In: Wolfe SW, Hotchkiss RN, Pederson WC, Kozin SH, editors. *Green's operative hand surgery.* 6a ed. Philadelphia: Churchill Livingstone/Elsevier; 2010. p. 25-38.
11. Fitzcharles-Bowe C, Denkler K, Lalonde DH. Finger injection with high-dose (1:1,000) epinephrine: does it cause finger necrosis and should it be treated? *Hand.* 2007;2(1):5-11.

12. Markovchick V, Burkhart KK. The reversal of the ischemic effects of epinephrine on a finger with local injections of phentolamine. *J Emerg Med.* 1991;9(5):323-4.
13. Lalonde DH, Bell M, Benoit P, Sparkes G, Denkler K, Chang P. A multicenter prospective study of 3110 consecutive cases of elective epinephrine use in the fingers and hand: the Dalhousie Project clinical phase. *J Hand Surg Am.* 2005;30(5):1061-7.
14. Nodwell T, Lalonde D. How long does it take phentolamine to reverse adrenaline-induced vasoconstriction in the finger and hand? A prospective, randomized, blinded study: the Dalhousie project experimental phase. *Can J Plast Surg.* 2003;11(4):187-90.
15. Sönmez A, Yaman M, Ersoy B, Numanodlu A. Digital blocks with and without adrenalin: a randomised-controlled study of capillary blood parameters. *J Hand Surg Eur Vol.* 2008;33(4):515-8.
16. Mann T, Hammert WC. Epinephrine and hand surgery. Evidence based medicine. *J Hand Surg Am.* 2012;37(6):1254-6.