

# Comparative study of pars plana vitrectomy with or without intravitreal dexamethasone implant for idiopathic epiretinal membrane

Surabhi S Sane<sup>1</sup>, Mohammad Hasnat Ali<sup>2,3</sup>, Baruch D Kuppermann<sup>4</sup>, Raja Narayanan<sup>1,3</sup>

**Purpose:** To investigate if use of adjunctive intravitreal dexamethasone implant during pars plana vitrectomy (PPV) leads to faster visual recovery and reduction of retinal thickness in idiopathic epiretinal membrane (ERM). **Methods:** In this non-randomized, comparative, interventional study 30 eyes (from 30 patients with idiopathic ERM) were enrolled. In the control group ( $n = 15$ ), patients underwent 25-G pars plana vitrectomy (PPV) and ERM peeling. In the study group ( $n = 15$ ), each patient underwent the same procedure as those in the control group, and also received an additional dexamethasone implant. Primary outcome after treatment was mean gain in best corrected visual acuity (BCVA), and secondary outcome was reduction in central retinal thickness (CRT). Data were analyzed using Fisher's exact test, Wilcoxon rank sum test, and two-sample  $t$ -test. **Results:** The mean gain in BCVA (logMAR) from baseline at 1-month follow-up was significantly higher in the study group (median = -0.3, IQR = -0.4, -0.1) than in the control group (median = 0, IQR = -0.1, 0.3;  $P < 0.008$ ). However, no significant difference in mean gain in BCVA between the two groups was detectable at the 6-month follow-up ( $P < 0.55$ ). At 1-month follow-up, one and seven patients in the control and study groups gained  $\geq 15$  letters of BCVA ( $P < 0.05$ ), respectively. The mean reductions in CRT at the 1-month follow-up were significantly higher in the study group than in the control group (Mean = -60  $\mu\text{m}$ , SD = 92.1;  $P < 0.014$ ; 95% CI = 19.75–156.54). The difference in mean reduction of CRT at 6 months was not significant ( $P < 0.24$ ). **Conclusion:** Adjunctive dexamethasone implant can aid faster visual recovery after PPV in idiopathic ERM, although the implants do not affect long-term gains in visual acuity.

**Key words:** Idiopathic epiretinal membrane (ERM), intravitreal dexamethasone implant, pars plana vitrectomy (PPV)

In idiopathic epiretinal membrane (ERM), fibrotic changes in the extracellular matrix at the vitreoretinal interface cause severe macular distortion with retinal edema and breakdown of the underlying blood retina barrier. The condition usually has a dual mechanism of pathogenesis consisting of: (1) mechanical traction by posterior vitreous detachment, which results in Müller cell gliosis; and (2) involvement of inflammatory cytokines and growth factors, which cause fibrosis. Various growth factors and cytokines are involved in vascular distortion with increased permeability and leakage resulting in macular edema.<sup>[1]</sup> These observations suggest the presence of underlying chronic inflammation in idiopathic ERMs.<sup>[1,2]</sup>

In symptomatic cases of idiopathic ERM with worsening visual acuity (VA) and increasing central retinal thickness (CRT), pars plana vitrectomy (PPV) with ERM peeling (MP) with or without internal limiting membrane (ILM) peeling is the standard of care.<sup>[3,4]</sup> However, improvement in VA and macular thickness are often slow with only 70% of operated patients experiencing a significant improvement in vision in the operated

eye over 6 months to 1 year.<sup>[5-7]</sup> Various studies have reported the differing efficacies of concomitant use of steroids—intravitreal triamcinolone acetonide (IVTA) and dexamethasone—to control chronic inflammation in the hope of improving VA.<sup>[8-11]</sup> While most of these studies have reported improvements in VA and CRT at 6 months post-surgery, none have investigated the early effects (1-month post-surgery) of steroid therapy.

In this study, we have investigated the early effects of dexamethasone therapy on improvements in VA after treating idiopathic ERMs with PPV and ERM peeling.

## Methods

### Study design and registration

This trial was a non-randomized, comparative, interventional study.

The trial was registered with the Clinical Trials Registry–India (<http://www.ctri.nic.in/CTRI/2018/05/014336>). The study

This is an open access journal, and articles are distributed under the terms of the Creative Commons Attribution-NonCommercial-ShareAlike 4.0 License, which allows others to remix, tweak, and build upon the work non-commercially, as long as appropriate credit is given and the new creations are licensed under the identical terms.

**For reprints contact:** [reprints@medknow.com](mailto:reprints@medknow.com)

**Cite this article as:** Sane SS, Ali MH, Kuppermann BD, Narayanan R. Comparative study of pars plana vitrectomy with or without intravitreal dexamethasone implant for idiopathic epiretinal membrane. Indian J Ophthalmol 2020;68:1103-7.

### Access this article online

#### Website:

[www.ijo.in](http://www.ijo.in)

#### DOI:

10.4103/ijo.IJO\_1045\_19

### Quick Response Code:



<sup>1</sup>Kanuri Santhamma Vitreo-Retina Service, L. V. Prasad Eye Institute, <sup>2</sup>Department of Biostatistics, L.V. Prasad Eye Institute, <sup>3</sup>Suven Clinical Research Center, Hyderabad Eye Research Foundation, L.V. Prasad Eye Institute, Hyderabad, Telangana, India, <sup>4</sup>Gavin Herbert Eye Institute, University of California, Irvine, USA

**Correspondence to:** Dr. Raja Narayanan, LV Prasad Eye Institute, L V Prasad Marg, Banjara Hills, Hyderabad - 500 034, Telangana, India. E-mail: [narayanan@lvpei.org](mailto:narayanan@lvpei.org)

Received: 01-Jun-2019

Revision: 10-Sep-2019

Accepted: 10-Jan-2020

Published: 25-May-2020

protocol adhered to the tenets of the Declaration of Helsinki and was approved by the local Institutional Review Board ECR/468/Inst./AP/2013/RR-16. All study participants gave their written, informed consents before being enrolled in the study. Patients were recruited from August 2017–July 2018.

### Patient eligibility

#### Inclusion criteria

Key inclusion criteria included: (1) patients with idiopathic ERM; (2) age >40 years; (3) Snellen VA <20/30 and >20/400; (4) CRT >300  $\mu$ m, diagnosis confirmed by optical coherence tomography (OCT); (5) pseudophakic/phakic patients; (6) duration since diagnosis <1 year.

#### Exclusion criteria

Key exclusion criteria included: (1) ERM secondary to other retinal diseases like diabetic retinopathy, vascular occlusions, uveitis, or age related macular degeneration; (2) aphakia, advanced glaucoma; (3) patients with hazy media or advanced cataract; (4) duration since diagnosis > 1 year; (5) ERM with full thickness macular hole; (6) previous vitreoretinal surgery in the study eye or anticipated surgery within 12 months of enrolment to this study; (7) previous pan-retinal laser photocoagulation or macular laser photocoagulation; (8) use of intraocular or periocular steroids or previous treatment with anti-vascular endothelial growth factor drugs in the study eye.

### Baseline evaluation

Thirty eyes of 30 patients with idiopathic ERM were studied. During the first visit, all the eyes were evaluated by standardized early treatment diabetic retinopathy study (ETDRS) refraction protocol for best-corrected visual acuity (BCVA), slit-lamp evaluation, intraocular pressure (IOP) by Goldman applanation tonometry and indirect ophthalmoscopy. Clinical diagnosis of idiopathic ERM was confirmed on OCT, and CRT was recorded on a Topcon DRI OCT Triton (Topcon, Inc, Tokyo, Japan) using a 3-D macular cube scan.

### Pars plana vitrectomy and intravitreal dexamethasone implant

Eyes in the study group ( $n = 15$ ) underwent a standard 25-G PPV and ERM peeling along with implantation of an intravitreal dexamethasone implant, Ozurdex® (Allergan Inc., Irvine, CA); eyes in the control group ( $n = 15$ ) underwent the same procedures, but did not receive an Ozurdex® implant. After core vitrectomy, posterior vitreous detachment was induced, and the ERM was removed with an intravitreal Eckardt forceps. Vitrectomy was carried out using an Alcon Constellation® Vitrectomy machine (Cut rate: 5000/min; vacuum: 400–500 mm Hg). Six patients from the study group and two patients from the control group with early nuclear sclerosis also underwent concomitant cataract surgeries by phacoemulsification.

### Subsequent visits

Patients were examined during postoperative follow-up visits on day 1, week 1, 1 month, 3 months, and 6 months after surgery. BCVA and IOP were recorded during each visit. Postoperative measures of OCT were obtained at 1, 3, and 6 months after surgery.

### Outcome measures

Primary outcome measure was the gain in BCVA at 1 and 6 months follow-up. Secondary outcome measures were

proportion of patients gaining in more than 15 letters BCVA, and reduction of CRT at 1 and 6 months. Adverse events such as glaucoma, cataract, and retinal detachment were analyzed.

### Statistical analyses

Fisher's exact test was used to analyze categorical variables, and both Wilcoxon rank sum test and two-sample *t*-test were used to analyze continuous variables. Results were considered significant for *P* values < 0.05. Data were analyzed using R software version 3.1.2 (R Development core team, R Foundation for Statistical Computing, Vienna, Austria).

## Results

Of the enrolled patients with idiopathic ERM ( $n = 30$ ), 16 were women, and 14 were men. The mean age of all enrolled subjects was  $66.9 \pm 7.3$  years (mean  $\pm$  SD). There were no significant differences in the demographic characteristics of the two groups at baseline, as described [Table 1]. The mean ages of patients were  $66.4 \pm 6.46$  and  $67.4 \pm 8.24$  years for the study and control groups, respectively. Mean baseline BCVA scores were  $0.6 \pm 0.2$  (Snellen equivalent 20/80) and  $0.5 \pm 0.2$  (Snellen equivalent 20/60) for the study and control groups, respectively. Mean baseline CRT levels were  $479.9 \pm 107.1$   $\mu$ m and  $425.9 \pm 147.3$   $\mu$ m for the study and control groups, respectively. Two out of fifteen eyes from the study group and nine out of fifteen eyes from the control groups were pseudophakic; all other eyes were phakic.

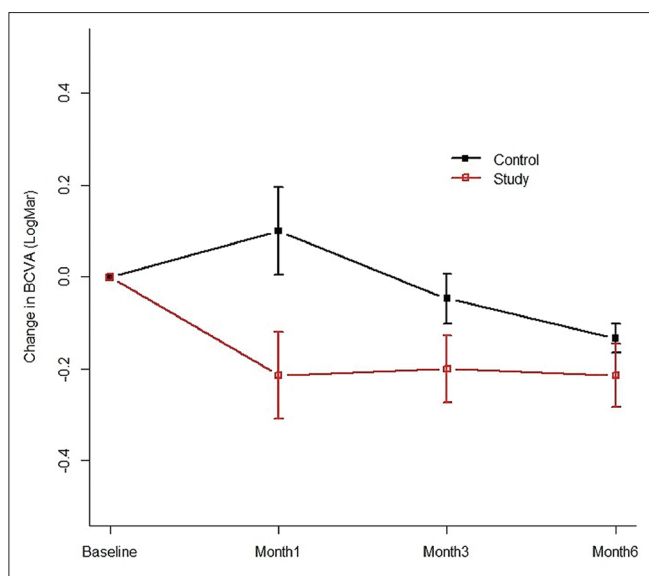
### Best corrected visual acuity (BCVA)

Analysis of the BCVA scores at the postoperative 1-month follow-up indicated that median BCVAs for the study and control groups were 0.2 (IQR = 0.3) (Snellen equivalent 20/30) and 0.5 (IQR 0.4, 0.8) (Snellen equivalent 20/60), respectively. The mean gains in BCVA from baseline (before surgery) till the 1-month follow-up were significantly higher in the study group (Median = -0.3, IQR -0.4, -0.1) than in the control group (Median = 0, IQR -0.1, 0.3) ( $P < 0.008$ ; 95% CI = 0.10–0.50). There were no significant differences in the mean gains in BCVA at the 3-month follow-up between the study (Mean = -0.2, SD = 0.3) and control (Mean = 0, SD = 0.2) groups ( $P < 0.1$ ; 95% CI = -0.03–0.34). Mean BCVA scores at the 6-month follow-up were 0.3 (IQR 0.2, 0.8) (Snellen equivalent 20/40) and 0.3 (IQR 0.2, 0.4) (Snellen equivalent 20/40) for the study and control groups, respectively. There were no significant differences in the mean gains in BCVA at the 6-month follow-up between the study (Median = -0.2, IQR -0.4, 0) and control (Median = -0.1, IQR -0.2, 0) groups ( $P < 0.55$ ; 95% CI = -0.10–0.30 [Fig. 1 and Table 2]).

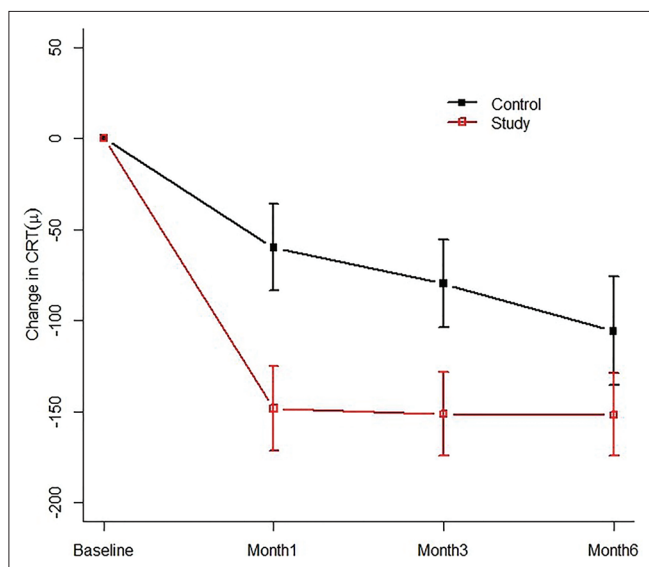
**Table 1: Baseline characteristics of the study and control groups**

	Study group	Control group	<i>P</i>
BCVA logMAR (SD*)	0.6 (0.2)	0.5 (0.2)	0.39
Central retinal thickness in $\mu$ m (SD)	479.9 (107.1)	425.9 (147.3)	0.261
Intraocular pressure in mm of Hg (SD)	14.3 (2.7)	14.6 (3.9)	0.78
Mean age in years	66	67	
Sex (Males: Females)	7: 8	7: 8	
Lens status (Pseudophakic: Phakic)	2:13	9:6	

\*Standard deviation



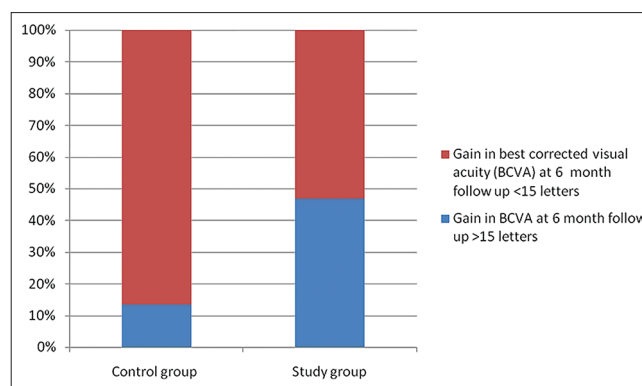
**Figure 1:** Best corrected visual acuity (BCVA) at the 6-month follow-up. At the 1-month follow-up, mean gain in BCVA from baseline is significantly higher in the study group than in the control group ( $P < 0.008$ ; 95% CI = 0.10–0.50). However, there were no significant differences in mean gain in BCVA from baseline at the 3- and 6-month follow-ups between the two groups ( $P < 0.10$ ; 95% CI = -0.03–0.34, and  $P < 0.55$ ; 95% CI = -0.10–0.30, respectively)



**Figure 3:** Central retinal thickness (CRT) during the six months of follow-up. Mean reductions in CRT values from baseline were significantly higher in the study group at the one-month follow-up than in the control group ( $P < 0.014$ ; 95% CI = 19.75–156.54). The mean reductions in CRT values were also significantly higher in the study group than in the control group at the three-month follow-up ( $P < 0.042$ ; 95% CI = 3.0–139.9). The differences in mean reductions in CRT values between the two groups at the six-month follow-up, however, were not significant ( $P < 0.24$ ; 95% CI = -31.3–122.9)

#### Percentage of patients who gained $\geq 15$ letters

Seven eyes from the study group (46.7%) and one eye from the control group (6.7%) gained  $\geq 15$  letters at the 1-month follow-up. Ten eyes from the study group (66.7%) and 3



**Figure 2:** Percentage of patients who gained  $\geq 15$  letters of best corrected vision acuity (BCVA). At the 6-month follow-up, two (13.3%) patients in the control group and seven (46.6%) in the study group gained  $\geq 15$  letters of BCVA ( $P < 0.05$ ; 95% CI = 0.45–58.42). Of these, one eye from the control group and all seven eyes from the study group gained  $\geq 15$  letters at the one-month follow-up

eyes from the control group (20%) gained  $\geq 10$  letters at the 1-month follow up also. At the 6-month follow-up, two patients (13.3%) in the control group and seven from the study group (46.6%) had gained  $\geq 15$  letters ( $P < 0.05$  with 95% CI 0.45–58.42) [Fig. 2].

#### Central retinal thickness (CRT)

The mean reductions in CRT at the 1-month follow-up were significantly higher in the study group (Mean = -148.1  $\mu$ m, SD = 87.4) than in the control group (Mean = -60  $\mu$ m, SD = 92.1) ( $P < 0.014$ ; 95% CI = 19.75–156.54). Mean reductions in CRT at the 3-month follow-up were also significantly higher in the study group (Mean = -151.2  $\mu$ m, SD = 86.6) than in the control group (Mean = -79.7  $\mu$ m, SD = 93.1) ( $P < 0.042$ ; 95% CI = 3.0–139.9). However, mean reductions in CRT at the 6-month follow-up were not significantly different between the study and control groups ( $P < 0.24$ ; 95% CI = -31.3–122.9) [Fig. 3, Table 3]. Fig. 4 depicts serial OCT scans of one representative eye from the control and study groups each. The visual improvement and reduction in central retinal thickness in study eye was better than the control group at 1 month follow up.

#### Adverse events

There were no significant differences between the 1-, 3-, and 6-month follow-ups with regard to changes in IOP ( $P < 0.3$ ,  $P < 0.7$ , and  $P < 0.8$ , respectively). One patient in the study group had raised IOP values (borderline, 23 mm Hg) at the 1-month follow-up, and was treated with short-term anti-glaucoma medication.

Two patients each in the study and control groups developed cataracts which warranted surgery during the 6-month follow-up period.

One patient in the study group with a baseline BCVA score of 0.3 (Snellen Equivalent 20/40) was found to have peripheral retinal detachment 1 week after surgery. After silicon oil injection and endolaser, the retina was attached during subsequent follow-up visits and the BCVA improved to 0.6 (Snellen equivalent 20/80) at 6 months. Another patient in the study group with a baseline BCVA score of 0.6 (Snellen equivalent 20/80) developed optic disc pallor 1 month after surgery. Though no other cause for disc pallor was found



on investigating further, the BCVA score for this patient at 6 months was found to be 0.6 (Snellen equivalent 20/80).

Discussion

Visual improvement after surgery for idiopathic ERM can be very slow.<sup>[5,6]</sup> However, this study shows that in eyes with idiopathic ERM undergoing vitrectomy, injection

with dexamethasone implant can drive rapid recovery (in 1 month) of VA along with a rapid reduction in macular edema (reduction in CRT).

A randomized, controlled trial by Guidi *et al.*<sup>[9]</sup> tested the effectiveness of intraoperative slow-release dexamethasone implants in improving BCVA after 25-G vitrectomy and ERM removal in patients affected by idiopathic macular pucker. After 6 months, the study indicated that although there were significant improvements in BCVA scores, and reductions in foveal thickness post-surgery, there were no significant differences between the control group and the group receiving the dexamethasone implants.<sup>[9]</sup> However, Guidi *et al.*<sup>[9]</sup> did not investigate early-stage improvements in BCVA scores or reduction in foveal thickness in their patients. Our study shows that treatment with dexamethasone at the time of vitrectomy may lead to a rapid improvement in VA, especially in the first month after surgery. However, our results also indicate that although the number of patients gaining ≥ 15 letters at the 1-month follow-up was significantly higher in the study group than in the control group, the final VA achieved at 6 months post-surgery, was similar between the two groups; at the 6-month post-surgery stage, our study shows similar results to previous studies carried out using either IVTA or dexamethasone implants.<sup>[8-10,12]</sup>

The sustained-release dexamethasone intravitreal implant (0.7 mg) delivers the steroid drug locally for up to 6 months after a single injection,<sup>[10,13]</sup> although the effects of the implant generally last for the next 3–4 months. The implant has a similar pharmacokinetic profile in non-vitrectomized as

Table 2: Comparisons between mean gains in best corrected visual acuity (BCVA) logMAR scores between the study and control groups during the six months of follow-up

Median (IQR*)/Mean (SD*)	Study group	Control group	P
One-month follow-up	-0.3 (-0.4, -0.1)	0 (-0.1,0.3)	0.008
Three-month follow-up	-0.2 (0.3)	0 (0.2)	0.101
Six-month follow-up	-0.2 (-0.4,0)	-0.1 (-0.2, 0)	0.55

\*Interquartile range. \*Standard deviation

Table 3: Comparisons between the mean reductions in central retinal thickness (CRT) (µm) at each follow-up

Mean reduction in µm (SD*)	Study group	Control group	P
One-month follow-up	-148.1 (87.4)	-60 (92.1)	0.014
Three-month follow-up	-151.2 (86.6)	-79.7 (93.1)	0.042
Six month follow-up	-151.6 (85.1)	-105.9 (115.4)	0.237

\*Standard deviation

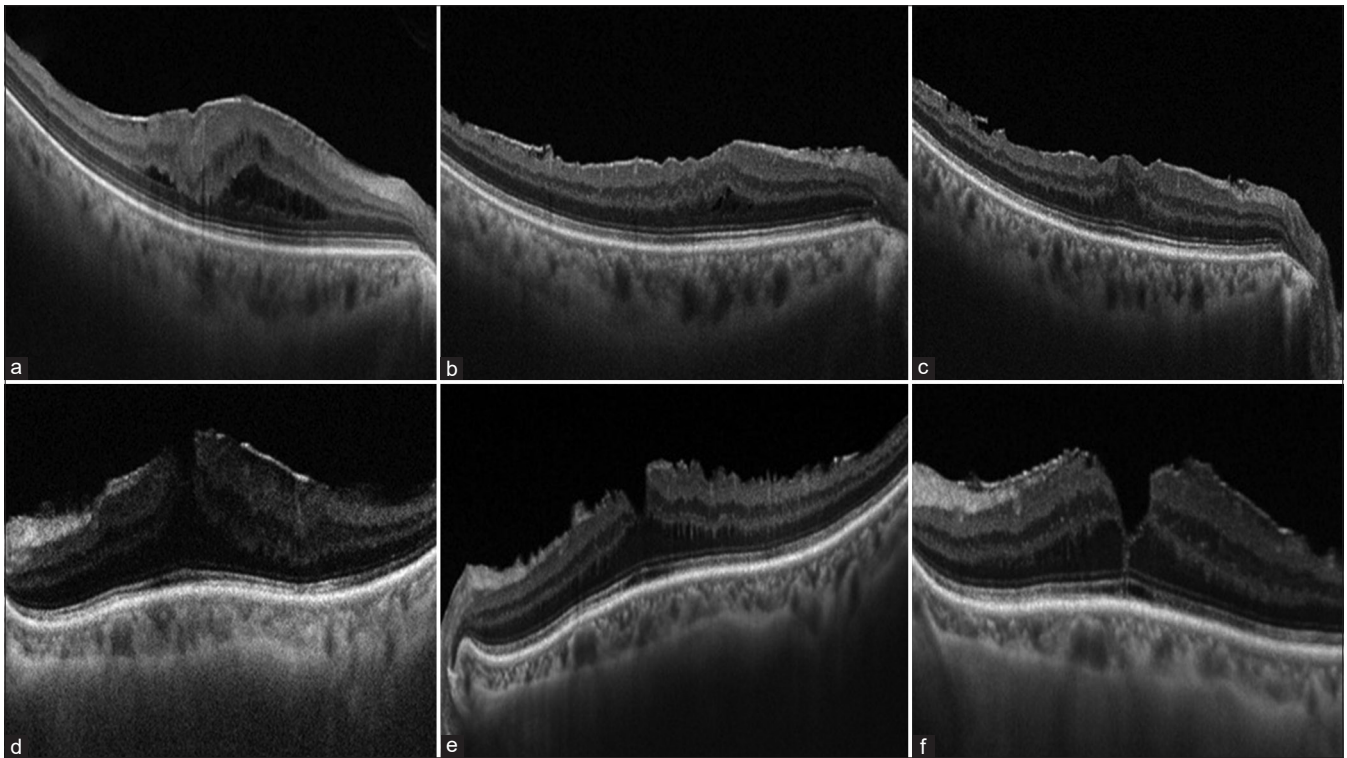


Figure 4: Composite picture showing OCT scans of representative patients from the control and the study group at baseline, 1 month and 6 months. (a-c) in the upper panel of the image represent the OCT scans of a 67 year old female patient from the control group with best corrected visual acuity (BCVA) of logMAR 0.6, 0.4 and 0.5 at baseline, 1 month and 6 months respectively. (d-e) in the lower panel represent OCT scans of a 70 year old female patient from the study group with BCVA logMAR 0.5, 0.2, 0.2 at baseline, 1 month and 6 month follow ups respectively

well as vitrectomized eyes.<sup>[14]</sup> As an anti-inflammatory agent, dexamethasone is approximately 12.5 times more potent than triamcinolone acetonide,<sup>[15]</sup> is the most water-soluble corticosteroid with the shortest half-life, and is least likely to aggregate in the trabecular meshwork to cause IOP elevation.<sup>[16]</sup> While IVTA is cleared more rapidly in vitrectomized eyes, IVTA treatment can lead to adverse events like macular toxicity, dose dependent IOP rise, and cataract formation.<sup>[17-19]</sup> Due to these reasons, we chose to use dexamethasone implant in our study. However, it must also be noted that a study by Yonekawa *et al.* compared the visual and anatomic outcomes of idiopathic ERM eyes undergoing PPV with intraoperative use of either intravitreal dexamethasone implants or IVTA found no differences between the two treatments.<sup>[11]</sup>

Besides the study by Yonekawa *et al.*<sup>[11]</sup> only one other study by Guidi *et al.* investigated the effects of simultaneous injections of dexamethasone implants during PPVs for ERM. Now, our work provides important data on how dexamethasone implants may help in improving recovery in patients treated for idiopathic ERM by helping them achieve faster visual rehabilitation after surgery; this data could also have important clinical implications for surgeons as well as patients while considering surgery for ERM.

Furthermore, although our study was performed only in patients with idiopathic ERM, these results may also be applicable to cases where ERM is secondary to intraocular inflammation. It is possible that dexamethasone implants could have even higher efficacies in treating cases where ERM is secondary to inflammation.

Although our study does provide important data on the use of steroid implants to enhance visual rehabilitation after surgery for idiopathic ERM, one of the main limitations of this study arises from the its non-randomized nature; although the study arm itself was prospective, our comparative arm was a historical control. Furthermore, this study has a relatively low sample size; although we were able to show clinically and statistically significant results, we were unable to gain a more complete understanding of the possible side effects (such as glaucoma and cataract) of using dexamethasone implants. Without this data, it is difficult to understand the factors that could affect visual improvement, especially since progression of cataracts in phakic patients could either be due to vitrectomy or the dexamethasone implant.

## Conclusion

In conclusion, our data show that dexamethasone implants can hasten visual rehabilitation by driving rapid VA recovery and reducing macular edema. Therefore, we believe that treatment of idiopathic ERM with PPV and ERM peeling can be improved with the concomitant use of dexamethasone implants.

## Financial support and sponsorship

Nil.

## Conflicts of interest

There are no conflicts of interest.

## References

- Harada C, Mitamura Y, Harada T. The role of cytokines and trophic factors in epiretinal membranes: Involvement of signal transduction in glial cells. *Prog Retin Eye Res* 2006;25:149-64.
- Bu SC, Kuijer R, Li XR, Hooymans JM, Los LI. Idiopathic epiretinal membrane. *Retina* 2014;34:2317-35.
- Pournaras CJ, Emarah A, Petropoulos IK. Idiopathic macular epiretinal membrane surgery and ILM peeling: Anatomical and functional outcomes. *Semin Ophthalmol* 2011;26:42-6.
- Rouvas A, Chatziralli I, Androu A, Papakonstantinou S, Kouvari MS, Alonistiotis D, *et al.* Long-term anatomical and functional results in patients undergoing observation for idiopathic nontractional epiretinal membrane. *Eur J Ophthalmol* 2016;26:273-8.
- Garcia-Fernandez M, Castro Navarro J, Gonzalez Castano C, Garcia Alonso A, Fonolla Gil M. Epiretinal membrane surgery: Anatomic and functional outcomes. *Arch Soc Esp Oftalmol* 2013;88:139-44.
- Pesin SR, Olk RJ, Grand MG, Boniuk I, Arribas NP, Thomas MA, *et al.* Vitrectomy for premacular fibroplasia. Prognostic factors, long-term follow-up, and time course of visual improvement. *Ophthalmology* 1991;98:1109-14.
- McDonald HR, Verre WP, Aaberg TM. Surgical management of idiopathic epiretinal membranes. *Ophthalmology* 1986;93:978-83.
- Lai CC, Wang NK, Wu WC, Yeung L, Hwang YS, Chen KJ, *et al.* The long-term anatomical and visual effect of intravitreal triamcinolone injection during vitrectomy for the treatment of idiopathic macular epiretinal membrane. *Cutan Ocul Toxicol* 2011;30:292-7.
- Guidi G, Casini G, Ripandelli G, Piaggi P, Dalle Lucche F, Sartini M, *et al.* Residual intraretinal edema after 25-gauge vitrectomy and macular pucker removal: Is intraoperative sustained-release dexamethasone a real treatment option? *Retina* 2018;38:993-9.
- Paspulati A, Punjabi OS, Theodoropoulou S, Singh RP. Triamcinolone acetonide as an adjuvant to membrane peeling surgery: A pilot study. *Ophthalmic Surg Lasers Imaging Retina* 2013;44:41-5.
- Yonekawa Y, Mammo DA, Thomas BJ, Wolfe JD, Hassan TS. A comparison of intraoperative dexamethasone intravitreal implant and triamcinolone acetonide used during vitrectomy and epiretinal membrane peeling: A case control study. *Ophthalmic Surg Lasers Imaging Retina* 2016;47:232-7.
- Konstantinidis L, Berguiga M, Beknazar E, Wolfensberger TJ. Anatomic and functional outcome after 23-gauge vitrectomy, peeling, and intravitreal triamcinolone for idiopathic macular epiretinal membrane. *Retina* 2009;29:1119-27.
- Haller JA, Bandello F, Belfort R, Jr., Blumenkranz MS, Gillies M, Heier J, *et al.* Randomized, sham-controlled trial of dexamethasone intravitreal implant in patients with macular edema due to retinal vein occlusion. *Ophthalmology* 2010;117:1134-46.
- Chang-Lin JE, Burke JA, Peng Q, Lin T, Orilla WC, Ghosn CR, *et al.* Pharmacokinetics of a sustained-release dexamethasone intravitreal implant in vitrectomized and nonvitrectomized eyes. *Invest Ophthalmol Vis Sci* 2011;52:4605-9.
- Kuppermann BD, Zacharias LC, Kenney MC. Steroid differentiation: The safety profile of various steroids on retinal cells *in vitro* and their implications for clinical use (an American ophthalmological society thesis). *Trans Am Ophthalmol Soc* 2014;112:116-41.
- Thakur A, Kadam R, Kompella UB. Trabecular meshwork and lens partitioning of corticosteroids: Implications for elevated intraocular pressure and cataracts. *Arch Ophthalmol* 2011;129:914-20.
- Veritti D, Di Giulio A, Sarao V, Lanzetta P. Drug safety evaluation of intravitreal triamcinolone acetonide. *Expert Opin Drug Saf* 2012;11:331-40.
- Tao Y, Jonas JB. Intravitreal triamcinolone. *Ophthalmologica* 2011;225:1-20.
- Chin HS, Park TS, Moon YS, Oh JH. Difference in clearance of intravitreal triamcinolone acetonide between vitrectomized and nonvitrectomized eyes. *Retina* 2005;25:556-60.