

Case report

Cervical cancer recurrence presenting as abdominal wall mass and accompanying cellulitis

Jesse Chou^a, Lauren Strzyzewski^{a,*}, Caitlin Timmers^b, Anna Hoekstra^{b,c}^a Western Michigan University Homer Stryker M.D. School of Medicine, Kalamazoo, MI, USA^b Department of Obstetrics and Gynecology, Western Michigan University Homer Stryker M.D. School of Medicine, Kalamazoo, MI, USA^c Division of Gynecologic Oncology, West Michigan Cancer Center, Kalamazoo, MI, USA

ARTICLE INFO

Keywords:

Cervical cancer
Abdominal wall metastases
Recurrence patterns

ABSTRACT

Background: Most recurrences of early stage cervical cancer occur in the pelvis or lymphatic system. Distant metastases occur in a minority of patients. Large abdominal wall recurrence presenting as cellulitis and intra-abdominal mass is unusual and presents diagnostic as well as treatment challenges.

Case: A 46-year-old woman with a history of stage 1B1 poorly differentiated squamous cell carcinoma of the cervix 2 years earlier presented with infraumbilical abdominal wall erythema, tenderness and warmth to the touch. She had a subcutaneous mass in that area with associated abdominopelvic pain. Imaging showed a 9.5 × 11 cm lobulated mass in the anterior lower abdominal wall, encompassing the width of the lower rectus muscles also invading the small bowel and the bladder. Superimposed cellulitis led to the symptoms with which she presented. She was treated with intravenous antibiotics, and biopsy of the mass revealed squamous cell carcinoma consistent with her prior cervical cancer. She was treated with neoadjuvant chemotherapy followed by surgical debulking with negative margins and adjuvant chemotherapy. Three months after completing treatment she recurred in the inguinal lymph nodes and restarted multimodality treatment. She was without evidence of disease for the entire 18 months of follow up following treatment to the lymph nodes.

Conclusion: Cervical cancer recurrence patterns can be unique. Surveillance for recurrence may also include consideration of these unusual patterns of recurrence.

1. Introduction

There were 13,170 new cases of cervical cancer diagnosed in 2019 in the US (Siegel et al., 2019). In many countries, formal screening programs have led to the dramatic decrease in mortality of cervical cancer. This is due, in part, to improved detection of early-stage cancers. Despite diagnosis at early stages, up to 20% of early stage cervical cancers recur (Salani et al., 2017). Generally, recurrent cervical cancer has a poor prognosis as it is not curable. Median survival rates for symptomatic patients ranges from 8 to 38 months and 8–53 months for asymptomatic patients (Salani et al., 2017). Most recurrences are detected at the time of pelvic exam with symptoms local to the pelvis such as pain or bleeding. The most common sites for local recurrence include the pelvic floor or lymph nodes (Van Den Tillaart et al., 2010). While less common, sites for distant hematogenous recurrence include lung, liver or bone (Nagarsheth et al., 2000). Here, we present a more unique presentation of recurrent cervical cancer associated with an unusual pattern of spread to the abdominal wall.

2. Case report

A 44 year old initially presented with abnormal pap screening and was diagnosed with a stage 1B1 high grade squamous cell carcinoma of the cervix. She was treated with laparoscopic radical hysterectomy and pelvic lymph node dissection for a 3 cm high grade tumor with no intermediate or high pathologic risk factors for recurrence. No adjuvant treatment was recommended, and she was lost to follow up after her postoperative visits.

Two years later, the patient presented to the Emergency Department with a three-month history of abdominopelvic pain and a warm, erythematous infraumbilical abdominal wall. She reported associated constipation and weight loss of 20 lbs. Physical exam revealed an approximately 7 cm indurated area in her lower abdominal wall. She had associated erythema and warmth, consistent with a clinical diagnosis of cellulitis (Fig. 1). She was afebrile with normal vital signs, but had a leukocytosis to 24 as well as thrombocytosis. CT scan revealed a lobulated mass with cystic areas measuring 9.5 cm × 11 cm extending

* Corresponding author at: 156 Portage St, Kalamazoo, MI, USA.

E-mail address: Lauren.Strzyzewski@med.wmich.edu (L. Strzyzewski).

<https://doi.org/10.1016/j.gore.2020.100619>

Received 16 June 2020; Received in revised form 26 July 2020; Accepted 31 July 2020

Available online 03 August 2020

2352-5789/ © 2020 The Authors. Published by Elsevier Inc. This is an open access article under the CC BY-NC-ND license

(<http://creativecommons.org/licenses/by-nc-nd/4.0/>).

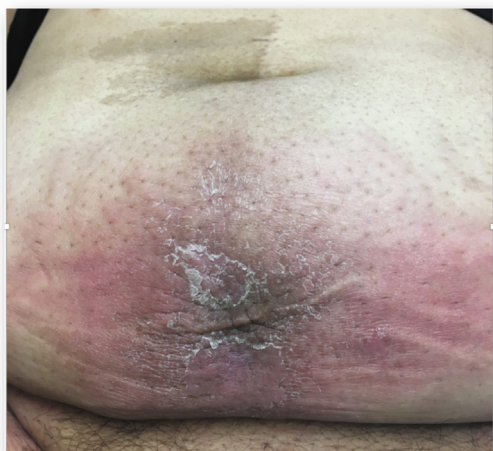

Fig. 1. Gross view of abdominal wall on presentation.

from immediately anterior to the sigmoid colon through the abdominal wall (Fig. 2a). There was suspicion of involvement of the small bowel and the superior urinary bladder.

Due to concern for cellulitis with possible recurrence of cervical cancer, the patient was admitted for intravenous antibiotic therapy and biopsy of the mass. CT-guided biopsy showed squamous cell carcinoma staining for p40 and p16, suggesting a recurrence of her cervical tumor (Fig. 3). Multidisciplinary tumor conference recommendation was for neoadjuvant chemotherapy followed by surgical resection. She was treated with 3 cycles of carboplatin and paclitaxel with favorable response on CT scan (Fig. 2b) obtained preoperatively. She underwent exploratory laparotomy, en-bloc resection of the abdominal wall, a portion of the omentum and small bowel, followed by abdominal wall reconstruction with mesh. No involvement of the bladder wall was observed at the time of the operation, however the mass was adherent to one loop of small bowel and to the bladder peritoneum. The small bowel was resected with the mass, and the bladder peritoneum was resected and oversewn. Final pathology was consistent with poorly differentiated squamous cell carcinoma extending through the full thickness of small intestine involving omentum and soft tissues with widely negative margins.

She was treated with 3 more cycles of chemotherapy. Within 3 months of completing chemotherapy, she recurred in her right inguinal lymph nodes. The inguinal node was biopsied and pathology was

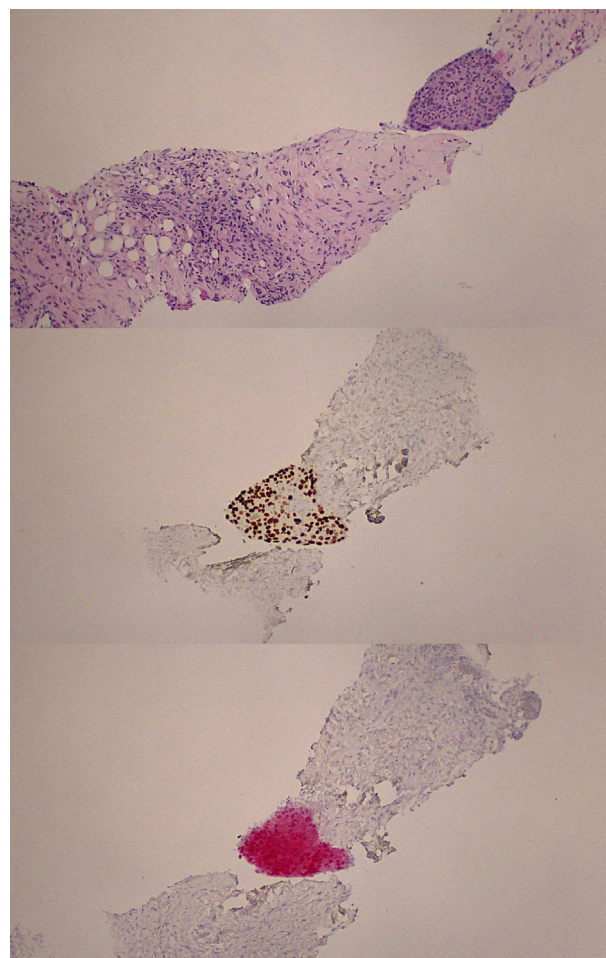


Fig. 3. 3a: H&E stain 100x magnification. 3b: p40 stain for squamous differentiation of tumors. 3c: p16 stain for high-risk HPV.

consistent with metastatic squamous cell carcinoma. She underwent treatment with weekly cisplatin and concurrent radiation to the whole pelvis and inguinal regions. At the time of the writing of this manuscript, she was without evidence of disease for 18 months following chemoradiation and was still in remission.

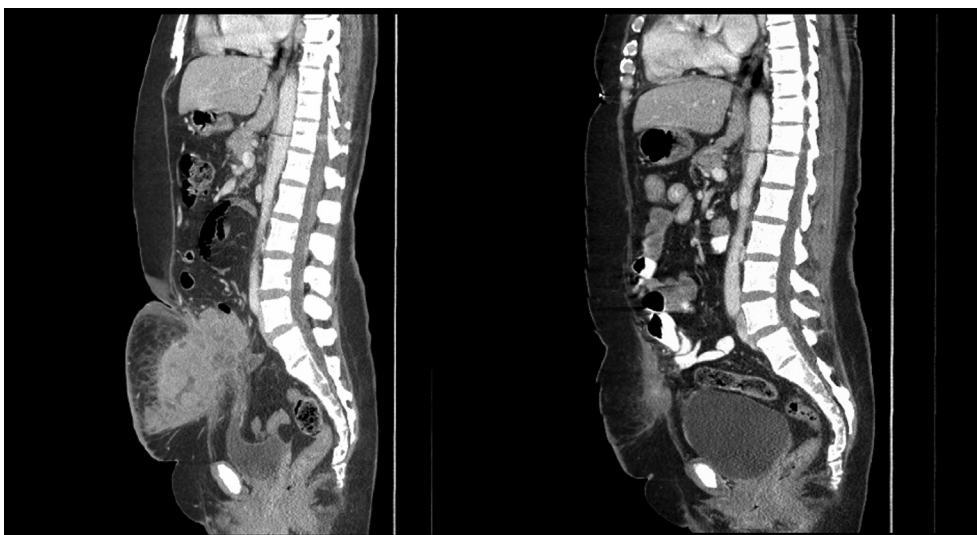

Fig. 2. 2a: CT image of patient at initial presentation. 2b: CT image of patient after three cycles of chemotherapy but prior to surgical resection.

3. Discussion

Abdominal wall recurrence with associated cellulitis is a rare presentation of recurrent cervical cancer. Between 10 and 20% of patients with stage I disease recur (Elit et al., 2010). The most common symptoms of recurrence include vaginal bleeding, pain, fatigue and weight loss (Salani et al., 2017). There are case reports, however, describing abdominal wall recurrences. Most of these involve port site or laparotomy incision recurrences presenting as either cutaneous lesions over scars or subcutaneous masses (Kohlberger et al., 2000; Lavie et al., 1999). Only one was asymptomatic and found on imaging at the time of restaging scans for a pelvic recurrence. In a retrospective single institution case control study, there was a 1.3% incidence of recurrence in the surgical scar after radical hysterectomy (Van Den Tillaart et al., 2010). To the knowledge of the authors, no reports showed cellulitis as the presenting symptom. Our patient's laparoscopic radical hysterectomy was performed in the standard fashion with a peri-umbilical trocar accompanied by right and left lower quadrant trochars. No suprapubic trocar was placed, which would be closest in proximity to the location of the recurrence. However, it is unclear whether this patient's recurrence was at an incision site due to its size, location and diffuse pattern. For patients with a cervical cancer history presenting with abdominal wall abnormalities, recurrence of their cancer must be a consideration.

Seventy-five percent of cervical cancer recurrences occur within the first 3 years after treatment (Elit et al., 2010). This patient and the patients detailed in the case reports of port/incision site recurrences all recurred within the 3-year timeframe (Kohlberger et al., 2000; Lavie et al., 1999). For this reason, the typical surveillance schedule involves a pelvic exam every 3–6 months for 2 years, then every 6 months for an additional 3 years (NCCN). Cytologic evaluation can be utilized to identify other lower genital tract dysplasia or local recurrence (Salani et al., 2017).

Most cervical cancer recurrences are symptomatic. Studies show that between 63% and 87% of recurrences present with symptoms (Duyn et al., 2002; Samlal et al., 1998). Data shows symptomatic recurrences portend a worse prognosis than asymptomatic recurrences. Noncompliance with routine surveillance exams may contribute to high rates of symptomatic recurrence with poor prognosis. Cervical cancer survivors may present to their primary care providers or emergency departments with symptomatic recurrences due to noncompliance with Gynecologic Oncology or discharge from the oncology practice after 5 years. Awareness of atypical recurrence patterns benefit not only Gynecologic Oncologists, but primary care providers as they care for cancer survivors.

The distribution of disease among women with recurrent cervical cancer can vary widely. The most common distribution of disease is centrally in the pelvic floor/cervix, in the lymphatics, or carcinomatosis (Samlal et al., 1998). There are, however, reports describing metastases in the cardiac muscle, bone, brain, lungs, and supraclavicular lymph nodes (Sasidharan et al., 2016). The case reports of women with port site/incisional recurrences reported some solitary recurrences on the skin, but others noted concurrent widespread metastases. A wide variety of metastatic sites can be involved with recurrent cervical cancer.

Atypical presentations and spread patterns may require unique treatment plans. Standard treatment for recurrent cervical cancer depends on location, distribution, and prior radiation therapy. For regional recurrence with no prior radiation, the NCCN recommendation would include surgery followed by radiation with or without

chemotherapy. In this case, it was unlikely that an initial operation would have obtained negative margins, and the risk of bladder or bowel injury was high. For these reasons, neoadjuvant chemotherapy was recommended. Negative margins were reported at the time of the debulking surgery, and completion of a total of 6 cycles of chemotherapy was recommended without radiation. Radiation was not recommended due to the lack of any known residual disease in addition to the extent of the surgery including a small bowel anastomosis and a reconstructed abdominal wall. It is unclear whether adjuvant radiation would have prevented the recurrence in the inguinal node area.

In conclusion, this is an unusual recurrence of cervical cancer in its presenting symptoms and spread pattern. This patient required an individualized treatment plan and unfortunately has a poor long-term prognosis.

Author contributions

J.C. and L.S. completed the literature review, wrote the original draft and edited the manuscript. C.T. edited the manuscript and assisted with the literature review. A.H. provided the care of the patient, reviewed, and edited.

Declaration of Competing Interest

The authors declare that they have no known competing financial interests or personal relationships that could have appeared to influence the work reported in this paper.

Written informed consent was obtained from the patient for publication of this case report and accompanying images. A copy of the written consent is available for review by the Editor-in-Chief of this journal on request.

References

- Duyn, A., Van Eijkeren, M., Kenter, G., Zwiderman, K., Ansink, A., 2002. Recurrent cervical cancer: Detection and prognosis. *Gynecol. Scand. Acta Obstet.* <https://doi.org/10.1034/j.1600-0412.2002.810414.x>.
- Elit, L., Fyles, A.W., Oliver, T.K., Devries-Aboud, M.C., Fung-Kee-Fung, M., 2010. Follow-up for women after treatment for cervical cancer. *Oncol. Curr.* <https://doi.org/10.3747/co.v17i3.514>.
- Kohlberger, P.D., Edwards, L., Collins, C., Milross, C., Hacker, N.F., 2000. Laparoscopic port-site recurrence following surgery for a stage IB squamous cell carcinoma of the cervix with negative lymph nodes. *Oncol. Gynecol.* <https://doi.org/10.1006/gyno.2000.5932>.
- Lavie, O., Cross, P.A., Beller, U., Dawlaty, B., Lopes, A., Monaghan, J.M., 1999. Laparoscopic port-site metastasis of an early stage adenocarcinoma of the cervix with negative lymph nodes. *Oncol. Gynecol.* <https://doi.org/10.1006/gyno.1999.5502>.
- Nagarsheth, N.P., Maxwell, G.L., Bentley, R.C., Rodriguez, G., 2000. Bilateral pelvic lymph node metastases in a case of FIGO stage IA1 adenocarcinoma of the cervix. *Oncol. Gynecol.* <https://doi.org/10.1006/gyno.2000.5786>.
- Salani, R., Khanna, N., Frimer, M., Bristow, R.E., Chen, L.M., 2017. An update on post-treatment surveillance and diagnosis of recurrence in women with gynecologic malignancies: Society of Gynecologic Oncology (SGO) recommendations. *Oncol. Gynecol.* <https://doi.org/10.1016/j.ygyno.2017.03.022>.
- Samlal, R.A.K., Van Der Velden, J., Van Eerden, T., Schilthuis, M.S., Gonzalez, D.G., Lammes, F.B., 1998. Recurrent cervical carcinoma after radical hysterectomy: An analysis of clinical aspects and prognosis. *J. Gynecol. Cancer Int.* <https://doi.org/10.1046/j.1525-1438.1998.09759.x>.
- Sasidharan, A., Hande, V., Mahantshetty, U., Shrivastava, S.K., 2016. Cardiac metastasis in cervical cancer. *BJR Case Reports.* <https://doi.org/10.1259/bjrcr.20150300>.
- Siegel, R.L., Miller, K.D., Jemal, A., 2019. Cancer statistics. *CA A Cancer J. Clin.* <https://doi.org/10.3322/caac.21551>.
- Van Den Tillaart, S.A.H.M., Schoneveld, A., Peters, I.T., Trimbos, J.B.M., Van Hylckama Vlieg, A., Fleuren, G.J., Peters, A.A., 2010. Abdominal scar recurrences of cervical cancer: Incidence and characteristics: A case-control study. *J. Gynecol. Cancer Int.* <https://doi.org/10.1111/IGC.0b013e3181db5153>.