

Addition of dexmedetomidine or fentanyl to ropivacaine for transversus abdominis plane block: evaluation of effect on postoperative pain and quality of recovery in gynecological surgery

Qi Chen
Xing Liu
Xuejiao Zhong
Bin Yang

Department of Anesthesiology,
Chongqing University Cancer
Hospital/Chongqing Cancer Institute,
Chongqing, China

Background: Transversus abdominis plane (TAP) block is reportedly a preferable technique for reducing postoperative pain in abdominal surgeries. The aim of this study was to compare the analgesic efficacy and recovery quality after gynecological surgery by adding dexmedetomidine or fentanyl into an ultrasound-guided TAP block.

Methods: We randomly assigned 100 elective gynecological patients into four groups (TAP, TAP-DEX, TAP-FEN, and control, n=25 in each). TAP blocks were performed postoperatively. The control group received patient-controlled intravenous analgesia (PCIA), the TAP group received TAP blocks with 0.375% ropivacaine, the TAP-DEX group received 0.375% ropivacaine with dexmedetomidine 1 µg/kg, and the TAP-FEN group received 0.375% ropivacaine with fentanyl 1 µg/kg. The primary outcomes were the first request time for PCIA bolus and quality of postoperative recovery assessed using the QoR-40 questionnaire 2 days after surgery. The secondary outcomes were the visual analog scale (VAS) scores at rest across the different time intervals, the total number of PCIA boluses required in 24 and 48 hours postoperatively, and associated complications.

Results: The first request time for PCIA was significantly longer in the TAP-DEX than in the TAP, TAP-FEN, and control groups (9.86±0.77, 7.86±0.56, 8.79±0.55, and 1.56±0.65 hours, respectively; $P<0.01$). The QoR-40 scores were highest in the TAP-DEX group ($P<0.05$). The mean PCIA bolus consumption in the first 24–48 hours was lowest in TAP-DEX group. VAS showed significant differences between TAP-DEX and TAP-FEN groups only at 6 hours ($P<0.01$).

Conclusion: The use of dexmedetomidine as an adjuvant to TAP blocks could facilitate postoperative analgesia and improve the quality of recovery without increasing related complications.

Keywords: transversus abdominis plane block, dexmedetomidine, fentanyl, pain, quality of postoperative recovery, adjuvant

Introduction

Open abdominal surgeries are inevitably accompanied by considerable postoperative pain, which is a detrimental important variable in patient outcomes and postoperative complications.¹ Opioids are widely used, but their side effects and possible delay in postoperative recovery limit their application. Transversus abdominis plane (TAP) block has been proved to be a useful and safe alternative technique to provide analgesia following abdominal surgeries. TAP block was designated to block the anterior branches of the spinal nerves from T7 to L1 which lie in the neurofascial plane between the internal oblique and transversus abdominis muscles and could anesthetize the median and lower

Correspondence: Bin Yang
Department of Anesthesiology,
Chongqing University Cancer Hospital/
Chongqing Cancer Institute, 181 Hanyu
Road, Shapingba District, Chongqing
400030, China
Tel +86 23 6507 5690
Fax +86 23 6507 5692
Email yangbin4332@outlook.com

abdominal wall.^{2,3} Recognized indications for a TAP block include open gastrointestinal surgery, gynecological surgery, and some urological surgeries. The safety of this block was also reported in patients with anticoagulant or coagulant defects.^{1,4} A large amount of related data have demonstrated the optimal abdominal area analgesia and the efficacy for providing perioperative analgesia with ultrasound-guided techniques. Unfortunately, a single-injection TAP block could provide effective abdominal wall analgesia for only up to 8 hours which limits its use.^{5,6} Diverse adjuvants (dexmedetomidine, fentanyl, MgSO₄, etc.) were added to local anesthetics to prolong the analgesic duration of TAP block,^{7–11} but the preferable regimen and optimal dosage of adjuvants to be added to local anesthetics still remain unclear.¹² The objectives of this study were to evaluate the potential benefits of dexmedetomidine or fentanyl when added to ropivacaine in TAP block for postoperative pain management and patient recovery after lower abdominal surgery.

Methods

This prospective randomized double-blind clinical trial was registered at www.clinicaltrials.gov under number ChiCTR-17011160 after approval from the ethics committee of Chongqing University Cancer Hospital, Chongqing, China (2016-50), and it was conducted in accordance with the Declaration of Helsinki. One hundred patients aged 18–60 years, with American Society of Anesthesiologists (ASA) class I–II status and body mass index (BMI) of 18.5–23.9, who were scheduled for open gynecological surgeries were enrolled in this study. All surgeries were performed with lower abdominal incision with the drainage tube inserted unilaterally. Exclusion criteria were as follows: bleeding diathesis, alcohol or drug abuse, opioid dependence, chronic pain, pain medication prior to surgery, infection at injection site, history of abdominal surgery or trauma, respiratory tract infection within 2 weeks, New York Heart Association class >II, and psychiatric illnesses that would interfere with perception and pain assessment (Figure 1). Patients were taught how to evaluate the visual analog scale (VAS) and QoR-40 questionnaire preoperatively. After written informed consent was obtained, patients were randomly allocated to four groups by using a computer-generated random number table. The group allocation information was concealed in sealed opaque envelopes, which were opened after patient's arrival to the operation room. Postoperative follow-ups were carried out by the third author (XZ).

All patients received induction with 1–2 mg midazolam and 0.3–0.5 µg/kg sufentanil along with target-controlled infusion of 2–4 ng/min propofol and 0.6 mg/kg rocuronium

to facilitate tracheal intubation. Anesthesia was maintained by sevoflurane (1–1.5 minimal alveolar concentration [MAC]). To assure suitable operating conditions, 0.03 mg/kg cisatracurium and 5–10 µg intravenous sufentanil bolus were given if the anesthesiologist deemed this to be necessary. The patients were intravenously administered 100 mg tramadol before the end of surgery. Ultrasound-guided TAP blocks were performed immediately using posterior approach by the same anesthesiologist on the patients after the completion of surgical procedures according to the grouping results. Patients underwent ultrasound-guided TAP block and received 40 mL of 0.375% ropivacaine hydrochloride (Markyrene®; Ropivacaine, AstraZeneca AB, Sodertalje, Sweden) which was divided into 20 mL and injected on each side.

To ensure blinding, the volume of the study medication was standardized at 40 mL, which was divided into 20 mL and injected on each side by ultrasound-guided TAP block. In this way, the four groups received injections as follows: 1) TAP group: 0.375% ropivacaine only; 2) TAP-DEX group: 1 µg/kg dexmedetomidine + 0.375% ropivacaine; 3) TAP-FEN group: 1 µg/kg fentanyl + 0.375% ropivacaine; and 4) control group: no TAP block.

All patients were carried to postanesthesia care unit (PACU) after the completion of TAP block. Reversal of the muscle relaxant was performed using neostigmine (0.04 mg/kg) and atropine (0.01 mg/kg) if needed. Postoperative analgesia comprised patient-controlled intravenous anesthesia (PCIA) with an initial sufentanil bolus of 2 µg once the VAS scores expressed by the patients were ≥3 as well as with a lockout period of 10 minutes. No background infusion was allowed for TAP groups, while 2 µg/hour background infusion of sufentanil was allowed in control group. If required, postoperative pain was treated with a PCIA bolus every 10 minutes to achieve a pain score less than or equal to 3, or until patients reported they were “comfortable”. Acetaminophen 325 mg (1–2 tablets by mouth every 4–6 hours, as needed) was given after the patients are sent back to ward. Ondansetron (4 mg) and droperidol (0.625 mg) were administered intravenously for postoperative nausea/vomiting (PONV). Patients were visited at 1, 2, 4, 8, 12, 24, and 48 hours by two follow-up investigators. The primary outcome in this study were the first request time for PCIA bolus and quality of recovery after surgery and anesthesia measured using QoR-40 questionnaire.^{13,14} The following observations were recorded: VAS scores at rest across the different time intervals and the total number of PCIA boluses required in 24 and 48 hours postoperatively. Additional data collected included the patient's age, sex, weight, height, BMI, and ASA physical status.

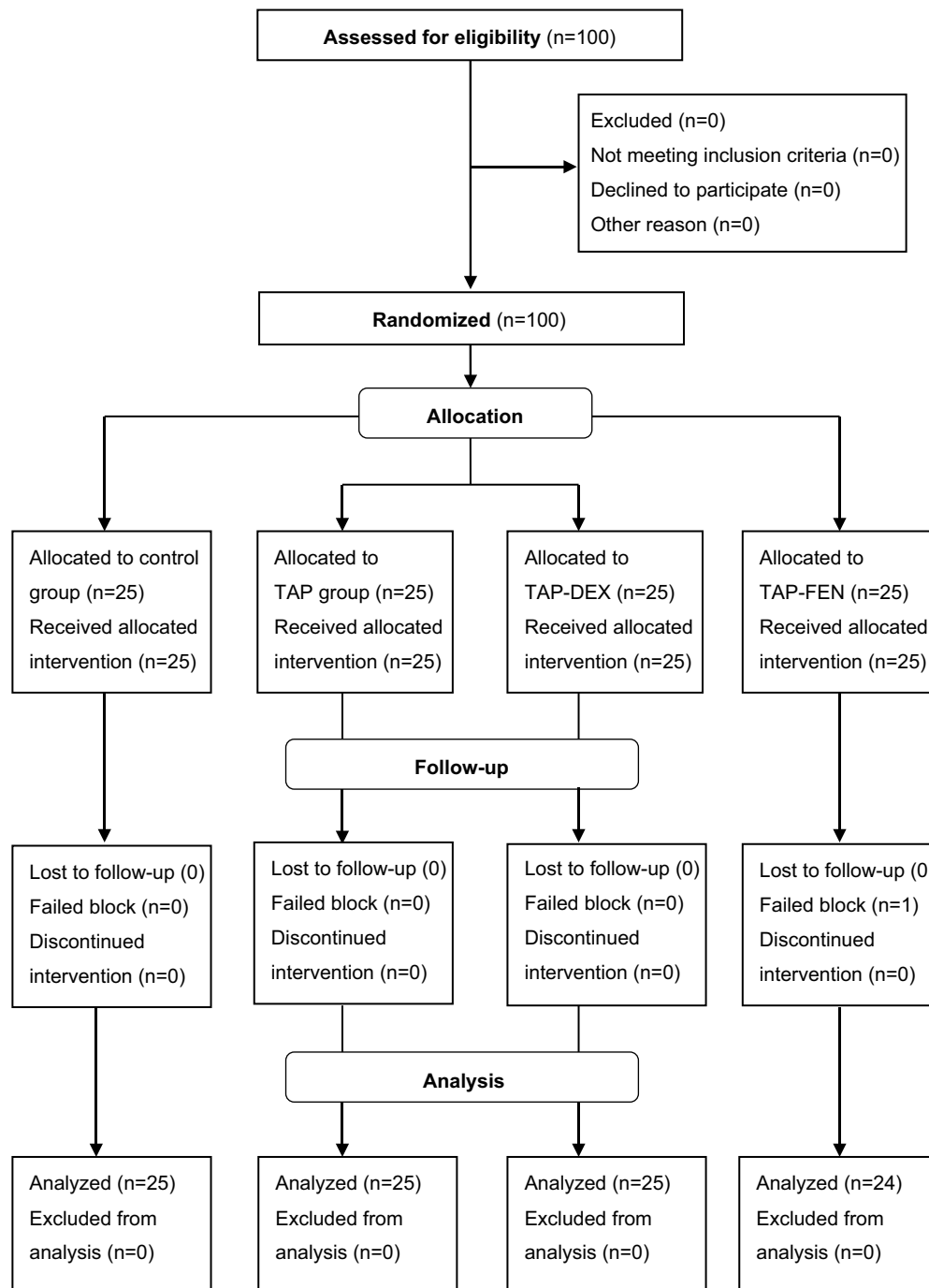


Figure 1 CONSORT flow diagram showing the number of patients at each phase of the study.
Abbreviation: TAP, transversus abdominis plane.

Statistical analysis

Study power

The sample size estimation was based on QoR-40 assumed scores (10-point difference) of a similar study performed by Sakamoto et al.¹⁵ To detect a 20% change in QoR-40 score with an error of 0.05 and a power of 80%, the minimum

sample size was found to be 23 patients per group. To account for dropouts, 100 patients were randomized.

Data analysis

Normally distributed interval data (age, weight, height, BMI, and time of TAP block) were reported as mean \pm SD values

and were evaluated using one-way ANOVA. Non-normally distributed interval and ordinal data (VAS scores, cumulative of remedial fentanyl bolus, and QoR-40 scores) were reported as median values (range or interquartile range) and were compared among groups using Kruskal–Wallis *H* test. Post hoc analysis was performed using Mann–Whitney *U* test with Bonferroni correction for multiple comparisons (four groups). Statistical analysis was performed using SPSS (Version 21.0; IBM Corporation, Armonk, NY, USA). Statistical significance in this study was set at $P < 0.05$. Statistical inference was evaluated at 5% level of significance.

Results

One hundred patients met the eligibility criteria and were randomized into one of the four groups (TAP, TAP-DEX, TAP-FEN, and control group) (Table 1). There were no significant differences in patients' characteristics and surgical profiles. The needle tip and local anesthesia diffusion were visualized using Mindray M7 ultrasound system.

Figure 2 shows that patients in TAP-DEX group had the longest effective analgesia among all three TAP groups (9.86 hours in TAP-DEX group, 8.79 hours in TAP-FEN group, and 7.86 hours in TAP group); TAP-DEX provided an additional 64 minutes (11.9%) of analgesia time compared with the TAP-FEN group ($P < 0.001$) and an additional 118.8 minutes of pain relief which is a relative increase of 25.2% compared with the TAP group ($P < 0.001$), whereas the control group required remedial analgesia 6 hours earlier than the TAP groups ($P < 0.01$).

Figure 3 summarizes the VAS scores at rest across the different time intervals and reveals that the VAS score was significantly lower in all TAP groups than in the control group at 1, 2, 4, and 8 hours postoperatively ($P < 0.05$) and there were significant differences in scores between TAP-DEX and TAP-FEN groups only at 6 hours ($P < 0.01$). At the same time, Figure 4 shows that the total number of PCIA boluses was significantly lower in TAP-DEX group compared with TAP-FEN and TAP groups at both 24 and 48 hours ($P < 0.05$).

Table 1 Patients' characteristics

	Control (n=25)	TAP (n=25)	TAP-DEX (n=25)	TAP-FEN (n=25)
Age (years)	45.04±7.57	45.28±7.30	46.80±7.75	45.95±7.21
Weight (kg)	52.96±6.41	53.76±6.20	53.44±6.25	54.47±6.32
Height (cm)	157.72±5.56	158.72±5.01	157.08±5.00	155.58±5.23
Body mass index (kg/m ²)	21.26±2.07	21.31±2.05	21.73±2.96	22.50±2.33
ASA class I/II status	10/15	13/12	14/11	11/13
Type of surgery				
Myomectomy	10	6	7	9
Ovarian cystectomy	7	10	8	7
Total hysterectomy	8	9	10	9
Duration of surgery (minutes)	70.56±6.12	73.00±6.50	72.48±5.85	72.42±4.92

Notes: All values are presented as mean ± SD or number of patients. There were no significant differences in parameters between groups.

Abbreviations: ASA, American Society of Anesthesiologists; TAP, transversus abdominis plane.

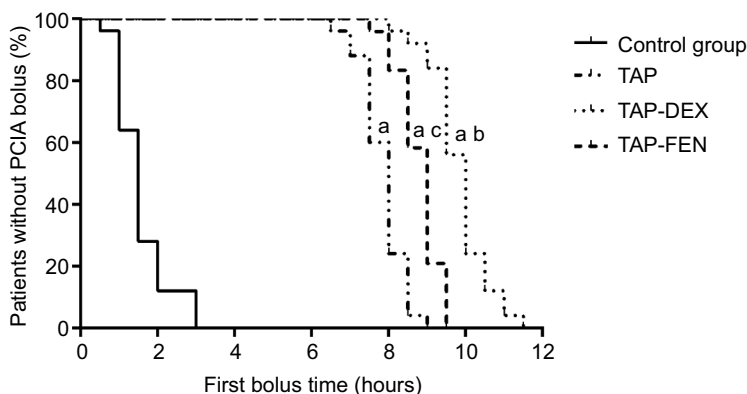


Figure 2 Assessment of the time of request of PCIA bolus. Data are expressed as mean ± SD.

Notes: ^aStatistical significance when compared with control group. ^bStatistical significance when compared with TAP group. ^cStatistical significance when compared with TAP-DEX group.

Abbreviations: PCIA, patient-controlled intravenous analgesia; TAP, transversus abdominis plane.

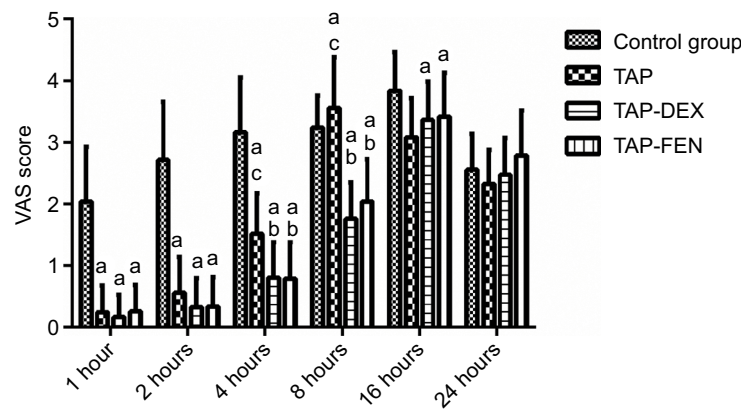


Figure 3 Pain evaluation at rest using VAS (0–100 mm, mean \pm SD) at 1 to 24-hour postoperative interval.

Notes: ^aStatistical significance when compared with control group. ^bStatistical significance when compared with TAP group. ^cStatistical significance when compared with TAP-DEX group.

Abbreviations: TAP, transversus abdominis plane; VAS, visual analog scale.

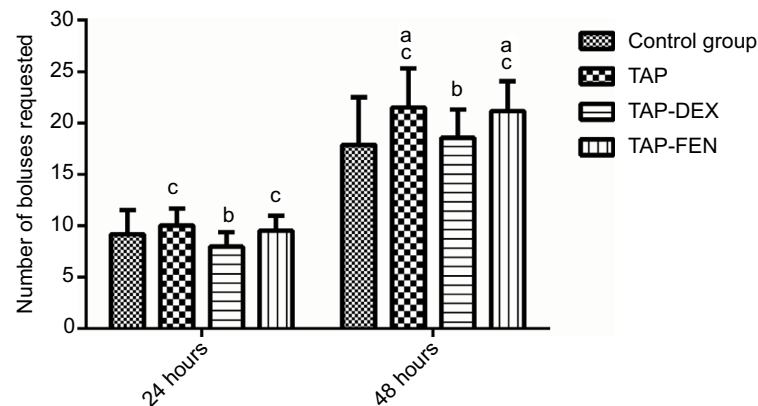


Figure 4 Cumulative opioid consumption based on the number of PCIA bolus requested at 24 and 48 hours postoperatively.

Notes: ^aStatistical significance when compared with control group. ^bStatistical significance when compared with TAP group. ^cStatistical significance when compared with TAP-DEX group.

Abbreviations: PCIA, patient-controlled intravenous analgesia; TAP, transversus abdominis plane.

Table 2 presents the assessment of recovery after surgery by QoR-40 questionnaire and shows that patients in all TAP groups had better QoR-40 scores on postoperative day 2. Although adequate postoperative analgesia was experienced by all groups, the QoR-40 score was lowest in the control group and highest in the TAP-DEX group, with a significant difference between these two groups ($P < 0.05$).

All groups were hemodynamically stable and required no injection of ephedrine after the TAP block. No bleeding, penetration of the peritoneum, or local anesthetic toxicity was found, but oversedation was recorded in one patient in TAP-DEX group. One patient could not tell the blocking scope and was excluded from the research. No patients developed postoperative complications such as infection or poor wound healing both during hospitalization and during the 4 weeks of follow-up. The incidence of PONV was recorded and

assessed using QoR-40 questionnaire. As noted, we did not observe any obvious delay in discharge of the patients from PACU in any group.

Discussion

This study evaluated the relative efficacy of and quality of early recovery initiated by dexmedetomidine vs those associated with fentanyl with regard to their roles as adjuvants for postoperative analgesia facilitated by the use of ultrasound-guided TAP block in gynecological surgery. We found that dexmedetomidine as an adjuvant to TAP blocks enhanced analgesia, reduced total systemic opiate consumption, and improved the quality of recovery without increasing postoperative complications.

The combination of peripheral nerve blocks and intravenous PCIA for postoperative analgesia in abdominal surgery

Table 2 QoR-40 questionnaire scores

Domain	Control (n=25)	TAP (n=25)	TAP-DEX (n=25)	TAP-FEN (n=24)	P-value
Comfort	47.20±1.73	52.04±2.37 ^a	54.08±1.89 ^a	52.08±2.35 ^a	<0.01
Emotions	40.28±1.10	40.68±1.14	40.88±1.01	40.92±1.53	0.271
Physical independence	20.60±1.08	20.92±1.03	20.88±1.24	20.88±1.11	0.815
Patient support	33.68±0.95	32.68±1.22 ^a	32.60±1.38 ^a	32.38±1.14 ^a	0.01
Pain	27.88±1.36	30.92±1.55 ^a	32.48±1.08 ^{a,b}	31.25±1.59 ^a	<0.01
Global	169.68±2.91	177.24±2.77 ^a	180.92±2.97 ^{a,b}	177.50±3.62 ^{a,c}	<0.01

Notes: Differences in the QoR-40 scores were analyzed using Kruskal–Wallis *H* test. Post hoc analysis was performed using Mann–Whitney *U* test if necessary. ^aStatistical significance when compared with control group. ^bStatistical significance when compared with TAP group. ^cStatistical significance when compared with TAP-DEX group.

Abbreviation: TAP, transversus abdominis plane.

has been extensively studied. Abdallah et al reported that TAP block has advantages as part of multimodal analgesia in abdominal surgery.¹⁶ Hebbard raised a subcostal TAP block, which is advantageous for the periumbilical region blocking during upper abdominal surgery.¹⁷

Regular gynecological incisions were performed through the midline, ~5 cm below the xiphoid and 5 cm below the umbilicus. The results from this study also indicate that the TAP block provided good-quality blocking from T8 to T12 sensory range for lower abdominal surgery. Due to insufficient analgesia and time of single TAP blocking as well as instability while placing the catheter into the abdominal wall, adjuvants have become the preferable choice to extend the duration of local anesthetics.^{18,19} In our study, all the patients who received TAP block were evaluated for the effect of postoperative analgesia through VAS at rest. In particular, remedial analgesia consumption significantly decreased and QoR-40 scores improved, indicating better postoperative recovery.

To maximize the duration of sensory blocking, multiple adjuvants have been introduced in daily clinical practice. Opioids and other additions (dexamethasone or dexmedetomidine) have been used for TAP block procedures.^{18,20,21} Nevertheless, it is documented that ropivacaine precipitates into crystal at a pH of 6.0 or above and adjuvants with TAP block might affect a patient's recovery and this should be taken into consideration.¹⁶ However, there were no reports on the optimal dose of dexmedetomidine for TAP blocks.²² Zhang et al showed that 100 µg alone as opposed to 50 µg dexmedetomidine worked in axillary brachial block in combination with ropivacaine.²³ Xu et al reported that multilevel thoracic paravertebral block using ropivacaine with 1 µg/kg dexmedetomidine could enhance postoperative analgesia and improve patient's satisfaction.²⁴ In the interest of safety, we administered 1 µg/kg dexmedetomidine and 1 µg/kg fentanyl which is a commonly used dosage for perineural blocks with

0.375% ropivacaine in our patients. In the present study, the VAS and QoR-40 scores were similar in the three TAP groups; however, compared with fentanyl, dexmedetomidine reduced the amount of remedial analgesia required and extended the block time by nearly 1.1 hour at an average. Meanwhile, the QoR-40 scores were significantly improved with the use of dexmedetomidine. At this concentration, no toxicity was found, which is consistent with the findings of Ding et al.²² Dexmedetomidine selective acts on α_2 -adrenoceptor with little effect on vasoconstriction at low concentrations, while fentanyl has high lipid solubility and rapid tissue uptake which limits its effect.⁷ Despite this study showing promising results with the use of dexmedetomidine, the optimal dosage still needs to be further explored.

The present study still has several limitations. First, we were unable to measure the onset time of TAP block because the patients did not fully recover from general anesthesia. Second, we did not assess the concentration–effect curves of dexmedetomidine and fentanyl. Finally, we did not analyze the plasma concentration of ropivacaine affected by dexmedetomidine or fentanyl.

Conclusion

Based on our findings, we suggest that TAP block is a preferable choice of multimodal analgesia for gynecological surgeries. The addition of dexmedetomidine to ropivacaine in TAP block has potential benefits for improving the quality of patient recovery, with better analgesia but lower analgesic consumption.

Data sharing statement

Since we have elaborated on the formulation and results of the various experimental groups in the manuscript, and further research is still in progress, we do not want to share the raw data obtained so far. If readers have any questions, they can send email to us directly and we will answer in detail.

Acknowledgments

The authors are grateful to Dr Zifeng Xu (International Peace Maternal and Child Health Hospital, Shanghai Jiaotong University) and Dr Ran An (Chongqing University Cancer Hospital/Chongqing Cancer Institute) for the constructive comments on our project. This work was supported by the Foundation of National Cancer Center in China (NCC2017A06 to Bin Yang).

Author contributions

All authors contributed to data analysis, drafting and revising the article, gave final approval of the version to be published, and agree to be accountable for all aspects of the work.

Disclosure

The authors report no conflicts of interest in this work.

References

- McDonnell JG, O'Donnell B, Curley G, Heffernan A, Power C, Laffey JG. The analgesic efficacy of transversus abdominis plane block after abdominal surgery: a prospective randomized controlled trial. *Anesth Analg*. 2007;104(1):193–197.
- Hebbard P, Fujiwara Y, Shibata Y, Royse C. Ultrasound-guided transversus abdominis plane (TAP) block. *Anaesth Intensive Care*. 2007;35(4):616–617.
- Niraj G, Searle A, Mathews M, et al. Analgesic efficacy of ultrasound-guided transversus abdominis plane block in patients undergoing open appendectomy. *Br J Anaesth*. 2009;103(4):601–605.
- Kanazi GE, Aouad MT, Abdallah FW, et al. The analgesic efficacy of subarachnoid morphine in comparison with ultrasound-guided transversus abdominis plane block after cesarean delivery: a randomized controlled trial. *Anesth Analg*. 2010;111(2):475–481.
- Sharma P, Chand T, Saxena A, Bansal R, Mittal A, Shrivastava U. Evaluation of postoperative analgesic efficacy of transversus abdominis plane block after abdominal surgery: a comparative study. *J Nat Sci Biol Med*. 2013;4(1):177–180.
- Young MJ, Gorlin AW, Modest VE, Quraishi SA. Clinical implications of the transversus abdominis plane block in adults. *Anesthesiol Res Pract*. 2012;2012:731645–11.
- Yaghoobi S, Seddighi M, Yazdi Z, Ghafouri R, Khezri MB. Comparison of postoperative analgesic effect of dexamethasone and fentanyl added to lidocaine through axillary block in forearm fracture. *Pain Res Treat*. 2013;2013:761583–6.
- Shah DM, Arora M, Trikha A, et al. Comparison of dexamethasone and clonidine as an adjuvant to 1.5% lignocaine with adrenaline in infraclavicular brachial plexus block for upper limb surgeries. *J Anaesthesiol-ClinPharmacol*. 2015;31:354–359.
- Sun J, Feng X, Zhu Q, et al. Analgesic effect of perineural magnesium sulphate for sciatic nerve block for diabetic toe amputation: a randomized trial. *PLoS One*. 2017;12(5):e0176589.
- Othman AH, El-Rahman AM, El Sherif F. Efficacy and safety of ketamine added to local anesthetic in modified pectoral block for management of postoperative pain in patients undergoing modified radical mastectomy. *Pain Physician*. 2016;19(7):485–494.
- Kirksey MA, Haskins SC, Cheng J, Liu SS. Local anesthetic peripheral nerve block adjuvants for prolongation of analgesia: a systematic qualitative review. *PLoS One*. 2015;10(9):e0137312.
- Brummett CM, Padda AK, Amodeo FS, Welch KB, Lydic R. Perineural dexmedetomidine added to ropivacaine causes a dose-dependent increase in the duration of thermal antinociception in sciatic nerve block in rat. *Anesthesiology*. 2009;111(5):1111–1119.
- Myles PS, Weitkamp B, Jones K, Melick J, Hensen S. Validity and reliability of a postoperative quality of recovery score: the QoR-40. *Br J Anaesth*. 2000;84(1):11–15.
- Gower ST, Quigg CA, Hunt JO, Wallace SK, Myles PS. A comparison of patient self-administered and investigator-administered measurement of quality of recovery using the QoR-40. *Anaesth Intensive Care*. 2006;34(5):634–638.
- Sakamoto B, Harker G, Eppstein AC, Gwartz K. Efficacy of local anesthetic with dexamethasone on the quality of recovery following total extraperitoneal bilateral inguinal hernia repair: a randomized clinical trial. *JAMA Surg*. 2016;151(12):1108–1115.
- Abdallah FW, Chan VW, Brull R. Transversus abdominis plane block: a systematic review. *Reg Anesth Pain Med*. 2012;37(2):193–209.
- Hebbard P. Subcostal transversus abdominis plane block under ultrasound guidance. *Anesth Analg*. 2008;106(2):674–675.
- Deshpande JP, Ghodki PS, Sardesai SP. The analgesic efficacy of dexamethasone added to ropivacaine in transversus abdominis plane block for transabdominal hysterectomy under subarachnoid block. *Anesth Essays Res*. 2017;11(2):499–502.
- Brummett CM, Hong EK, Janda AM, Amodeo FS, Lydic R. Perineural dexmedetomidine added to ropivacaine for sciatic nerve block in rats prolongs the duration of analgesia by blocking the hyperpolarization-activated cation current. *Anesthesiology*. 2011;115(4):836–843.
- Almarakbi WA, Kaki AM. Addition of dexmedetomidine to bupivacaine in transversus abdominis plane block potentiates post-operative pain relief among abdominal hysterectomy patients: a prospective randomized controlled trial. *Saudi J Anaesth*. 2014;8(2):161–166.
- Wang LZ, Liu X, Zhang YF, Hu XX, Zhang XM. Addition of fentanyl to the ultrasound-guided transversus abdominis plane block does not improve analgesia following cesarean delivery. *Exp Ther Med*. 2016;11(4):1441–1446.
- Ding W, Li W, Zeng X, et al. Effect of adding dexmedetomidine to ropivacaine on ultrasound-guided dual transversus abdominis plane block after gastrectomy. *J Gastrointest Surg*. 2017;21(6):936–946.
- Zhang Y, Wang CS, Shi JH, et al. Perineural administration of dexmedetomidine in combination with ropivacaine prolongs axillary brachial plexus block. *Int J Clin Exp Med*. 2014;7(3):680–685.
- Xu J, Yang X, Hu X, Chen X, Zhang J, Wang Y. Multilevel thoracic paravertebral block using ropivacaine with/without dexmedetomidine in video-assisted thoracoscopic surgery. *J Cardiothorac Vasc Anesth*. 2018;32(1):318–324.

Journal of Pain Research

Publish your work in this journal

The Journal of Pain Research is an international, peer reviewed, open access, online journal that welcomes laboratory and clinical findings in the fields of pain research and the prevention and management of pain. Original research, reviews, symposium reports, hypothesis formation and commentaries are all considered for publication.

Submit your manuscript here: <https://www.dovepress.com/journal-of-pain-research-journal>

Dovepress

The manuscript management system is completely online and includes a very quick and fair peer-review system, which is all easy to use. Visit <http://www.dovepress.com/testimonials.php> to read real quotes from published authors.