

Pulmonary artery stenting in a patient with Takayasu's arteritis using a novel balloon-expandable covered stent

SAGE Open Medical Case Reports
Volume 7: 1–3
© The Author(s) 2019
Article reuse guidelines:
sagepub.com/journals-permissions
DOI: 10.1177/2050313X19841955
journals.sagepub.com/home/sco



Barry S Weinstock^{1,2}  and Yitzhak Daniel Haim¹

Abstract

Patients with Takayasu's arteritis have pulmonary artery involvement more commonly than previously appreciated. The majority of these lesions are in segmental or sub-segmental arteries, but there are some patients who have severe stenosis of the main pulmonary arteries. Interventional treatment of these patients is technically feasible, but there are only limited case reports describing such intervention. Balloon angioplasty and stenting in these lesions often require high pressure inflations to achieve adequate results and thus has increased risk due to the possibility of pulmonary artery rupture. The recently approved Viabahn BX balloon-expandable covered stent may be an optimal device for main pulmonary artery stenosis as it is relatively low profile, can be over-expanded to large vessel diameter without compromise or disruption of the polytetrafluoroethylene covering and virtually eliminates the risk of catastrophic pulmonary artery rupture. We report here the first known use of this novel stent for treatment of severe pulmonary artery stenosis.

Keywords

Cardiovascular, Takayasu's arteritis, pulmonary hypertension, stent

Date received: 23 December 2018; accepted: 14 March 2019

Introduction

There is limited experience with balloon angioplasty and stenting of pulmonary artery (PA) stenosis in patients with inflammatory conditions, such as Takayasu's arteritis. PA involvement in Takayasu's patients has been reported by Qin et al. in 86% of patients. They treated one patient with balloon angioplasty and three with stenting.¹ The uncertainty regarding the optimal stent for PA stenosis is evident from the use of three different stents—a balloon-expandable covered stent, a self-expanding nitinol stent and a balloon-expandable stainless-steel stent. The largest stent diameter utilized in any of these studies was 10 mm. Although PA involvement is common, most lesions are found in segmental or sub-segmental arteries with involvement of the main PA representing only 5% of PA stenoses.² In 2004, Tyagi et al.³ reported a single patient with right PA stenosis treated with a balloon-expandable covered stent. A case report from 2007 described stenting of a PA for management of severe Takayasu's related pulmonary hypertension,⁴ but details of the stent utilized were not provided.

In Takayasu patients, inflammatory changes and fibrosis lead to wall thickening, luminal stenosis and occlusion. These

lesions often require high-pressure balloon dilatation which increases the risk of complications, including dissection and vessel rupture. Stenting can improve the final lumen diameter compared to that obtained with angioplasty, but may further increase the risk of rupture if high balloon inflation pressures are required to achieve complete stent expansion. The use of a covered stent is attractive to reduce the risk of catastrophic PA rupture. However, previously available covered stents were only available in diameters smaller than that of most main PA's.

Case report

A 50-year-old woman with Takayasu's arteritis was admitted with left sided pneumonia after a several year history of exertional dyspnea. A CT angiogram was obtained and revealed severe stenosis of the right main PA, resulting in

¹AdventHealth Orlando, Orlando, FL, USA

²Orlando Heart & Vascular Institute, Altamonte Springs, FL, USA

Corresponding author:

Barry S Weinstock, Orlando Heart & Vascular Institute, 450 W Central Parkway, Altamonte Springs, FL 32714, USA.

Email: bweinstock@heartorlando.com



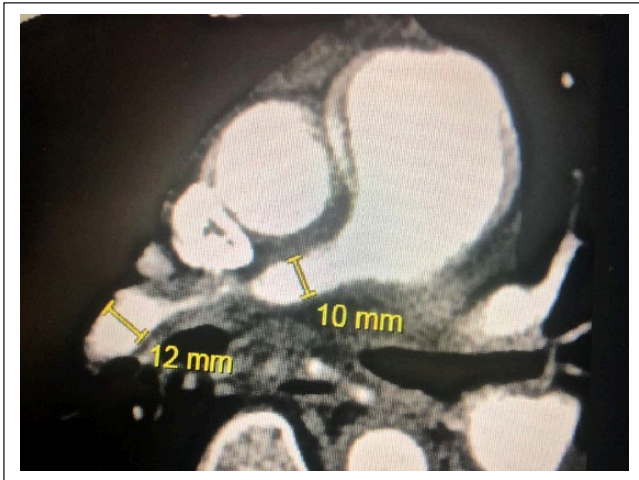


Figure 1. CT angiogram of right pulmonary artery.

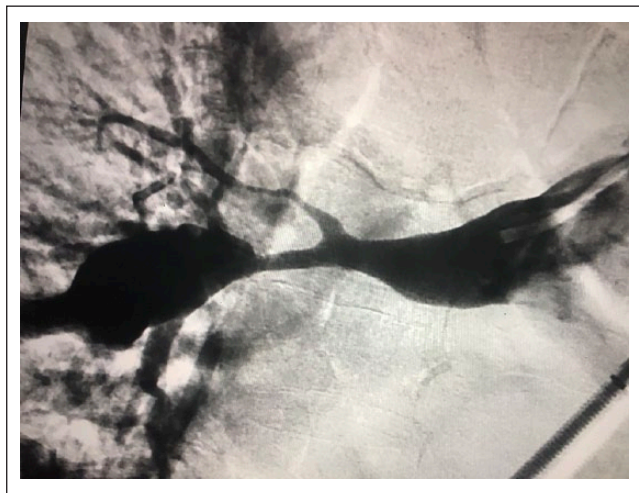

Figure 2. Selective right pulmonary artery baseline angiogram.

marked reduction in blood flow to the right lung (Figure 1). Echocardiography demonstrated normal left ventricular (LV) function, moderate tricuspid regurgitation and estimated PA pressure of 62 mmHg. To minimize the risk of PA rupture, we planned to use the Viabahn BX balloon-expandable covered stent (W.L. Gore & Associates, Inc., Flagstaff, AZ) as definitive treatment. Due to the risk of post-procedure pulmonary edema, the patient was electively intubated prior to the procedure. An 8F 90 cm sheath (Pinnacle Destination, Terumo Medical Corp., Somerset, NJ) was advanced from the right common femoral vein to the main PA. A 7F AL-1 coronary guide catheter (Cordis/Cardinal Health, Inc., Dublin, OH) was used for selective angiography (Figure 2) and to advance a 0.018 V18 wire (Boston Scientific, Inc., Marlborough, MA) to the distal right PA. Systemic anticoagulation was achieved with intravenous heparin. The right PA was then studied with intravascular ultrasound imaging (Visions PV, Philips N.V., Amsterdam,

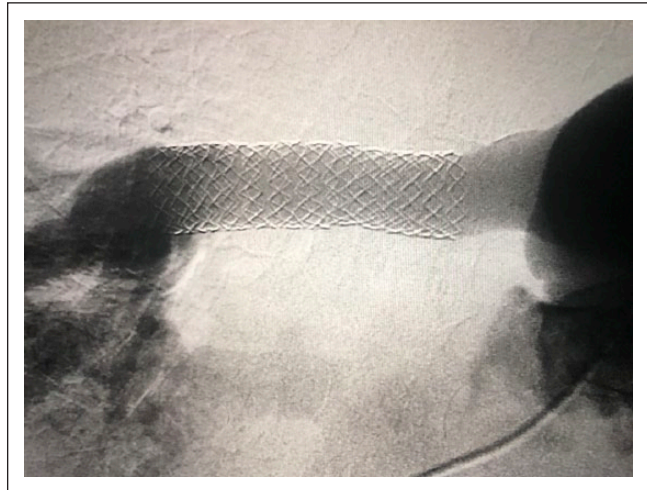


Figure 3. Final angiogram. Right pulmonary artery after Viabahn BX stent.

Netherlands) which confirmed severe stenosis of 96% (lesion cross-sectional area 5.7 mm² with reference area 157.0 mm²) due to fibrotic thickening of the vessel wall due primarily to thickening of the media. The PA diameter was measured at 14 mm. The stenosis was dilated using a 7 mm x 40 mm angioplasty balloon (Pacific Plus, Medtronic, Inc., Minneapolis, MN) and a 10 mm x 40 mm angioplasty balloon (Evercross, Medtronic, Inc.). The result appeared sub-optimal with 60% residual stenosis and an irregular appearance to the luminal wall. Lesion length was estimated at 40 mm. The 0.018" wire was exchanged for a 260 cm 0.035" J-tipped guide wire. The AL-1 guide catheter and the 8F 90 cm sheath were exchanged for an 8F 45 cm sheath (Terumo Medical Corp, Inc.). (A shorter sheath was required as the 14 mm angioplasty balloon planned for post-stent dilatation was only available with a 75 cm shaft). An 11 mm x 59 mm Viabahn BX stent was advanced to the stenosis and deployed. The stent was further dilated with a 14 mm x 60 mm angioplasty balloon (Atlas, C.R. Bard, Inc., Murray Hill, NJ) which resulted in the expected foreshortening of the 59 mm stent to a final length of 42 mm. Final angiography revealed no residual stenosis with satisfactory stent position (Figure 3). As anticipated, the patient developed pulmonary edema post-procedurally which resolved in 48 h with aggressive diuresis allowing extubation. Systemic anticoagulation (for paroxysmal atrial fibrillation) was resumed with Rivaroxaban 20 mg daily. Clopidogrel 75 mg daily was added and will be administered indefinitely for anti-platelet effect to minimize the risk of stent thrombosis. A repeat echocardiogram obtained 1 week after the procedure showed only minimal decrease in estimated PA pressure compared to baseline (57 mmHg vs. 62 mmHg). She underwent a CT angiogram 3 months post-procedure which showed the PA stent to be widely patent with no evidence of restenosis, and she was stable without dyspnea at 6-month clinical follow-up.

Discussion

This patient with Takayasu's arteritis had a critical right PA stenosis which was not diagnosed until she developed pneumonia and underwent CT angiography. Left untreated, this stenosis likely would have progressed to total occlusion. The risk of PA rupture is apparent from the tendency of previous operators to utilize a covered stent (JoStent, Jo Med, Inc.), rather than a bare metal stent. However, the previously available covered stents have size limitations which make them sub-optimal for use in the PA. The Viabahn BX covered stent has the unique capacity to be over-expanded without disruption of the polytetrafluoroethylene (PTFE) covering with a maximum achievable diameter of 16 mm. This over-expansion results in predictable foreshortening which must be considered when selecting a stent. While the acute angiographic result appears optimal, there is inadequate data to predict the rate of restenosis or occlusion in the PA. In a small series reported by Qureshi et al.,⁵ restenosis rates were lower in patients with Takayasu's arteritis treated with covered stent-grafts, rather than with bare metal stents for vascular occlusive disease. Patency rates with Viabahn BX have been high in complex atherosclerotic aorto-iliac procedures,⁶ but it is unknown if those results can be extrapolated to the PA circulation particularly in patients with an inflammatory rather than atherosclerotic etiology. Nonetheless, the Viabahn BX stent may be the best option available for PA procedures due to the enhanced safety provided by a covered stent and due to its ability to be "over-dilated" to diameters of up to 16 mm. Although long-term anti-platelet therapy is planned for this patient, there is no standardized recommendation for anti-platelet or anti-coagulant therapy after placement of a Viabahn BX stent.⁷

Conclusion

Severe stenosis of the main PAs due to Takayasu's arteritis occurs more frequently than previously appreciated. There is limited data concerning treatment of this inflammatory rather than atherosclerotic lesion. Percutaneous therapy is desirable due to the considerable morbidity and mortality associated with surgical intervention. To minimize the risk of catastrophic PA rupture, covered stents although undersized have been used by some operators in the past for PA stenting. This report describes the first use of the Viabahn BX balloon-expandable PTFE covered stent for treatment of severe PA stenosis due to Takayasu's arteritis. The ability of this stent to be over-expanded from its nominal diameter of 10 mm to a final diameter of up to 16 mm without compromising the integrity of the PTFE endograft makes this device potentially

ideally suited for this complex application. Continued follow-up is required to better understand the long-term patency rate associated with this procedure.

Declaration of conflicting interests

The author(s) declared the following potential conflicts of interest with respect to the research, authorship, and/or publication of this article: B.S.W. is a member of the speaker's bureau for W.L. Gore & Associates, but did not receive any support for this case report. Y.D.H. has no conflict of interest.

Ethical approval

Our institution does not require ethical approval for reporting individual cases or case series.

Funding

The author(s) received no financial support for the research, authorship and/or publication of this article.

Informed consent

Informed consent for patient information to be published in this article was obtained from the patient via email by B.S.W.

ORCID iD

Barry S Weinstock  <https://orcid.org/0000-0002-8211-5471>

References

1. Qin L, Hong-Liang Z, Zhi-Hong L, et al. Percutaneous transluminal angioplasty and stenting for pulmonary stenosis due to Takayasu's arteritis: clinical outcome and four-year follow-up. *Clin Cardiol* 2009; 32(11): 639–643.
2. Yamada I, Shibuya H, Matsubara O, et al. Pulmonary artery disease in Takayasu's arteritis: angiographic findings. *AJR* 1992; 159: 263–269.
3. Tyagi S, Mehta V, Kashyap R, et al. Endovascular stent implantation for severe pulmonary artery stenosis in aortoarteritis (Takayasu's arteritis). *Catheter Cardiovasc Interv* 2004; 61(2): 281–285.
4. Garcia-Olivé I, Prats Bardají MS, Calvo Pascual S, et al. Severe pulmonary hypertension and Takayasu arteritis. *Arch Bronconeumol* 2008; 44(3): 170–172.
5. Qureshi MA, Martin Z and Greenberg RK. Endovascular management of patients with Takayasu arteritis: stents versus stent grafts. *Semin Vasc Surg* 2011; 24(1): 44–52.
6. Bismuth J, Gray BH, Holden A, et al. Pivotal study of a next-generation balloon-expandable stent-graft for treatment of iliac occlusive disease. *J Endovasc Ther* 2017; 24(5): 629–637.
7. Ullery B, Tran K, Itoga N, et al. Safety and efficacy of anti-platelet/anticoagulation regimens after Viabahn stent graft treatment for femoropopliteal occlusive disease. *J Vasc Surg* 2015; 61(6): 1479–1488.