


Case Report

Preoperative simulation by volume rendering image and intraoperative navigation by ultrasound for posterior urethroplasty: A report of initial three cases

Akihiro Kanematsu,¹  Kenji Nakamura,² Noriko Kotoura,² Takahiko Hashimoto¹ and Shingo Yamamoto¹

Departments of ¹Urology, and ²Radiation Technology, Hyogo College of Medicine, Nishinomiya, Hyogo, Japan

Abbreviations & Acronyms

EPA = excision and primary anastomosis
MRI = magnetic resonance imaging
TRUS = transrectal ultrasound
VR = volume rendering

Correspondence: Akihiro Kanematsu M.D., Ph.D., Department of Urology, Hyogo College of Medicine, 1-1 Mukogawacho, Nishinomiya, Hyogo 663-8501, Japan.
Email: aqui@hyo-med.ac.jp

This is an open access article under the terms of the Creative Commons Attribution-NonCommercial-NoDerivs License, which permits use and distribution in any medium, provided the original work is properly cited, the use is non-commercial and no modifications or adaptations are made.

Received 23 October 2018; accepted 3 December 2018.
Online publication 9 January 2019

Introduction: In posterior urethroplasty, exposure of the proximal urethral stump is the most important step that determines surgical outcome. However, this is sometimes difficult due to deviation of the prostate or overlying scar tissue. We present a novel preoperative simulation and intraoperative navigation method for this step.

Case presentation: Three patients underwent excision and primary anastomosis for posterior urethral disruption after pelvic fracture. Preoperatively, volume-rendering image of the posterior urethra was constructed from gadolinium-enhanced magnetic resonance image, enabling simulation from the viewpoint of the operator in all three cases. Intraoperative navigation was performed in two patients by using transrectal ultrasound, visualizing the acoustic shadow of a cystoscope inserted into the prostatic urethra via the cystostomy tract. The overlying scar tissue was removed toward the urethral stumps identified by navigation. Urethroplasty was successful in all three patients.

Conclusion: The present methods were useful for precise identification of the proximal urethral stump.

Key words: intraoperative navigation, magnetic resonance imaging, transrectal ultrasound, urethroplasty, volume-rendering imaging.

Keynote message

We hereby report on three cases where preoperative simulation and intraoperative navigation for locating the proximal urethral stump was carried out in posterior urethroplasty for urethral disruption due to pelvic fracture. MRI-based VR images enabled preoperative simulation, and TRUS enabled intraoperative navigation. Each of these methods, as well as a combination of both, was useful for precise exposure of the stump and enabled successful end-to-end anastomosis.

Introduction

In transperineal reconstruction of the posterior urethra, exposure of the proximal urethral stump is the most important step that determines surgical success.^{1,2} To access the stump, scar tissue is removed under the guidance of the cystoscope light in the proximal urethra. If the light is invisible, approximate location of the stump is identified by palpation of a metal bougie inserted via the cystostomy tract. However, this step is sometimes difficult when the prostate is deviated due to trauma, or massive scarring is present, and blind palpation has risk of false passage. When the proximal stump can hardly be identified, some authors recommend a more invasive abdomino-perineal reconstruction.¹ To overcome this problem, we developed a preoperative simulation method by using a VR image produced from MRI combined with an intraoperative navigation method guided by TRUS. We tested the utility of the methods in three cases of posterior urethroplasty.

Case presentation

Three male patients underwent EPA for membranous urethral disruption due to pelvic fracture. The profile of the patients are summarized in Table 1. The Institutional Review Board approved the study. The patients submitted written informed consent for publishing the clinical image.

For preoperative simulation, the VR image of the urethra was constructed from thin-slice gadolinium-enhanced MRI to visualize the healthy urethral mucosa. The VR image in sagittal view corresponded to standard combined cystourethrogram with additional information of scar tissue in various 3-dimensional views (Fig. 1a,b). The VR images in transverse view were similar to the surgical view from the operator and enabled preoperative simulation in all three cases (Fig. 2).

Intraoperatively, after the bulbus was isolated, the cystoscope was inserted via the cystostomy tract for light guidance. Intraoperative TRUS was performed to locate the proximal stump if the stump could not be visualized with the cystoscope light alone due to deviation of the prostate or scarring.

Case 1 was a 48-year-old otherwise healthy man. He was buried in the ground while working on plumbing, and had bilateral pubic bone fracture. Case 2 was a 53-year-old man. He fell from a 2-m high position to the ground, and had a bone fracture in the pelvis and left femur. In both cases, patients were referred to our hospital after a suprapubic

cystostomy tube was inserted, and underwent EPA 5 months after the injury. In these two cases, the stump could not be visualized after the transection of the bulbus by the light of a flexible cystoscope in the prostatic urethra, due to deviation of the prostate and scarring. However, intraoperative TRUS could locate the proximal stump by visualizing the acoustic shadow of the cystoscope (Fig. 3a). An 18-G needle was inserted under ultrasound and cystoscope guidance to the prostatic urethra past the stump, and the scar was removed toward the direction of the needle (Fig. 3b).

Case 3 was a 62-year-old man. He was run over by a feast parade float (called 'Danjiri' in Japanese) and had a pelvic fracture. He underwent EPA 5 months after the injury. In this case, the proximal stump was easily found after transection of bulbus without a need for further TRUS navigation.

The time needed for the exposure of the proximal stump, from transection of bulbus to initiation of anastomosis, was 47, 50, and 27 min in Cases 1, 2, and 3, respectively. The first two cases needed longer time than Case 3 for identification of the invisible stump, and TRUS guidance seemed to minimize unnecessary hesitation at this step.

All three patients are currently able to void without incontinence. In all cases, flexible cystoscope could be passed through the anastomosis 3 months postoperatively.

The patient in Case 1 experienced erectile dysfunction after the pelvic fracture, which temporarily worsened after urethroplasty, but he is still recovering. The other two patients had

Table 1 Summary of cases

Case	Age (years)	Length of defect (mm)	Deviation of the proximal stump	MRI simulation	TRUS navigation	Postoperative uroflowmetry			
						Voided volume (mL)	Qmax (mL/s)	Postvoid residual (mL)	Postoperative cystoscopy
1	47	15	No	Yes	Yes	206	17	10	Passed (3 m)
2	52	15	Yes (posterolateral)	Yes	Yes	285	21.6	3	Passed (3 m)
3	64	15	Yes (lateral)	Yes	No	188	13.2	0	Passed (3.5 m)

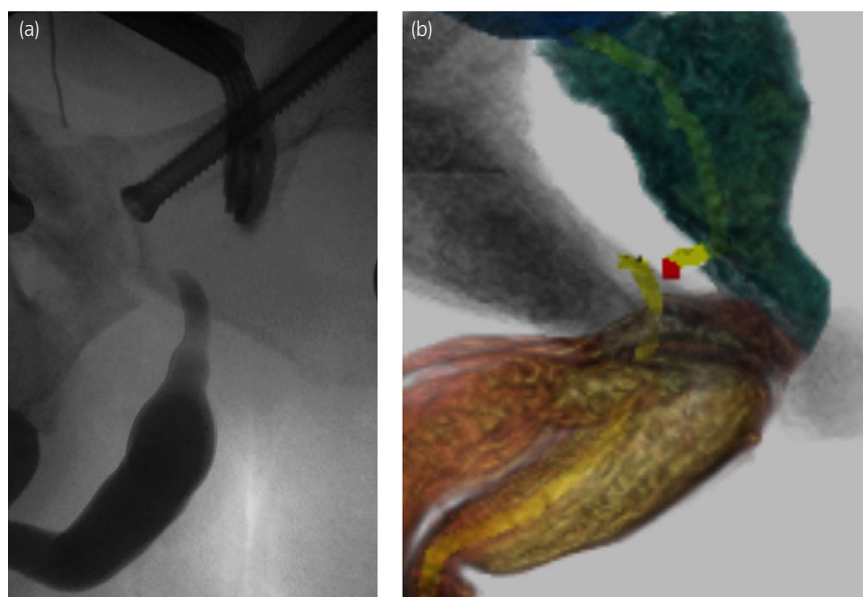


Fig. 1 (a) Combined ante- and retrograde urethrogram of Case 2. Note posterior distraction of the proximal stump. (b) VR image of the urethra, created from thin-slice MRI image from the same patient as (a). Urethra is marked in yellow, and the scar, in red. Posterior deviation of the proximal stump is shown by sagittal view, corresponding to urethrogram similar to (a).

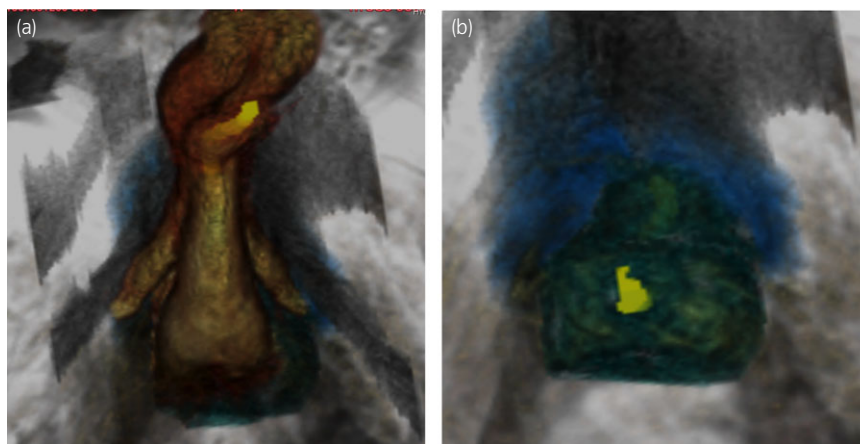


Fig. 2 Transverse view of VR image of the urethra, which simulates the surgeon's viewpoint, created from thin-slice MRI image from the same patient as Figure 1. The urethra is marked in yellow. (a) Distal view corresponding to the surgeon's view before transection of the bulbus. (b) Proximal view corresponding to the surgeon's view after transection of the bulbus and dissection of the proximal stump.

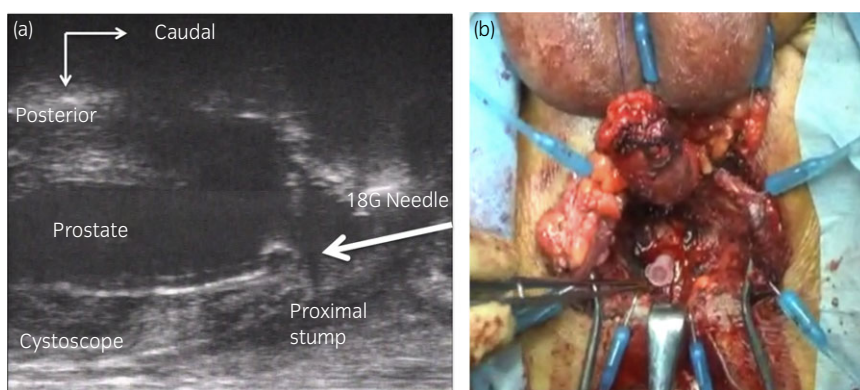


Fig. 3 Intraoperative navigation by TRUS. (a) TRUS showing flexible cystoscope placed in the prostatic urethra. An 18-G needle is passed from perineal side (right side of the panel). (b) Intraoperative photograph showing the marking by the 18-G needle. The tip of the needle is placed in the prostatic urethra, past the scar and stump. Once direction of the dissection was established, the needle is removed, and the scar is excised until the light of cystoscope becomes visible.

erectile dysfunction before the injury and did not complain. No other complication was noted.

Discussion

The present method consists of two novel components, MRI-based VR simulation and TRUS guidance. To the best of our knowledge, reconstruction of the VR image from MRI as reported here is the first report in literature. Enhancement of the urethra was usually stronger than the scar, enabling construction of 3D image. However, enhanced image alone could not completely differentiate between scar tissue and healthy urethra, and we may not be able to omit combined cystourethrogram yet. Rather, the strongest merit of VR image is that it provides more 3D information than does a cystourethrogram, because it can be processed from various view angles. In urology, VR imaging has been used to visualize renal tumors and reportedly has the advantages of greater ease of execution and a time saving of almost 50% compared with axial images.³ TRUS is a familiar tool for urologists in prostate biopsy. Ukimura reported the utility of TRUS for intraoperative navigation in laparoscopic prostatectomy and for the identification of the vesicoprostatic junction and rectum.⁴ In our method, we visualized the invisible prostatic urethra from the perineal side and marked the stump by an 18-G needle in a maneuver identical to that performed during a transperineal biopsy. It seemed to have greatly facilitated dissection for exposing the proximal stump, which otherwise

may have been attained by palpation of bougie, requiring experience-based expertise. The dissection was carried out toward the rectum without fear of injury.

Either component of our method, VR image and TRUS guidance was novel and useful by itself, and their combination could create a reliable guidance method when the proximal stump cannot be easily identified. In the future, we can also expect further improvements in these methods such as presentation of merged images, similar to that used in MRI/TRUS-guided prostate biopsy.⁵

Though we reported here feasibility of the system, it may be difficult to assess the impact of navigation until further accumulation of cases. We should also note that the usefulness and need of the navigation system might depend upon the experiences of individual surgeons, though we could predict that it may remain a viable option for inexperienced surgeons.

Conclusion

The present method enabling precise visualization of the proximal stump could be a useful tool for posterior urethral reconstruction.

Acknowledgment

This work was supported in part by KAKENHI 17K10164 of the Japan Society for the Promotion of Science.

Conflict of interest

The authors declare no conflict of interest.

References

- 1 Mundy AR, Andrich DA. Posterior urethral strictures. In: Brandes SB, Morey AF (eds). *Advanced Male Urethral and Genital Reconstructive Surgery*. Humana press, New York, 2014; 273–87.
- 2 Gomez RG, Scarberry K. Anatomy and techniques in posterior urethroplasty. *Transl. Androl. Urol.* 2018; **7**: 567–79.
- 3 Sofia C, Magno C, Silipigni S *et al.* Value of three-dimensional volume rendering images in the assessment of the centrality index for preoperative planning in patients with renal masses. *Clin. Radiol.* 2017; **72**: 33–40.
- 4 Ukimura O. Image-guided surgery in minimally invasive urology. *Curr. Opin. Urol.* 2010; **20**: 136–40.
- 5 Miyagawa T, Ishikawa S, Kimura T *et al.* Real-time Virtual Sonography for navigation during targeted prostate biopsy using magnetic resonance imaging data. *Int. J. Urol.* 2010; **17**: 855–60.