



Open Access

## ORIGINAL ARTICLE

Male Health

# The role of tumor size, ultrasonographic findings, and serum tumor markers in predicting the likelihood of malignant testicular histology

Gang Song<sup>1,2,\*</sup>, Geng-Yan Xiong<sup>1,2,\*</sup>, Yu Fan<sup>1,2</sup>, Cong Huang<sup>1,2</sup>, Yong-Ming Kang<sup>1,2,3</sup>, Guang-Jie Ji<sup>1,2</sup>, Jin-Chao Chen<sup>1,2</sup>, Zhong-Cheng Xin<sup>2,4</sup>, Li-Qun Zhou<sup>1,2</sup>

The clinical predictive factors for malignant testicular histology remain unclear because of the low prevalence. Therefore, the aim of this study was to investigate predictors of malignant histology for testicular masses and decide more testis-sparing surgeries before surgery. This retrospective study enrolled 325 consecutive testicular mass patients who underwent radical orchiectomy (310/325) or testicular preserving surgery (15/325) from January 2001 to June 2016. The clinicopathological factors, including tumor diameter, cryptorchidism history, ultrasound findings, serum alpha-fetoprotein, and human chorionic gonadotropin (HCG) levels, were collected retrospectively for statistical analysis. A predictive nomogram was also generated to evaluate the quantitative probability. Among all patients, 247 (76.0%) were diagnosed with a malignant testicular tumor and 78 (24.0%) with benign histology. Larger tumor diameter (per cm increased, hazard ratio [HR] = 1.284,  $P = 0.036$ ), lower ultrasound echo (HR = 3.191,  $P = 0.001$ ), higher ultrasound blood flow (HR = 3.320,  $P < 0.001$ ), and abnormal blood HCG (HR = 10.550,  $P < 0.001$ ) were significant predictive factors for malignant disease in all testicular mass patients. The nomogram generated was well calibrated for all predictions of malignant probability, and the accuracy of the model nomogram measured by Harrell's C statistic (C-index) was 0.92. According to our data, the proportion of patients who underwent radical orchiectomy for benign tumors (24.0%) was much larger than generally believed (10.0%). Our results indicated that the diameter, ultrasonic echo, ultrasonic blood flow, and serum HCG levels could predict the malignancy in testicular mass patients.

Asian Journal of Andrology (2019) 21, 196–200; doi: 10.4103/aja.aja\_119\_18; published online: 15 January 2019

**Keywords:** malignant likelihood; predictive model; testicular tumor; urological oncology

## INTRODUCTION

Testicular tumor is a relatively rare neoplasm among men, accounting for 1%–2% of cancers in the United States.<sup>1</sup> More than 95% of testicular tumors are germ cell tumors (GCTs),<sup>2</sup> and they are categorized as seminoma and nonseminoma germ cell tumors (NSGCTs) based on their different biological characteristics. Before the era of cisplatin-based chemotherapy, the cure rate for patients with advanced GCT was <10%, with malignant testicular tumors affecting both patient survival and fertility at that time.<sup>3</sup> With the development of chemotherapy and the integration of surgery, the cure rate of malignant testicular tumors has increased significantly in recent years.<sup>4–7</sup> However, because orchiectomy remains the gold surgical treatment of this disease, the preservation of fertility in these patients is still an urgent problem to be solved.

As the less common type of all testicular tumors, benign tumors present mass and local compression symptoms without invasive growth or metastasis. In clinical practice, there are many testicular benign tumor patients treated as malignant tumors because of inaccurate

preoperative diagnosis or fear of the probability of malignant disease. For these patients, partial orchiectomy or regular observation is a more reasonable treatment strategy, especially for young childless patients.<sup>8</sup> In recent years, with the development of diagnostic imaging and serum tumor markers, the diagnostic capability of testicular tumors has been greatly improved.<sup>9</sup> However, because of its low prevalence, there is a lack of accurate predictive models to determine benign or malignant tumors at present. In addition, biopsy is still considered as a contraindication because of the potential for tumor metastasis.

In this study, we analyzed several common clinical indicators with the relationship between benign and malignant testicular tumors, determined the predictors, and constructed an accurate clinical factor-based predictive model for testicular mass patients.

## PATIENTS AND METHODS

### Patient population

In this study, we obtained data from pathologically diagnosed testicular tumor patients ( $n = 325$ ) treated at Peking University First Hospital

<sup>1</sup>Department of Urology, Peking University First Hospital, Beijing 100034, China; <sup>2</sup>Institute of Urology, Peking University, National Urological Cancer Center, Beijing 100034, China; <sup>3</sup>Department of Urology, Suining Central Hospital, Suining 629000, China; <sup>4</sup>Department of Andrology, Peking University First Hospital, Beijing 100034, China.

\*These authors contributed equally to this work.

Correspondence: Dr. G Song (sgbmupaper@163.com) or Dr. ZC Xin (xinzc@bjmu.edu.cn)

Received: 29 March 2018; Accepted: 03 December 2018

(Beijing, China) between January 1, 2001 and June 30, 2016. The ethics committee of Peking University First Hospital approved this study, and the requirement for informed consent was waived.

### Diagnosis and treatment

Standard orchiectomy or testicular preserving surgery (in 15 testicular mass patients without any evidence of malignancy) procedures were performed on all members of the study population. To determine the appropriate treatment strategies, scrotal ultrasound, alpha-fetoprotein (AFP) and human chorionic gonadotropin (HCG) measurements were conducted before surgery, and cryptorchidism histories were recorded in detail. All blood samples were collected before surgery.

All surgical specimens were processed according to standard pathological procedures, and all slides were re-evaluated by another senior pathologist. All pathologists were blinded to this study. Ultrasound results were subjective determined by professional physicians with >5 years' experience. Limited by the technical characteristics of ultrasound, the echo could not be numerically defined. In general, the echo-like liver is defined as heterogeneous, the echo-like renal hamartoma is defined as hyperechoic, and the echo-like renal carcinoma is defined as hypoechoic. For the clinical convenience, the blood flow-like renal carcinoma is defined as high flow and the blood flow-like liver is defined as moderate. All tumors were classified according to the World Health Organization classification of testicular tumors.<sup>10</sup>

### Follow-up

Routine follow-up consisted of physical examination, ultrasound, computed tomography (CT)/magnetic resonance imaging (MRI), AFP, and HCG every 3 months in the 1<sup>st</sup> year, 6 months in the 2<sup>nd</sup> year, and once a year thereafter.

### Statistical analyses

Patients were divided into two groups according to the final pathology results. Differences between the two groups were analyzed using the Mann-Whitney U test for nonstandard, normally distributed continuous variables and grade variables, and the Chi-square test for categorical variables. Univariable log-rank tests and multivariable logistic regressions were performed to evaluate the predictive factors to determine the malignant testicular tumor. A predictive model (nomogram) was also built using statistical software R (The R Foundation for Statistical Computing, Vienna, Austria). Other statistical tests were performed using SPSS version 21.0 software (IBM Corp., Armonk, NY, USA). Value of  $P < 0.05$  was considered statistically significant.

## RESULTS

### Clinical characteristics

In all, 325 consecutive patients who had undergone orchiectomy or testicular preserving surgery at Peking University First Hospital during this period were identified in this study, and all 15 patients who underwent preserving surgery were pathologically diagnosed with benign diseases after surgery. Of these 325 patients, 93 masses (28.6%) were seminoma, 64 (19.7%) were tumors of more than one histologic type (mixed forms), 53 (16.3%) were teratoma, 26 (8.0%) were lymphoid and hematopoietic tumors, 22 (6.8%) were sex cord-gonadal stromal tumors, 15 (4.6%) were embryonal carcinoma, 12 (3.7%) were tuberculosis, and 40 (12.3%) were other types (4 adenocarcinoma, 4 metastatic solid tumor, 3 granulomatous orchitis, 3 desmoplastic small-round-cell tumor, 3 squamous cell carcinoma, 3 gonadoblastoma,

2 nonspecific orchitis, 2 adenoma, 2 inflammatory pseudotumor, 2 sperm granuloma, 1 epidermal cyst, 1 adenomatoid tumor, 1 inflammatory myofibroblastoma, 1 liposarcoma, and 8 unclassified malignant tumors). The distribution of clinical characteristics is shown in **Table 1** and **Figure 1**.

### Nomogram and calibration

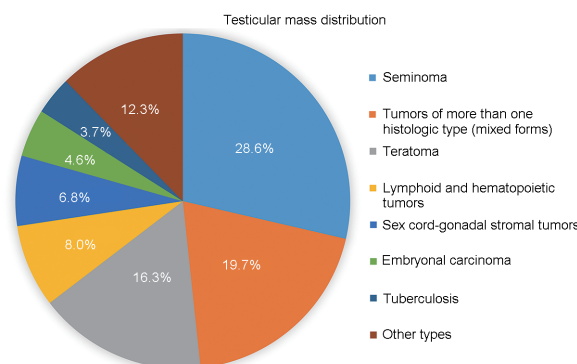
There were 78 (24.0%) benign and 247 (76.0%) malignant testicular tumor patients in our study cohort. The results for predicting malignant from benign patients are shown in **Table 2**. By multivariable analysis, larger tumor diameter (per cm increased, hazard ratio [HR] = 1.284,  $P = 0.036$ ), lower ultrasound echo (HR = 3.191,  $P = 0.001$ ), higher ultrasound blood flow (HR = 3.320,  $P < 0.001$ ), and abnormal blood HCG (HR = 10.550,  $P < 0.001$ ) were significant predictive factors for malignant disease in all testicular mass patients. To predict the probability of malignant tumors, we also used multivariable logistic regression coefficients to construct a corresponding nomogram and calibration plot for these data (**Figure 2**). The accuracy of the model nomogram measured by Harrell's C statistic (C-index) was 0.92 (95% CI: 0.88–0.96).

### Diagnostic use of nomogram

In the final points-based nomogram (**Figure 2a**), four significant predictors are located on the left side, tailing with their respective scales on the right. Each scale position has corresponding points located on the "point" scale. The sum of all points for each variable was used to calculate the "Total Points". Each "Total Points" represents the different probability to be a malignant testicular tumor. For example, in a 42-year-old male clinical diagnosed testicular mass patient, whose HCG and AFP levels were normal, the ultrasonography report was left testicular mass, 4.5 cm × 2.5 cm × 2.5 cm, high blood flow and low tumor echo. For this patient, the "Total Points" = 20 (4.5 cm) + 38 (low ultrasound echo) + 58 (high blood flow) + 0 (normal HCG) = 116. The probability of malignancy for this patient was 82%. The calibration plots (**Figure 2b**) suggested, in general, the nomogram was well calibrated for all predictions of malignant probability.

## DISCUSSION

Because radical orchiectomy remains the procedure of choice for the majority of cases with testicular tumors, this surgery results in the unnecessary loss of an otherwise normal organ for benign masses. It is well accepted that approximately 90% of solid testicular masses in adult patients are malignant.<sup>11</sup> However, in the consecutive testicular tumor population treated in our hospital; the benign tumor proportion was 24.0%. According to our data, the proportion of patients who underwent radical orchiectomy for benign tumors was much larger



**Figure 1:** The distribution of testicular masses of study cohort.

**Table 1: The distribution of clinical characteristics of the study cohort**

Variable	Total patients (n=325)	Benign testicular tumor patients (n=78)	Malignant testicular tumor patients (n=247)	P
Age (year)				0.131
Mean±s.d.	37.4±0.9	36.3±2.0	37.7±1.0	
Median (range)	34 (9–95)	30 (13–95)	34 (9–86)	
Tumor diameter (mm)				<0.001*
Mean±s.d.	4.9±0.2	3.1±0.3	5.4±0.2	
Median (range)	4.5 (0.5–230.0)	2.5 (0.5–140.0)	5.0 (0.7–230.0)	
Cryptorchidism history, n (%)				0.004*
Yes	32 (9.8)	1 (1.3)	31 (12.6)	
No	293 (90.2)	77 (98.7)	216 (87.4)	
Ultrasound echo, n (%)				<0.001*
Hyperechoic	26 (8.0)	18 (23.1)	8 (3.2)	
Heterogeneous	62 (19.1)	21 (26.9)	41 (16.6)	
Hypoechoic	236 (72.6)	39 (50.0)	197 (79.8)	
Data unavailable	1 (0.3)	0 (0)	1 (0.4)	
Ultrasound blood flow, n (%)				<0.001*
No flow	54 (16.6)	36 (46.2)	18 (7.3)	
Moderate flow	63 (19.4)	17 (21.8)	46 (18.6)	
High flow	206 (63.4)	25 (32.1)	181 (73.3)	
Data unavailable	2 (0.6)	0 (0)	2 (0.8)	
AFP, n (%)				0.084
Normal	149 (45.9)	37 (47.4)	112 (45.3)	
Abnormal	123 (37.8)	20 (25.6)	103 (41.7)	
Data unavailable	53 (16.3)	21 (26.9)	32 (13.0)	
HCG, n (%)				<0.001*
Normal	107 (32.9)	44 (56.4)	63 (25.5)	
Abnormal	152 (46.8)	8 (10.3)	144 (58.3)	
Data unavailable	66 (20.3)	26 (33.3)	40 (16.2)	

\* $P < 0.05$ . HCG: human chorionic gonadotropin; AFP: alpha-fetoprotein; s.d.: standard deviation

**Table 2: The prognostic factors for malignant testicular tumors**

Variable	Univariable analysis		Multivariable analysis	
	HR (95% CI)	P	HR (95% CI)	P
Age (per 1 year)	1.006 (0.989–1.022)	0.495	-	-
Tumor diameter (per 1 cm increased)	1.727 (1.430–2.086)	<0.001*	1.284 (1.017–1.622)	0.036*
Cryptorchidism history (yes)	11.051 (1.483–82.332)	0.019*	4.501 (0.465–43.566)	0.194
Ultrasound echo (hypoechoic)	3.118 (2.105–4.619)	<0.001*	3.191 (1.645–6.190)	0.001*
Ultrasound blood flow (moderate)	3.699 (2.613–5.238)	<0.001*	3.320 (1.895–5.816)	<0.001*
AFP (abnormal)	1.701 (0.928–3.119)	0.086	-	-
HCG (abnormal)	12.571 (5.596–28.243)	<0.001*	10.550 (3.563–31.244)	<0.001*

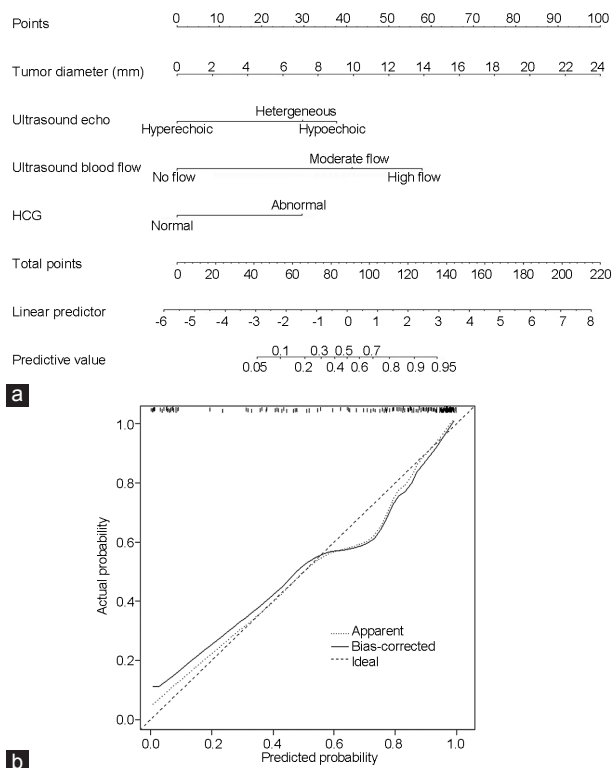
\* $P < 0.05$ . -: not included. AFP: alpha-fetoprotein; HR: hazard ratio; HCG: human chorionic gonadotropin; CI: confidence interval

than previously thought. As a result, whether patients could receive testicular sparing surgery (TSS) that would save their testicle, or have radical orchiectomy to remove the testicle and the mass, poses a clinical dilemma for urologists. Although Matei *et al.*<sup>12</sup> recently showed that the frozen section examination of testicular masses could greatly aid in making the decision, those who have any combination with advanced age, hypertension, and heart failure may not be suitable for invasive manipulation. As a result, the main aim of our study was to identify benign and malignant testicular masses and protect the fertility capability of these patients, which utilized pre-operative and noninvasive parameters.

Our study demonstrates an association between larger diameter and malignant testicular tumors. According to the general oncological rule, compared with benign tumors, malignant tumors present faster growth rate, and it is not difficult to understand the relationship between

tumor diameter and tumor malignancy. To treat small testicular masses properly, Sbrollini *et al.*<sup>13</sup> have defined a new diagnostic-therapeutic pathway in 2014. However, there is not a well-accepted tumor diameter criterion for judging because of the low prevalence of testicular tumors. In a previous study, Shilo *et al.*<sup>14</sup> reported that with a size cutoff of 18.5 mm, 38.5% of smaller lesions are benign compared with 2% above this threshold. In our study, the mean diameter of benign versus malignant lesions was 3.1 cm versus 5.4 cm ( $P < 0.001$ ), and 18.5 mm was still a significant certified criterion (46.9% [30/64] vs 18.4% [48/261],  $P < 0.001$ ). More importantly, using logistic regression, we certified that with the growth of the tumor diameter, the risk of malignancy also increased (per cm increased, HR = 1.284,  $P = 0.036$ ). This was the diameter data used for the construction of the predictive model.

As a common serum testicular tumor marker, HCG may be detected in seminoma, choriocarcinoma, tumors of more than one



**Figure 2:** (a) Nomogram to predict malignant probability for testicular mass patients and (b) calibration plot for predicting malignant probability. HCG: human chorionic gonadotropin.

histologic type and malignant teratoma patients.<sup>9</sup> In our study, it was a strong predictor for malignant disease (HR = 10.550,  $P < 0.001$ ). The proportion of abnormal HCG in the malignant cohort (70.6%) was much higher than that in the benign population (15.4%). However, we failed to confirm the predictive effect of AFP in the total study population ( $P > 0.5$ ). To investigate the unusual phenomenon of AFP, we further analyzed the distribution of AFP in detail. In our study, a total of 272 patients had detectable AFP before surgery (or the patients had already detected AFP in another center before admission, and the records were not available in the His system in our hospital). There were 20 patients with abnormal AFP in the benign group, and dermoid cyst patients (9/20, 45.0%) were predominant in this cohort. In the 112 patients with normal AFP in the malignant group, the highest proportion had pure seminoma (51/112, 45.5%). Considering the high prevalence of seminoma, we excluded the pure seminoma patients and finally confirmed the effect of AFP to predict malignant tumors (HR = 3.124,  $P < 0.001$ ). In addition, 25/196 (12.8%) benign lesions were detected in patients with at least one elevated tumor marker.

Scrotal ultrasonography is the most common examination to distinguish malignant and benign testicular tumors. Accurate tumor diameter, tumor ultrasound echo and tumor ultrasound blood flow could be easily detected by scrotal ultrasonography. We identified an increasing malignant probability with the increase of ultrasound blood flow (HR = 3.320,  $P < 0.001$ ). In general, malignant tumors tend to have a rich blood supply, and it is an important indicator to distinguish benign from malignant. For the superficial organs such as the testes, vascular conditions can be accurately evaluated by ultrasonography, which may be used to assess and ultimately improve the clinical diagnostic accuracy. Similar to renal tumors,

with an increase in tissue adiposity, benign testicular tumors usually present higher ultrasound echo than malignant masses, and this conclusion was further certified in our study (HR = 3.191,  $P = 0.001$ ). In recent years, with the development of imaging technology, MRI and contrast-enhanced ultrasound (CEUS) also play an important role in the diagnosis of testicular tumors. MRI, because of its superior soft-tissue contrast and multiplanar capabilities, is increasingly being used as a supplemental diagnostic problem-solving tool in cases where scrotal ultrasonography findings are inconclusive or nondiagnostic.<sup>15</sup> Moreover, CEUS increases the accuracy of ultrasound on tumor blood supply determination.<sup>16,17</sup> However, the scrotal ultrasonography with a combination of gray-scale and color Doppler techniques has still been the first-line imaging modality for evaluation of testicular tumors because of its low cost, wide availability, and high diagnostic accuracy.<sup>18,19</sup> In summary, as a noninvasive examination, scrotal ultrasonography may greatly increase the diagnostic accuracy of testicular tumors and should be considered as the primary preoperative examination for all the patients.

This study has certain limits and constraints. First, this study represents a retrospective review of findings at a single center. Second, because some proportion of patients had undergone some examination in other hospitals before admission, there was a minor dearth of HCG, AFP and ultrasonography data in our record system, which reduces the strength of this study. Third, the lack of contrast enhanced ultrasounds, and testicular microlithiasis data could reduce the accuracy of the study. Fourth, there is a lack of the external validation of the nomogram. Fifth, due to the unbalanced tumor composition caused by retrospective study, AFP has not been adopted in model construction. However, as described in the discussion section, it is still an important malignant marker for testicular tumors and should be given sufficient clinical attention.

## CONCLUSION

Our results suggest that diameter, ultrasonic echo, ultrasonic blood flow, and serum HCG levels can predict the malignancy of testicular masses in patients. We have constructed a predictive model for a testicular lesion, which may be used by clinicians to predict the probability of benign lesions. A surgical approach with testis-sparing could be offered in selected cases.

## AUTHOR CONTRIBUTIONS

GS, GYX, and ZCX contributed to the conception and design of the study. GS, GYX, YF, CH, YMK, GJJ, JCC, and LQZ collected the data. GS, GYX, and CH drafted and revised the manuscript. GS, GYX, YF, and CH participated in preparing figures and performing statistical analysis. All authors read and approved the final manuscript.

## COMPETING INTERESTS

All authors declare no competing interests.

## ACKNOWLEDGMENTS

The authors would like to thank the entire staff of the Department of Urology, Peking University First Hospital. Moreover, we would like to acknowledge Dr. Da Ren for collecting partial data, Dr. Qun He for analyzing pathological results, and Dr. Shuqing Li for conducting ultrasound procedure.

## REFERENCES

- 1 Siegel RL, Miller KD, Jemal A. Cancer statistics, 2017. *CA Cancer J Clin* 2017; 67: 7–30.
- 2 Wein A, Kavoussi L, Partin A, Peters C. *Campbell-Walsh Urology*. 11<sup>th</sup> ed. Philadelphia: Elsevier; 2015. p4168.
- 3 Einhorn LH. Testicular cancer as a model for a curable neoplasm: the Richard and

- Hinda Rosenthal Foundation Award Lecture. *Cancer Res* 1981; 41: 3275–80.
- 4 Einhorn LH. Treatment of testicular cancer: a new and improved model. *J Clin Oncol* 1990; 8: 1777–81.
  - 5 Einhorn LH, Williams SD, Chamness A, Brames MJ, Perkins SM, *et al*. High-dose chemotherapy and stem-cell rescue for metastatic germ-cell tumors. *N Engl J Med* 2007; 357: 340–8.
  - 6 de Wit R, Roberts JT, Wilkinson PM, de Mulder PH, Mead GM, *et al*. Equivalence of three or four cycles of bleomycin, etoposide, and cisplatin chemotherapy and of a 3- or 5-day schedule in good-prognosis germ cell cancer: a randomized study of the European Organization for Research and Treatment of Cancer Genitourinary Tract Cancer Cooperative Group and the Medical Research Council. *J Clin Oncol* 2001; 19: 1629–40.
  - 7 de Wit R, Stoter G, Kaye SB, Sleijfer DT, Jones WG, *et al*. Importance of bleomycin in combination chemotherapy for good-prognosis testicular nonseminoma: a randomized study of the European Organization for Research and Treatment of Cancer Genitourinary Tract Cancer Cooperative Group. *J Clin Oncol* 1997; 15: 1837–43.
  - 8 Haas GP, Shumaker BP, Cerny JC. The high incidence of benign testicular tumors. *J Urol* 1986; 136: 1219–20.
  - 9 Gilligan TD, Seidenfeld J, Basch EM, Einhorn LH, Fancher T, *et al*. American Society of Clinical Oncology Clinical Practice Guideline on uses of serum tumor markers in adult males with germ cell tumors. *J Clin Oncol* 2010; 28: 3388–404.
  - 10 Vogelzang N, Scardino P, Shipley W, Debruyne F, Linehan W. Comprehensive Textbook of Genitourinary Oncology. Philadelphia: Lippincott Williams & Wilkins; 1999. p544.
  - 11 Powell TM, Tarter TH. Management of nonpalpable incidental testicular masses. *J Urol* 2006; 176: 96–8.
  - 12 Matei DV, Vartolomei MD, Renne G, Tringali VML, Russo A, *et al*. Reliability of frozen section examination in a large cohort of testicular masses: what did we learn? *Clin Genitourin Cancer* 2017; 15: e689–96.
  - 13 Sbrrollini G, Mazzaferro D, Ettamimi A, Montironi R, Cordari M, *et al*. Diagnostic-therapeutic pathway for small lesions of the testis. *Arch Ital Urol Androl* 2014; 86: 397–9.
  - 14 Shilo Y, Zisman A, Lindner A, Raz O, Strauss S, *et al*. The predominance of benign histology in small testicular masses. *Urol Oncol* 2012; 30: 719–22.
  - 15 Acar T, Efe D. Is contrast-enhanced MRI efficient in testicular infarction mimicking testicular tumor on scrotal ultrasound? *Turk J Emerg Med* 2015; 15: 192–3.
  - 16 Peil-Grun A, Trenker C, Gorg K, Neesse A, Haasenritter J, *et al*. Diagnostic accuracy and interobserver agreement of contrast-enhanced ultrasound in the evaluation of residual lesions after treatment for malignant lymphoma and testicular cancer: a retrospective pilot study in 52 patients. *Leuk Lymphoma* 2018; Doi: 10.1080/10428194.2018.1439170. [Epub ahead of print].
  - 17 Manganaro L, Saldari M, Pozza C, Vinci V, Gianfrilli D, *et al*. Dynamic contrast-enhanced and diffusion-weighted MR imaging in the characterisation of small, non-palpable solid testicular tumours. *Eur Radiol* 2018; 28: 554–64.
  - 18 Kachramanoglou C, Rafailidis V, Philippidou M, Bertolotto M, Huang DY, *et al*. Multiparametric sonography of hematologic malignancies of the testis: grayscale, color Doppler, and contrast-enhanced ultrasound and strain elastographic appearances with histologic correlation. *J Ultrasound Med* 2017; 36: 409–20.
  - 19 Mittal PK, Abdalla AS, Chatterjee A, Baumgarten DA, Harri PA, *et al*. Spectrum of extratesticular and testicular pathologic conditions at scrotal MR imaging. *Radiographics* 2018; 38: 806–30.

This is an open access journal, and articles are distributed under the terms of the Creative Commons Attribution-NonCommercial-ShareAlike 4.0 License, which allows others to remix, tweak, and build upon the work non-commercially, as long as appropriate credit is given and the new creations are licensed under the identical terms.

©The Author(s)(2019)