

Case Report

Severe Ondansetron-associated Hypokalemia in a Patient Diagnosed with Aspiration Pneumonia

Atousa Hakamifard^{1,2}, Amir Aria³, Mahnaz Momenzadeh⁴

¹Department of Infectious Diseases, School of Medicine, Isfahan University of Medical Sciences, Isfahan, Iran

²Infectious Diseases and Tropical Medicine Research Center, Shahid Beheshti University of Medical Sciences, Tehran, Iran

³Department of Internal Medicine, Faculty of Medicine, Isfahan University of Medical Sciences, Isfahan, Iran

⁴Department of Clinical Pharmacy and Pharmacy Practice, Isfahan University of Medical Sciences, Isfahan, Iran

Received: 03-01-2022.

Accepted: 11-04-2022.

Published: 14-12-2022.

ABSTRACT

This case report aims to introduce a patient with severe hypokalemia as one of the rare complications of ondansetron injection. The stroke patient was 56 years old and hospitalized in the emergency department with and purulent sputum. The symptoms and lung computed tomography scan confirmed the diagnosis of aspiration pneumonia. A nasogastric tube was inserted, and food gavage was performed for the patient. The treatment was started with meropenem to manage aspiration pneumonia. The patient could not tolerate the gavage. Consequently, ondansetron was prescribed, but severe hypokalemia of 2.5 mEq/l was developed. The causes of hypokalemia were evaluated. The hematological, biochemical, and liver function tests were done, and the potassium level was measured daily. Afterward, causes of hypokalemia was ruled out and with discontinuation of ondansetron the hypokalemia was resolved. Hypokalemia may be caused by ondansetron. It is required that potassium monitoring be always considered during administrating of this medicine.

KEYWORDS: *Aspiration pneumonia, hypokalemia, Ondansetron, stroke*

INTRODUCTION

Ondansetron belongs to a pharmaceutical class described as serotonin 5-HT₃ receptor antagonists that is prescribed to prevent nausea and vomiting related to cancer chemotherapy, radiotherapy, and surgery. This medicine blocks the activity of serotonin as a natural substance that causes nausea and vomiting.^[1] 5HT₃ antagonists are extensively applied in vomiting induced by chemotherapy and radiotherapy.^[2] Hypokalemia is recognized as one of the rare complications related to ondansetron.^[3] Hypokalemia is caused by several reasons, including redistribution of potassium in the intracellular space, gastrointestinal injuries, or excessive renal dysfunction. It is possible to maintain intracellular potassium transport for acute alkalosis, insulin and glucose use (both treat hyperkalemia), or reactions to catecholamine.^[4,5] In addition, hypokalemia may be caused by an increasing gastrointestinal loss

in cases of diarrhea, vomiting, or colon tumors. We frequently observe hypokalemia caused by highly renal loss of potassium in treatment with diuretics.^[6] The patient regularly has no symptoms until the potassium level is <0.3 mEq/l. Clinical signs of hypokalemia include muscle weakness.^[3] The classic findings include prominent U-wave electrocardiogram (ECG), ST depression, QT prolongation, and T-wave flattening.^[7] We report a rare side effect, hypokalemia following intravenous (IV) ondansetron, which may be challenging to manage without any warning. This case report was approved by the ethics committee of Isfahan University of Medical Sciences (ethics code: IR.MUI.MED.REC.1399.436).

Address for correspondence: Dr. Mahnaz Momenzadeh,
E-mail: Mahnazmomenzadehf@gmail.com

This is an open access journal, and articles are distributed under the terms of the Creative Commons Attribution-NonCommercial-ShareAlike 4.0 License, which allows others to remix, tweak, and build upon the work non-commercially, as long as appropriate credit is given and the new creations are licensed under the identical terms.

For reprints contact: WKHLRPMedknow_reprints@wolterskluwer.com

How to cite this article: Hakamifard A, Aria A, Momenzadeh M. Severe ondansetron-associated hypokalemia in a patient diagnosed with aspiration pneumonia. *J Res Pharm Pract* 2022;11:87-90.

Access this article online	
Quick Response Code: 	Website: www.jrpp.net
	DOI: 10.4103/jrpp.jrpp_13_22

CASE REPORT

A 56-year-old male with a cerebrovascular accident and acute shortness of breath was hospitalized at the Emergency Department of Kashani Hospital, an educational and medical center of Isfahan University of Medical Sciences. The patient had a fever of 38°C and a respiratory rate of 23 breath per min. The patient's blood pressure was 110/90 mmHg.

He was neither a known diabetic nor hypertensive and did not have drug sensitivity. The patient experienced pulmonary symptoms 5 days before hospitalization. Physicians diagnosed aspiration pneumonia considering the signs and symptoms and history using a lung computed tomography (CT) scan. A nasogastric tube was inserted, and food gavage was performed for him. He was treated with meropenem at a dose of 1 g every 8 h. The patient's para clinical findings are shown in Table 1.

The patient could not tolerate gavage on the 4th day of hospitalization and 8 mg of IV ondansetron was given to him every 12 h. The physicians managed to eliminate the problem of gavage intolerance on the 5th day of hospitalization, but hypokalemia of 2.5 mEq/l was developed. IV and oral potassium chloride was also applied in addition to essential interventions for hypokalemia. The patient's potassium level reached 2.6 mEq/l despite receiving potassium. It is necessary to state that ondansetron was discontinued after 2 days (the 7th day) due to gavage tolerance. After that, potassium was increased to a normal level [Figure 1]. PH was 7.35, and HCO₃ was equal to 23 in the patient's venous blood gases. It was not possible to control urinary potassium 24 h a day. The other factors causing hypokalemia were excluded and liver, thyroid, electrocardiography, and echocardiography were normal. Side effects of meropenem, N-acetyl cysteine, pantoprazole, and heparin (as the prophylactic dose) were assessed, and it was diagnosed that the patient's hypokalemia was not related to them. The patient was followed up for

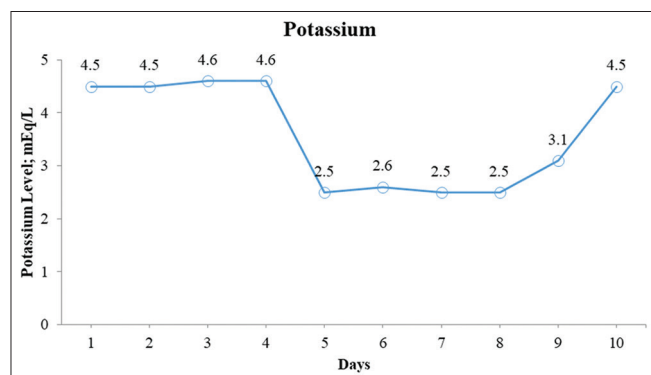


Figure 1: Report of the patient's potassium level during hospitalization

2 months and did not report a return of hypokalemia. The amount of magnesium was also estimated, which was normal during hypokalemia and at that time.

DISCUSSION

In general, ondansetron is widely used to control nausea and vomiting due to many causes. 5HT₃-containing antagonists are also used to treat chemotherapy-induced nausea and vomiting.^[8] In a percentage of the patients, side effects such as anaphylaxis, extrapyramidal effects, and ectopic changes were seen. Besides, liver enzyme disruption may occur in 5% of cases. Hypokalemia with this drug has rarely been reported,^[2,9] probably in terms of the effect of ondansetron on kidney tubules.^[10,11] Ondansetron acts in nephrons at two levels: (1) At the Henle level, it decreases the cotransporter Na⁺-K⁺-2Cl⁻(NKCC2) and (2) increases the delivery of sodium to distant nephron. It causes K⁺ secretion through the potassium channel ROMK and enables the reuptake of sodium electroneutral in the distant nephron's epithelial sodium channels (ENaC), resulting in hypokalemia.

Moreover, in the nephron, especially the distant hinge, Na⁺-K⁺ ATPase is adjusted by ondansetron. It causes

Table 1: Laboratory investigations

Laboratory tests	Result
Hematological	
White blood cell	14,600 cell/mm ³
Hemoglobin	9.2 g/l
Platelets	230,000 cell/mm ³
Erythrocyte sedimentation rate	28 mm/h
C-reactive protein	45
Biochemical	
Blood sugar	140 g/l
BUN	20 mg/dL
Serum creatinine	0.8 mg/dL
Blood sodium level	136 meq/L
Blood potassium level	4.6 meq/L
Magnesium blood	2.1 mg/dL
pH	7.35
HCO ₃	23 mEq/L
Liver function tests	
Total bilirubin	0.96 g/l
Direct	0.36 g/l
Indirect	0.60 g/l
SGOT	25 IU/l
SGPT	22 IU/l
Alkaline phosphatase	135 IU/l
Total protein	7.6 g/l
Albumin	4.0 g/l

BUN=Blood urea nitrogen, pH=Potential hydrogen, HCO₃=Bicarbonate, SGOT=Serum glutamic oxaloacetic transaminase, SGPT=Serum glutamic pyruvic transaminase

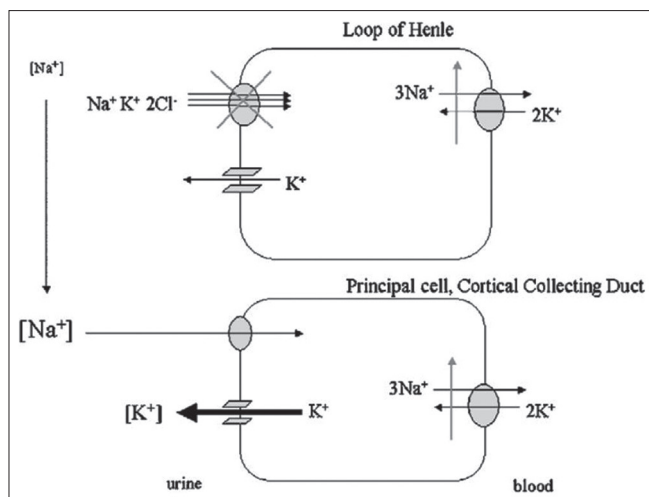


Figure 2: Impact of ondansetron on $\text{Na}^+ -\text{K}^+ -2\text{Cl}^-$ (NKCC2)^[13]

worsening of renal K dissipation in discarded cells expressing ENaC [Figure 2]^[12] by decreasing intracellular sodium levels that increase sodium tubular entry into this section. Matthews *et al.*^[2] reported a 45-year-old man hospitalized for 2 h with a sudden onset of weakness in both limbs. Six hours earlier, he was referred to a local hospital for a 2-day fever associated with nausea and had received two doses of IV ondansetron. The patient had severe symptomatic hypokalemia about 6 h after eight milligrams of ondansetron. This patient had no symptomatic hypokalemia characteristics before. In our patient, the hypokalemia introduced after about 1 day of using ondansetron.

The patient had been normokalemic after K + correction and possibly after complete discontinuation of the drug. The patient remained stable at discharge and for up to 2 months of follow-up.^[2] In the current case, we had no access to the genetic history of the patient, but no history was reported about him or his family during the evaluation.

Ten patients admitted for IV hydration and chemotherapy were assessed by Friedrich *et al.*^[12] for ondansetron-related hypokalemia in nearby oncology patients. Blood and urine samples were gathered before and after ondansetron administration, and dietary records and IV reports were analyzed to compute sodium and potassium balance. There was an expected drop in urinary osmolyte and an increase in urinary sodium, but no statistically considerable changes were found in sodium or potassium balance before and after ondansetron. They concluded that ondansetron does not result in considerable loss of potassium in hydrated and nourished patients but recommended careful monitoring of serum potassium in patients with nutritional deficiencies or chronic volume deficiencies who receive the drug.^[12]

In this case report, the patient had gavage intolerance only once; thus, his nutrition and vomiting were not the cause of his severe hypokalemia. When ondansetron was applied for 2 days, potassium levels reduced, and IV and oral potassium continued with ondansetron (during these 2 days) but potassium did not increase. Potassium began to increase with discontinuation of the drug; the patient had none of the symptomatic hypokalemia characteristics. The difference between our case and the others is that the patient was a stroke patient hospitalized in the emergency department with shortness of breath, and ondansetron was used to control the symptoms of gavage intolerance. The strength of our report is the daily measurement of the patient's potassium level during hospitalization can show the effect of the treatment and is suggested to do for the same cases.

CONCLUSION

Our report shows that doctors must be aware of electrolyte disorders, including hypokalemia caused by ondansetron. Potassium monitoring may always be considered during ondansetron administration.

Declaration of patient consent

The authors certify that they have obtained all appropriate patient consent forms. In the form, the patient(s) has/have given his/her/their consent for his/her/their images and other clinical information to be reported in the journal. The patients understand that their names and initials will not be published and due efforts will be made to conceal their identity, but anonymity cannot be guaranteed.

AUTHORS' CONTRIBUTION

A. Hakamifard and M. Momenzadeh acquired data, analyzed and interpreted the data. M. Momenzadeh and A. Aria wrote the first draft of the manuscript. All authors have read and approved the final manuscript.

Financial support and sponsorship

Nil.

Conflicts of interest

There are no conflicts of interest.

REFERENCES

1. Cerit Z. Arrhythmic side of ondansetron alongside antiemetic effect. *Pediatr Emerg Care* 2017;33:e9.
2. Mathew SK, Kutty KK, Ramya I, Padmakumar C, Pius P. Ondansetron-induced life threatening hypokalemia. *J Assoc Physicians India* 2016;64:81-2.
3. Turner SR, Pinski M. Ondansetron-associated hypokalemia in a 2-year-old with pre-B-cell ALL. *J Pediatr Hematol Oncol* 2008;30:58-60.
4. Gennari FJ. Hypokalemia. *N Engl J Med* 1998;339:451-8.
5. Aliaga CA, Arizon LF, Bermúdez RM, Castán JA, Santandreu AV.

- Severe hypokalemia secondary to abuse of β -adrenergic agonists in a pediatric patient: Case report. *J Bras Nefrol* 2019;42:250-3.
- Chhabria M, Portales-Castillo I, Chowdhury M, Sohail A, Sanchez-Tejera D, Bress J, *et al.* A case of severe hypokalemia. *Am J Kidney Dis* 2020;76:A9-12.
 - Huang CL, Kuo E. Mechanism of hypokalemia in magnesium deficiency. *J Am Soc Nephrol* 2007;18:2649-52.
 - Patel P, Paw Cho Sing E, Dupuis LL. Safety of clinical practice guideline-recommended antiemetic agents for the prevention of acute chemotherapy-induced nausea and vomiting in pediatric patients: A systematic review and meta-analysis. *Expert Opin Drug Saf* 2019;18:97-110.
 - Goodin S, Cunningham R. 5-HT(3)-receptor antagonists for the treatment of nausea and vomiting: A reappraisal of their side-effect profile. *Oncologist* 2002;7:424-36.
 - Welston K, Dianne May D. Chapter-32 Gastrointestinal drugs. In: Ray SD, editor. *Side effects of drugs: annual: a worldwide yearly survey of new data in adverse drug reactions*, vol. 39. p. 373-87 [R].
 - Danielsson B, Webster WS, Ritchie HE. Ondansetron and teratogenicity in rats: Evidence for a mechanism mediated via embryonic hERG blockade. *Reprod Toxicol* 2018;81:237-45.
 - Fiedrich E, Sabhaney V, Lui J, Pinsk M. Assessment of ondansetron-associated hypokalemia in pediatric oncology patients. *ISRN Oncol* 2012;2012:798239.
 - Knepper MA, Kim GH, Fernández-Llama P, Ecelbarger CA. Regulation of thick ascending limb transport by vasopressin. *J Am Soc Nephrol* 1999;10:628-34. doi: 10.1681/ASN.V103628.