

## CASE REPORT

# The First Case Series Report of *Typhonium trilobatum* Tuber Poisoning in Humans

Devendiran Anandhi<sup>1</sup>, KNJ Prakash Raju<sup>2</sup>, Vivekanandan Muthu Pillai<sup>3</sup>, Vadivelu Kumaresan<sup>4</sup>

### ABSTRACT

*Typhonium* is a genus belonging to the *Araceae* family, native to southern Asia and Australia. In folk medicine, *Typhonium* is used for its analgesic, anti-inflammatory, antidiarrheal, and wound-healing properties. We report a toxidrome of airway compromise due to *Typhonium trilobatum* tuber ingestion. We present an interesting case series of four patients who consumed raw tuber of *T. trilobatum* with suicidal thoughts. They exhibited a constellation of symptoms such as swelling of lips and tongue, drooling of saliva, and severe throat pain. One patient had significant upper airway edema and severe respiratory distress requiring emergency endotracheal intubation. Laboratory investigations were grossly normal in all four individuals, except for mild asymptomatic hypokalemia in one and eosinophilia in another patient. We successfully managed all our patients with repeated adrenaline nebulization, antihistamines, and steroids. *Typhonium* is believed to be a beneficial herb. Toxicity of *Typhonium* is not reported much in the literature till date. An emergency department (ED) physician should be aware of this tuber toxicity as it presents with airway compromise, which resolves over hours. The symptoms are due to the local effects of calcium oxalate crystals in the tuber. Airway management is the priority and repeated adrenaline nebulization together with supportive care is advised.

**Keywords:** Angioedema, Karunai-k-kilanku, *Typhonium trilobatum*, Wild tuber.

*Indian Journal of Critical Care Medicine* (2020): 10.5005/jp-journals-10071-23479

### INTRODUCTION

Intentional self-harm poses a large burden in all emergency departments (EDs), with drug intoxication being common in developed countries, whereas pesticides and toxic plant ingestion in developing countries.<sup>1</sup> *Typhonium trilobatum* (Bengal Arum) is a small herb seen in Assam, Bangladesh, China, India, Nepal, Sri Lanka, Thailand, and Vietnam.<sup>2</sup> Some people use this herb as a native medicine for its anti-inflammatory, analgesic, and antidiarrheal properties.<sup>3</sup> To the best of our knowledge, poisoning due to ingestion of *T. trilobatum* is not reported in the literature till date. We present the first case series of *T. trilobatum* tuber poisoning manifesting with a toxidrome of painful pricking sensation of oral cavity, swelling of lips and tongue, increased salivation, drooling of saliva, upper airway angioedema, and airway compromise.

### CASE DESCRIPTIONS

We describe four patients who consumed raw toxic tuber (Senai kizhangu in Tamil) with suicidal intention.

#### Case 1

A 39-year-old man was brought to our ED, 3 hours after ingesting a raw tuber plant with suicidal intent. He had swollen lips and tongue, drooling of saliva, and also minimal breathing discomfort (Fig. 1A). He developed these symptoms within 30 minutes of ingestion. His vital signs were heart rate 120/minute, blood pressure 130/80 mm Hg, SpO<sub>2</sub> 98% at room air, and respiratory rate 28/minute. In view of angioedema secondary to unknown tuber poisoning, he was placed in a propped-up position with oxygen by simple face mask, and also was given chlorpheniramine maleate 10 mg and hydrocortisone 100 mg intravenously. Meanwhile, endotracheal intubation was planned with rescue option being surgical airway (cricothyroidotomy), if needed. With adrenaline 5 mL (1:1,000) nebulization, he remained stable and hence intubation was deferred. With repeated adrenaline nebulization over the

<sup>1-3</sup>Department of Emergency Medicine, Jawaharlal Institute of Postgraduate Medical Education and Research, Puducherry, India

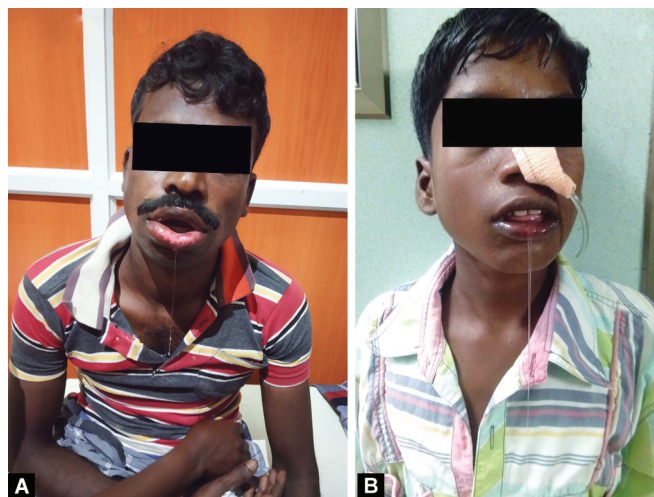<sup>4</sup>Department of Botany, Kanchi Mamunivar Centre for Postgraduate Studies, Puducherry, India

**Corresponding Author:** KNJ Prakash Raju, Department of Emergency Medicine, Jawaharlal Institute of Postgraduate Medical Education and Research, Puducherry, India, Phone: +91 9000190662, e-mail: jyothi prakash41@gmail.com

**How to cite this article:** Anandhi D, Prakash Raju KNJ, Vivekanandan MP, Kumaresan V. The First Case Series Report of *Typhonium trilobatum* Tuber Poisoning in Humans. *Indian J Crit Care Med* 2020;24(7): 581–584.

**Source of support:** Nil

**Conflict of interest:** None



**Figs 1A and B:** Angioedema in patients who consumed *Typhonium trilobatum* tuber: (A) Case 1; (B) Case 4

next 2 hours, angioedema reduced significantly and further he did not develop any new symptoms. He received maintenance doses of chlorpheniramine maleate and hydrocortisone during hospitalization. His routine laboratory investigations were normal except for asymptomatic mild hypokalemia (2.9 mEq/L) and was discharged after 4 days.

### Case 2

A 26-year-old man presented to our ED after 6 hours of consuming a wild tuber for purpose of self-harm. Initial assessment revealed a threatened airway and besides the patient was in severe respiratory distress. He was immediately shifted to the resuscitation zone and prepped for emergency endotracheal intubation. His vital signs were pulse rate 122/minute, blood pressure 122/80 mm Hg, and SpO<sub>2</sub> 60% at room air. His sensorium was poor (GCS E2 V2 M5) and history was negative for intoxication. Both of his lips were swollen, tongue was edematous and protruding outside the oral cavity, with continuous drooling of saliva. He began developing these symptoms within 15 minutes of ingestion. In view of anticipated difficult airway, only sedative agent was provided without any paralyzer. After injecting fentanyl 100 µg and propofol 50 mg intravenously, the airway was secured using 8.0 size endotracheal tube. He was administered chlorpheniramine maleate 10 mg iv, hydrocortisone 100 mg iv, and adrenaline 0.5 mg intramuscularly followed by repetitive doses of adrenaline nebulization. Chest examination was normal. His sensorium improved by 6 hours and was extubated in a period of 12 hours. He was continued on maintenance doses of chlorpheniramine maleate and hydrocortisone. His laboratory investigations showed neutrophilic leukocytosis (WBC: 14930 cells/cumm). He got discharged on day 5 and follow-up visits were unremarkable.

### Case 3

A 17-year-old male was brought to us 5 hours after intentional ingestion of a raw tuber. On arrival his airway was maintainable, and even he had similar symptoms such as swollen lips and tongue along with drooling of saliva. He complained of pin-pricking sensation over the tongue and buccal cavity as well as difficulty in swallowing owing to severe pain. All these symptoms started within 15 minutes of ingestion. He was vitally stable and routine laboratory investigations were normal. He responded well to chlorpheniramine maleate 10 mg, intravenous

hydrocortisone 100 mg, and repeated adrenaline nebulization. He was discharged after 3 days of observation and psychiatric counseling.

### Case 4

A 14-year-old adolescent pursued self-harm by ingesting the same toxic tuber. He presented with complaints of inability to open mouth, difficulty to articulate, severe pain in the throat and chest, dribbling of saliva from the mouth (Fig. 1B), chest tightness, and breathlessness. He developed all these symptoms within 15 minutes of chewing the raw tuber. He was managed with chlorpheniramine maleate 10 mg, hydrocortisone 100 mg iv, and frequent adrenaline nebulization. His symptoms rapidly improved. Laboratory reports showed elevated alkaline phosphatase (428 IU/L) probably owing to his growing bones and eosinophilia (10%). He was discharged after 2 days of monitoring.

Retrospectively, we explored our medical records to find that eight patients had presented over a period of 2 years with history of similar wild tuber poisoning. All such individuals were adolescents and young adults hailing from same locality (Tamil Nadu) in the southern part of India. The common manifestations were upper airway compromise with angioedema, severe pain in throat, and drooling of saliva.

Due to curiosity, I (corresponding author) visited the patients' localities to enquire about the unknown tuber. I was taken to the agricultural fields where the tuber was growing as weed alongside banana plantations (Fig. 2). The farmers said that it was difficult to restrict its growth because of the underground corm. Then I collected specimens of few herbs with tuber (Fig. 3) and met various toxicologists and phytologists. One of the phytologists performed cross-section of the tuber and identified it as *T. trilobatum* belonging to the *Araceae* family. Later, we dried the tuber and sent it for phytochemical analysis. Phytochemical screening showed presence of cardiac glycosides, coumarins, saponins, and terpenoids. HPLC-UV detector for calcium oxalate content revealed  $12.6 \pm 0.51$  mg/100 g of tuber.

## DISCUSSION

The genus *Typhonium* belongs to the *Araceae* family, which is native to southern Asia and Australia. *Typhonium trilobatum* (Bengal Arum, Lobed Leaf Typhonium) is an aroid growing in wooden areas across

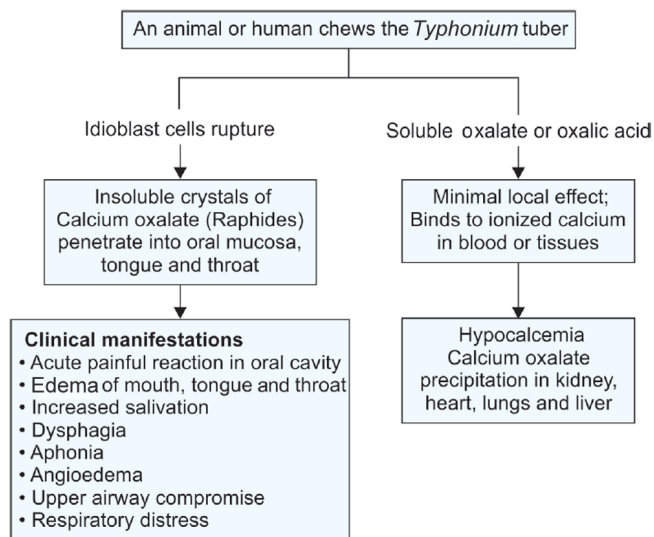


Fig. 2: *Typhonium trilobatum* plant with tubers



Fig. 3: Corresponding author collected the wild tuber plants which caused the toxicity in humans

Flowchart 1: Pathophysiology of *T. trilobatum* toxicity



India. Its local names vary; in Tamil—senai kizhangu, pitikarunai, karukarunaikilanku, and karunai-k-kilanku.

### *Typhonium trilobatum* in Literature

The *Araceae* (Arum) family comprises of monocotyledonous flowering plants (aroids), which are born as inflorescence termed spadix. This family includes as many as 114 genera and 3,750 species. In folk medicine, *T. trilobatum* has been popular because of its analgesic, anti-inflammatory, antidiarrheal,<sup>3</sup> wound-healing,<sup>4</sup> and anti-ulcerogenic properties.<sup>5</sup> Also it has been believed to prevent against malignancies of breast, liver,<sup>6</sup> and leukemia owing to its antioxidant effects.<sup>7</sup>

### Toxicity of *Araceae* Family Tubers (Flowchart 1)

Poisonous plants of *Araceae* family have not been studied extensively. The toxicity of *Dieffenbachia* species belonging to the Arum family is well explained in the literature. The key chemical constituents include saponins, cyanogenic glucosides, phenolic compounds including flavonoids, and calcium oxalate raphides being responsible for skin irritation as well as painful sensation on mucous membranes (eyes, mouth, throat).<sup>8</sup> The *Araceae* tubers have spindle-shaped specialized cells (idioblasts) that constitute needle-shaped insoluble crystals of calcium oxalate (raphides),<sup>9</sup> coated by a proteolytic enzyme.<sup>10</sup> When a tuber is chewed, the idioblasts break injecting the insoluble sharp crystals together with protease into the surrounding structures such as the buccal mucosa. Within minutes of ingestion, burning sensation of the oral cavity begins,<sup>11</sup> which has been attributed to calcium oxalate crystal-induced mechanical damage as well as proteolytic enzyme by stimulating bradykinin-histamine release.<sup>12</sup> This acute pain in the mouth frequently limits the individual's ability to ingest further. Some may develop intense burning pain and edema of throat, dysphagia, ulceration, increased salivation, and aphonia. In case oropharyngeal edema progresses, respiratory distress and upper airway compromise will ensue.

Although soluble oxalate may possibly have a little local action, it has been shown to bind more effectively to ionized calcium in blood. There is a postulated risk of hypocalcemia in case of large ingestions. And also, a considerable proportion of calcium oxalate crystals may precipitate in vital organs such as heart, lungs, liver, and

kidneys.<sup>13</sup> None of our patients developed systemic manifestations or hypocalcemia.

### Management of Toxicity

Gastrointestinal decontamination using activated charcoal or other methods is usually not of any significant benefit. Airway and breathing should be monitored; and in case of upper airway compromise, securing the airway is crucial. Endoscopy may be necessary in patients with oral ulcerations or dysphagia.

Antihistamines have not been of proven benefit for mucosal edema. All our patients received repeated adrenaline nebulization and they responded dramatically within hours. Emesis may require fluid resuscitation and antiemetics. Ensuring adequate hydration also hastens the renal excretion of calcium oxalate.<sup>14</sup>

In case of systemic symptoms, monitoring of blood counts, serum electrolytes including calcium, and renal function is recommended. Asymptomatic hypocalcemia does not warrant treatment but in the presence of symptoms, intravenous calcium gluconate is advisable. Deteriorating renal function may demand hemodialysis in addition to supportive care.<sup>14</sup>

Our case series clearly shows that *T. trilobatum* tuber is toxic in humans. Although this tuber toxicity is not yet reported in the literature, its harmful consequences are popular and well known to the local community. Our patients would have chosen this tuber for self-harm as it is available at ease nearby their residence.

### CONCLUSION

An ED physician should be aware of this *Typhonium* tuber toxicity as it presents with airway compromise, which resolves over hours. The symptoms are due to the local effects of calcium oxalate crystals in the tuber. Airway management is the priority and repeated adrenaline nebulization together with supportive care is advised.

### REFERENCES

- Eddleston M. Patterns and problems of deliberate self-poisoning in the developing world. *Q J Med* 2000;93(11):715–731. DOI: 10.1093/qjmed/93.11.715.

- Ghani A. Medicinal plants of Bangladesh: chemical constituents and uses. 2nd ed., Dhaka, Bangladesh: J Asiat Soc Bangladesh; 2003. pp. 31. 39-40, 418, 500-5, 580-9.
- Ali K, Ashraf A, Biswas NN. Analgesic, anti-inflammatory and anti-diarrheal activities of ethanolic leaf extract of *Typhonium trilobatum* L. Schott. Asian Pac J Trop Biomed 2012;2(9):722-729. DOI: 10.1016/S2221-1691(12)60217-2.
- Roy SK, Mishra PK, Nandy S, Datta R, Chakraborty B. Potential wound healing activity of the different extract of *Typhonium trilobatum* in albino rats. Asian Pac J Trop Biomed 2012(3):S1477-S1486. DOI: 10.1016/S2221-1691(12)60441-9.
- Mohan S, Abdul AB, Wahab SA, Al-Zubairi AS. Antibacterial and antioxidant activities of *Typhonium flagelliforme* (Lodd) Blume tuber. Am J Biochem Biotechnol 2008;4(4):402-407. DOI: 10.3844/ajbbsp.2008.402.407.
- Alfarabi M, Rosmalawati S, Bintang M, Miftahudin, Rofa'ani E, Chaidir. Antiproliferation activity of tuber protein from *Typhonium flagelliforme* (Lodd) blumei on MCF-7 cell line. Int J Biosci 2015;6(12):52-60. DOI: 10.12692/ijb/6.12.52-60.
- Farida YP, Wahyudi S, Wahono S, Hanafi M. Flavonoid glycoside from the ethyl acetate extract of keladitikus *Typhonium flagelliforme* (Lodd) Blume leaves. Asian J Nat Appl Sci 2012;4: 16-21.
- Hegnauer R, Araceae. Review of cyanogenesis and cyanogenic compounds. 1986; pp 581-591.
- Franceschi VR, Nakata PA. Calcium oxalate in plants: Formation and function. Annu Rev Plant Biol 2005;56(1):41-71. DOI: 10.1146/annurev.arplant.56.032604.144106.
- Slaughter RJ, Beasley DM, Lambie BS, Wilkins GT, Schep LJ. Poisonous plants in New Zealand: a review of those that are most commonly enquired about to the national poisons centre. N Z Med J 2012;125(1367):87-118.
- Mrvos R, Dean BS, Krenzelok EP. Philodendron/Dieffenbachia ingestions – are they a problem. J Toxicol Clin Toxicol 1991;29(4):485-491. DOI: 10.3109/15563659109025745.
- Gardner DG. Injury to the oral mucous-membranes caused by the common houseplant, dieffenbachia – a review. Oral Surg Oral Med Oral Pathol 1994;78(5):631-633. DOI: 10.1016/0030-4220(94)90177-5.
- Chen CL, Fang HC, Chou KJ, Wang JS, Chung HM. Acute oxalate nephropathy after ingestion of star fruit. Am J Kidney Dis 2001;37(2):418-422. DOI: 10.1053/ajkd.2001.21333.
- Šnajdauf J, Mixa V, Rygl M, Vyhnanek M, Morávek J, Kabelka Z. Aortoesophageal fistula – an unusual complication of esophagitis caused by dieffenbachia ingestion. J Pediatr Surg 2005;40(6):e29-e31. DOI: 10.1016/j.jpedsurg.2005.03.036.