



Endovenous Intervention of May-Thurner Syndrome with Thrombus beyond Iliac Vein Stenosis

Heungman Jun

Department of Surgery, Ilsan Paik Hospital, Inje University College of Medicine, Goyang, Korea

Purpose: With the increase in the incidence of venous thrombosis, interest in May-Thurner syndrome (MTS) accompanying iliac vein compression has increased. Some patients with MTS have inferior vena cava thrombosis or thrombosis beyond iliac vein stenosis (TBIVS). This study aimed to identify the characteristics of MTS with TBIVS including pulmonary embolism (PE) and post-thrombotic syndrome (PTS) compared to those of MTS without TBIVS.

Materials and Methods: Thirty-five patients with deep vein thrombosis associated with MTS were treated between March 2012 and February 2016. Demographic data, medical history, computed tomography findings (iliac vein size of stenosis and stenotic ratio compared with the other side), and clinical outcomes (preoperative PE and PTS) were retrospectively collected and reviewed by dividing into groups with or without TBIVS.

Results: Eight of the 35 patients with MTS had TBIVS. The group with TBIVS had a statistically significantly greater iliac vein size ($P<0.001$) and ratio ($P=0.001$). PE was more prevalent in the group with TBIVS (63% vs. 15%, $P=0.007$). However, no statistically significant intergroup difference in PTS prevalence was found.

Conclusion: The presence of mild iliac vein stenosis in MTS can be used to predict TBIVS and the requirement for more attention to PE.

Key Words: May-Thurner syndrome, Venous thrombosis, Pulmonary embolism

Received December 26, 2018

Revised March 22, 2019

Accepted April 15, 2019

Corresponding author: Heungman Jun

Department of Surgery, Ilsan Paik Hospital, Inje University College of Medicine, 170 Juhwa-ro, Ilsanseo-gu, Goyang 10380, Korea

Tel: 82-31-910-4947

Fax: 82-31-910-7784

E-mail: junh@paik.ac.kr

<https://orcid.org/0000-0003-2530-4388>

Copyright © 2019, The Korean Society for Vascular Surgery

This is an Open Access article distributed under the terms of the Creative Commons Attribution Non-Commercial License (<http://creativecommons.org/licenses/by-nc/4.0>) which permits unrestricted non-commercial use, distribution, and reproduction in any medium, provided the original work is properly cited.

Vasc Specialist Int 2019;35(2):90-94 • <https://doi.org/10.5758/vsi.2019.35.2.90>

INTRODUCTION

With the increase in the incidence of lower-extremity deep vein thrombosis (DVT), interest in May-Thurner syndrome (MTS) accompanying iliac vein compression has also increased. MTS comprises a small proportion of lower-extremity venous disorders [1], however many left-sided iliofemoral DVT cases exhibit iliac vein spurs resulting from extrinsic compression [2]. In particular, some patients with MTS have inferior vena cava (IVC) thrombosis or thrombosis beyond iliac vein stenosis (TBIVS). IVC thrombosis is rarely seen and reported in patients with lower-extremity DVT [3]. In a report on lower-extremity DVT with IVC thrombus

extension, the primary venous patency of IVC thrombosis is reportedly similar to that in lower-extremity DVT alone, while the incidence of post-thrombotic syndrome (PTS) is rather low [4].

In cases of MTS in which the iliac vein is compressed, the thrombus is generally located within the boundary of the stenotic lesion (Fig. 1A) [5]. However, in some cases, TBIVS can be observed (Fig. 1B). This study aimed to identify the different characteristics of MTS with TBIVS and its complications including pulmonary embolism (PE) and PTS compared to those of MTS without TBIVS and reveal the anatomical features that induce MTS with TBIVS.

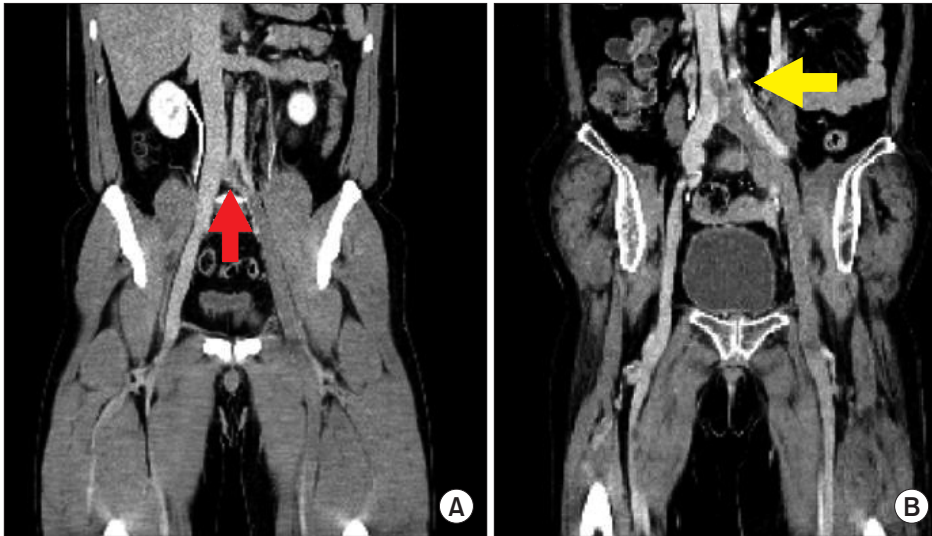


Fig. 1. Coronal view on a computed tomography scan of a patient with May-Thurner syndrome. (A) Stenotic lesion in the left common iliac vein (arrow) without thrombosis beyond iliac vein stenosis (TBIVS). (B) Stenotic lesion in the left common iliac vein with TBIVS (arrow).

MATERIALS AND METHODS

This retrospective review of the medical records was approved by the Ilsan Baik Hospital Institutional Review Board (IRB no. 2018-03-018) with the exemption of written informed consent. Thirty-five patients with DVT and MTS were treated with different interventional modalities, including catheter-directed thrombolysis (CDT), percutaneous mechanical thrombectomy (PMT), and iliac vein stent placement, between March 2012 and February 2016.

Twenty-two females and 13 males fulfilled the inclusion criteria. Patients were included if they: i) presented within 3 weeks from the onset of symptoms; ii) demonstrated a >50% reduction in iliac vein diameter on computed tomographic (CT) venography; and iii) were a possible candidate for aggressive treatment, including CDT, PMT, and stent. Patients were excluded if they: i) were advanced cancer patients whose life expectancy was <1 year; ii) did not fulfill the criteria for or agree to undergo aggressive therapy; and iii) showed bilateral involvement of the iliac vein. TBIVS was defined as thrombosis originating from the distal portion of the iliac vein stenosis extended to the IVC. Patients with isolated IVC thrombosis not related to MTS were excluded.

The demographic data (age, sex, and symptom duration), medical history (diabetes, hypertension, smoking habit, use of antithrombotic agents, and bedridden state), CT findings (iliac vein size of stenosis and stenotic ratio compared with the other side), and clinical outcomes PE and PTS were retrospectively collected and reviewed by dividing the patients into groups by TBIVS status. PE was initially evaluated in all cases of DVT with MTS by contrast-enhanced chest enhanced CT at admission and PTS was defined by a Villalta's score ≥ 5 or the presence of a venous ulcer after 10 months from onset [6].

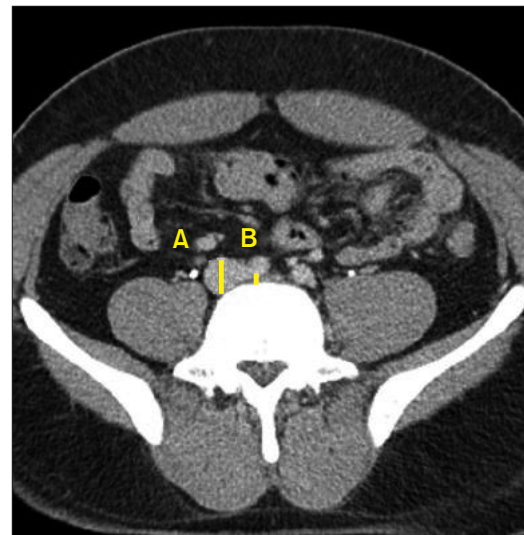


Fig. 2. Axial view on computed tomography scan of a patient with May-Thurner syndrome. Diameter ratio was defined as the diameter of the stenotic iliac vein (B) divided by the diameter of the contralateral iliac vein (A).

MTS was diagnosed using spiral CT venography. Diameter was the maximum anteroposterior length in the axial plane. Diameter ratio was defined as the diameter of the stenotic iliac vein divided by the diameter of the contralateral iliac vein. An examiner (H.J.) assessed for compression of the common iliac vein by scanning in the axial plane (Fig. 2).

Prophylactic IVC filter placement using the jugular approach was performed on all possible patients, excluding those with chronic components, and the filter was removed within 1 month after placement. This center's policy is to perform IVC filter insertion whenever possible in all patients undergoing iliac vein procedures because of the possibility of PE. No IVC filter was used in patients who were evalu-

ated as having chronic thrombosis and did not need PMT. PMT was performed in all the patients except one with severe chronic thrombi. One patient did not undergo PMT after the confirmation of chronic lesions and many collaterals on venography and CT. Self-expanding stents were mainly used and performance was decided based on the stenosis status. Stents were usually placed when the iliac vein was shown to have >50% stenosis compared with just the distal vein on venography. Overnight antegrade thrombolysis with urokinase through the popliteal sheath was performed for 12 hours if a residual thrombus was observed. Low-molecular-weight heparin (enoxaparin) at 1 mg/kg twice daily for 3-5 days was administered subcutaneously for DVT starting at admission. Thereafter, an oral factor Xa inhibitor (rivaroxaban) was administered for 6 months at an initial dosage of 15 mg twice daily during the first 3 weeks and was later increased to 20 mg once daily.

Because the continuous variables were not normally distributed, the Mann-Whitney U-test was used to compare the means. The χ^2 test was used to examine categorical variables. A P-values of <0.05 were considered significant. Multivariate binary logistic regression analysis was used to predict TBIVS.

RESULTS

Among the 35 patients with MTS, 22 were female and 13 were male. Eight patients had TBIVS. All patients presented with leg swelling. The symptom duration was 2-20 days (median, 7 days). Between patients with and those without TBIVS, no statistically significant differences in characteristics, including age, hypertension, body mass index, bedridden state, and cancer history, were found (Table 1).

Table 1. Characteristics of patients with May-Thurner syndrome by TBIVS status

Characteristic	With TBIVS (n=8)	Without TBIVS (n=27)	P-value
Age (y)	71 (58-81)	73 (61-84)	0.690
Male	4 (50.0)	9 (33.3)	0.392
Hypertension	3 (37.5)	11 (40.7)	0.869
Diabetes	3 (37.5)	4 (14.8)	0.159
Body mass index	23.44 (23-26)	23.50 (22-30)	0.845
Smoking	2 (25.0)	8 (29.6)	0.799
Use of anti-thrombotics	3 (37.5)	13 (48.1)	0.595
Bedridden state	1 (12.5)	9 (33.3)	0.252
Cancer patient	0 (0.0)	2 (7.4)	0.428
Symptom duration (d)	7 (5-20)	7 (2-20)	0.778

Values are presented as median (interquartile range) or number (%). TBIVS, thrombosis beyond iliac vein stenosis.

The median diameter of the left common iliac vein, where the stenosis originated, was 4.15 mm (range, 2.0-9.5 mm), whereas the median diameter of the right common iliac vein at the same level was 14.0 mm (range, 9.0-20.0 mm) on the axial plane of CT venography. The mean stenotic ratio of the compressed left common iliac vein to the right common iliac vein was 0.29 (range, 0.21-0.48). The group with TBIVS showed statistically significant greater iliac vein size of stenosis (6.31 mm vs. 3.42 mm, $P<0.001$) and ratios (0.44 ± 0.11 vs. 0.26 ± 0.12 , $P=0.001$). PE on CT at admission was significantly more prevalent in the group with than in the group without TBIVS (62.5% vs. 14.8%, respectively, $P=0.007$; Table 2). Symptomatic PE, including pulmonary necrosis, was not observed in the patients with PE. In the interventional procedure, no statistically significant intergroup differences were found in the frequency of overnight thrombolysis, PMT, iliac stenting, and IVC filter placement. All patients with TBIVS underwent iliac venous stent placement, whereas 5 without TBIVS did not undergo placement after real venography. A patient without TBIVS had chronic thrombosis on venography and underwent only overnight thrombolysis without PMT and stenting. Immediately after the procedure, the symptoms improved in all cases, and there were no signs of technical failure.

No statistically significant intergroup differences in PTS prevalence were found (25.0% vs. 22.2%, $P=0.615$; Table 2). No cases of recurrent thrombosis within the stent or mortality occurred within the follow-up periods. An MTS patient without TBIVS had an embolic stroke after 2 weeks from onset. In a binary logistic regression analysis of variable predictors of TBIVS, stenosis size was significantly correlated with TBIVS in MTS ($P=0.005$).

Table 2. Clinical characteristics and results of patients with May-Thurner syndrome by TBIVS status

Characteristic	With TBIVS (n=8)	Without TBIVS (n=27)	P-value
Iliac vein size (mm) ^a	6.31±1.90	3.42±1.28	<0.001
Stenotic ratio	0.44±0.11	0.26±0.12	0.001
Overnight thrombolysis	2 (25.0)	5 (18.5)	0.504
PMT	8 (100.0)	26 (96.3)	0.581
Iliac stent	8 (100.0)	22 (81.5)	0.189
IVC filter	8 (100.0)	22 (81.5)	0.189
PE	5 (62.5)	4 (14.8)	0.007
PTS	2 (25.0)	6 (22.2)	0.615
Follow-up (mo)	11.76±15.10	11.13±9.99	0.773

Values are presented as mean±standard deviation or number (%). TBIVS, thrombosis beyond iliac vein stenosis; PMT, percutaneous mechanical thrombectomy; IVC, inferior vena cava; PE, pulmonary embolism; PTS, post-thrombotic syndrome.

^aIliac vein size was measured in stenosis.

DISCUSSION

The main symptoms of patients with MTS accompanying iliac vein compression are acute pain and swelling of the lower left extremity [7]. However, they also present symptoms, such as venous claudication, chronic venous insufficiency, lipodermatosclerosis, recurrent superficial venous thrombophlebitis, and PE [1]. For acute DVT, early recanalization is highly important and plays an important role in preventing PTS. In current MTS treatment plans, endovascular therapy, including CDT, PMT, and stent placement, is commonly applied with satisfactory results [8,9].

Despite the fact that patients with MTS commonly present with DVT, PE is rarely found in these patients. Few studies have examined the correlation between stenosis extent and PE in patients with MTS. However, Chan et al. [5] claimed that left common iliac vein narrowing protects against symptomatic PE by trapping large emboli, analogous to an IVC filter. In particular, this study reported that significant iliac vein stenosis >70% or <4 mm in luminal diameter have a significantly lower odds of developing symptomatic PE [5]. In MTS, the stenotic lesion prevents the passage of the thrombus into the IVC and thereby lowers the frequency of PE [10]. Only small embolic fragments pass through the stenotic lesion, and these do not lead to symptomatic PE [5]. In this study, severe stenosis of the left iliac vein caused by MTS was associated with a better protective effect against the development of TBIVS. Also, TBIVS was associated with the development of PE at the time of presentation. This study aimed to explain that, depending on the state of the iliac vein stenosis, the state of cephalad migration of the distal thrombus can change beyond preventing a stenotic lesion, thus influencing the development of PE.

Apart from data on MTS with TBIVS, few data are available on IVC thrombosis. IVC thrombosis is rarely seen in patients with lower-extremity DVT [3]. Risk factors of IVC

thrombosis are an unretrieved IVC filter, bilateral DVT, ilio-femoral DVT, IVC congenital anomaly, severe PTS, and renal cell carcinoma, among others [11]. The mortality rate of IVC thrombosis is reportedly twice higher than that of lower-extremity DVT [4]. Without proper treatment, PTS, PE, and disabling venous claudication, occurring at prevalence rates of 90%, 30%, and 45%, respectively, reportedly develop in patients with IVC thrombosis [12,13]. MTS with TBIVS and IVC thrombosis may differ pathophysiologically but can be observed as part of IVC thrombosis. This study showed that many patients with MTS and TBIVS presented with PE but are not expected to show high morbidity and mortality rates like those seen in IVC thrombosis.

Here we compared MTS with and MTS without TBIVS. To identify the predictors of TBIVS, binary logistic regression was performed. The greater the stenosis size, the higher the incidence of TBIVS. This study has limitations, including its small sample size and insufficient predictive values in a single center. This study only included patients who underwent an endovascular procedure; thus, it could not represent the entire cohort of patients with MTS. However, unlike general DVT, in MTS due to a structural abnormality, the fact that the iliac vein size of the stenosis has a greater effect on thrombus extension than patient status is important in diagnosis and prognosis. In this study, five patients without TBIVS did not undergo iliac venous stent placement because the stenosis was not severe on venography. We understand TBIVS as the process of thrombus progression and believe that various factors, such as vessel angulation and medical conditions in addition to vessel size are involved in this process.

CONCLUSION

TBIVS may be a different concept from MTS without TBIVS and is a risk factor of PE. Patients with mild iliac vein stenosis in MTS may be more susceptible to TBIVS and require closer monitoring for the occurrence of PE. Patients with MTS require thorough inspections for stenotic size and TBIVS.

CONFLICTS OF INTEREST

The author has nothing to disclose.

ORCID

Heungman Jun

<https://orcid.org/0000-0003-2530-4388>

Table 3. Binary logistic regression analysis of the predictors of TBIVS in in May-Thurner syndrome

Predictors	OR	SE	95% CI	P-value
Iliac vein size (mm) ^a	3.276	0.426	1.421-7.554	0.005
Stenotic ratio (%) ^b	0.961	0.082	0.818-1.129	0.631
Symptom duration (d)	1.028	0.073	0.891-1.186	0.702
Age (y)	0.953	0.085	0.806-1.126	0.570
Body mass index	0.867	0.251	0.531-1.418	0.570

TBIVS, thrombosis beyond iliac vein stenosis; OR, odds ratio; SE, standard error; CI, confidence interval.

^aIliac vein size was measured in stenosis.

^bStenotic ratio percentage is expressed by multiplying stenotic ratio by 100.

REFERENCES

- 1) Mousa AY, AbuRahma AF. May-Thurner syndrome: update and review. *Ann Vasc Surg* 2013;27:984-995.
- 2) Knipp BS, Ferguson E, Williams DM, Dasika NJ, Cwikiel W, Henke PK, et al. Factors associated with outcome after interventional treatment of symptomatic iliac vein compression syndrome. *J Vasc Surg* 2007;46:743-749.
- 3) Kahn SR, Shbaklo H, Lamping DL, Holcroft CA, Shrier I, Miron MJ, et al. Determinants of health-related quality of life during the 2 years following deep vein thrombosis. *J Thromb Haemost* 2008;6:1105-1112.
- 4) Avgerinos ED, El-Shazly O, Jeyabalan G, Al-Khoury G, Hager E, Singh MJ, et al. Impact of inferior vena cava thrombus extension on thrombolysis for acute iliofemoral thrombosis. *J Vasc Surg Venous Lymphat Disord* 2016;4:385-391.
- 5) Chan KT, Popat RA, Sze DY, Kuo WT, Kothary N, Louie JD, et al. Common iliac vein stenosis and risk of symptomatic pulmonary embolism: an inverse correlation. *J Vasc Interv Radiol* 2011;22:133-141.
- 6) Kahn SR, Partsch H, Vedantham S, Prandoni P, Kearon C. Definition of post-thrombotic syndrome of the leg for use in clinical investigations: a recommendation for standardization. *J Thromb Haemost* 2009;7:879-883.
- 7) Moudgill N, Hager E, Gonsalves C, Larson R, Lombardi J, DiMuzio P. May-Thurner syndrome: case report and review of the literature involving modern endovascular therapy. *Vascular* 2009;17:330-335.
- 8) Liu Z, Gao N, Shen L, Yang J, Zhu Y, Li Z, et al. Endovascular treatment for symptomatic iliac vein compression syndrome: a prospective consecutive series of 48 patients. *Ann Vasc Surg* 2014;28:695-704.
- 9) Nazir SA, Ganeshan A, Nazir S, Uberoi R. Endovascular treatment options in the management of lower limb deep venous thrombosis. *Cardiovasc Intervent Radiol* 2009;32:861-876.
- 10) Zhu QH, Zhou CY, Chen Y, Wang J, Mo HY, Luo MH, et al. Percutaneous manual aspiration thrombectomy followed by stenting for iliac vein compression syndrome with secondary acute isolated iliofemoral deep vein thrombosis: a prospective study of single-session endovascular protocol. *Eur J Vasc Endovasc Surg* 2014;47:68-74.
- 11) Alkhouli M, Morad M, Narins CR, Raza F, Bashir R. Inferior vena cava thrombosis. *JACC Cardiovasc Interv* 2016;9:629-643.
- 12) McAree BJ, O'Donnell ME, Fitzmaurice GJ, Reid JA, Spence RA, Lee B. Inferior vena cava thrombosis: a review of current practice. *Vasc Med* 2013;18:32-43.
- 13) Kahn SR. The post-thrombotic syndrome: the forgotten morbidity of deep venous thrombosis. *J Thromb Thrombolysis* 2006;21:41-48.