

Rituximab therapy combined with methotrexate for severe necrotizing scleritis in a case of granulomatosis with polyangiitis

Somasheila I Murthy, Sahil Shah, Bhupesh Bagga, Rajkiran Dudam¹

Access this article online	
Quick Response Code:	Website: www.ijo.in
	DOI: 10.4103/ijo.IJO_2249_19

Department of Cornea, The Cornea Institute, L.V. Prasad Eye Institute, Kallam Anji Reddy Campus, L.V. Prasad Marg, Banjara Hills, Hyderabad, ¹Department of Rheumatology, Hyderabad Rheumatology Center, Prakash Nagar, Begumpet, Hyderabad, India

The work was carried out at the L V Prasad Eye Institute, Kallam Anji Reddy Campus, Hyderabad, India.

Correspondence to: Dr. Somasheila I Murthy, Head, Cornea Service, L.V Prasad Eye Institute, Kallam Anji Reddy Campus, LV Prasad Marg, Banjara Hills, Hyderabad - 500 034, Telangana. E-mail: smurthy@lvpei.org.

Received: 06-Dec-2019

Revision: 09-Feb-2020

Accepted: 05-Apr-2020

Published: 20-Aug-2020

A 19-year-old girl presented with severe pain and redness in her right eye and also with nasal congestion and epistaxis since the past 5 months. The patient was systemically investigated and tested positive for proteinase 3 anti-neutrophil cytoplasmic antibody (PR-3 ANCA) with raised erythrocyte sedimentation rate (ESR). The provisional diagnosis of granulomatosis with polyangiitis (GPA) was made, and she was started on systemic steroids and azathioprine after consultation with the rheumatologist. However on steroid taper, she developed severe reactivation of the scleritis and the corneal involvement was noted in the form of peripheral ulcerative keratitis. Instead of starting another course of high dose oral cortico-steroids or pulse cyclophosphamide, she was started on rituximab infusion (two doses), and oral methotrexate was added, leading to the successful remission of the disease.

This is an open access journal, and articles are distributed under the terms of the Creative Commons Attribution-NonCommercial-ShareAlike 4.0 License, which allows others to remix, tweak, and build upon the work non-commercially, as long as appropriate credit is given and the new creations are licensed under the identical terms.

For reprints contact: WKHLRPMedknow_reprints@wolterskluwer.com

Cite this article as: Murthy SI, Shah S, Bagga B, Dudam R. Rituximab therapy combined with methotrexate for severe necrotizing scleritis in a case of granulomatosis with polyangiitis. Indian J Ophthalmol 2020;68:1981-3.

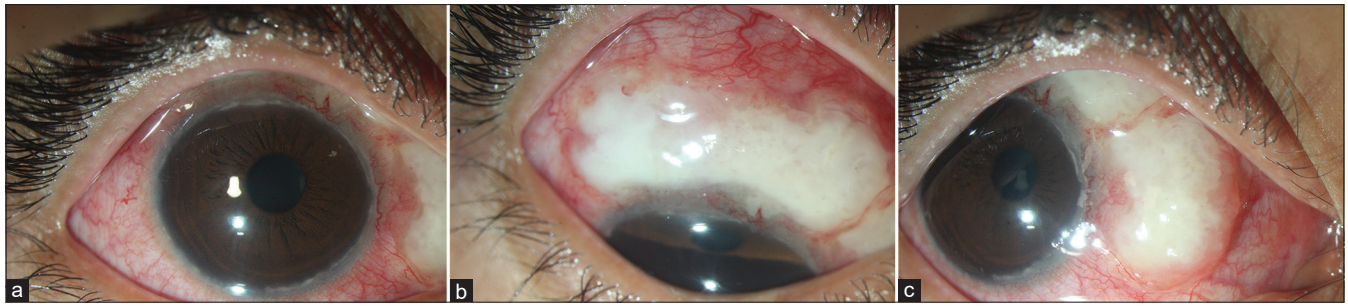


Figure 1: (a) Diffuse slit lamp photograph of the right eye showing diffuse necrotizing anterior scleritis. (b) Inferior gaze showing a large area of whitening in the superior quadrant. (c) Right gaze showing an extension of the superior area of whitening in the nasal quadrant as well

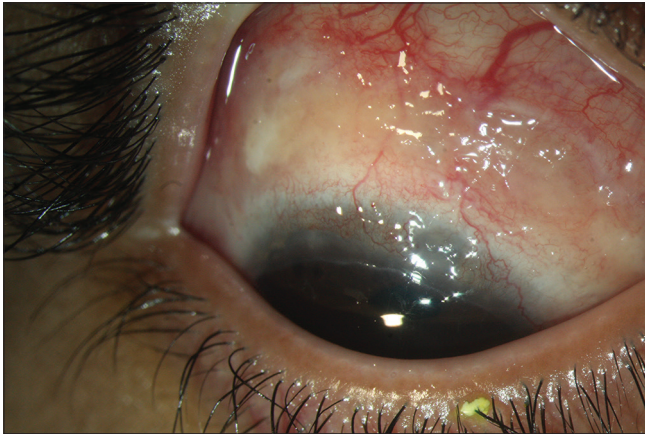


Figure 2: Inferior gaze showing the development of peripheral ulcerative keratitis in the superior cornea, one month after starting oral steroids. There is a partial resolution of the scleritis

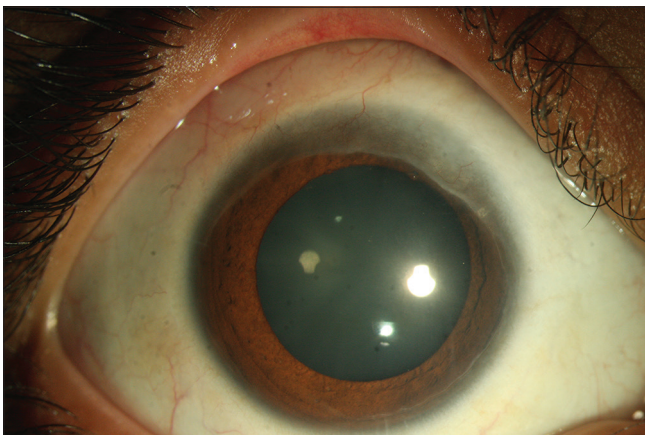


Figure 3: Complete resolution with quiescence of scleritis and healed peripheral ulcerative keratitis

Key words: Granulomatosis with polyangiitis, necrotising scleritis, peripheral ulcerative keratitis, refractory scleritis, rituximab

Granulomatosis with polyangiitis (GPA) is a multisystem disorder characterized by necrotizing granulomatous inflammation and pauci-immune small-vessel vasculitis. Ocular involvement occurs in 50%–60% of patients with GPA, and can affect the entire eye, from the orbit to the eyelid and optic nerve. It can occur as follows) de novo affecting

the eye only, 2) or as spread of the disease from contiguous structures such as the sinuses 3) or as a part of systemic GPA.^[1] Ophthalmic presentations include scleritis, peripheral ulcerative keratitis (PUK) and orbital mass formation and other rare presentations such as adnexal inflammation and nasolacrimal duct changes.^[2] Herein, we present a case of a young patient with proteinase 3 anti-neutrophil cytoplasmic antibody (PR-3 ANCA) positive scleritis who developed worsening on tapering oral prednisolone and azathioprine, but was successfully treated with rituximab and methotrexate.

Case Report

A 19-year-old girl presented to the emergency department with the chief complaints of severe pain in her right eye since the past 5 months, with worsening since 45 days. She also complained of epistaxis along with nasal congestion since 5 months. She was diagnosed elsewhere with a scleral abscess of possible infectious etiology and underwent scleral biopsy at that centre; with histopathological examination reported as chronic necrotizing abscess (further details were not available with the patient). The CT-scan of mastoids was done 2 years prior, which was reported as chronic sclerosing mastoiditis and chronic suppurative otitis media. Examination showed visual acuity of 20/25 in her right eye. Slit lamp examination showed diffuse and deep episcleral congestion and a large area of scleral whitening from 11 to 4 o'clock position adjacent to the limbus [Fig. 1a-c]. Peripheral cornea showed cellular infiltration. The left eye was normal. She was diagnosed with necrotizing scleritis with a provisional diagnosis of GPA. Serological reports showed positivity to proteinase 3 –ANCA along with an elevated ESR of 38 mm/hr (normal 0–20 mm/hr) and elevated C-reactive protein of 11.1 mg/dL (normal 0.08–3.1 mg/dL) and other investigations were normal (rheumatoid factor, HLA B27, angiotensin converting enzyme, antinuclear antibodies, complete blood picture, urine analysis, Mantoux test, and chest X-ray). The diagnosis of GPA was considered and the patient was started on topical steroids (6 weeks course of topical prednisolone acetate 1%, starting at 6 times a day, tapered every week) and referred immediately to the rheumatologist for further systemic evaluation and to initiate systemic immunosuppression. Treatment was commenced with oral prednisolone 1mg/kg per day tapered every two weeks and oral azathioprine 50 mg twice a day. The patient's symptoms improved initially but a month later on tapering oral prednisolone the scleritis worsened and a mild proptosis was also noted. Despite stepping up oral corticosteroids, the patient started developing peripheral ulcerative keratitis [Fig. 2]. Considering the worsening on

tapering the doses of oral prednisolone and despite being on azathioprine; the patient and family were explained about the therapeutic options and were counseled for rituximab therapy. After ensuring fitness for receiving biologic infusion, she was given 2 infusions of rituximab (1000 mg per dose 2 doses, 2 weeks apart) (biosimilar Reditux, Reddy's laboratories, Hyderabad India) and oral immunomodulator therapy was switched to oral methotrexate, which was started at 10 mg once a week. The patient improved significantly 1 month post rituximab therapy with complete resolution of the scleritis and PUK over subsequent follow up [Fig. 3]. Methotrexate was continued as maintenance therapy. She did not have any further relapses and could be taken off oral corticosteroids. She continues to be in remission with a maintenance dose of 7.5 mg methotrexate every week for 18 months later.

Discussion

The ocular associations of scleritis and PUK in ANCA-associated vasculitis are well known, with scleritis being reported in 75% cases and PUK in 16.1%.^[3] Rituximab is a chimeric monoclonal antibody against the CD20 antigen expressed only on the surface of immature and mature B cells.^[4] Vasculitic manifestations are related to ANCA originating from B cells; whereas, the granulomatous manifestations are related to CD4 positive T cells. This is one of the reasons why rituximab is highly effective in severe scleritis of GPA as scleritis is a vasculitic phenomenon.^[5] Rituximab is preferred over cyclophosphamide for young patients as the latter has the risk of gonadal toxicity. In a study reported by Stone *et al.*^[6] it was shown that rituximab was non inferior to cyclophosphamide in the induction regime of ANCA associated vasculitis. In a larger single centre study of 63 patients, Pérez-Jacoiste Asín *et al.*^[7] were able to show success with rituximab over cyclophosphamide especially in refractory cases. However this drug should be used only after complying with the check list^[8] and with caution and should not be considered as first-line therapy in all cases as ocular side effects such as progressive outer retinal necrosis^[9] and systemic side effects such as progressive multifocal leukoencephalopathy^[10] have been reported, albeit these cases received both cyclophosphamide and a multiple infusions of rituximab.

Conclusion

Rituximab appears to be a promising agent in the management of severe or refractory scleritis especially in the presence of systemic disease, and can produce prompt and sustained response. In much selected cases such as young patients with severe disease and after complete work-up for its safe

institution, it could be considered as an earlier therapeutic modality instead of the conventional step-wise therapy.

Declaration of patient consent

The authors certify that they have obtained all appropriate patient consent forms. In the form the patient(s) has/have given his/her/their consent for his/her/their images and other clinical information to be reported in the journal. The patients understand that their names and initials will not be published and due efforts will be made to conceal their identity, but anonymity cannot be guaranteed.

Financial support and sponsorship

Source of funding for Somasheila I Murthy, Sahil Shah and Bhupesh Bagga: Hyderabad Eye Research Foundation.

Conflicts of interest

There are no conflicts of interest.

References

1. Woywodt A, Haubitz M, Haller H, Matteson EL. Wegener's granulomatosis. *Lancet* 2006;367:1362-6.
2. Pakrou N, Selva D, Leibovitch I. Wegener's granulomatosis: Ophthalmic manifestations and management. *Semin Arthritis Rheum* 2006;35:284-92.
3. Watkins AS, Kempen JH, Choi D, Liesegang TL, Pujari SS, Newcomb C, *et al.* Ocular disease in patients with ANCA-positive vasculitis. *J Ocul Biol Dis Infor* 2010;3:12-9.
4. Miserocchi E, Pontikaki I, Modorati G, Gattinara M, Meroni PL, Gerloni V. Anti-CD 20 monoclonal antibody (rituximab) treatment for inflammatory ocular diseases. *Autoimmun Rev* 2011;11:35-9.
5. Aouba A, Pagnoux C, Bienvenu B, Mahr A, Guillevin L. Analysis of Wegener's granulomatosis responses to rituximab: Current evidence and therapeutic prospects. *Clin Rev Allergy Immunol* 2008;34:65-73.
6. Stone JH, Merkel PA, Spiera R, Seo P, Langford CA, Hoffman GS, *et al.* RAVE ITN Research Group. Rituximab versus cyclophosphamide for ANCA associated vasculitis. *N Engl J Med* 2010;363:221-32.
7. Perez-Jacoiste Asín MA, Charles P, Rothchild PR, Terrier B, Brenzin A, Mouthon L, *et al.* Ocular involvement in granulomatosis with polyangiitis: A single-center cohort study on 63 patients. *Autoimmun Rev* 2019;18:493-500.
8. Dudam R, Gundal N. Checklist prior to biologics: Indian perspective. *Indian J Rheumatol* 2016;11:126-8.
9. Dogra M, Bajgai P, Kumar A, Sharma A. Progressive outer retinal necrosis after rituximab and cyclophosphamide therapy. *Indian J Ophthalmol* 2018;66:591-3.
10. Calabrese LH, Molloy ES. Therapy: Rituximab and PML risk-informed decisions needed! *Nat Rev Rheumatol* 2009;5:528-9.