

Subacute cutaneous lupus erythematosus induced by gemcitabine in 2 patients with pancreatic cancer



Matthew A. Cornacchia, BSc,^a Alexandra J. Coromilas, MD,^b Stephanie M. Gallitano, MD,^b Richard C. Frank, MD,^c and Charles L. Halasz, MD^b
Miramar, Florida; New York, New York; and Norwalk, Connecticut

Key words: chemotherapeutics; drug reaction; gemcitabine; photo-recall; subacute cutaneous lupus erythematosus.

INTRODUCTION

Gemcitabine is a nucleoside analog that inhibits cell growth by incorporating into DNA and prohibiting DNA polymerases. This chemotherapeutic agent is approved for the treatment of multiple solid tumors. Common side effects include hematologic toxicity, flu-like symptoms, peripheral edema, and gastrointestinal disturbances.¹ Cutaneous reactions occur in up to 30% of patients but rarely require discontinuation.² Reports have surfaced over the years of gemcitabine-induced erysipeloid, pseudo-cellulitis reactions, lipodermatosclerosis, and skin necrosis.³ To our knowledge, only 3 previous reports exist that describe gemcitabine-induced subacute cutaneous lupus erythematosus (SCLE) (Table 1).⁴⁻⁶ We present 2 cases of SCLE induced by gemcitabine chemotherapy in patients with pancreatic cancer.

CASE 1

An 88-year-old active, independent woman with hypothyroidism, hypertension, gastroesophageal reflux disease and atrial fibrillation was referred to a gastroenterologist by her primary care physician for abdominal pain, distention, pale bowel movements, and jaundice for 6 weeks. Workup found pancreatic ductal adenocarcinoma. The patient opted for treatment rather than palliative/hospice care. She was treated with oral capecitabine, 825 mg/m² twice a day for 14 days of a 21-day cycle, and subsequently dose-attenuated gemcitabine, 900 mg/m²

Abbreviations used:

ANA: antinuclear antibodies
 DI: drug-induced
 SCLE: subacute cutaneous lupus erythematosus

intravenously on days 1, 8, and 15 was added. After her second weekly dose of gemcitabine, pruritic, red papules and plaques with focal scale developed in a photodistributed pattern; these lesions were centrally confluent on her chest and back (Fig 1). The lesions did not respond to initial treatment with hydrocortisone 2.5% topical lotion twice daily nor to a methylprednisolone 4-mg dose pack.

Skin biopsy findings included parakeratosis, hyperkeratosis, epidermal atrophy, vacuolar interface change, subtle epidermal dysmaturation, and a sparse lymphocytic infiltrate (Fig 2). Direct immunofluorescence testing was negative. Serologic analysis was positive for antibodies SS-A, greater than 8 (reference range, <1.0); SS-B, 4.9 (reference range, <1.0); antinuclear antibodies (ANAs) with a titer of 1:160 (reference range, <1:40); and a nucleolar pattern supporting a diagnosis of SCLE. Because of the patient's grade 3 reaction with marked pruritus interfering with her ability to sleep, gemcitabine was discontinued 2 weeks after the onset of the rash. Triamcinolone 0.1% cream was also added to her treatment regimen. Capecitabine and rabeprazole were continued. Her pruritus and rash gradually

From Ross University School of Medicine, Miramar^a; the Department of Dermatology, Columbia University^b; and the Department of Hematology-Oncology, Norwalk Hospital.^c

Funding sources: None.

Conflicts of interest: None disclosed.

Correspondence to: Charles L. Halasz, MD, Department of Dermatology, Columbia University, 149 East Ave, Ste 20, New York, NY 06851. E-mail: clh1@columbia.edu; Charles.halasz@gmail.com.

JAAD Case Reports 2019;5:596-601.
 2352-5126

© 2019 by the American Academy of Dermatology, Inc. Published by Elsevier, Inc. This is an open access article under the CC BY-NC-ND license (<http://creativecommons.org/licenses/by-nc-nd/4.0/>).

<https://doi.org/10.1016/j.jdc.2019.04.020>

Table I. Comparison of case 1 and case 2 with current cases reported in the literature

	Case 1	Case 2	Wiznia et al ⁴	Ben Zvi et al ⁵	Lam ⁶
Age	88	67	71	63	73
Sex	F	M	F	F	F
Incubation period	2 wk	1 wk	2 wk	3 d	5 mo
Serology	+ ANA, SSA, SSB	+ ANA, SSA	+ ANA, SSA, SSB	Negative	Negative
Cutaneous features	Red papules and plaques with focal scale of chest and back	Annular and confluent scaly pink plaques face, neck, chest, arms	Scaly erythematous annular plaques of arms, papules of chest	Reddish-violaceous annular-like edematous scaly lesions of lower extremities	Erythematous plaques of scalp, chest, back, arms, legs
Histopathology	Epidermal atrophy, vacuolar interface change, sparse lymphocytic infiltrate; DIF negative	Epidermal necrosis, superficial perivascular lymphocytic infiltrate; DIF negative	Thinned epidermis, dermoepidermal junction vacuolar alteration, superficial and deep perivascular infiltrate	Effaced rete pegs, vacuolar interface, superficial and deep perivascular mononuclear lymphocyte infiltrate and dermal mucin deposition	Epidermal atrophy, band-like lymphocytic infiltrate at dermoepidermal junction, vacuolar degeneration, mild increase in dermal mucin
Outcome	Resolution after discontinuation + topical and oral steroids	Resolution after discontinuation + quinacrine	Resolution after discontinuation + topical and oral steroids	Resolution after discontinuation + oral steroids	Resolution after discontinuation + topical steroids
Time to resolution after discontinuing gemcitabine	3 mo	4 mo	5 wk	Unknown	8 mo

DIF, Direct immunofluorescence.

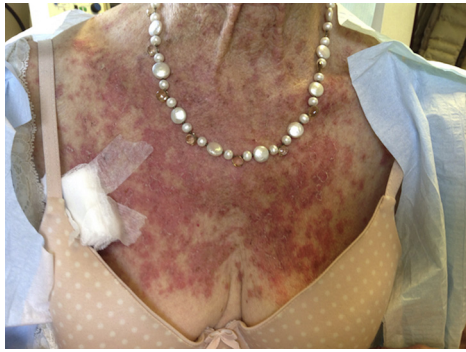

Fig 1. Erythematous, papulosquamous changes on the patient's chest after her second weekly dose of gemcitabine (case 1).

resolved over the next 3 months; however, both the ANA titer (1:320) and SS-A titer (>8) remained elevated. Interestingly, the SS-B titer declined to 1.2.

CASE 2

A 67-year-old man with a medical history of pulmonary sarcoidosis not on active treatment, atrial fibrillation, and unspecified connective tissue disease (diagnosed over 7 years prior based on joint pain, pericardial effusion, and positive ANA/anti-Ro, anti-La antibodies) presented for unintentional 45-pound weight loss. Pancreatic ductal adenocarcinoma was the ultimate diagnosis. The patient received 4 infusions of neoadjuvant mFOLFIRINOX (modified regimen of 5-fluorouracil, leucovorin, irinotecan, and oxaliplatin) and underwent distal pancreatectomy and splenectomy. Two months postoperatively he began adjuvant chemotherapy with gemcitabine and capecitabine. Within 1 week of his first infusion, he developed a rash, oral ulcers, and fatigue developed. Dermatologic evaluation found pink plaques with focal central scale (some annular and others more confluent) of the lateral face with notable sparing of the mid-face, posterior, and lateral neck; upper chest; and bilateral forearms (Fig 3). There was ulceration of the frenulum and the gingivae. Laboratory results were notable for pancytopenia with white blood cell count of 2.65 cells/L; hemoglobin, 11.0 g/dL; and platelet count of 42,000 per microliter. Serologic analysis was positive for ANA (no titer available) and anti SS-A antibodies. Anti SS-B antibodies were negative. Histopathology from skin biopsy of the arm demonstrated interface change with extensive epidermal necrosis, dermal superficial perivascular lymphocytic infiltrate, and rare eosinophils (Fig 4). Direct immunofluorescence was negative. Drug-induced SCLE (DI-SCLE) was diagnosed based on clinical presentation and supportive histopathology and serologies.

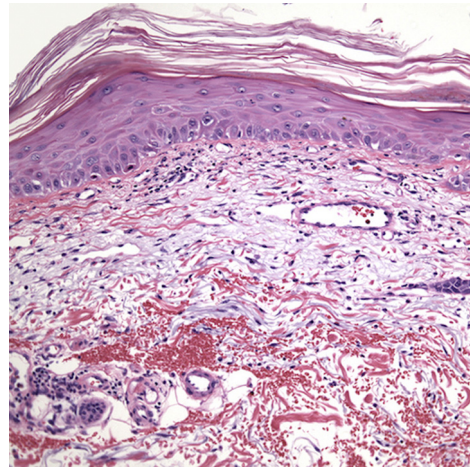


Fig 2. Interface dermatitis with basilar necrotic keratinocytes, subtle dysmaturation, and foci of parakeratosis (case 1).

Capecitabine was felt to be the most likely culprit and was discontinued. The patient began topical clobetasol and resumed chemotherapy with gemcitabine and abraxane. However, the patient's rash flared after receiving the infusion. This re-exposure confirmed that gemcitabine was actually the culprit medication, and gemcitabine was subsequently discontinued. The rash persisted after medication was discontinued for 6 weeks, which is not uncommon for DI-SCLE but is less common in phototoxic skin reactions. The patient was initiated on quinacrine, as he had a history of retinopathy secondary to hydroxychloroquine, which had been discontinued 2 years before this evaluation. The patient's chemotherapy was transitioned to FOLFIRI (5-fluorouracil, irinotecan, and leucovorin calcium). Within 4 months of follow-up the patient's rash completely resolved with hypo- and hyperpigmentation.

DISCUSSION

SCLE is a subset of cutaneous lupus erythematosus that is characterized by a nonscarring papulosquamous rash, photosensitivity, and anti-Ro/SS-A antibodies. Over the last decade, there has been an increasing number of drugs implicated as triggers for DI-SCLE, most notably antihypertensive drugs, such as calcium channel blockers, angiotensin-converting enzyme inhibitors, and antifungals. Chemotherapeutics have also been implicated in DI-SCLE including fluorouracil, capecitabine, doxorubicin, paclitaxel, doxorubicin, gemcitabine, and the selective estrogen receptor modulator, tamoxifen.⁴ The pathogenesis of DI-SCLE is not fully understood. In particular, it is hypothesized that chemotherapeutic agents can induce SCLE

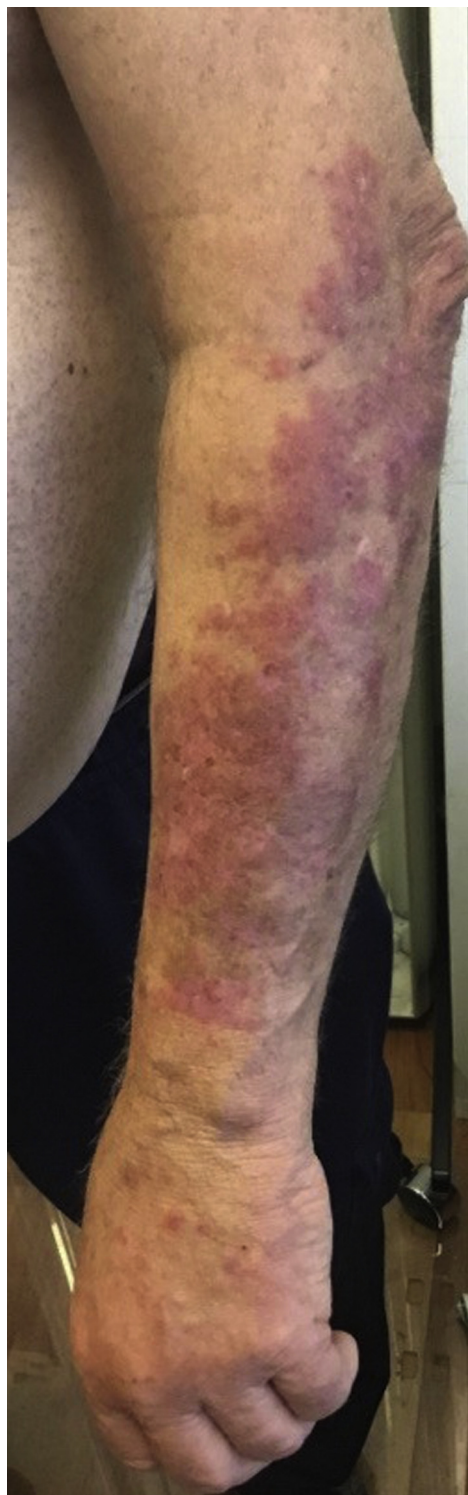

Fig 3. Psoriasiform papules coalescing into plaques on the forearm (case 2).

through induction of apoptosis, leading to nucleosome release, which then act as target antigens and induce an autoimmune response.⁷ Gemcitabine is a nucleoside analog that leads to apoptosis through

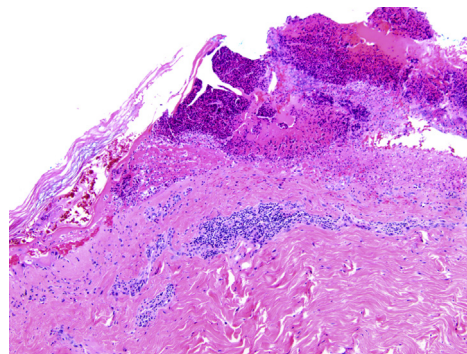


Fig 4. Interface change with extensive epidermal necrosis, dermal superficial perivascular lymphocytic infiltrate, and rare eosinophils (case 2).

replacement of cytosine in DNA replication and through inactivation of ribonucleotide reductase. Thus, it is reasonable to speculate that similar to other chemotherapeutic agents implicated in DI-SCLE, gemcitabine stimulates an exacerbated immune response through increased levels of apoptotic products.

SCLE can present weeks to years after medication initiation with a photoexacerbated psoriasiform or annular, scaly rash. It is classically distributed on the chest (V pattern), upper back, shoulders, and neck. The lateral face can be involved, but the central face is typically spared. Although drug-induced SCLE is usually clinically indistinguishable from the nonmedication-related cases, it has been reported to have higher predilection for the face and lower extremities and more commonly presents with cutaneous vasculitis and bullous lesions. Laboratory findings include positive ANA, and positive anti-SSA in up to 90% of cases. Anti-SSB antibodies may be positive in a lower percentage of cases. Skin biopsy shows interface dermatitis with vacuolization of the basal layer and perivascular lymphocytic infiltrate, and direct immunofluorescence may or may not be positive for IgG, IgM, and C3 at the dermoepidermal junction. Eosinophils may be present in both DI-SCLE and SCLE but cannot be used to differentiate the 2 conditions.⁸ The rash typically resolves with medication cessation, and the serologies may fluctuate over time.

Our patients' new-onset rashes presented in a photodistributed pattern. For case one, the presentation was striking in that it developed in early spring, with the presence of cold temperatures and limited sun exposure. Case 2 presented in early summer. Given these patterns, a photo-recall phenomenon was also considered, particularly because gemcitabine has been reported as a culprit.⁹ Photo-recall reactions are similar to radiation-recall

reactions, in which an eruption occurs on areas of previous ultraviolet-induced sunburn or radiation damage, respectively. Clinical findings for photo-recall resemble an exaggerated sunburn reaction, with confluent bright red erythema sharply demarcated from sun-protected sites. There may be superimposed blisters. Photo-recall reactions have been reported after administration of multiple medications.¹⁰ Although interface dermatitis with necrotic keratinocytes has been documented in photo-recall reactions, the patients' clinical presentations with papulosquamous and annular lesions and positive ANA, SS-A, and, in case one, SS-B antibodies, are more consistent with SCLE.^{11,12} In case 2, the patient's history of positive ANA and autoimmune diathesis may have predisposed him to DI-SCLE. Additionally, the recurrence of skin eruption with rechallenge further supports the diagnosis of DI-SCLE.

The distinction between photo-recall and SCLE is important. Photo-recall occurs on previously sunburned skin, usually 1 to 8 days after drug administration. It does not typically spare the mid-face. It does not usually recur with drug rechallenge and may be managed with topical/systemic corticosteroids and photo-protective measures.^{11,13} DI-SCLE can be managed similarly, but resolution of symptoms requires discontinuation of the offending agent.^{12,14} In previous reports of chemotherapy-induced photo-recall, ANA, anti-Ro, and anti-La were not always measured.¹¹ It is important that serologic analysis of antibodies be performed after a drug-induced rash to help distinguish between the 2 diseases.

The incubation period between medication initiation and rash onset is varied in DI-SCLE and is medication dependent. In both of our patients, the onset of cutaneous symptoms was soon after gemcitabine initiation, after the second and first infusions, respectively. These incubation periods are similar to those in cases of gemcitabine-induced SCLE reported by Wiznia and colleagues.⁴ Both patients presented in this report were simultaneously taking the chemotherapeutic agent capecitabine, which has also been implicated in DI-SCLE.^{15,16} Determining which agent is the most likely medication culprit is a challenge. In case 1, the chronology of administration made gemcitabine more likely. In case 2, capecitabine was felt to be the more likely agent, given the higher number of cases reported in the literature, and was discontinued first; however, resolution occurred only after discontinuation of gemcitabine.

Spontaneous resolution of DI-SCLE commonly occurs within 6 to 12 weeks of drug withdrawal, and Ro/SS-A titers decrease within 8 months in most

patients.¹⁷ Administration of topical corticosteroids can accelerate the process and provide symptomatic relief.¹⁸ Full resolution can vary as apparent by our cases and can require additional therapy. In case 2, quinacrine was added to hasten disease resolution.

Our cases add to the literature on gemcitabine-induced SCLE. Gemcitabine is a commonly used chemotherapeutic agent. Cutaneous side effects of all grades are common and require discontinuation in less than 1% of cases.² However, physicians should be aware of the rare presentation of photo-distributed DI-SCLE, as discontinuation of the causative drug is indicated. This type of case requires close multidisciplinary care with oncology and dermatology departments.

REFERENCES

1. Tonato M, Mosconi AM, Martin C. Safety profile of gemcitabine. *Anticancer Drugs. Semin Oncol.* 1995;6:27-32.
2. *Gemzar [package insert]*. Indianapolis, IN: Eli Lilly and Company; 2018.
3. Mittal A, Leventhal JS. Gemcitabine-associated acute lipodermatosclerosislike eruption: an underrecognized phenomenon. *JAAD case Rep.* 2017;3(3):190-195.
4. Wiznia LE, Subtil A, Choi JN. Subacute cutaneous lupus erythematosus induced by chemotherapy gemcitabine as a causative Agent. *JAMA Dermatol.* 2013;149(9):1071-1075.
5. Ben Zvi M, Vaknine H, Menczer J, et al. Gemcitabine-induced subacute cutaneous lupus erythematosus: a case report. *Chemotherapy.* 2016;61(5):236-239.
6. Lam L. Gemcitabine-induced subacute cutaneous lupus erythematosus-like eruption responding to insulin therapy in a patient with pancreatic cancer. *J Am Acad Dermatol.* 2015;72(5):48.
7. Chen M, Crowson AN, Woofter M, Luca MB, Magro CM. Docetaxel (Taxotere) induced subacute cutaneous lupus erythematosus: report of 4 cases. *J Rheumatol.* 2004;31(4):818-820.
8. Hillesheim PB, Bahrami S, Jeffy BG, Callen JP. Tissue eosinophilia: not an indicator of drug-induced subacute cutaneous lupus erythematosus. *Arch Dermatol.* 2012;148(2):190-193.
9. Badger J, Uzieblo A, Srinivas S, Kang S. Double diagnosis in cancer patients and cutaneous reaction related to gemcitabine: CASE 3. Photo therapy recall with gemcitabine following ultraviolet B treatment. *J Clin Oncol.* 2005;23(28):7224-7225.
10. Sanborn R, Sauer D. Cutaneous reactions to chemotherapy: commonly seen, less described, little understood. *Dermatol Clin.* 2008;26(1):103-119.
11. Droitcourt C, Le Hô H, Adamski H, et al. Docetaxel-induced photo-recall phenomenon. *Photodermatol Photoimmunol Photomed.* 2012;28(4):222-223.
12. Smith KJ, Germain M, Skelton H. Histopathologic features seen with radiation recall or enhancement eruptions. *J Cutan Med Surg.* 2002;6(6):535-540.
13. Caloglu M, Yurut-Caloglu V, Cosar-Alas R, et al. An ambiguous phenomenon of radiation and drugs: recall reactions. *Onkologije.* 2007;30(4):209-214.
14. Marzano AV, Tvecchio S, Menicanti C, et al. Drug-induced lupus erythematosus. *G Ital Dermatol Venereol.* 2014;149(3):301-309.

15. Fernandes NF, Rosenbach M, Elenitsas R, Kist JM. Subacute cutaneous lupus erythematosus associated with capecitabine monotherapy. *Arch Dermatol*. 2009;145(3):340-341.
16. Floristan U, Feltes RA, Sendagorta E, et al. Subacute cutaneous lupus erythematosus induced by capecitabine. *Clin Exp Dermatol*. 2009;34(7):e328-e329.
17. Srivastava M, Rencic A, Diglio G, et al. Drug-induced, Ro/SSA-positive cutaneous lupus erythematosus. *Arch Dermatol*. 2003;139:45-49.
18. Lowe G, Henderson CL, Grau RH, et al. A systematic review of drug-induced subacute cutaneous lupus erythematosus. *Br J Dermatol*. 2011;164(3):465-472.