

# Correlations Between Intratumoral Microvessel Density and Histopathological Type or Neoadjuvant Radiotherapy for Rectal Carcinoma

T. DUMITRESCU<sup>1</sup>, C.D. USCATU<sup>2</sup>, D.O. ALEXANDRU<sup>3</sup>, C. MEȘINĂ<sup>1</sup>, S.Ș. MOGOANTĂ<sup>1</sup>, ILEANA DINCĂ<sup>1</sup>, E. MORARU<sup>1</sup>, ALEXANDRA DUMITRESCU<sup>4</sup>, D.I. GHEONEA<sup>5</sup>, RALUCA ELENA NICOLI<sup>6</sup>, I. VASILE<sup>1</sup>

<sup>1</sup>Department of Surgery, University of Medicine and Pharmacy of Craiova, Romania;

Department of Surgery, Emergency County Hospital Craiova, Romania

<sup>2</sup>Department of Pathology, Emergency County Hospital Craiova, Romania; Department of Cellular and Molecular Biology, University of Medicine and Pharmacy of Craiova, Romania

<sup>3</sup>Department of Medical Informatics and Biostatistics, University of Medicine and Pharmacy of Craiova, Romania

<sup>4</sup>Department of Oncology, Emergency County Hospital Craiova, Romania

<sup>5</sup>Department of Gastroenterology, University of Medicine and Pharmacy of Craiova, Romania

<sup>6</sup>Department of Human Genomix Laboratory, University of Medicine and Pharmacy of Craiova, Romania

**ABSTRACT: Purpose:** This study aims to evaluate intratumoral microvessel density in rectal carcinoma cases with different histopathological type (adenocarcinoma and mucinous carcinoma) and different preoperative neoadjuvant radiotherapy status (irradiated / non-irradiated), thus analyzing any possible statistical correlation between these parameters. **Material and methods:** Our prospective study consists in standard immunohistochemistry procedures using CD34, CD31 and CD105 antibodies, which were performed on 25 samples of rectal carcinoma, in order to determine intratumoral microvessel density. **Results:** The 25 case study group was divided either by histopathological type or by prior radiotherapeutical treatment as follows: 9 cases of mucinous carcinoma versus 16 cases of adenocarcinoma and 13 cases of rectal cancer that have not received neoadjuvant radiotherapy versus 12 cases of rectal cancer with preoperative radiotherapy. **Conclusions:** The number of intratumoral microvessels is higher in non-irradiated rectal tumors and in adenocarcinomas, this remark being statistically significant (with only one exception – CD34 staining in non-irradiated versus irradiated tumors) for all types of vessels (new-grown and mature). This result is due to the benefic effect of neoadjuvant radiotherapy on decreasing angiogenic activity, thus having an important prognostic value for rectal cancer.

**KEYWORDS:** rectal cancer, CD34, CD31, CD105, radiotherapy, histopathological

## Introduction

Rectal cancer (RC), as a part of the large entity – colorectal cancer (CRC), is one of the major health problems worldwide. The angiogenesis of CRC is more and more studied as treatments are based on many anti-angiogenic factors that have a benefic effect on tumors evolution.

Tumor angiogenesis can be evidenced with many antibodies using immunohistochemistry. Although a specifically antibody for the endothelial intratumoral cells has not yet been discovered, the majority of studies use three endothelial markers for evaluating intratumoral microvessel density (ITMVD): CD34, CD31 (PECAM-1) and CD105 (endoglin) [1, 2]. Numerous studies revealed that the endoglin (CD105) marks just the proliferating (activated) endothelium, respectively the neoformed vessels and could be considered the most reliable immunohistochemical marker for neoformation blood vessels detection [3, 4, 5]. During blood vessel maturation, CD105 expression is

gradually diminishing and CD31 expression is increasing. It is known that the CD31, a platelet endothelial cell adhesion molecule, also marks the mature and neoformed vessels. Therefore CD 31 and CD34 (which is expressed in blood vessel – mature and new-grown - and lymphatic vessels, as well) are panendothelial cell markers for blood vessel endothelium [6].

## Purpose

This study aims to evaluate intratumoral microvessel density (ITMVD) in rectal carcinoma cases with different histopathological type (adenocarcinoma and mucinous carcinoma) and different preoperative neoadjuvant radiotherapy status (irradiated and non-irradiated), thus analyzing any possible statistical correlation between these parameters.

## Material and methods

We developed a prospective study in which rectal carcinoma tissue samples were collected from 25 patients that underwent surgery at

Emergency County Hospital, IInd Surgery Clinic, Craiova, Romania from May 2014 to October 2014. All patients were informed about their participation in this study and a written consent was provided by every patient.

Thirteen of them had surgery as a first therapeutical step, while the other twelve underwent surgery after preoperatory neoadjuvant radiotherapy.

All the samples were processed using classical histopathological technique (fixation in 10% buffered formalin and embedding in paraffin). Serial sections of 3  $\mu$ m in thickness were cut from each paraffin block.

The first section from each case was stained with Hematoxylin–Eosin (HE) for diagnosis orientation and was revised for the histopathological type (adenocarcinoma or mucinous carcinoma). The next three consecutive sections were immunostained with one of the three antibodies (CD34, CD31, CD105) for detection of different type of blood vessels in the following order: the first of the three sections was stained for CD34 (Endothelial Cell Marker) expression, the second was stained for CD31 (PECAM-1) expression and the third section was stained for CD105 (Endoglin) expression. All three antibodies were provided by Novocastra and were Lyophilized Mouse Monoclonal Antibodies, used in dilution 1:70.

We used a standard immunohistochemistry (IHC) technique: dewaxing in xylene; rehydrating in graded solutions of ethanol; blocking of endogenous peroxidase with 6% H<sub>2</sub>O<sub>2</sub>; retrieving of the antigen: microwaving slides in citrate buffer - pH 6.0, 20 minutes, 650W; washing in PBS (pH 7.0); blocking nonspecific binding sites with 3% Nonfat-Dried Milk Bovine (Sigma-Aldrich) for 30 minutes at 250C; incubating with primary antibody for 30 minutes at 250C; incubating with EnVision (Dako) for 30 minutes at 250C; antibody detection with diaminobenzidine (DAB) for 9 minutes at 250C; counterstaining with Hematoxylin-Eosin.

After performing HE and IHC staining, all slides were photographed with an Olympus CX 31 microscope and a ColorView II camera and

analyzed using AnalySis Pro 5.0 software. For each slide stained for blood vessels evaluation, five photographs were selected from the middle of the tumor, from approximately the same area, using the 20x objective of the microscope. Afterwards, we counted the blood vessels stained with CD34, CD31 and CD105, and we reported their number per square millimeter in tumor mass in order to obtain ITMVD. All measurements were exported in an Excel file (Microsoft Office, 2007). The lowest value (VMIN), the highest value (VMAX), mean/average value (AV) and standard deviation (STDEV) were assessed for each of the defined subgroups.

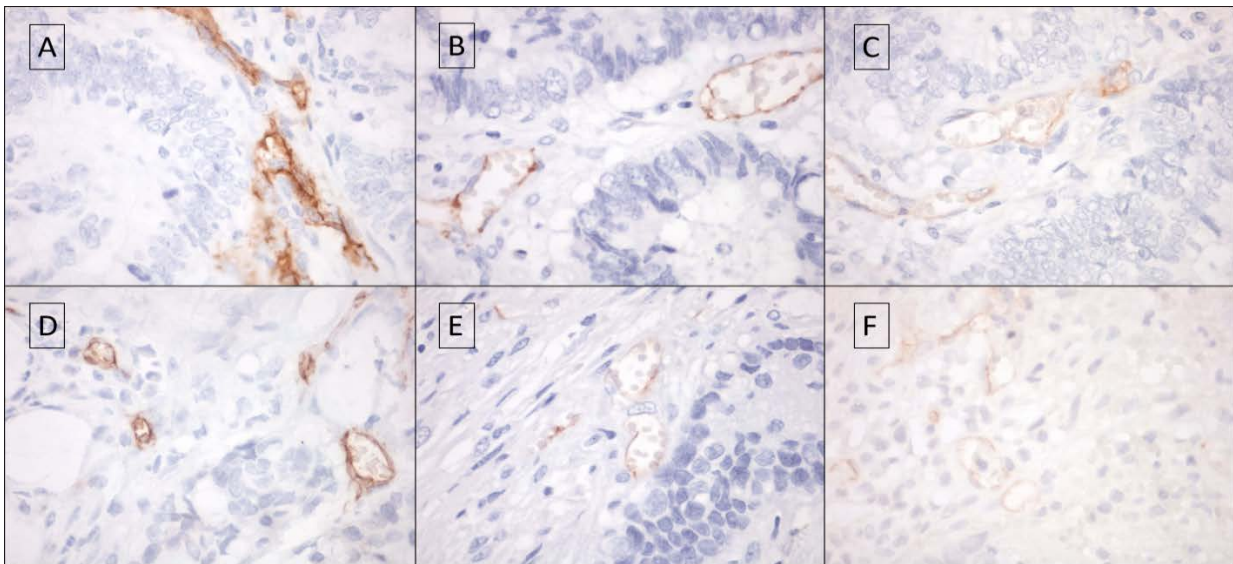
Statistical data analysis was done with the help of Student's t-test from XLSTAT version 3.02 ( $p < 0.05$  indicates statistical significance).

## Results

The 25 case study group was divided either by histopathological type or by prior radiotherapeutical treatment as follows: 9 cases of mucinous carcinoma versus 16 cases of adenocarcinoma and 13 cases of rectal cancer that have not received neoadjuvant radiotherapy versus 12 cases of rectal cancer with preoperatory radiotherapy.

For each rectal cancer case was obtained a certain ITMVD (after counting microvessels) corresponding to each immunohistochemical staining with CD34, CD31 and CD105 (Fig. 1). We used these three markers in order to remark the differences between the number of new-formed blood vessels (that are marked with CD105), mature blood vessels (that are marked with CD31) and all blood vessels (that are marked with CD34).

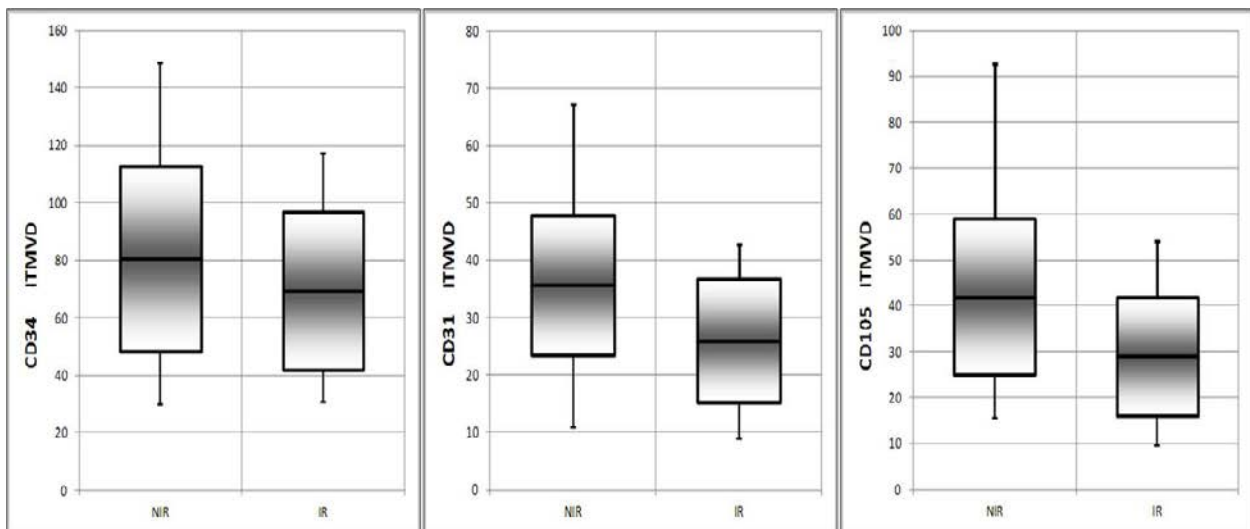
ITMVD values depending on histopathological type and on neoadjuvant radiotherapy status were used for graphic representation (using average value (AV) of ITMVD, standard deviation (STDEV), the lowest value (VMIN) and the highest value (VMAX) for each created subgroup) and for statistical evaluation in order to analyze the correlations between them.



**Fig.1. ITMVD determination using CD34, CD31 and respectively CD105 for adenocarcinoma (A, B, C) and for mucinous carcinoma (D, E, F)**

The average value (AV) was higher for each immunohistochemical staining in non-irradiated group of rectal tumors. Standard deviation values (STDEV) were not significantly different in the two groups, therefore the intervals

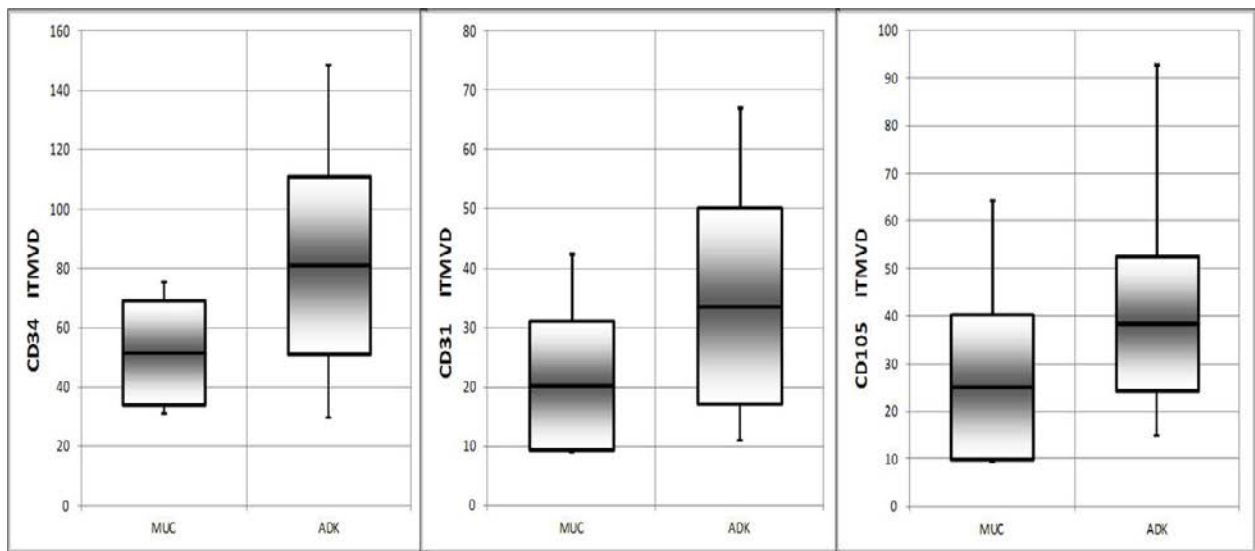
comprising the majority of ITMVD values were almost equal. However, in irradiated rectal tumor group, this interval was displaced towards the lower values of ITMVD (Fig. 2).



**Fig.2. Distribution of ITMVD values (obtained with CD34, CD31 and respectively CD105) depending on neoadjuvant radiotherapy**

Mucinous carcinomas had a smaller AV for ITMVD values compared to adenocarcinomas for each of the three studied antibodies. STDEV values for ITMVD were also lower in MUC group in CD34 and CD31 staining and the

intervals comprising the majority of ITMVD values were smaller than those in ADK group, thus defining MUC group as a more compact group, with fewer number of microvessels (Fig. 3).



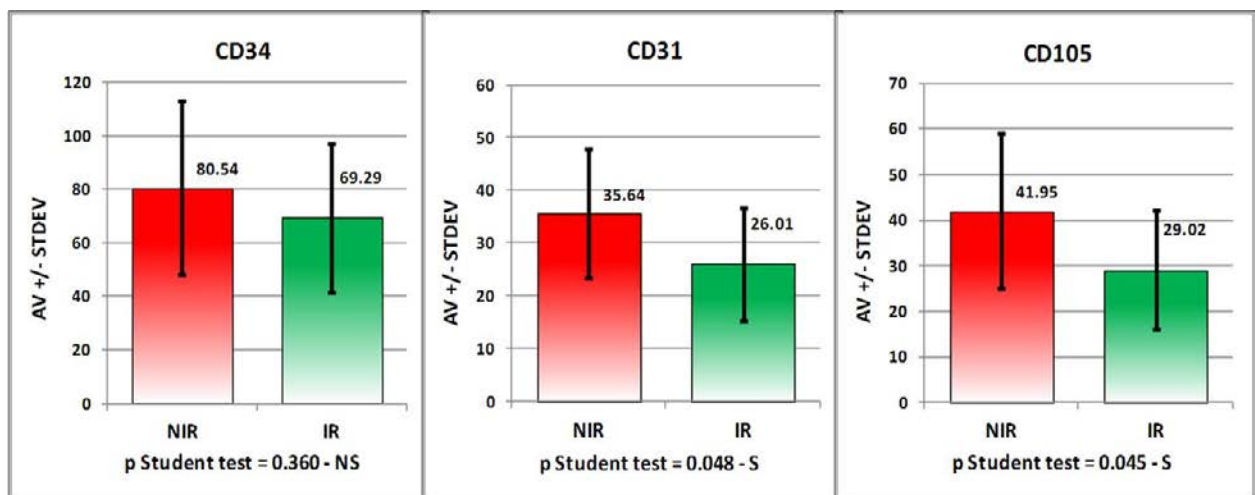
**Fig.3. Distribution of ITMVD values (obtained with CD34, CD31 and respectively CD105) depending on histopathological type**

Using Student test for each immunohistochemical staining with CD34, CD31 and CD105 depending on the two studied

parameters (histopathological type and neoadjuvant radiotherapy status), the following p – values were obtained (Table 1, Fig.4, 5):

**Table 1. p-values using Student test for each IHC staining in non-irradiated versus irradiated group and in mucinous carcinoma versus adenocarcinoma**

	<b>CD34</b>	<b>CD31</b>	<b>CD105</b>
<b>NIR vs. IR</b>	0.36 – non significant	0.048 - significant	0.045 - significant
<b>MUC vs. ADK</b>	0.013 - significant	0.04 - significant	0.039 - significant



**Fig.4. Student test for ITMVD values (obtained with CD34, CD31 and respectively CD105) depending on neoadjuvant radiotherapy**

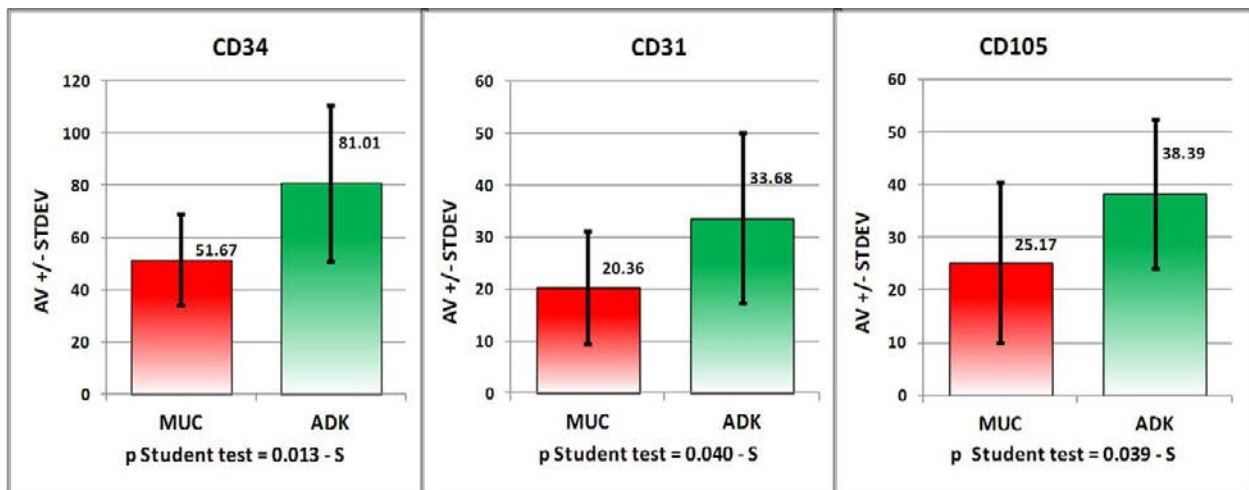


Fig.5. Student test for ITMVD values (obtained with CD34, CD31 and respectively CD105) depending on histopathological type

## Discussions

This study demonstrates the presence of a higher number of microvessels in the tumoral mass for non-irradiated rectal tumors compared to irradiated ones, these findings being confirmed by other authors as well [7, 8, 9]. This observation is valid for all types of microvessels (the overall number of vessels, the new-grown ones and the mature ones), and the same result was obtained for each of the three immunohistochemical staining with CD34, CD31 and CD105, the result being statistically significant for CD31 and CD105 (Figure 4). Therefore, once again, it can be remarked the benefic effect of neoadjuvant radiotherapy on decreasing angiogenic activity in rectal carcinoma by destroying the integrity of the vascular structure. This favorable effect on ITMVD, together with the well-known shrinking effect on tumor size, have an important prognostic value for rectal cancer, increasing survival rates [10]. ITMVD and its relationship to the outcome of treatment and prognosis of rectal cancer have been studied extensively lately, therefore ITMVD is thought to be a favorable marker for tumor behavior during radiotherapy and a predictor of overall survival after radiotherapy [7].

Adenocarcinomas have a high number of microvessels compared to mucinous carcinomas in this study. This remark is applicable for all type of vessels (young, mature and whole vessels) and has statistically significance for each of the three antibodies CD34, CD31 and CD105 (Figure 5). This lower number of microvessels found in mucinous carcinomas can be explained by mucus accumulation inside the

tumor, which reduces very much tumoral stroma.

## Conclusions

The number of intratumoral microvessels is higher in non-irradiated rectal tumors and in adenocarcinomas and this finding has statistical significance (with only one exception – CD34 staining in non-irradiated versus irradiated tumors) for all types of vessels (new-grown and mature).

This result is due to benefic effect of neoadjuvant radiotherapy on decreasing angiogenic activity, having an important prognostic value for rectal cancer.

## Acknowledgement

This paper was published under the frame of European Social Found, Human Resources Development Operational Programme 2007-2013, project no. POSDRU/159/1.5/136893

## References

1. Gurzu S, Cimpean AM, Kovacs J et al, Counting of angiogenesis in colorectal carcinomas using double immunostain, *Tumori* 2012, 98(4), 485-90.
2. Moreira LR, Schenka AA, Latuf-Filho P et al, Immunohistochemical analysis of vascular density and area in colorectal carcinoma using different markers and comparison with clinicopathologic prognostic factors, *Tumour Biol.* 2011, 32(3), 527-34.
3. Gurzu S, Jung J, Azamfirei L et al, The aspects of angiogenesis in anal canal carcinomas compared with that in colorectal carcinomas, *Rom J Morphol Embryol.* 2007, 48(4), 349-53.
4. Romani AA, Borghetti AF, Del Rio P et al, The risk of developing metastatic disease in colorectal cancer is related to CD105-positive vessel count, *J Surg Oncol* 2006, 93, 446-455.

5. Fonsatti E, Altomonte M, Nicotra MR et al, Endoglin (CD105): a powerful therapeutic target on tumor-associated angiogenic blood vessels, *Oncogene* 2003, 22(42), 6557–6563.
6. Hasan J, Byers R, Jayson GC, Intra-tumoural microvessel density in human solid tumours, *Br J Cancer* 2002, 86, 1566–1577.
7. Svagzdys S, Lesauskaite V, Pavalkis D et al, Microvessel density as new prognostic marker after radiotherapy in rectal cancer, *BMC Cancer* 2009, 9, 95.
8. Coen I, Castermans K, Lammering G et al, Effects of radiotherapy and chemotherapy on angiogenesis and leukocyte infiltration in rectal cancer, *Int J Radiat Oncol Biol Phys* 2006, 66, 1219-1227.
9. Holmqvist A, Gao J, Adell G et al, The location of lymphangiogenesis is an independent prognostic factor in rectal cancers with or without preoperative radiotherapy, *Ann Oncol.* 2010, 21(3), 512-7.
10. Zhou YJ, Ye Q, Lu HS et al, Association of microvessel density and blood vessel invasion with the prognosis in rectal carcinoma at stages I to II, *Zhonghua Wei Chang Wai Ke Za Zhi*, 2010, 13(7), 516-9.

---

*Corresponding Author: Theodor Dumitrescu, MD, PhD, Department of Surgery,  
University of Medicine and Pharmacy of Craiova, 2-4 Petru Rares St., Craiova, Romania;  
Emergency County Hospital Craiova, 1<sup>st</sup> Tabaci St, Craiova, Romania;  
e-mail: theodor\_dumitrescu@yahoo.com*