

Iliac vein compression syndrome caused by a large bladder diverticulum: Case report and literature review

Journal of International Medical Research

2022, Vol. 50(9) 1–8

© The Author(s) 2022

Article reuse guidelines:

sagepub.com/journals-permissions

DOI: 10.1177/03000605221123670

journals.sagepub.com/home/imr

Xuebin Wang, Xueming Chen, Xiang Gao*
and Hai Feng* 

Abstract

Iliac vein compression syndrome is a rare disorder that causes oedema of one or both legs, with or without thrombosis. This current case report describes a 71-year-old male patient with left iliac vein compression caused by a bladder diverticulum that occurred secondary to chronic prostatic hyperplasia. The patient presented with left leg oedema without deep vein thrombosis. Contrast-enhanced computed tomography of the abdomen and pelvis, Doppler ultrasound imaging of the lower limb veins and magnetic resonance imaging helped confirm the diagnosis. The patient initially underwent urinary catheter placement, which relieved urinary retention and iliac vein compression. He subsequently underwent bladder diverticulectomy and transurethral prostatectomy. The postoperative clinical course was uneventful. During the 1.5-year follow-up, the patient did not have lower extremity oedema. Bladder diverticulum is an extremely rare cause of iliac vein compression syndrome, and only five such cases, including this one, have been reported to date. This article presents a literature review of these cases and a summary of the diagnosis and treatment experience.

Keywords

Iliac vein compression syndrome, bladder diverticulum, iliac vein, leg oedema, chronic prostatic hyperplasia, case report, literature review

Date received: 24 March 2022; accepted: 16 August 2022

Introduction

Iliac vein compression syndrome (IVCS) is characterized by unilateral or bilateral lower limb oedema with or without thrombosis. It primarily occurs secondary to

Department of Vascular Surgery, Beijing Friendship Hospital, Capital Medical University, Beijing, China

*These authors contributed equally to this work.

Corresponding author:

Hai Feng, Department of Vascular Surgery, Beijing Friendship Hospital, Capital Medical University, 95 Yong'an Road, Xicheng District, Beijing 100050, China.

Email: vascusugfh@ccmu.edu.cn



Creative Commons Non Commercial CC BY-NC: This article is distributed under the terms of the Creative Commons Attribution-NonCommercial 4.0 License (<https://creativecommons.org/licenses/by-nc/4.0/>) which permits non-commercial use, reproduction and distribution of the work without further permission provided the original work is attributed as specified on the SAGE and Open Access pages (<https://us.sagepub.com/en-us/nam/open-access-at-sage>).

congenital ectopia of iliac artery vessels (May-Thurner syndrome); and it is rarely associated with pelvic tumours, aortic aneurysms, retroperitoneal haematoma, retroperitoneal fibrosis, pregnant uterus, lumbar hyperosteoplasia, enlarged bladder and other diseases.¹⁻³ Further, it is extremely rare for IVCS to occur secondary to an enlarged bladder diverticulum. To date, only four such cases have been reported.⁴⁻⁷ Timely diagnosis and therapy are required to prevent potential complications and adverse sequelae of IVCS. This current case report describes a 71-year-old male patient with left iliac vein compression caused by a bladder diverticulum that occurred secondary to chronic prostatic hyperplasia.

Case report

In October 2020, a 71-year-old male patient was transferred to the Department of Vascular Surgery, Beijing Friendship Hospital Affiliated to Capital Medical University, Beijing, China due to recurrent oedema of the left lower extremity for 6 years (Figure 1a). The patient had a 20-year history of benign prostatic hyperplasia and had recurrent dysuria and urinary incontinence in the past 6 years. Typically, each time this patient developed urinary incontinence, left lower limb oedema also occurred. After 4-7 days, with the gradual improvement of urinary incontinence, leg oedema also gradually eased. However, this time, the patient's urinary incontinence lasted for 20 days and the

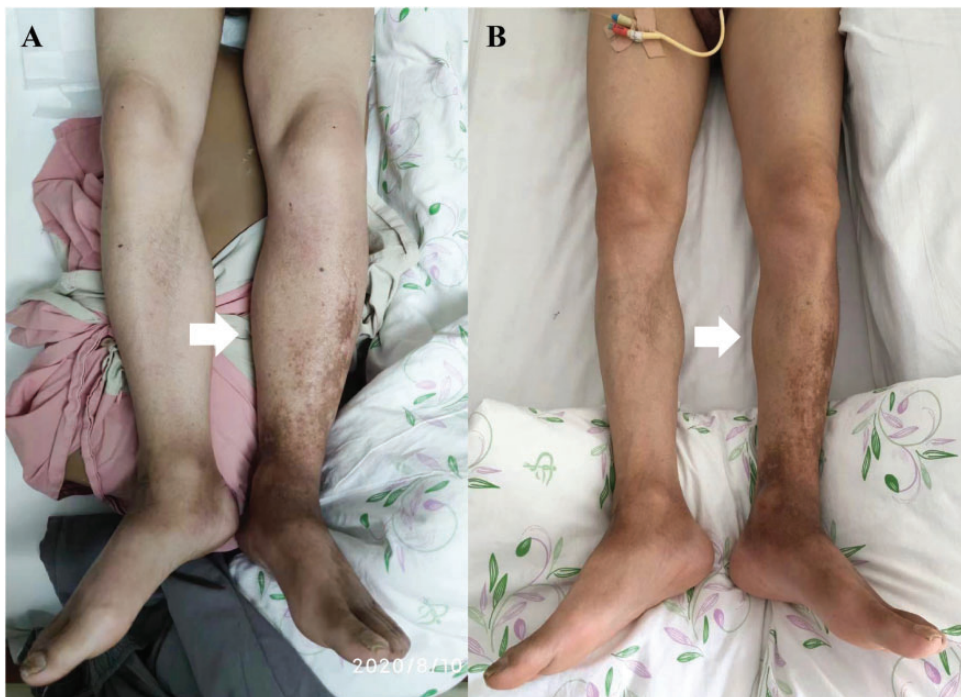

Figure 1. Representative photographs of a 71-year-old male patient that presented with recurrent oedema of the left lower extremity for 6 years: (a) On admission, the patient had significant left lower limb oedema (white arrow) and (b) Three days after indwelling of the urinary catheter, oedema of the left lower limb subsided (white arrow). The colour version of this figure is available at: <http://imr.sagepub.com>.

left lower limb oedema also continued for 20 days without relief. Urinary catheterization was performed at the local hospital but failed. The patient was then referred to the Department of Vascular Surgery, Beijing Friendship Hospital for further diagnosis and treatment.

At the time of admission, the patient's vital signs were stable. Physical examination revealed pitting oedema of the left lower extremity that extended from the foot to the groin. The circumference of the 15 cm above the knees of the bilateral lower limbs differed by 3 cm and the circumference of the 15 cm below the knee differed by 4 cm. No erythema, warmth or tenderness was present. Significant pigmentation was observed on the skin of the left ankle and calf. The patient did not exhibit Homans' sign. His bladder was obviously distended. Blood test results revealed renal impairment (urea, 13.45 mmol/l; creatinine, 193 μ mol/l) and an abnormal total prostate-specific antigen level (5.99 ng/ml). Blood gas analysis revealed respiratory acidosis (pH = 7.279, pCO₂ = 52.5 mmHg, PO₂ = 75 mmHg, SpO₂ = 94.5%). The D-dimer level was normal. Ultrasound examination of the leg veins showed that there was no thrombus. Contrast-enhanced computed tomography (CT) of the abdomen and pelvis showed an enlarged prostate gland, bilateral renal pelvis and ureteral dilatation, and a massive diverticulum of the bladder that resulted in severe compression of the left iliac vein (Figure 2a).

Treatment was initiated with oxygen inhalation and venous return promotion. A urinary catheter was successfully inserted into the bladder with the assistance of a urologist. Three days after indwelling of the urinary catheter, oedema of the left lower limb subsided (Figure 1b) and the serum creatinine and urea levels returned to normal. CT re-examination indicated that the bladder diverticulum was obviously

retracted and there was no compression of the left iliac vein (Figure 2b). Magnetic resonance imaging of the prostate showed that the prostate was significantly enlarged and partially protruded into the bladder (Figure 3). The patient was subsequently referred to the Department of Urology, Beijing Friendship Hospital Affiliated to Capital Medical University, Beijing, China where he underwent transurethral laser prostatectomy and laparoscopic bladder diverticulectomy. The postoperative clinical course was uneventful. At 1.5 years of follow-up, the patient was free of pain, venous oedema, varicose veins, skin indurations and ulcers in the left lower extremity, with only limited old skin pigmentation. During this period, the patient did not use compression therapy measures such as elastic stockings. He had a Venous Clinical Severity Score of 1 point. The reporting of this study conforms to CARE guidelines.⁸ Patient consent to treatment was obtained. Case reports are exempt from the requirement of ethics committee approval at the Capital Medical University, Beijing, China. Signed patient consent to publish was not required because the patient details were de-identified so that the identity of the patient cannot be ascertained in any way.

Discussion

As part of a narrative review of the literature regarding IVCS occurring secondary to an enlarged bladder diverticulum, a comprehensive bibliographic search of PubMed[®] was performed using the following search terms: (((“vesical”[All Fields] OR “vesicals”[All Fields]) AND (“diverticulae”[All Fields] OR “diverticulas”[All Fields] OR “diverticulum”[MeSH Terms] OR “diverticulum”[All Fields] OR “diverticula”[All Fields])) OR (“bladder diverticulum”[Supplementary Concept] OR “bladder diverticulum”[All Fields] OR “bladder diverticulum”[All Fields] OR (“bladders”

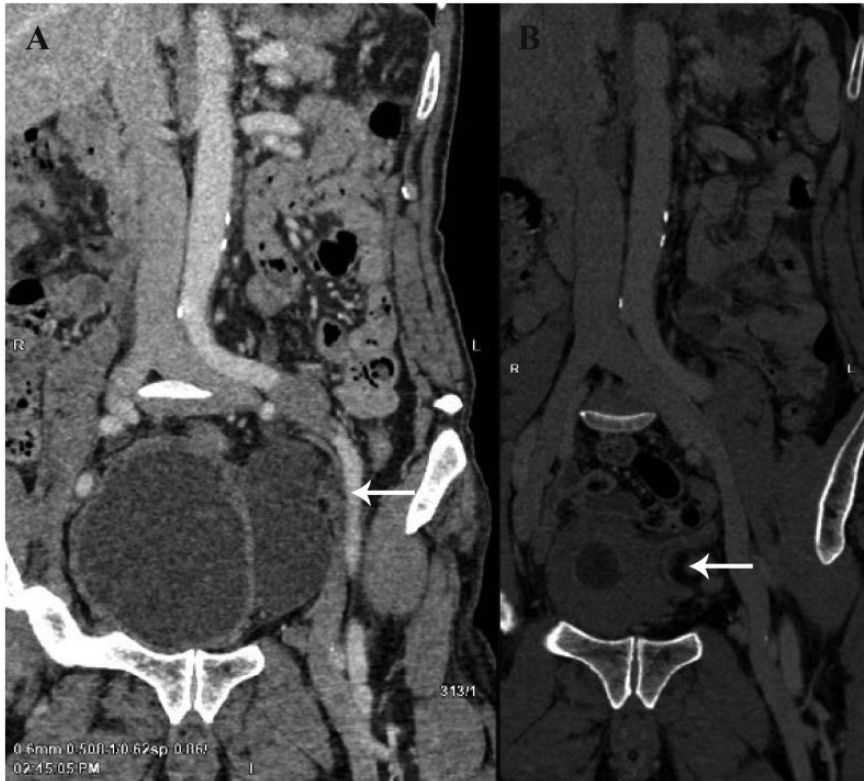

Figure 2. Representative computed tomography (CT) images of a 71-year-old male patient that presented with recurrent oedema of the left lower extremity for 6 years: (a) contrast-enhanced CT of the abdomen and pelvis showed a massive diverticulum of the bladder that resulted in severe compression of the left iliac vein (white arrow) and (b) CT re-examination indicated that the bladder diverticulum was obviously retracted and there was no compression of the left iliac vein (white arrow).

[All Fields] OR “urinary bladder”[MeSH Terms] OR (“urinary”[All Fields] AND “bladder”[All Fields]) OR “urinary bladder”[All Fields] OR “bladder”[All Fields] OR “bladders”[All Fields]) AND (“diverticulae”[All Fields] OR “diverticula”[All Fields] OR “diverticulum”[MeSH Terms] OR “diverticulum”[All Fields] OR “diverticula”[All Fields])) OR (“vesical”[All Fields] OR “vesicals”[All Fields]) AND (“diverticulum”[MeSH Terms] OR “diverticulum”[All Fields] OR “diverticulums” [All Fields])) AND (“veins”[MeSH Terms] OR “veins”[All Fields] OR “venous”[All Fields] OR

(“veins”[MeSH Terms] OR “veins”[All Fields] OR “vein”[All Fields])). The search identified 23 relevant citations. All the titles and abstracts were evaluated and 17 were excluded because they did not fit the research topic. Therefore, only six were selected for a full-text review. One of the six articles was found to be irrelevant, because it reported an enlarged bladder diverticulum compressing the inferior vena cava, although the pathogenesis was very similar to what is reported in the current case report. It was thus excluded considering that the topic of this article was iliac vein compression syndrome. For another article,

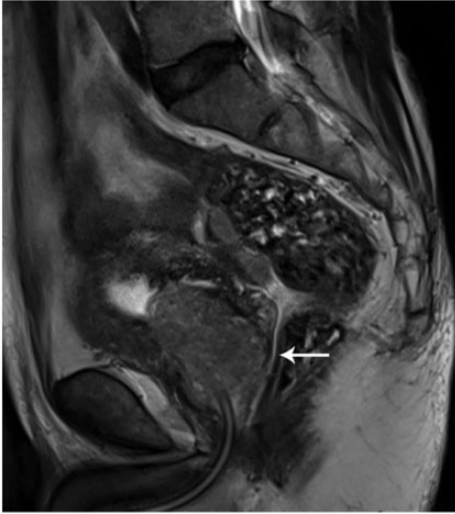

Figure 3. Magnetic resonance imaging of the prostate of a 71-year-old male patient that presented with recurrent oedema of the left lower extremity for 6 years showed that the prostate was significantly enlarged and partially protruded into the bladder (white arrow).

the full text was not available. Four studies were finally retrieved in full and cross-reference searches were performed.⁴⁻⁷ Finally, a total of five cases, including the current case, were reviewed. The process was completed by two investigators (X.B.W. & X.G.) that first determined the search terms and screened the retrieved literature. If necessary, the authors were contacted by email or telephone to obtain information not identified in the literature but meaningful to this study. When disagreement occurred, the superior physician (H.F.) was consulted for further clarification.

The demographic and clinical data for these five cases, including the current case, are shown in Table 1.⁴⁻⁷ All five were male; two were newborn infants and the other three were elderly men, with a median age of 71 years. One elderly patient was referred for progressive dyspnoea and the remaining four patients (including the current patient) were referred for different degrees of lower

Table 1. Results of the literature review of iliac vein compression syndrome due to bladder diverticulum.⁴⁻⁷

Authors	Year	Age, years	Sex	Presentation	Diagnosis	Therapy	Follow-up
Valadez et al. ⁴	1987	0.4	Male	Acute oedema and bluish discoloration of the lower extremities; urinary retention	Congenital bladder diverticulum; bilateral iliac vein compression	Urethral catheterization; diverticulum resection and ureteral replantation	Not reported
Miller et al. ⁵	2007	0.1	Male	Acute oedema and bluish discoloration of left leg and lower abdomen	Congenital bladder diverticulum; left iliac vein compression	Urethral catheterization; diverticulum resection and ureteral replantation	3 months
Gupta et al. ⁶	2010	70	Male	Acute oedema of the left leg; urinary retention	Bladder diverticulum; benign prostatic hyperplasia; left iliac vein compression; deep vein thrombosis	Anticoagulation; thrombectomy; thrombolysis; urethral catheterization; transurethral prostatectomy	Not reported

(continued)

Table 1. Continued.

Authors	Year	Age, years	Sex	Presentation	Diagnosis	Therapy	Follow-up
Zimmermann et al. ⁷	2015	73	Male	Progressive dyspnoea; urinary retention	Bladder diverticulum; benign prostatic hyperplasia; right iliac vein compression; deep vein thrombosis pulmonary embolism	Urethral catheterization; anticoagulation	Not reported
Current case	2022	71	Male	Acute oedema of the left leg; urinary retention	Bladder diverticulum; benign prostatic hyperplasia; left iliac vein compression	Urethral catheterization; transurethral prostatectomy; diverticulum resection	1.5 years

extremity oedema. Two elderly patients had lower extremity deep vein thrombosis and one of them had pulmonary embolism. Our patient did not have deep vein thrombosis. The two infants were diagnosed with congenital bladder diverticulum and the three elderly patients were diagnosed with bladder diverticulum secondary to chronic prostatic hyperplasia. Aetiological diagnosis was established by voiding cystourethrography in the two infants, while the three elderly patients were diagnosed by CT or colour Doppler ultrasound examination. With the exception of one elderly patient that opted for temporary catheterization because of concurrent anticoagulation treatment, all the other patients underwent radical bladder diverticulectomy with or without ureteral reconstruction. Two of the elderly patients, including the current patient, also underwent transurethral prostatectomy.

A bladder diverticulum is a hernia of the bladder epithelium that protrudes through the detrusor muscle.⁹ Generally, bladder diverticula are the result of elevated intravesical pressure associated with lower urinary tract obstructive lesions, but they can also be congenital in the absence of obvious lower urinary tract obstruction.¹⁰ Congenital bladder diverticula are more common in male infants and can manifest as urinary tract infection, vesicoureteral reflux, bladder outlet obstruction, and rarely, diverticulum stones or spontaneous perforation.^{11,12} Bladder diverticula usually abuts the ureteral orifice; alternatively, the ureteral orifice is pulled into the diverticulum.¹³ Secondary diverticula are more common in patients with chronic prostatic hyperplasia.^{14,15} Most bladder diverticula are asymptomatic, but infection, stone formation, rupture and cancer have been described as rare complications in some patients, especially in cases of narrow-necked diverticula.^{16,17}

The diagnosis of IVCS caused by bladder diverticula is difficult because it is

extremely rare and may, therefore, require a prolonged and meticulous diagnostic workup. In the present case, the urinary catheter could not be implanted initially. As a result, CT examination was performed and the enlarged bladder diverticulum compressing the left iliac vein was found. If the catheter had been successfully implanted at the first attempt, the patient's leg oedema would have been resolved. This means that the patient is likely to miss the diagnosis. Therefore, when encountering elderly patients with lower extremity oedema and symptoms of chronic urinary tract obstruction in clinical practice, it is important to inquire about the history of the lower extremity oedema. In the current case, the patient had a history of recurrent episodes of lower extremity oedema and the marked hyperpigmentation of the skin of the left calf indicated chronic leg oedema. In addition, the lower extremity oedema in the current patient was closely associated with urinary incontinence. In such cases, clinicians should be vigilant about the possibility of bladder enlargement or a bladder diverticulum compressing the iliac vessels. This is especially important because urinary catheter placement may alleviate the compression of the iliac vein caused by the diverticulum, and the diagnosis may be missed. Therefore, in patients with oedema of the lower extremities and symptoms of urinary tract obstruction, abdominal and pelvic CT examination should be performed first, and this should be followed by Doppler ultrasound examination of the lower limb veins to exclude the presence of deep vein thrombosis of the lower extremities. However, in the case of infants and pregnant women, there is a risk of radiation exposure, so Doppler ultrasound imaging and voiding cystourethrography can be performed instead.

With regard to treatment, for cases of iliofemoral vein thrombosis caused by bladder diverticulum compressing the iliac vein,

it is safe to give standard anticoagulation therapy before a urinary catheter is implanted.¹⁸ In patients with lower extremity oedema without thrombosis (as in the current case), catheter implantation can help temporarily relieve lower urinary tract obstruction until the cause is identified, and then, bladder diverticulectomy and treatments that target lower urinary tract obstruction (e.g. transurethral prostaticectomy) can provide complete relief.

In conclusion, bladder diverticulum is an extremely rare cause of iliac vein compression syndrome, and only five such cases, including this current one, have been reported to date. A literature review of these five cases and a summary of the diagnosis and treatment experience has been presented.

Author contributions

X.B.W. was involved in protocol/project development, data collection and management, data analysis and manuscript writing. X.M.C. was involved in project development and collection of images. H.F. and X.G. were involved in project development and review/editing of the manuscript. All authors have read and approved the manuscript.


Declaration of conflicting interest

The authors declare that there are no conflicts of interest.

Funding

The authors disclosed receipt of the following financial support for the research, authorship, and/or publication of this article: This work was supported by the Beijing Friendship Hospital Seed Plan Talent Project (no. YYZZ202017), the Capital Medical University School Cultivation Fund (Natural Category) (no. 1220010147) and the Capital Health Research and Development of Special Grant (no. 2020-2-1102).

ORCID iD

Hai Feng  <https://orcid.org/0000-0001-9508-0696>

References

1. Shebel ND and Whalen CC. Diagnosis and management of iliac vein compression syndrome. *J Vasc Nurs* 2005; 23: 10–17; quiz 18–19. doi: 10.1016/j.jvn.2004.12.001.
2. Ouyang L, Peng X and Chen S. Strategies for the diagnosis and treatment of the iliac vein compression syndrome. *J Interv Med* 2019; 2: 123–127. doi: 10.1016/j.jjimed.2019.09.012.
3. Palma L, Peterson MC and Ingebretsen R. Iliac vein compression syndrome from urinary bladder distension due to prostatism. *South Med J* 1995; 88: 959–960. doi: 10.1097/00007611-199509000-00014.
4. Valadez R, Maizels M and Fernbach SK. Lower extremity cyanosis: an unusual presentation of congenital paraureteral diverticula. *J Urol* 1987; 138: 364–365. doi: 10.1016/s0022-5347(17)43147-8.
5. Miller M, Baker LA, Tannin G, et al. Lower extremity venous obstruction secondary to congenital bladder diverticulum. *J Urol* 2007; 177: 1891. doi: 10.1016/j.juro.2007.01.082.
6. Gupta V, Shaik I, Abbas J, et al. Iliofemoral venous thrombosis from external compression by a vesical diverticulum. *J Vasc Surg* 2010; 52: 1671–1673. doi: 10.1016/j.jvs.2010.06.156.
7. Zimmermann O, Torzewski J, Reichenbach-Klinke E, et al. Large diverticulum of the urinary bladder: A rare cause of deep vein thrombosis with consecutive pulmonary embolism. *Can Urol Assoc J* 2015; 9: E321–E323. doi: 10.5489/cuaj.2533.
8. Gagnier JJ, Kienle G, Altman DG, et al. The CARE guidelines: consensus-based clinical case reporting guideline development. *Headache* 2013; 53: 1541–1547. doi: 10.1111/head.12246.
9. Eyraud R, Laydner H, Autorino R, et al. Robot-assisted laparoscopic bladder diverticulectomy. *Curr Urol Rep* 2013; 14: 46–51. doi: 10.1007/s11934-012-0290-9.
10. Silay MS and Koh CJ. Management of the bladder and calyceal diverticulum: options in the age of minimally invasive surgery. *Urol Clin North Am* 2015; 42: 77–87. doi: 10.1016/j.ucl.2014.09.007.
11. Celebi S, Sander S, Kuzdan O, et al. Current diagnosis and management of primary isolated bladder diverticula in children. *J Pediatr Urol* 2015; 11: 61.e1-5. doi: 10.1016/j.jpuro.2014.10.004.
12. Bhat A, Bothra R, Bhat MP, et al. Congenital bladder diverticulum presenting as bladder outlet obstruction in infants and children. *J Pediatr Urol* 2012; 8: 348–353. doi: 10.1016/j.jpuro.2011.07.001.
13. Boechat MI and Lebowitz RL. Diverticula of the bladder in children. *Pediatr Radiol* 1978; 7: 22–28. doi: 10.1007/BF00975333.
14. Garraway WM, Collins GN and Lee RJ. High prevalence of benign prostatic hypertrophy in the community. *Lancet* 1991; 338: 469–471. doi: 10.1016/0140-6736(91)90543-x.
15. Agarwal DK and Krambeck AE. Holmium laser enucleation of the prostate is an effective treatment in patients with concomitant bladder diverticula and outlet obstruction. *World J Urol* 2018; 36: 87–90. doi: 10.1007/s00345-017-2114-5.
16. Keeler LL and Sant GR. Spontaneous rupture of a bladder diverticulum. *J Urol* 1990; 143: 349–351. doi: 10.1016/s0022-5347(17)39958-5.
17. Shah B, Rodriguez R, Krasnokutsky S, et al. Tumour in a giant bladder diverticulum: a case report and review of literature. *Int Urol Nephrol* 1997; 29: 173–179. doi: 10.1007/BF02551338.
18. Kakkos SK, Gohel M, Baekgaard N, et al. Editor's Choice – European Society for Vascular Surgery (ESVS) 2021 Clinical Practice Guidelines on the Management of Venous Thrombosis. *Eur J Vasc Endovasc Surg* 2021; 61: 9–82. doi: 10.1016/j.ejvs.2020.09.023.