

[ CASE REPORT ]

## Nocturnal Hypertension in Multiple System Atrophy May Cause Posterior Reversible Encephalopathy Syndrome

Kaoru Yagita, Kazuto Tsukita, Akiyo Shinde and Toshihiko Suenaga

### Abstract:

Nocturnal hypertension (NH) is a symptom of cardiovascular dysautonomia in multiple system atrophy (MSA); however, care and medication are often insufficient. We herein report a patient with MSA who showed posterior reversible encephalopathy syndrome (PRES) caused by hypertension during sleep. He presented clinically with total blindness; T2-weighted magnetic resonance imaging showed high signal intensities in the bilateral subcortical occipital-temporal lobes. His PRES was completely reversed by blood pressure control. NH may contribute to the development of PRES. The appropriate assessment and management of hemodynamic changes in MSA, including NH, is necessary to prevent severe complications such as PRES.

**Key words:** multiple system atrophy (MSA), nocturnal hypertension (NH), posterior reversible encephalopathy syndrome (PRES)

(Intern Med 57: 3187-3191, 2018)

(DOI: 10.2169/internalmedicine.0759-18)

### Introduction

Posterior reversible encephalopathy syndrome (PRES) is clinically heterogeneous and characterized by vasogenic brain edema that can induce acute neurological symptoms. A primary cause of PRES is wide fluctuations in blood pressure (1).

Multiple system atrophy (MSA) is a rare neurodegenerative disorder characterized by progressive autonomic failure and extrapyramidal and cerebellar features in various combinations. Variable autonomic failure is observed in MSA patients and is associated with a poor prognosis (2). Cardiovascular autonomic failures, such as orthostatic hypotension, supine hypertension, and nocturnal hypertension (NH), may cause marked fluctuations in blood pressure. However, only two studies have reported MSA cases with cardiovascular autonomic failures leading to PRES (3, 4).

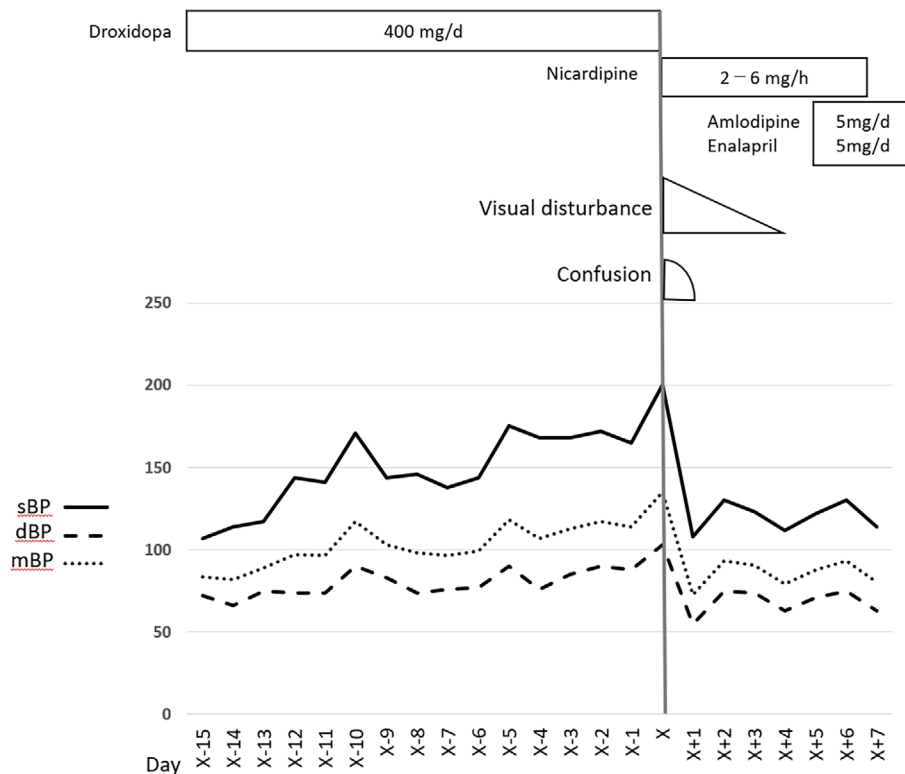
We herein report a case of MSA in which the patient developed PRES during sleep. He was later determined to have NH which may have caused his PRES. This is the first case in which an MSA patient developed PRES during sleep. This suggests that cardiovascular autonomic failure and NH in MSA can cause severe complications, such as

PRES.

### Case Report

A 63-year-old man with a 3-year history of MSA had total blindness upon waking. Approximately three years earlier, he had developed parkinsonism with bradykinesia and rigidity. His parkinsonism gradually became resistant to levodopa, and he developed cerebellar ataxia and autonomic failure, which manifested as conditions such as constipation and urinary retention. <sup>123</sup>I-metaiodobenzylguanidine (MIBG) scintigraphy showed early and delayed heart-to-mediastinum (H/M) ratios of 2.04 and 1.79, respectively. The washout rate was 56.8%. Brain magnetic resonance imaging (MRI) showed cruciform hyperintensity in the pons and high-intensity bilateral lesions at the middle cerebellar peduncles on T2-weighted sequencing. He was diagnosed with a probable parkinsonian variant of MSA (5).

Thirty-two months after developing parkinsonism, he experienced frequent episodes of postural syncope and was eventually bedridden despite taking droxidopa after breakfast. The initial dosage was 200 mg/day, with an increase to 400 mg/day 1 month later. He also became more susceptible to infections and developed aspiration pneumonia and a uri-



**Figure 1.** Time course showing gradual progression of supine hypertension and favorable response to nicardipine, amlodipine, and enalapril. X: day of onset, sBP: systolic blood pressure, dBP: diastolic blood pressure, mBP: mean blood pressure

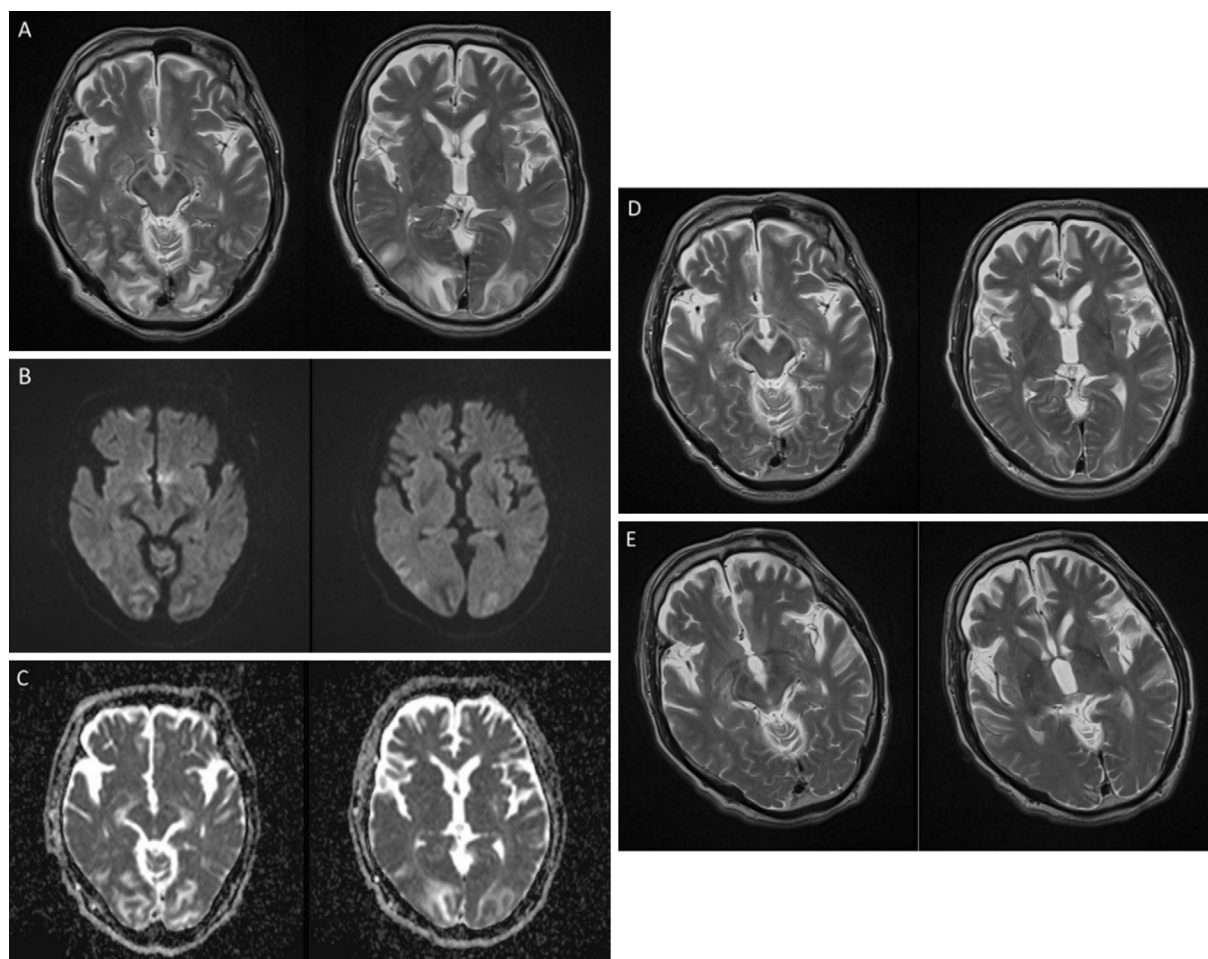
nary tract infection. Four days prior to the onset of total blindness, he developed aspiration pneumonia and began taking sulbactam/ampicillin. He remained primarily in a supine position, and his blood pressure increased without pain. His supine blood pressure was 130/60 mmHg 2 weeks before the onset of total blindness and increased to 170/80 mmHg a few days before the onset (Fig. 1). He awoke with total blindness despite having intact visual acuity the previous day.

The patient's medical history included gastrectomy for cancer and endoscopic submucosal dissection for esophageal cancer. His medications included taltirelin hydrate, droxidopa, and laxatives. He had not taken anticancer or immunosuppressant drugs. On an examination, he was confused and disoriented. His supine blood pressure was 200/103 mmHg, his pulse was 81 bpm and regular, and his temperature was 37.6°C. On a neurological examination, he had no light perception but did have a brisk bilateral light reflex. No other findings were remarkable compared with those on recent previous examinations. He exhibited right-dominant rigidity and a grade of 4 on the Medical Research Council scale in all muscle groups without paralysis. The levels of hemoglobin, platelets, serum protein, albumin, creatinine, and liver enzymes were all within the normal ranges, but his white blood cell count and C-reactive protein level were elevated, indicating an inflammatory response to aspiration pneumonia. These data were unchanged from two days earlier. T2-weighted brain MRI showed a high signal intensity

in the bilateral cortical and subcortical occipital-temporal-parietal lobes. MR angiography did not show clear evidence of cerebral vasoconstriction. Fig. 2A-C shows a lesion with a high signal intensity on diffusion-weighted images and an apparent diffusion coefficient map.

The patient was diagnosed with PRES, and hypertension was considered the most probable cause. Droxidopa was discontinued, and nicardipine was continuously administered for one week. His visual acuity improved markedly. He was able to count fingers two days after onset, and his visual acuity returned to normal five days after onset. Six days after he developed PRES, he was administered amlodipine at 5 mg/day and enalapril at 5 mg/day. His supine blood pressure was controlled between 100/65 and 140/80 mmHg (Fig. 1). Brain MRI showed marked improvement 15 days after the onset, but the change was completely unremarkable 92 days after the onset (Fig. 2D and E).

A head-up tilt test conducted 23 days after the onset revealed severe orthostatic hypotension with a blood pressure of 142/78 mmHg in the supine position and 96/60 mmHg 5 min after the head-up test, with a heart rate increase from 70 bpm to 86 bpm and a noradrenalin value within the normal range. The 24-h ambulatory blood pressure monitoring (24-h ABPM) score 30 days after the onset revealed NH (Fig. 3). The 24-h ABPM score indicated reverse dipping NH; the daytime mean blood pressure was 108/68 mmHg, and the nighttime mean was 116/71 mmHg (6). The patient also exhibited postprandial hypotension, and his blood pres-



**Figure 2.** Brain magnetic resonance imaging (MRI) on the day of onset of posterior reversible encephalopathy syndrome. (A) T2-weighted image showing hyperintensity in the cortical and subcortical bilateral occipital-temporal lobes. (B), (C) Diffusion-weighted image and apparent diffusion coefficient map demonstrating vasogenic edema. (D) T2-weighted brain MRI after 15 days, showing remarkable reduction in high signal intensity, and (E) MRI after 92 days, showing complete resolution of abnormalities.

sure fluctuated widely because of postural changes during rehabilitation.

The patient discontinued taking droxidopa and spent lots of time in the head-up position throughout the day and night after the development of PRES, which was effective for his supine hypertension. In addition, we tried to change his posture and administer meals more slowly to prevent blood pressure fluctuation. These nonpharmacological interventions were effective, and his syncope was not seen despite the discontinuation of droxidopa.

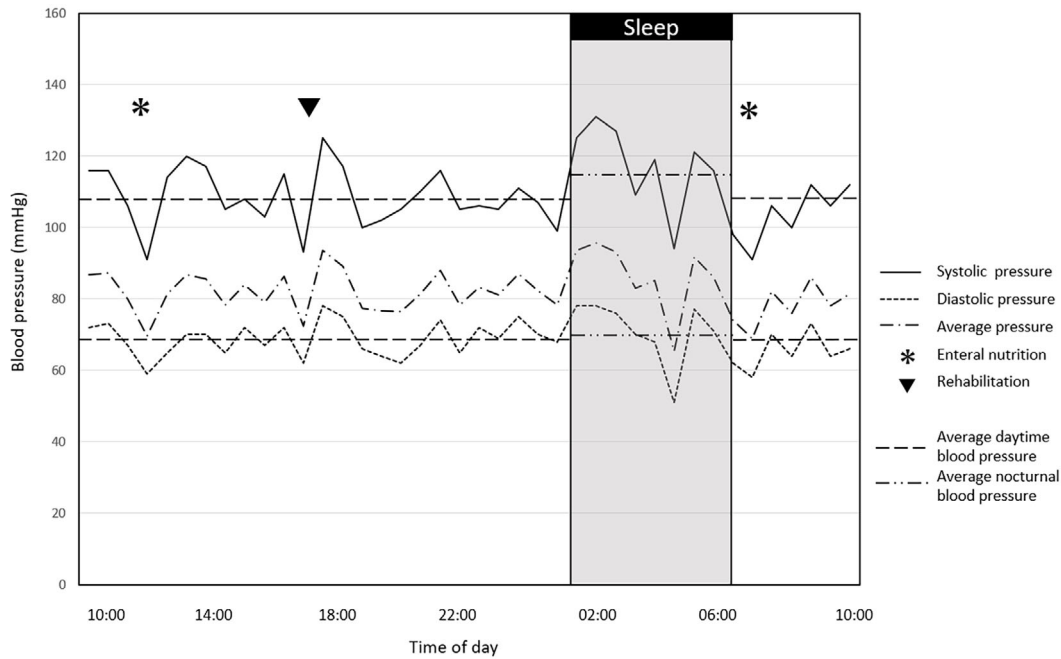
## Discussion

PRES is a clinically heterogeneous neurological syndrome that occurs in many settings, including hypertensive crisis, renal failure, and preeclampsia, among others. These clinical settings induce failure in the autoregulation of cerebral blood flow and endothelial dysfunction, resulting in subcortical vasogenic brain edema (1).

The most frequent symptom of cardiovascular autonomic

failure in MSA is orthostatic hypotension; a large registry of the European MSA Study Group showed a prevalence of 75% among MSA patients (7). In addition, almost half of all cases develop comorbid supine hypertension, and the loss of physiological circadian blood pressure rhythm induces NH, which was observed in 50% of MSA patients in a previous study (6).

Cardiovascular autonomic failure in MSA can induce severe blood pressure fluctuation. However, only two studies have reported the development of PRES in MSA patients. One report described a 51-year-old man with a 3-year history of MSA who presented with confusion, headache, dysarthria, and generalized tonic-clonic seizures caused by PRES (3). The patient had supine hypertension with a blood pressure of 180/100 mmHg at the onset, and the researchers considered the cause to be the oral administration of midodrine for 3 months. The other report described a 51-year-old man with a 7-year history of MSA who presented with visual disturbance, confusion, and generalized tonic-clonic seizures (4). He developed PRES two hours after brief syn-



**Figure 3.** Scores for 24-hour ambulatory blood pressure monitoring over the 30-day disease course, showing higher blood pressure during the night than during the daytime (i.e., reverse dipping nocturnal hypertension). Blood pressure widely fluctuated with external stimulation, such as enteral nutrition and changes in position.

cope. His blood pressure increased to 205/115 mmHg from 88/60 mmHg for 80 min. The authors considered the cause of PRES to be severe blood pressure fluctuation.

This is the first case in which an MSA patient developed PRES during sleep, suggesting that NH influenced its pathogenesis. The two previous cases of MSA with PRES were able to walk, and their posture changes affected their blood pressure fluctuation. In our case, the individual was almost completely bedridden, suggesting that NH might be a primary reason for the severe fluctuation of his blood pressure that caused PRES.

NH may be non-dipping or reverse dipping. The non-dipping form is characterized by a decrease in the blood pressure of less than 10% during the night compared to the previous day, whereas the reverse dipping form is characterized by an increase in the blood pressure during the night (8). The 24-h ABPM score showed that he had reverse dipping NH in a severe form. NH was also considered a cause of PRES in previous reports (9, 10).

The 24-h ABPM score also showed that our patient's blood pressure fluctuated widely with external stimulation, such as enteral nutrition and body movement, despite appropriate medical care. His supine blood pressure increased to approximately 170/80 mmHg gradually before he developed PRES and exceeded 200/100 mmHg at onset. His blood pressure may have been higher during sleep and fluctuated more on the day he developed PRES than on the day of 24-h ABPM. In more advanced MSA cases, pathological nocturnal blood pressure appears more frequently and is associated with a pronounced blood pressure decrease after head-up tilting (6). Therefore, we considered progressive cardio-

vascular dysautonomia with NH as the most likely contributor to PRES in this case.

There was also one case report suggesting that NH in Parkinson's disease (PD) might be associated with the development of PRES (11). That report described a 77-year-old man with a 10-year history of PD who had supine hypertension, orthostatic hypotension, and NH, just as in our case. The authors inferred that these cardiac dysautonomias contributed to the pathogenesis. Compared with that case, the present patient developed PRES only three years after the onset of MSA, and the supine hypertension of our case progressed a few weeks before the development of PRES. Autonomic failures in MSA are generally more profound and progress more quickly than those in PD, so the course in our case indicates that early appropriate management is very important in MSA patients.

Furthermore, MIBG scintigraphy in that previous PD case showed a markedly reduced uptake and high washout ratio, while our case showed mild abnormal values. Autonomic failure in PD originates from postganglionic sympathetic dysfunction, while that in MSA originates from the central nervous system, and the postganglionic sympathetic fibers are intact (12). The present case developed severe autonomic dysfunction despite mild abnormal results of MIBG scintigraphy. The MIBG uptake of PD may correlate with the cardiovascular autonomic function, but the MIBG uptake of MSA does not correlate with cardiac dysautonomia (13-15).

In the present case, the progression of clinical events accompanied by rapid improvement in radiological abnormalities strongly suggested that PRES was caused by hypertension and severe blood pressure fluctuation. The mechanisms

underlying the development of PRES were complex. Our patient had pneumonia at the time, and the presence of inflammatory cytokines may have injured the cerebral endothelial cells, leading to the development of PRES (1). The continuous intake of droxidopa might also have affected his blood pressure fluctuation. However, the use of droxidopa started four months prior to PRES development, and our patient took droxidopa after his morning meals, so it was not a new risk factor of his pathogenesis, including NH.

Many MSA patients with severe autonomic dysfunction take vasopressors, such as droxidopa, midodrine, and fludrocortisone. These pharmacologic therapies frequently induce supine hypertension as a side effect, and appropriate monitoring is needed. If supine hypertension is detected, patients should increase the duration of sitting upright during the daytime and should sleep in the head-up tilt position to avoid exacerbation of their NH (16). The course of the present case indicates that appropriate blood pressure management, including nonpharmacological intervention, is important for MSA patients in order to prevent severe complications such as PRES.

In conclusion, the hemodynamics of MSA change dramatically during the course of the disease, and our case suggests that NH may result in PRES. Although a causal relationship cannot be confirmed, infection and vasopressor use may have been exacerbating factors. Further studies are needed in order to determine how NH influences MSA progression, as well as to define appropriate care.

**The authors state that they have no Conflict of Interest (COI).**

## References

1. Fugate JE, Rabinstein AA. Posterior reversible encephalopathy syndrome: clinical and radiological manifestations, pathophysiology, and outstanding questions. *Lancet Neurol* **14**: 914-925, 2015.
2. Coon EA, Sletten DM, Suarez MD, et al. Clinical features and autonomic testing predict survival in multiple system atrophy. *Brain* **138**: 3623-3631, 2015.
3. Kim J-S, Lee K-S, Lim S-C, et al. Reversible posterior leukoencephalopathy syndrome in a patient with multiple system atrophy: a possible association with oral midodrine treatment. *Mov Disord* **22**: 1043-1046, 2007.
4. Franken TP, Demaerel P, Vandenberghe W. Posterior reversible encephalopathy syndrome in multiple system atrophy. *Parkinsonism Relat Disord* **28**: 155-156, 2016.
5. Gilman S, Wenning GK, Low PA, et al. Second consensus statement on the diagnosis of multiple system atrophy. *Neurology* **71**: 670-676, 2008.
6. Fanciulli A, Strano S, Ndayisaba JP, et al. Detecting nocturnal hypertension in Parkinson's disease and multiple system atrophy: proposal of a decision-support algorithm. *J Neurol* **261**: 1291-1299, 2014.
7. Köllensperger M, Geser F, Ndayisaba J-P, et al. Presentation, diagnosis, and management of multiple system atrophy in Europe: final analysis of the European multiple system atrophy registry. *Mov Disord* **25**: 2604-2612, 2010.
8. Staessen JA, Asmar R, De Buyzere M, et al. Task Force II: blood pressure measurement and cardiovascular outcome. *Blood Press Monit* **6**: 355-370, 2001.
9. Casetta I, Cesnik E, Pedelini F. Posterior reversible encephalopathy associated with nocturnal blood pressure non-dipping pattern. *Blood Press* **23**: 61-63, 2014.
10. Kaut O, Kovacs A, Okulla T, et al. Reversible multifocal leukoencephalopathy associated with a nocturnal blood pressure non-dipper pattern. *Blood Press* **19**: 267-269, 2010.
11. Morozumi S, Kato S, Yasui K, et al. Posterior reversible encephalopathy syndrome in Parkinson disease probably caused by prominent supine hypertension and blood pressure fluctuation. *Rinsho Shinkeigaku (Clinical Neurology)* **56**: 754-758, 2016 (in Japanese, Abstract in English).
12. Orimo S, Takahashi A, Uchihara T, et al. Degeneration of cardiac sympathetic nerve begins in the early disease process of Parkinson's disease. *Brain Pathol* **17**: 24-30, 2007.
13. Katagiri A, Asahina M, Araki N, et al. Myocardial <sup>123</sup>I-MIBG uptake and cardiovascular autonomic function in Parkinson's disease. *Parkinsons Dis* **2015**: 1-5, 2015.
14. Berganzo K, Tijero B, Somme JH, et al. SCOPA-AUT scale in different parkinsonisms and its correlation with (123) I-MIBG cardiac scintigraphy. *Parkinsonism Relat Disord* **18**: 45-48, 2012.
15. Braune S, Reinhardt M, Schnitzer R, et al. Cardiac uptake of [123I]MIBG separates Parkinson's disease from multiple system atrophy. *Neurology* **53**: 1020-1025, 1999.
16. Fanciulli A, Wenning GK. Multiple-system atrophy. *N Engl J Med* **372**: 249-263, 2015.

The Internal Medicine is an Open Access journal distributed under the Creative Commons Attribution-NonCommercial-NoDerivatives 4.0 International License. To view the details of this license, please visit (<https://creativecommons.org/licenses/by-nc-nd/4.0/>).