

The maxillofacial injuries: A study

Departments of Oral and Maxillofacial Surgery, ¹Anaesthesia, K.G. Medical University, Lucknow, India

Vibha Singh, Laxman Malkunje, Shadab Mohammad, Nimisha Singh, Satish Dhasmana¹, Sanjib Kumar Das

ABSTRACT

Objectives: The aim of this study was to evaluate the incidence and etiology of maxillofacial fractures and also to evaluate different treatment modalities. **Study design:** The sample consisted of 1,038 patients, with maxillofacial injuries treated at our center from June 2006 to June 2011. Cause, type, site of injury, gender, age and treatment given to them, all these parameter are evaluated. **Conclusion:** The results of this study exhibit that road traffic accidents is the main reason for maxilla facial injuries followed by fall from height. Maxillofacial injuries are more frequent in male than in female. The mandible was most frequently involved facial bone. The miniplate osteosynthesis was the most widespread of the fixation technique but conservative management of the fractured bone also has a significance importance in treatment modalities.

Address for correspondence:

Dr. Vibha Singh,
A-43, Krishna Nagar,
Lucknow, India.
E-mail: drvibha66@yahoo.com

Key words: Close reduction, maxillofacial injuries, road traffic accidents

INTRODUCTION

Hippocrates described an array of facial injuries as long ago as 400 BC. The injuries to the facial regions are clinically highly significant for number of reasons. Facial region provides anterior protection for the cranium and plays significant role in appearance. Maxillofacial region is associated with a number of important functions of the daily life sight, smell, eating, breathing, and talking. These functions are severely affected and ultimately result in poor quality of life.

Facial injuries occur in significant proportion in trauma patients requiring prompt diagnosis and management. Maxillofacial injuries are common both in war and peace. The number of maxillofacial injuries is continuously increasing due to rise in traffic, and failure to take preventive measures in the traffic leads to road traffic accidents, which is the main etiological factor in maxillofacial fractures.

The aim of this study was to find out the incidence and pattern of maxillofacial injuries resulting from various etiological factors and treatment modalities and their complications. The maxillofacial injuries remain serious clinical problems because of its anatomical significance, i.e., important organs are located in this area and digestive and respiratory systems start from this area. Due to anatomical proximity together with maxillofacial injuries, the damage to the central nervous system may occur and injuries in this region can result in serious dysfunction. This descriptive analytical study assesses the etiology, type, demographic, and treatment data of maxillofacial fractures managed at our center in the last 5 years.

MATERIALS AND METHODS

The sample consisted of 1,038 patients, with maxillofacial injuries treated at our center from June 2006 to June 2011. Around 350 patients who were not admitted in the department and were treated as the outdoor patients were not included in this study, as it was not possible to obtain their complete data. Most of them were treated by conservative management. They were put on the intermaxillary fixation. The diagnosis was made on the basis of history, clinical examinations, and other investigations. Radiographs, orthopantomogram, occipitomental view, submentovertex view, postero-

Access this article online	
Quick Response Code: 	Website: www.njms.in
	DOI: 10.4103/0975-5950.111372

anterior (P.A.) view mandible, lateral oblique view mandible, were the main tools to confirm clinical diagnosis. CT scans, 3D CT, and dentaScan were used according to indications.

The parameters assessed included age, sex, etiology, fractured bones, and treatment modalities and complications. The treatment modalities were close reduction, open reduction, and fixation. Different approaches for reduction and fixation of fractures were used according to indications either intra-oral approach or extra-oral approach.

RESULTS

The most common site of fracture maxilla was found to be leforte 2 fracture. In our study, gender distribution was 9:1 [Table 1], but in other studies, it was 2:1. Males are more prone for trauma because of outdoor works, rash driving, and alcoholism.^[1-3] The most common involved age group was 21-30 (37.66%) years [Table 2], followed by 31-40 years (19.36%).^[4-6] The road traffic accident (97.10%) was the most common etiological factor [Table 3].

The commonest fractured bone is mandible (47.87%). Most of the patients had multiple bone fractures including mandible, maxilla, and zygomatic complex fracture (62.42%) [Table 4]. Adeyemo stated that road traffic crashes remain the major cause of maxillofacial injuries, unlike in most developed countries where assaults/interpersonal violence has replaced road traffic crashes as the major cause of the injuries.^[6]

The most commonly involved site was body of the mandible (51.50%) followed by parasymphysis (45.25%). Coronoid fracture was reported^[6-8] to be least common (1.08%) [Table 5]. Among maxillary fractures, the most common fracture was leforte 2 fracture (84.00%) followed by leforte 1 and then leforte 3 [Table 6]. Motamedi^[7] also reported leforte 2 was the commonest fracture in his study.

In the study of Motamedi *et al.*,^[7] they found there were (72.9%) mandibular, (13.9%) maxillary, (13.5%) zygomatic, (24.0%) zygomatico-orbital, (2.1%) cranial, (2.1%) nasal, and (1.6%) frontal injuries. Car accidents (30.8%), motorcycle accidents (23.2%), altercations (9.7%), sports (6.3%), and warfare (9.7%) caused the maxillofacial injuries. Regarding distribution of mandibular fractures, 32% were seen in the condylar region, 29.3% in the symphyseal–parasymphyseal regions, 20% in the angle region, 12.5% in the body, 3.1% in the ramus, 1.9% in the dentoalveolar, and 1.2% in the coronoid region. The distribution of maxillary fractures

Table 1: Gender (N = 1,038)

Gender	Number of patients	Percentage
Male	931	89.69
Female	107	10.30

In our study, gender distribution was 89.69:10.30 around 9:1

Table 2: Age group (N = 1,038)

Age group	Number of patients	Percentage
0-10	69	6.64
11-20	152	14.64
21-30	391	37.66
31-40	201	19.36
41-50	127	12.23
51-60	76	7.32
61-70	14	1.34
71-80	8	0.07
81-90	0	0

The most common involved age group was 21-30 (37.66%) years, followed by 31-40 years (19.36%)

Table 3: Etiology

Factors	Number of patients	Percentage
RTA	1,008	97.10
Fall from height	22	2.11
Assault	4	0.38
Fire arm injury	2	0.11
Animal bite	2	0.11

RTA: Road traffic accident

Table 4: Fracture involving different bones (N = 1,038)

Bones	Number of patients	Percentage
Mandible only	497	47.88
Mandible + maxilla + zygoma	648	62.42
Maxilla	275	26.49
Zygomatic complex	225	21.67
NOE	10	0.96
Orbital floor	5	0.48

The commonest fractured bone is mandible (47.87%). Most of the patients had multiple bone fractures including mandible, maxilla, and zygomatic complex fracture (62.42%), NOE: Naso orbito ethmoid

Table 5: Mandible fracture sites

Fracture site	Number of patients	Percentage
Parasymphysis	225	45.27
Symphysis	21	4.22
Body	256	51.50
Angle	134	26.96
Condyle, subcondyle	135	27.16
Coronoid	5	1.08
Ramus	8	1.60
Edentulous mandible	3	0.60

Regarding distribution of mandible fractures, the most commonly involved site was body of the mandible (51.50%) followed by parasymphysis (45.25%) and the coronoid fracture was least common (1.08%)

Table 6: Maxilla fractures

Site	Number of patients	Percentage
Leforte 1	23	8.36
Leforte 2	231	84.00
Leforte 3	17	6.18

Regarding treatment modalities, most of the patients were treated by open reduction and fixation, (72.83%) and conservative management (22.73%), and 2.50% patients were treated by circum-mandibular wiring

was Le Fort II (54.6%), Le Fort I (24.2%), Le Fort III (12.1%), and alveolar (9.1%). Of the all mandibular fractures, 56.9% were treated by closed reduction, 39.8% by open reduction, and 3.5% by observation only. Of all maxillary fractures, 54.6% were treated using closed reduction, 40.9% using open reduction, and 4.5% with observation only. Approximately, 52.1% of the patients were treated under general anesthesia and 47.9% were treated under local anesthesia and sedation.

Regarding treatment modalities we used, most of the patients were treated by open reduction and fixation (72.83%) and conservative management (22.73%), and 2.50% patients were treated by circum-mandibular wiring mostly in pediatric patients and edentulous patients [Table 7].

According to Ajmal, *et al.*,^[8] open reduction and internal fixation has proven to be the most effective method for treatment of mandibular fractures. In most of the patients, Open reduction & internal fixation (ORIF) was done under general anesthesia, rest of them under local anesthesia and conscious sedation. All the patients of circum-mandibular wiring were treated under General anaesthesia (GA). The close reduction was done under local anesthesia.

According to study of Back, *et al.*,^[1] most patients were males (76%), the average age was 38 years, and drugs or alcohol were a significant aspect of the history in 30% of the cases. The most common mechanism of injury was assault (47%), followed by falls and sporting injuries. Fifty percent of the fractures involved the orbital or orbito-zygomatic complex, and 55% had associated injuries. Average follow-up was for 6 weeks (range: 0-44 weeks). Most patients were managed conservatively based on our current criteria of un-displaced/minimally displaced fracture (57%) or minimal/no symptoms (24%). At final review, a number had residual symptoms, but only three required corrective surgery. The other reasons for conservative management included patient non-compliance (11%) and medical contraindications (8%).

Being a developing country, the socioeconomic status of the majority is low and the patients coming to our center are from remote areas of the state and from neighboring states with the poor background, so choice of plating systems are limited.

Different systems of plating were used according to indications and affordability. Miniplates (stainless steel or titanium), 3D plates, locking plates, reconstruction plates, lag screws, and biodegradable systems were used. Reconstruction of orbital floor was done with autogenous bone graft and in few cases with medpore. In most of the patients, stainless steel plates were

used [Figures 1-9].

In patients with only mandibular fractures (497), 21% patients were treated with intermaxillary fixation and 84.78% with open reduction and fixation with different systems [Table 8].

Danda, *et al.*^[9] concluded from their study that the results of this study have shown that no significant clinical difference exists between patients undergoing closed treatment and rigid maxillomandibular fixation or open reduction and internal fixation. However, a radiographically better anatomic reduction of the condylar process was seen in the patients treated with open reduction and internal fixation.

Out of patients who received ORIF (64.78%), in 25.19% cases plates were removed within 6 months to 2 years because of secondary infection, sinus formation, or pus discharge from the site. There was no single case of delayed union or non-union reported [Tables 6 and 9].

DISCUSSION

World Health Organization has estimated that nearly 25% of all injuries fatalities worldwide are a result of road traffic crashes with 90% of the fatalities occurring in low- and middle-income countries.^[10]

Road traffic accidents have been steadily falling in the developed countries; they continue to rise with the horrifying speed in the low- and middle-income countries of Africa and Asia. It is the major cause of death in India. The majority of the accidents results due

Table 7: Treatment modalities

Treatment modalities	Number of patients	Percentage
Conservative	236	22.73
Open reduction and fixation	756	72.83
Circum-mandibular wiring	26	2.50

Table 8: Treatment modalities used for mandible fractures (N= 497)

Treatment modalities	Number of patients	Percentage
Conservative IMF	175	35.21
Open reduction and fixation	322	64.78

The 35.21% of patients were treated with intermaxillary fixation and 64.78% with open reduction and fixation, IMF: inter maxillary fixation

Table 9: Need of second surgery for removal of plates in 1,038 patients

Number of patients/sites	Number of patients	Percentage
1,038	295	28.42
Mandible	269	91.18
Mid-face	26	8.81

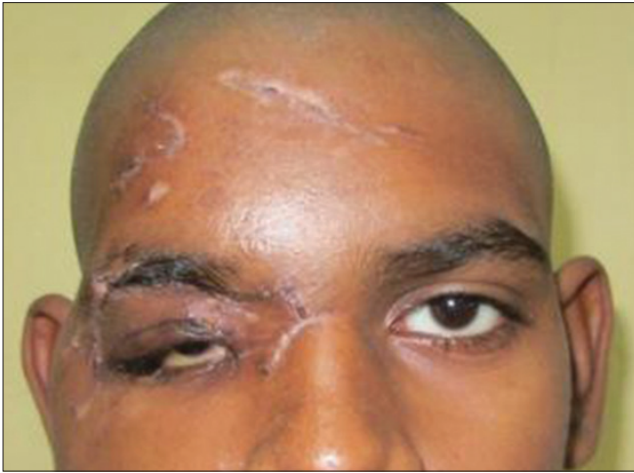

Figure 1: Pre-operative photograph of patient

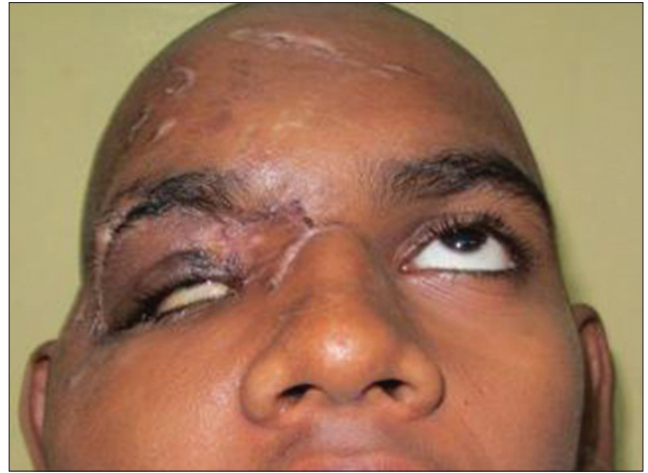

Figure 2: Pre-operative photograph of patient

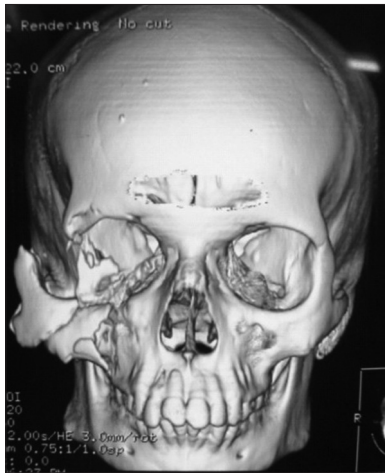


Figure 3: Pre-operative CT scan

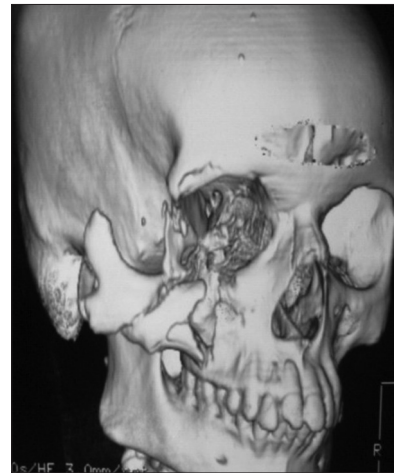

Figure 4: Pre-operative CT scan

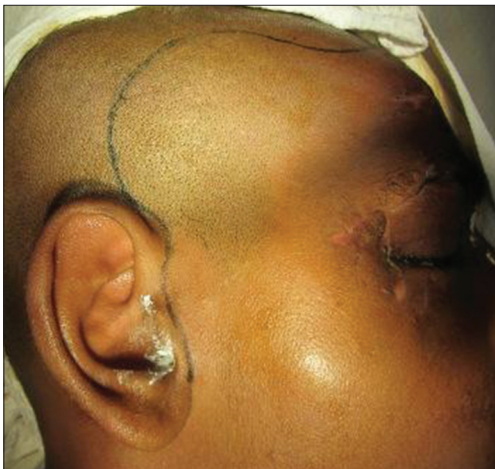

Figure 5: Intra-operative photograph of patient

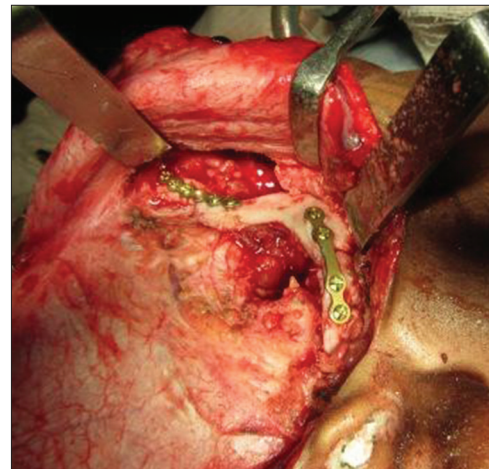


Figure 6: Intra-operative photograph of patient

to speeding and legislation. Alcoholism is associated with road traffic accidents internationally. Fatigue is another important factor especially in commercial vehicle drivers who drives very long distances. Bad road conditions also play an important role in RTA but

some studies reported more RTAs on well paved and broad roads.^[4]

The reason for the accidents in our country is due to violation of traffic rules, whereas in developed

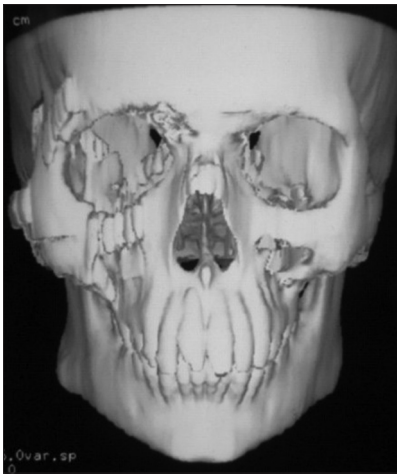

Figure 7: Post-operative CT scan

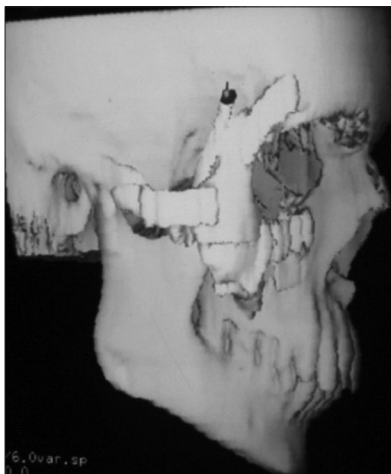

Figure 8: Post-operative CT scan

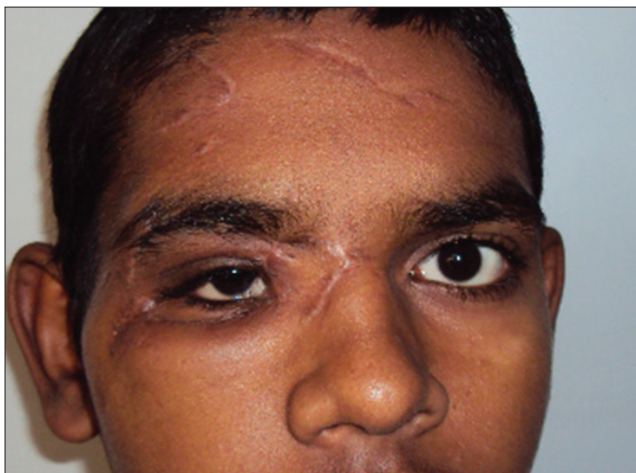

Figure 9: Post-operative photograph of patient

countries, accidents are most commonly due to alcoholic intoxications.

This study shows that the most common cause of facial

injuries was road traffic accidents, which is consistent with observation in other studies in India and other countries.^[8,3-5,11] Mandible fracture was the most common fracture observed in this study because it is the most prominent bone in the face and is often fractured more than strongly supported middle third of face.

Fractures have been treated by a series of methods including close reductions, internal fixation, and circum-mandibular wiring. Coletti^[10] stated that the IMF self-drilling/tapping screws has been shown to be a useful modality to establish maxillomandibular fixation. It is a safe and time-sparing technique; however, it is not without limitations or potential consequences which the surgeon must be aware of in order to provide safe and effective treatment.

Pediatric patients were treated by circum-mandibular wiring and few cases with bioresorbable plates under general anesthesia. Pediatric patients benefit from the advantage of bioresorbable plates as it results in faster mobilization and the avoidance of secondary surgery for removal of implants.^[12]

The old age successful management of these injuries using close reduction technique should be considered.^[13,9] Patients with edentulous atrophic mandible were all so treated with circum-mandibular wiring and results were satisfactory.

The minimally displaced fractures can be treated with conservative methods like close reduction to avoid hospitalization, cost factor, and significantly low risk of infections.

In our study, there was no infection, non-union, mal union, or any functional disability reported in the patients who received inter maxillary fixation for 4-6 weeks. Mouth opening was normal in all patients. Temporomandibular joint stiffness was reported during first week of after releasing IMF which comes normal after a week with physiotherapy.

However despite the professional and commercial interest in open reduction and semi-rigid fixation, we should think about patient's interest affordability and well-being. Conservative management should not be overlooked when indicated. Sometimes, patients' general condition, neurosurgical conditions, spinal injuries, medically compromised patients should be treated with conservative treatment. It is very cost effective, reduces hospital stay, or even no need for hospitalization.

Only dietary restrictions due to mouth closure and patient compliance are limitations. In few patients like epileptic, we cannot use inter maxillary fixation for

the management of maxillofacial trauma in minimally displaced fractures.

Other studies also did not show a clear overall benefits of the open reduction and fixation over conventional Maxillo mandibular fixation (MMF) treatment.^[6,14,15] Marker, *et al.*^[14] found non-surgical treatment of fracture of condyle is non-traumatic, safe, and predictable and also support the conservative management of mandibular fractures. The fractures with little displacement can be treated with close reduction. The cases with extensive displacement, associated fractures of mid-face, open reduction and fixation are indicated.^[1,15-17]

According to Worsaae and Thorn^[18] in the study of open versus closed reduction of unilaterally dislocated low subcondylar fractures, they concluded that complications such as malocclusion, mandibular asymmetry, impaired masticatory function, and pain located to the affected joint or masticatory muscles were seen significantly more frequent in patients treated with closed reduction compared with those treated surgically ($P = 0.005$). Neither the degree of dislocation of the proximal fragment, concomitant mandibular fractures nor the absence of posterior occlusal support seemed to influence the results.

CONCLUSIONS

The results of this study exhibit that road traffic accidents is the main reason for maxilla facial injuries followed by fall from height. Maxillofacial injuries are more frequent in male than in female. The mandible was most frequently involved facial bone. The miniplate osteosynthesis was the most widespread of the fixation technique but conservative management of the fractured bone also has a significance importance in treatment modalities.

REFERENCES

1. Back CP, McLean NR, Anderson PJ, David DJ. The conservative management of facial fractures: Indications and outcomes. *J Plast Reconstr Aesthet Surg* 2007;60:146-51.
2. Gassner R, Tuli T, Hächl O, Rudisch A, Ulmer H. Cranio-maxillofacial trauma: A 10 year review of 9,543 cases with 21,067 injuries.

3. J Craniomaxillofac Surg 2003;31:51-61.
3. Gupta R, Suryanarayan S, Sharma A, Pandya V, Sathaye S. Traumatic mandibular fractures: Pendulum towards closed reduction. *The World Articles in Ear, Nose and Throat* 2010;3:1-3.
4. Al Ahmed HE, Jaber MA, Abu Fanas SH, Karas M. The pattern of maxillofacial fractures in Sharjah, United Arab Emirates: A review of 230 cases. *Oral Surg Oral Med Oral Pathol Oral Radiol Endod* 2004;98:166-70.
5. Malara P, Malara B, Drugacz J. Characteristics of maxillofacial injuries resulting from road traffic accidents—A 5 year review of the case records from Department of Maxillofacial Surgery in Katowice, Poland. *Head Face Med* 2006;2:27.
6. Adeyemo WL, Ladeinde AL, Ogunlewe MO, James O. Trends and characteristics of oral and maxillofacial injuries in Nigeria: A review of the literature. *Head Face Med* 2005;1:7.
7. Motamedi MH. An assessment of maxillofacial fractures: A 5-year study of 237 patients. *J Oral Maxillofac Surg* 2003;61:61-4.
8. Ajmal S, Khan MA, Jadoon H, Malik SA. Management protocol of mandibular fractures at Pakistan Institute of Medical Sciences, Islamabad, Pakistan. *J Ayub Med Coll Abbottabad* 2007;19:51-5.
9. Danda AK, Muthusekhar MR, Narayanan V, Baig MF, Siddareddi A. Open versus closed treatment of unilateral subcondylar and condylar neck fractures: A prospective, randomized clinical study. *J Oral Maxillofac Surg* 2010;68:1238-41.
10. Adeyemo WL, Ladeinde AL, Ogunlewe MO, James O. Trends and characteristics of oral and maxillofacial injuries in Nigeria: A review of the literature. *Head Face Med* 2005;1:7.
11. El-Degwi A, Mathog RH. Mandible fractures—Medical and economic considerations. *Otolaryngol Head Neck Surg* 1993;108:213-9.
12. Lawoyin DO, Lawoyin JO, Lawoyin TO. Fractures of the facial skeleton in Tabuk North West Armed Forces Hospital: A five year review. *Afr J Med Med Sci* 1996;25:385-7.
13. Blitz M, Notarnicola K. Closed reduction of the mandibular fracture. *Atlas Oral Maxillofac Surg Clin North Am* 2009;17:1-13.
14. Marker P, Nielsen A, Bastian HL. Fractures of the mandibular condyle. Part 2: Results of treatment of 348 patients. *Br J Oral Maxillofac Surg* 2000;38:422-6.
15. Abreu ME, Viegas VN, Ibrahim D, Valiati R, Heitz C, Pagnoncelli RM, *et al.* Treatment of comminuted mandibular fractures: A critical review. *Med Oral Patol Oral Cir Bucal* 2009;14:E247-51.
16. Fordyce AM, Lalani Z, Songra AK, Hildreth AJ, Carton AT, Hawkesford JE. Intermaxillary fixation is not usually necessary to reduce mandibular fractures. *Br J Oral Maxillofac Surg* 1999;37:52-7.
17. Peter W, Stephen A, Schendel, Jag-Erich H. *Maxillo Facial Surgery*. Vol. 1, 2nd ed. Churchill Living Stone Elsevier Ltd.; 2007.
18. Worsaae N, Thorn JJ. Surgical versus nonsurgical treatment of unilateral dislocated low subcondylar fractures: A clinical study of 52 cases. *J Oral Maxillofac Surg* 1994;52:353-60.

How to cite this article: Singh V, Malkunje L, Mohammad S, Singh N, Dhasmana S, Das SK. The maxillofacial injuries: A study. *Natl J Maxillofac Surg* 2012;3:166-71.

Source of Support: Nil. **Conflict of Interest:** None declared.