

[CASE REPORT]

Successful Treatment of Intestinal Mycosis Caused by a Simultaneous Infection with *Lichtheimia ramosa* and *Aspergillus calidoustus*

Yukihiro Kaneko^{1,2}, Ken-Ichi Oinuma^{1,2}, Tsuneko Terachi³, Yasuaki Arimura⁴, Mamiko Niki^{1,2}, Koichi Yamada^{2,5}, Hiroshi Kakeya^{2,5} and Tetsu Mizutani³

Abstract:

A 53-year-old woman was hospitalized due to septic shock after developing pneumococcal pneumonia after undergoing esophageal cancer surgery. Her transverse colon became perforated after receiving antimicrobial chemotherapy; therefore, emergency subtotal colectomy was performed. Fungi detected in both her colon tissue and a drainage sample indicated intestinal mucormycosis. Early intensive treatment with high-dose liposomal amphotericin B was successful, and she was subsequently discharged from the hospital. The fungal isolates were identified to be *Lichtheimia ramosa* and *Aspergillus calidoustus* via gene sequencing using pan-fungal primers as well as species-specific primers against elongation factor 1 and beta-tubulin for detecting *Lichtheimia* and *Aspergillus*, respectively.

Key words: intestinal mucormycosis, *Lichtheimia ramosa*, *Aspergillus calidoustus*, zygomycosis, fungal infection

(Intern Med 57: 2421-2424, 2018)

(DOI: 10.2169/internalmedicine.0254-17)

Introduction

Mucormycosis, previously called zygomycosis, is a life-threatening infection caused by filamentous fungi that belong to the order Mucorales. Mucormycosis mainly occurs in immunocompromised individuals, and most commonly affects the sinuses or lungs following the inhalation of fungal spores. Gastrointestinal mucormycosis is relatively rare and accounts for only 4-7% of all mucormycosis cases (1, 2). *Lichtheimia ramosa*, formerly known as *Absidia ramosa*, is an uncommon human pathogen belonging to the order Mucorales (3). Separately, *Aspergillus calidoustus* was once identified as *Aspergillus ustus*, another rare pathogen, but it was reclassified as a new species following the discovery of distinct characteristics by Varga et al. in 2008 (4). We herein describe a rare episode of a patient with invasive intestinal

mycosis caused by a simultaneous infection with *L. ramosa* and *A. calidoustus*.

Case Report

A 53-year-old woman was admitted to Osaka Police Hospital with septic shock after having contracted pneumococcal pneumonia. She had undergone surgery for esophageal cancer 2.5 years prior to this presentation. Her gastric tube, which had been reconstructed by esophagogastrostomy, had become obstructed and her nutrition status was poor (body mass index: 11.8 kg/m²). She had a history of smoking (10 cigarettes/day) and alcohol consumption (4 glasses of wine/day). She did not have diabetes mellitus and tested negative for the human immunodeficiency virus antibody. Penicillin-susceptible *Streptococcus pneumoniae* was isolated from hemoculture, and she was treated with meropenem (2 g/

¹Department of Bacteriology, Osaka City University Graduate School of Medicine, Japan, ²Research Center for Infectious Disease Sciences, Osaka City University Graduate School of Medicine, Japan, ³Department of Infection Control Center, Osaka Police Hospital, Japan, ⁴Clinical Laboratory Center, Osaka Police Hospital, Japan and ⁵Department of Infection Control Science, Osaka City University Graduate School of Medicine, Japan

Received: September 21, 2017; Accepted: January 5, 2018; Advance Publication by J-STAGE: March 9, 2018

Correspondence to Dr. Yukihiro Kaneko, ykaneko@med.osaka-cu.ac.jp

day), immunoglobulin (5 g/day), and hydrocortisone (200 mg/day) for 7 days under ventilation and continuous hemodiafiltration for an invasive pneumococcal infection.

On day 12, abdominal radiography and computed tomography revealed free air in the peritoneal cavity (Fig. 1), and emergency surgery was performed for a transverse colon

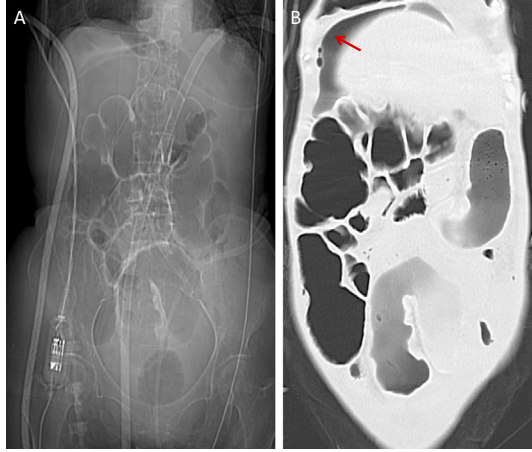


Figure 1. Abdominal radiography and computed tomography findings. Radiograph (A) and computed tomography scan (B) showing the entire colon filled with gas and free air in the suprahepatic area (red arrow).

perforation. Multiple ulcers were observed throughout the colon along with a single perforation associated with thinning of the intestinal wall. Hence, we performed subtotal colectomy from the cecum to the upper rectum and created a stoma. The formation of colonic ulcers and fistula was confirmed by histopathological examinations (Fig. 2A and B). A 38°C fever and high degree of inflammation were sustained after surgery, although no lung field lesions were observed. Meropenem, teicoplanin, metronidazole, and caspofungin were administered to treat the perforation peritonitis. Fever and rectal bleeding persisted on day 16, and multiple ulcers and bleeding in the residual rectum were confirmed by colonoscopy. *Aspergillus* spp. and other filamentous fungi were isolated from drainage from Douglas' pouch. An *Aspergillus* galactomannan antigen test was positive (0.5 pg/mL). On day 20, filamentous fungi were detected in almost all ulcers in the colon tissue collected during surgery (Fig. 2C-E). Gastrointestinal type mucormycosis and aspergillosis were suspected, and liposomal amphotericin B (L-AMB) administration was started at 8 mg/kg. Subsequently, the fever subsided, filamentous fungus was no longer detected in the drainage fluid from Douglas' pouch, and the inflammatory response both diminished. The multiple ulcers markedly improved along with the patient's general condition, and she was discharged from the hospital

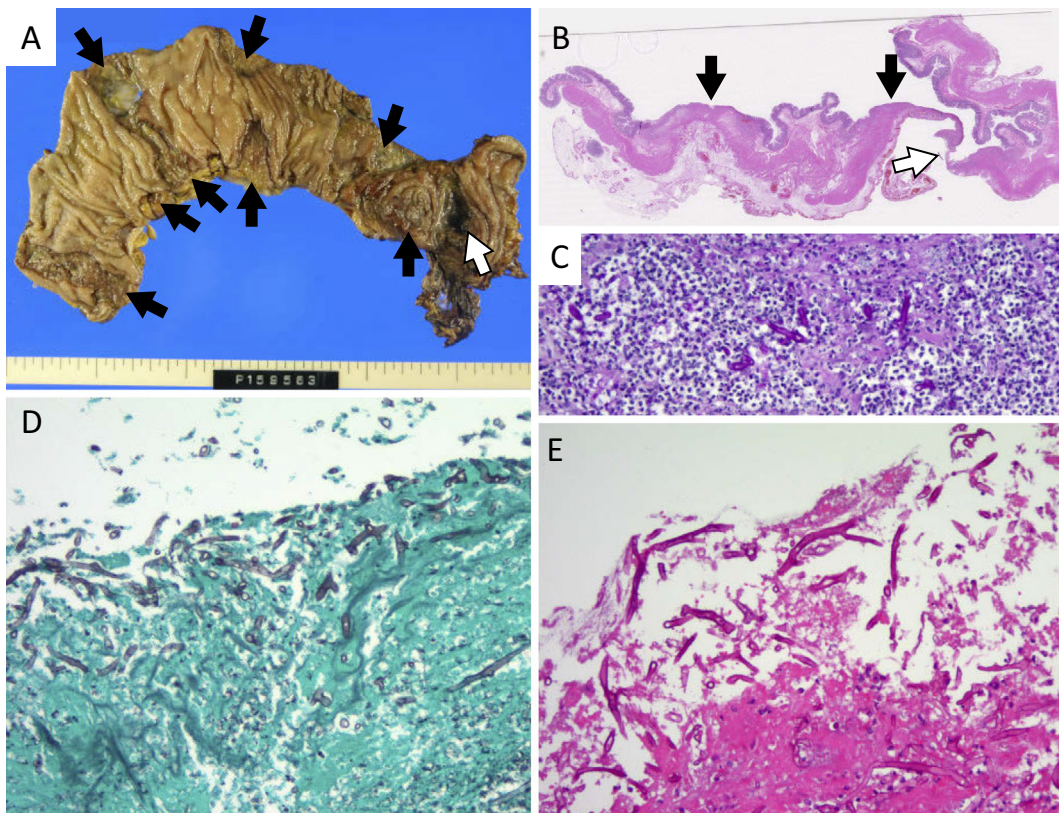


Figure 2. Macroscopic and microscopic examination of the removed colon. A and B: Multiple ulcers (black arrows) and a fistula (white arrow) were recognized macroscopically (A) or under loupe magnification (B). C-E: A microscopic examination revealed filamentous fungi in the ulcerative region (Magnification: $\times 400$). The tissue specimens were stained with Hematoxylin and Eosin staining (B and E), periodic acid Schiff (C), or Grocott methenamine silver (D).

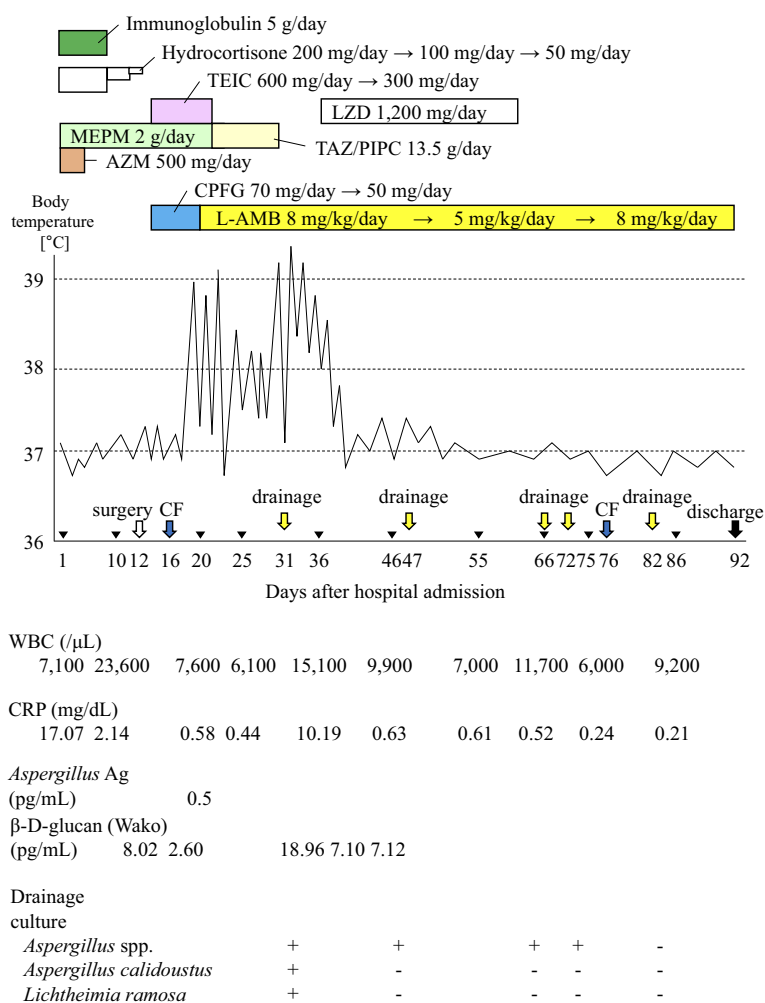


Figure 3. The clinical course of the patient. Fever subsided after intensive liposomal amphotericin B (L-AMB) treatment. Filled inverted triangles (▼) indicate the date when the WBC and CRP data were obtained. AZM: azithromycin, CF: colonofiberscopy, CPFG: caspofungin, LZD: linezolid, MEPM: meropenem, TAZ/PIPC: tazobactam/piperacillin, TEIC: teicoplanin

(Fig. 3).

Two filamentous fungi that were isolated from the Douglas pouch drainage sample were further investigated. Each of their macroscopic and microscopic characteristics was distinct. Gene sequencing using panfungal primers against the internal transcribed spacer and D1/D2 of the 26S nuclear ribosomal RNA gene revealed one strain to be *Lichtheimia* spp. and the other to be *Aspergillus* spp. Further analysis using species-specific primers targeting elongation factor 1 α of *Lichtheimia* and β -tubulin of *Aspergillus* identified the species as *L. ramosa* (100% match in a 407 bp region) and *A. calidoustus* (100% match in a 343 bp region), respectively. The specific primers for internal transcribed spacer were: for ITS1 (TCCGTAGGTGAACCTGCGG) and ITS4 (TCCTCCGCTTATTGATATGC); for D1/D2: NL1 (GCATATCAATAAGCGGAGGAAAA) and NL4 (GGTCCGTGTTTCAAGACGG); for elongation factor 1 α : EF1alpha M1 (GCTGGTATCTCCAAGGATGG) and EF1alpha M2 (CGACGGACTTGACTTTCRGTGG); and for β -tubulin: bTub1 (AATTGGTGCCGCTTTCTGG) and bTub2 (AGTTGTCCG GACGGAATAG) (3, 5-7).

Discussion

We successfully treated a patient with intestinal mycosis caused by a coinfection with *L. ramosa* and *A. calidoustus*. These species are often isolated from patients who have undergone transplantations (4, 8) and are currently regarded as emerging fungal pathogens. Although the epidemiological status of mucormycosis in Japan is unclear, autopsy case studies indicate that Mucorales fungi are the third most frequent cause of invasive fungal infection (9, 10). A rising incidence rate of mucormycosis has been reported in European countries, with *Lichtheimia* spp. being one of the most frequently involved species (11). Most patients who develop such infections have serious background diseases or other conditions such as hematological malignancies or trauma/surgical wounds, or else are receiving immunosuppressant therapy (11). The risk factors in our patient included alcohol consumption, malnutrition, immunocompromised status induced by invasive pneumococcal disease, broad-spectrum antibacterial drug administration, and high-dose steroid ther-

apy. Because she initially had no gastrointestinal symptoms such as abdominal pain and melena, the time of gastrointestinal mycosis onset was unknown. A histopathological analysis indicated the presence of filamentous fungi, but did not clearly differentiate between *Aspergillus* and *Mucorales* spp. The endothelial cells exhibited slightly positive immunostaining for cytomegalovirus, but the patient's blood tested negative for C7-HRP at admission.

This episode was rare in that the patient was simultaneously infected with both *L. ramosa* and *A. calidoustus*. Moreover, this is the first reported case of gastrointestinal *A. calidoustus* infection to our knowledge, although one patient with gastrointestinal mucormycosis caused by *L. ramosa* was previously reported (12). An accurate diagnosis of mycosis requires the genetic investigation of fungal isolates, which is difficult to perform at medical facilities lacking specialized laboratories. Therefore, a significant number of patients with *A. calidoustus* infection may have been overlooked in the past, and its incidence rate may be much higher than the currently accepted estimate.

Mucormycosis has a high mortality rate mainly owing to its rapid progression and challenging premortal diagnosis (11, 13). *Mucorales* spp. are generally difficult to cultivate from tissue specimens. Moreover, many patients are ineligible for surgery because of their poor physical condition. Therefore, the proportion of patients with confirmed premortal diagnoses of mucormycosis is quite small; a relatively large number of patients are diagnosed for the first time at autopsy. To achieve a successful outcome, clinicians must often commence antifungal therapy based on a presumptive diagnosis at an early stage of infection. High-dose L-AMB is very effective against most *Mucorales* species with a few exceptions, such as *Cunninghamella bertholletiae* (11). In our patient, emergency surgery was performed immediately, and fungal culturing and histopathological examinations were conducted; intestinal mucormycosis was suspected based on these clinical findings, and high-dose L-AMB therapy was therefore initiated. We therefore would like to emphasize that an early presumptive diagnosis and the immediate initiation of antifungal therapy are critical for achieving a favorable outcome in such patients.

The authors state that they have no Conflict of Interest (COI).

Financial Support

This research is partially supported by the Research Program on Emerging and Re-emerging Infectious Diseases funded by the Japan Agency for Medical Research and Development, Grant-in-Aid for Scientific Research from the Japan Society for the Promotion of Science to H.K. (16725777) and Y.K. (17894158), and Pfizer Academic Contributions to Y.K.

Acknowledgement

We thank Yukimi Kira and Yoriko Yabunaka (Central Laboratory of Osaka City University Medical School) for their valuable technical support.

References

- Roden MM, Zaoutis TE, Buchanan WL, et al. Epidemiology and outcome of zygomycosis: a review of 929 reported cases. *Clin Infect Dis* **41**: 634-653, 2005.
- Lantermier F, Dannaoui E, Morizot G, et al. A global analysis of mucormycosis in France: the RetroZygo Study (2005-2007). *Clin Infect Dis* **54**: S35-S43, 2012.
- Woo PC, Leung SY, Ngan AH, Lau SK, Yuen KY. A significant number of reported *Absidia corymbifera* (*Lichtheimia corymbifera*) infections are caused by *Lichtheimia ramosa* (syn. *Lichtheimia hongkongensis*): an emerging cause of mucormycosis. *Emerg Microbes Infect* **1**: e15, 2012.
- Varga J, Houbraken J, Van Der Lee >HA, Verweij PE, Samson RA. *Aspergillus calidoustus* sp. nov., causative agent of human infections previously assigned to *Aspergillus ustus*. *Eukaryot Cell* **7**: 630-638, 2008.
- White TJ, Bruns TD, Lee SB, et al. Amplification and direct sequencing of fungal ribosomal rna genes for phylogenetics. In: PCR Protocols A Guide to Methods and Applications. Innis MA, Gelfand DH, Sninsky JJ, White TJ, Eds. Academic Press, New York, 1990: 315-322.
- Kurtzman CP, Robnett CJ. Identification of clinically important ascomycetous yeasts based on nucleotide divergence in the 5' end of the large-subunit (26S) ribosomal DNA gene. *J Clin Microbiol* **35**: 1216-1223, 1997.
- Balajee SA, Gribskov JL, Hanley E, Nickle D, Marr KA. *Aspergillus lentulus* sp. nov., a new sibling species of *A. fumigatus*. *Eukaryot Cell* **4**: 625-632, 2005.
- Egli A, Fuller J, Humar A, et al. Emergence of *Aspergillus calidoustus* infection in the era of posttransplantation azole prophylaxis. *Transplantation* **94**: 403-410, 2012.
- Shimodaira K, Okubo Y, Nakayama H, et al. Trends in the prevalence of invasive fungal infections from an analysis of annual records of autopsy cases of Toho University. *Mycoses* **55**: 435-443, 2012.
- Kurosawa M, Yonezumi M, Hashino S, et al. Epidemiology and treatment outcome of invasive fungal infections in patients with hematological malignancies. *Int J Hematol* **96**: 748-757, 2012.
- Guinea J, Escribano P, Vena A, et al. Increasing incidence of mucormycosis in a large Spanish hospital from 2007 to 2015: Epidemiology and microbiological characterization of the isolates. *PLoS One* **12**: e0179136, 2017.
- Irtan S, Lamerain M, Lesage F, et al. Mucormycosis as a rare cause of severe gastrointestinal bleeding after multivisceral transplantation. *Transpl Infect Dis* **15**: E235-E238, 2013.
- Yano S, Minami J, Nishiwaki K, et al. Rapid progression and unusual premortal diagnosis of mucormycosis in patients with hematologic malignancies: analysis of eight patients. *Int J Hematol* **93**: 344-350, 2011.

The Internal Medicine is an Open Access article distributed under the Creative Commons Attribution-NonCommercial-NoDerivatives 4.0 International License. To view the details of this license, please visit (<https://creativecommons.org/licenses/by-nc-nd/4.0/>).