

Positron emission tomography detection of synchronous colon cancer in a patient with chronic lymphocytic leukemia

Jeong Eun Lee¹, Sang Mook Bae¹, Moon Sung Kim¹, Woo Hyeon Kim¹, Kyung Jin Yun¹, Min jung Cho¹, and Seok-Goo Cho^{1,2}

¹Department of Internal Medicine,
²Catholic Blood and Marrow Transplantation Center, Seoul St. Mary's Hospital, The Catholic University of Korea College of Medicine, Seoul, Korea

To the Editor,

Patients with chronic lymphocytic leukemia (CLL) have an increased incidence of secondary malignancies, such as solid tumors and lymphoid malignancies, during their clinical course. Here, we report a case of synchronous detection of colon cancer during initial staging with whole-body positron emission tomography (PET) with fluorine-18 fluorodeoxyglucose (¹⁸F-FDG) in a 53-year-old male patient with newly diagnosed CLL. Extranodal involvement and high-intensity FDG uptake in CLL are rare; thus, increased uptake in localized extranodal sites is highly suspicious of transformation to other hematological malignancies or the development of secondary solid tumors. Our findings suggest that patients with CLL should be carefully evaluated for secondary cancers in the initial staging and during the follow-up period. ¹⁸F-FDG-PET/computed tomography (CT) may be useful for detecting secondary malignancies; however, further studies are needed to investigate the cost-effectiveness of this imaging procedure compared to conventional CT in the follow-up setting.

A 53-year-old male presented with chronic fatigue, night sweats, constipation, and a weight loss of 4 kg experi-

enced over a 3-month period. He was otherwise relatively well and asymptomatic and had no history of previous exposure to ionizing radiation, cytotoxic agents, or a family history of leukemia. Physical examination revealed no lymphadenopathy, but the spleen tip was palpable 8 cm below the left lower costal margin. The peripheral blood (PB) white cell count was $34.3 \times 10^9/L$, with 70% lymphocytes. The complete blood count revealed a hemoglobin level of 11.0 g/dL and platelet count of $149 \times 10^9/L$ of blood. Bone marrow (BM) aspirate was hypercellular; 70% of cells were mature B-lymphocytes. Immunophenotyping of PB and BM revealed a monoclonal B-lymphocyte population expressing surface immunoglobulin (slg) kappa (κ), CD19, CD20, CD5, and CD23 antigens. However, cytogenetic analysis using fluorescence *in situ* hybridization showed no specific chromosomal abnormalities. The diagnosis of B-cell stage II (intermediate-risk) was established according to the Rai staging system. Conventional abdomen/pelvic CT showed a focal soft tissue mass of ~6 cm with irregular borders involving the hepatic flexure of the right colon without pericolic infiltration or regional lymphadenopathy and marked

Received: May 31, 2009
Revised : July 13, 2009
Accepted: August 12, 2009

Correspondence to
Seok-Goo Cho, M.D.
Department of Internal Medicine, and Catholic Blood and Marrow Transplantation Center, Seoul St. Mary's Hospital, The Catholic University of Korea College of Medicine, 222 Banpo-daero, Seocho-gu, Seoul 137-701, Korea
Tel: +82-2-2258-6052
Fax: +82-2-599-3589
E-mail: chosg@catholic.ac.kr

splenomegaly. Because the incidence of extranodal involvement in CLL is low, ^{18}F FDG-PET/CT was performed to evaluate secondary malignancies such as Richter's transformation to diffuse large B-cell lymphoma, which is more aggressive than the underlying CLL or colon cancer. The staging ^{18}F FDG-PET/CT revealed intense FDG uptake in the ascending colon and mild focal metabolic activity in the left internal jugular region. The scan revealed diffuse increased FDG activity related to splenic lesions associated with splenomegaly (Fig. 1). Colonoscopy and biopsy identified a massive ulcerofungating tumor measuring $\sim 6.0 \times 5.5$ cm on the hepatic flexure. A right hemicolectomy was performed (Fig. 2A). Pathology revealed a well-differentiated adenocarcinoma invading the submucosa with no metastatic lymph nodes (0/48) that was classified as pT1NoMo according to the Union Internationale Contre le Cancer staging system (Fig. 2B). The patient then received intravenous fludarabine $25 \text{ mg/m}^2/\text{day}$ (42.5 mg total daily dose) and cyclophosphamide $250 \text{ mg/m}^2/\text{day}$ (450 mg total daily dose) for 3 consecutive days every 4 weeks; a total of three cycles of chemotherapy. No delays in administration or dose reductions were required, and no

complications developed during chemotherapy. Treatment response was assessed by physical examination and evaluation of the blood and BM 2 months after chemotherapy. The patient's constitutional symptoms and splenomegaly resolved, and his clinical laboratory tests and BM findings returned to normal. On follow-up CT, no hepatosplenomegaly or lymphadenopathy or recur

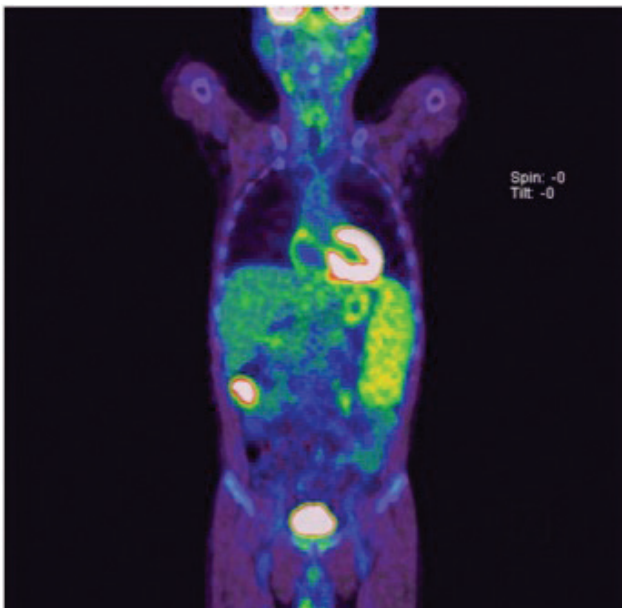


Figure 1. Whole-body positron emission tomography with fluorine-18 fluorodeoxyglucose (FDG). Intense FDG uptake in the ascending colon and mild focal metabolic activity in the left internal jugular region and diffuse increased FDG activity related to splenic lesions associated with splenomegaly.

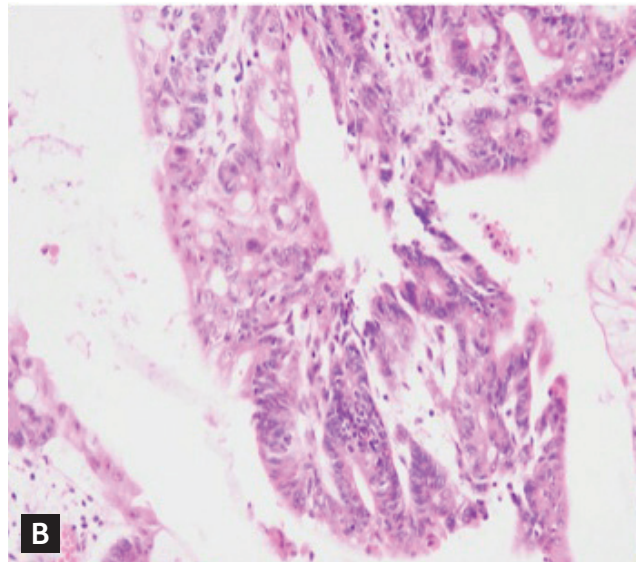
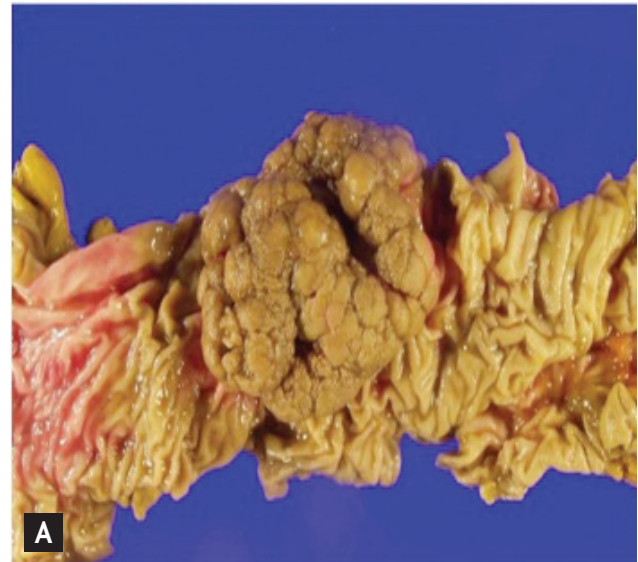


Figure 2. Gross specimen and histological findings following right hemicolectomy. (A) Colonoscopy revealed a massive ulcerofungating tumor of $\sim 6.0 \times 5.5$ cm on the hepatic flexure. (B) Pathological analysis of the biopsy specimen revealed a well-differentiated adenocarcinoma invading the submucosa with no metastatic lymph nodes (0/48), which was classified as pT1NoMo according to the Union Internationale Contre le Cancer staging system (H&E, $\times 200$).

rence of colon cancer was found. The surveillance PET/CT scan and colonoscopy were unremarkable. At the time of writing, the patient had received a total of five cycles of fludarabine plus cyclophosphamide (FC) chemotherapy and is in complete remission without recurrence of colon cancer following the surgery.

CLL and other malignant neoplasms occasionally occur concomitantly, and patients with CLL are at significantly increased risk of developing solid tumors such as lung cancer, gastrointestinal carcinoma, and melanoma (Supplementary Table 1 online). In a large study involving 4,869 patients with CLL diagnosed between 1935 and 1971, subsequent neoplasms were observed in 4.8% of cases, and the relative risk (RR) was estimated to be 1.1, with a 95% confidence interval (CI) of 1.0 to 1.3. The National Cancer Institute's Surveillance, Epidemiology, and End Results Cancer Statistics Review 1973 to 1996 reported subsequent neoplasms in 11.1% of CLL cases (RR, 1.20; 95% CI, 1.15 to 1.26). Both reports found significant excess risks of Kaposi's sarcoma (RR, 5.3 and 5.09, respectively) and malignant melanoma (RR, 6.7 and 3.18, respectively). However, the neoplasms most commonly identified as having an elevated RR were cancers of the lung (RR, 1.5 and 1.66, respectively) and colon (RR, 1.0 and 1.13, respectively).

Prolonged immunosuppression caused by asymptomatic B-cell CLL and chemotherapy, including the use of alkylating agents, may explain the association between CLL and secondary malignancies. That is, patients with CLL have an increased risk of developing additional malignancies during their clinical course, particularly when they have been treated with alkylating agents for long periods. Thus, clinicians should be aware of the potential for a secondary malignancies occurring in patients with CLL [1].

Secondary malignancies may be detected incidentally regardless of treatment regime, but they may be more frequent in patients with CLL exposed to nucleoside analog therapy [2]. The present case is notable because the synchronous colon cancer was detected during initial staging with whole body PET with ^{18}F -FDG in a patient with newly diagnosed CLL.

PET imaging is useful for diagnosing hematological malignancies, particularly Hodgkin's lymphoma and aggressive non-Hodgkin's lymphoma, and is recommended for staging, prediction of prognosis, treatment

planning, and response evaluation of lymphomas [3]. Furthermore, ^{18}F -FDG PET/CT is of high diagnostic value in the staging and restaging of various malignant diseases, such as colorectal cancer, lung cancer, breast cancer, head and neck cancer, and malignant lymphomas. In a retrospective study of 37 patients with CLL undergoing ^{18}F -FDG PET/CT between March 2003 and July 2005, Richter's transformation of CLL to diffuse large B-cell lymphoma and a new malignancy showing abnormally increased ^{18}F -FDG uptake were detected with high sensitivity (94%), specificity (90%), and negative predictive values (97%) [4]. However, ^{18}F -FDG PET/CT has not provided useful information for the management of CLL with the exception of detecting Richter's transformation; thus, further studies should investigate the cost-effectiveness and benefit of PET/CT compared to conventional CT in the follow-up period [3,4]. The prognosis for CLL with secondary malignancies is generally poor.

Here we present a case of synchronously diagnosed B-cell CLL and adenocarcinoma of the colon. Although previous studies have reported a nonsignificant increase in colon cancer subsequent to the diagnosis of CLL, we noted an epidemiological association in our case suggesting the neoplasm was not a simple coincidence. This synchronous relationship may be explained in terms of prolonged immunosuppression as a result of asymptomatic B-cell CLL or shared cancer genes. A common alteration on chromosome 7, which has been demonstrated in 10% to 15% of B-cell CLL and 75% of colorectal cancer patients, may be the genetic basis of an association between hematological malignancy and hereditary nonpolyposis colon cancer with abnormalities in p53 gene expression. Chemotherapy administered in early stage B-cell CLL does not provide a survival advantage over conservative treatment and does not reduce the incidence of second neoplasms. Furthermore, the risk of recurrent solid tumors with a diagnosis of B-cell CLL has not been investigated.

Here, we report an incidentally identified colon cancer in a 53-year-old male with newly diagnosed CLL during initial staging with whole body PET scanning with ^{18}F -FDG. Our patient achieved complete remission 2 months after three cycles of FC chemotherapy with no evidence of recurrent colon cancer or other malignancies following surgery. Patients with CLL have an in-

creased risk of subsequent cancers, such as other hematological malignancies or secondary solid tumors. Although the role of shared etiological factors remains unclear, patients with CLL should be carefully evaluated in initial staging and during the follow-up period for subsequent cancers, which can be detected using ^{18}F FDG-PET/CT.

Keywords: Leukemia, lymphocytic, chronic, B-cell; Colonic neoplasms; Synchronous

Conflict of interest

No potential conflict of interest relevant to this article is reported.

Acknowledgments

The present study was supported by a grant from the Korean Health Technology R&D Project, Ministry of Health and Welfare, Republic of Korea (A092258).

REFERENCES

1. Robak T. Second malignancies and Richter's syndrome in patients with chronic lymphocytic leukemia. *Hematology* 2004;9:387-400.
2. Cheson BD, Vena DA, Barrett J, Freidlin B. Second malignancies as a consequence of nucleoside analog therapy for chronic lymphoid leukemias. *J Clin Oncol* 1999;17:2454-2460.
3. Burton C, Ell P, Linch D. The role of PET imaging in lymphoma. *Br J Haematol* 2004;126:772-784.
4. Bruzzi JF, Macapinlac H, Tsimberidou AM, et al. Detection of Richter's transformation of chronic lymphocytic leukemia by PET/CT. *J Nucl Med* 2006;47:1267-1273.