

Effect of bacterium in the malignant wounds of soft tissue sarcoma

EIJI NAKATA, TOMOHIRO FUJIWARA, HARUYOSHI KATAYAMA,
TAKUTO ITANO, TOSHIYUKI KUNISADA and TOSHIFUMI OZAKI

Department of Orthopedic Surgery, Okayama University Hospital, Okayama, Okayama 700-8558, Japan

Received April 7, 2022; Accepted June 8, 2022

DOI: 10.3892/ol.2022.13465

Abstract. Malignant wounds (MWs) are rare skin lesions, which accompany ulceration, necrosis and infection caused by infiltration or damage by malignant tumor. The present study aimed to investigate the bacterial etiology implicated in MW in soft tissue sarcoma (STS), and the effectiveness of culture-guided perioperative antibacterial administration. A retrospective evaluation was conducted on medical records of patients who presented with MW between 2006 and 2020. A total of seven patients were included in the present study, in whom all tumors were relatively large (>5 cm) and high-grade. Subsequently, five patients underwent limb-sparing surgery, and three patients had distant metastases with a 5-year overall survival of 71%. Preoperative microbiological sampling from the wound identified 11 different bacterial strains in five patients. The infections were polymicrobial with an average of 2.6 strains isolated per patient (1 aerobic, 1.6 anaerobic bacteria). They were predominantly methicillin-sensitive *Staphylococcus aureus*. Patients with MWs from STS reported symptoms, including bleeding (71%), exudation (71%) and malodorous wound (43%) at the initial presentation; these completely resolved after surgery. All but one patient reported pain at the MW site with an average numeric rating scale of 4.4 at presentation that decreased to 1.4 (P=0.14) and 0.6 (P=0.04) one and two weeks after surgery, respectively. The patients had elevated C-reactive protein (71%), anemia (57%), low albumin (86%) and renal/liver dysfunction (14-29%). One patient was diagnosed with sepsis. Surgical resection afforded symptomatic relief and resolution of abnormal laboratory values. Although selected antibiotics were administered in four patients based on the preoperative antibiotic sensitivity test, surgical site infection (SSI) occurred in three patients. Therefore, the effectiveness of the selected antibiotics based on the results of the preoperative culture in preventing SSI needs to be investigated in the future. In conclusion, physicians

should keep in mind that although surgical resection can improve the symptoms and abnormal values in laboratory examination from MW, it is accompanied with a high rate of SSI and poor prognosis.

Introduction

Malignant wounds (MWs) are lesions caused by malignant tumors infiltrating or damaging the skin (1-3). MWs are often accompanied by ulcerations, necrosis, hemorrhage, and inflammation (1,2). It is estimated that 5-7% of cancer patients experience MWs, especially patients with breast cancer, soft tissue sarcoma (STS), head and neck cancer, and melanoma (1,2). Previous studies mainly enrolled patients with limited life expectancy due to unresectable advanced or metastatic breast and skin cancers (4,5). Some studies reported an incidence of 3-4% for MW in patients with STS (6-9).

MWs are often infected because necrotic tissue provides a suitable environment for bacterial growth. Patients frequently report symptoms as malodorous wounds, exudation, pain, and bleeding. These symptoms lead to impaired mobility, emotional distress, and a poor quality of life (3-5). Fromantin *et al* proposed that MWs in patients with breast cancer had polymicrobial colonization predominated by *Staphylococcus aureus* and *Pseudomonas aeruginosa* (4). Biofilms were present in the wounds of 35% of the patients, and the concentration of bacteria correlated with the emergence of odor and pain. Few studies have focused on the bacteriological investigation of MWs in patients with STS (10-12). Lutchminarian *et al* reported that the most common pathogen in MW from STS was *Staphylococcus aureus* (33%), followed by β -hemolytic *Streptococcus* (17%), and *Pseudomonas aeruginosa* (17%) (13). These infections sometimes lead to severe clinical problems, such as sepsis and surgical site infection (SSI) (10,12). Elfallal *et al* reported a case of life-threatening sepsis from severe necrotic wound in a patient with giant angioliipoma of the back (14). Immediate tumor excision with hemostasis was required. This supports the need for early diagnosis and treatment of concurrent sepsis. The effectiveness of sensitivity-guided perioperative antibacterial prophylaxis remains unclear. Data on perioperative improvement of clinical symptoms and laboratory data are lacking.

MWs have some oncologic features in STS; thus, it is important to manage both oncologic and infectious problems. In previous reports, patients with MWs from STS were older (mean age: 65-73 years), and presented with higher grade,

Correspondence to: Dr Eiji Nakata, Department of Orthopedic Surgery, Okayama University Hospital, 2-5-1 Shikata-cho, Okayama, Okayama 700-8558, Japan
E-mail: eijinakata8522@yahoo.co.jp

Key words: malignant wounds, soft tissue sarcoma, microbiological analysis, surgical site infection, prognosis

higher stage, and higher proportion of metastases (20-33%) compared to those without MWs (15-18). When the lesions are large, possibly requiring skin reconstruction, limb salvage was sometimes difficult, leading to a high rate of amputation (13-33%) (15-18). Although resection of the tumor can control the symptoms associated with MWs, previous studies reported high rates of surgical site infection (SSI) as much as 26-42% (15,18). Hoshi *et al* reported 42% incidence of postoperative (SSI), and *Candida* species was the most common isolate, followed by *Pseudomonas aeruginosa* and *Enterococcus* species (18).

Therefore, this study aimed to perform microbiological analyses in a series of STS patients with MWs. We specifically investigated the bacterial profile in MWs and the effectiveness of sensitivity-guided perioperative antibacterial prophylaxis. Lastly, we investigated the incidence of sepsis and the changes in laboratory values after treatment.

Materials and methods

Study design and setting. We retrospectively evaluated the medical records of patients who presented with MWs at Okayama University Hospital (Okayama, Japan) between April 2006 and April 2020.

Study population. Patients who had pathologically confirmed MW and underwent surgical resection for STS in the extremity were included in the study. The exclusion criteria were as follows: (a) only conservative management done; (b) follow-up less than two years post-surgery; (c) development of MW during the clinical course. Finally, seven patients (four males, three females) were included in this study (Table I). Their median age at the start of treatment was 59 years (range, 30-78). Histological diagnosis was established according to the WHO Classification (19). Myxoid liposarcoma was diagnosed in two patients, and myxofibrosarcoma, undifferentiated pleomorphic sarcoma (UPS), fibrosarcoma, angiosarcoma, leiomyosarcoma, and malignant peripheral nerve sheath tumor (MPNST) was diagnosed in one patient each. The median tumor size was 10 cm (range: 6-31) and was superficial in 5 patients and deep in 2 patients. The grade was determined using the French Fédération Nationale des Centres de Lutte Contre Le Cancer (FNCLCC) grading system; grade 2 cancer was observed in three patients and grade 3 in four patients (20). The American Joint Committee on Cancer (AJCC) stages were IIIA in four patients and IV in three patients. The locations of the tumor were as follows: the thigh (4), each upper arm (1), lower leg (1), and abdomen (1). No patient had a treatment history of hypertension, diabetes mellitus (DM), renal disorder, liver disorder, or respiratory disorder. The median follow-up period was 53 months (range: 4-152 months).

Microbiological sampling and testing. Preoperative microbiological samples were obtained from the necrotic zone of the wound. Detection of aerobic, facultative anaerobic, and strict anaerobic bacteria was carried out using a quantitative method. We investigated the incidence of SSI based on the definition provided by the Centers for Disease Control (CDC) (Table SI) (21).

Clinical investigation. We investigated the symptoms of the wound (e.g., bleeding, odor/exudate, and pain) and clinical

condition (fever) on presentation and after surgery. Fever was defined as a temperature higher than or equal to 37.5°C. Pain was quantified using a 10-point numeric rating scale (NRS). The symptoms were documented at baseline, one, and two weeks postoperatively. Bleeding was reported in five patients, foul odor in three patients, and exudate in five (Table II). These symptoms disappeared after surgery. All but one patient had pain at the MW site during the initial presentation, with an average NRS of 4.4 (range: 0-10). It decreased after surgery; the average NRS were 1.4 (range: 0-10, P=0.14) and 0.6 (range: 0-3, P=0.04) after one and two weeks of surgery, respectively. During the last follow-up, all but one patient had pain at the surgical site. Two patients presented with fever, which defervesced one week after surgery.

We investigated the presence of sepsis at the initial presentation. The diagnosis for sepsis was defined based on the Japanese Clinical Practice Guidelines for Management of Sepsis and Septic Shock 2020 (J-SSCG 2020) (22). By this definition, suspected infection can be rapidly identified in the presence of two or more quick Sequential Organ Failure Assessment (qSOFA) score: A respiratory rate (≥ 22 /min), altered mentation (Glasgow Coma Score ≤ 14), and a systolic blood pressure (≤ 100 mmHg) (23-25). Next, the diagnosis of sepsis was confirmed when the SOFA score was ≥ 2 points higher in the presence of a clear infection or suspected infection (Table III). Septic shock was defined as persistent hypotension requiring vasopressors to maintain a mean arterial pressure of ≥ 65 mmHg and a serum lactate level > 2 mmol/l (18 mg/dl) despite adequate volume resuscitation (22). One patient met the diagnostic criteria for sepsis (case 2).

Laboratory investigation. The following laboratory parameters were documented at baseline and 2-6 weeks after surgery: white blood cell (WBC) count, serum C-reactive protein (CRP), hemoglobin (Hgb), blood urea nitrogen (BUN), creatinine (Cr), albumin (Alb), alanine aminotransferase (ALT), aspartate aminotransferase (AST), and total bilirubin (T-bil). Anemia was defined as hemoglobin (Hgb) < 12.0 g/dl in non-pregnant women and < 13.0 g/dl in men based on the World Health Organization (WHO) criteria (26).

Treatment. Five patients initially underwent limb-sparing surgery, amputation was performed for one patient, and disarticulation was performed for one patient. Surgical excision margins were estimated based on the AJCC residual tumor classification (R classification) (27). These surgical margins were classified as follows: R0 margin, free of malignancy; R1 margin, microscopic tumor cells present at the inked border of the specimen; and R2 margin, grossly positive margins. Surgical margins were estimated as R0 in all patients. Soft tissue coverage was required in four patients: two free flaps (latissimus dorsi flap), one medial gastrocnemius muscle flap and skin graft, and one skin graft. Since all patients achieved R0 resection, radiation therapy was not performed for any of the patients. No patients received pre- or postoperative chemotherapy.

Statistical analysis. The Mann-Whitney U test was used to analyze continuous parameters, while Fisher's exact test was used for categorical parameters. We used the BellCurve for

Table I. Patient characteristics.

Case	Sex	Age, years	Histology	Size, cm	Location	FNCLCC	AJCC	Margin	Reconstruction	Metastases	Outcome
1	Female	75	Myxoid liposarcoma	17	Thigh	2	IV	R0	Skin graft	Lymph node	NED
2	Female	42	Myxoid liposarcoma	31	Thigh	2	IV	R0 (hip disarticulation)		Lung	DOD
3	Male	76	Undifferentiated sarcoma	8	Thigh	3	IIIA	Initial surgery; R0 Recurrence; R0 (hip disarticulation)	Latissimus dorsi flap + skin graft	Lung Soft tissue (follow up period)	DOD
4	Female	59	Fibrosarcoma	9	Thigh	3	IIIA	R0	Gastrocnemius muscle flap + skin graft		DOA
5	Male	55	Angiosarcoma	10	Lower leg	3	IV	R0 (Amputation)		Lymph node Bone Lung (follow-up period)	DOD
6	Male	78	Myxofibrosarcoma	10	Upper arm	2	IIIA	R0	Latissimus dorsi flap	Lymph node (follow-up period)	NED
7	Male	30	Malignant peripheral nerve sheath tumor	6	Abdomen	3	IIIA	R0			CDF

FNCLCC, French Fédération Nationale des Centres de Lutte Contre Le Cancer; AJCC, American Joint Committee on Cancer; NED, no evidence of disease; DOD, dead of disease; DOA, dead of another disease; CDF, continuous disease free.

Table II. Characteristics of the malignant wound.

Case	Bleeding	Odor	Exudate	Awareness of the tumor	Duration of the malignant wound
1	-	+	+	24 months	12 months
2	+	+	+	36 months	3 days
3	+	-	+	4 months	3 days
4	+	-	+	36 months	4 months
5	+	-	-	7 months	4 months
6	-	+	+	13 months	11 days
7	+	-	-	4 months	1 day

Table III. Sequential Organ Failure Assessment score.

Variables	Assessment score				
	0	1	2	3	4
Respiration					
PaO ₂ /FIO ₂ (mm Hg)	≥400	<400	<300	<200	<100
Coagulation					
Platelets (x10 ³ /l)	≥150	<150	<100	<50	<20
Liver					
Bilirubin (mg/dl)	<1.2	1.2-1.9	2.0-5.9	6.0-11.9	≥12.0
Cardiovascular					
Mean arterial pressure (mmHg)	≥70	<70	Dopamine ≤5 or dobutamine (any)	Dopamine >5 or norepinephrine ≤0.1	Dopamine >15 or norepinephrine >0.1
Nervous system					
Glasgow Coma Score	15	13-14	10-12	6-9	<6
Renal					
Creatinine (mg/dl)	<1.2	1.2-1.9	2.0-3.4	3.5-4.9	>5.0
Urine output (ml/d)				<500	<200

Excel (Social Survey Research Information Co., Ltd.) for all the analyses. The overall survival (OS) was calculated from the date of diagnosis to the date of death or the last follow-up visit. Survival rates were estimated using the Kaplan-Meier method. A P-value of <0.05 was considered statistically significant.

Results

Microbiological analyses. Microbiological sampling from the wound was performed prior to surgery for five patients and 11 different bacterial strains were identified in them (Table IV). The average number of bacterial strains isolated per wound was 2.6 (1 aerobic, 1.6 anaerobic species). The aerobic bacteria identified included *Pseudomonas aeruginosa*, *Alcaligenes faecalis*, *Acinetobacter baumannii* complex, *Stenotrophomonas maltophilia*, and *Bacillus cereus* (all of these were isolated in one patient). The facultative anaerobic bacteria were methicillin-sensitive *Staphylococcus aureus* (MSSA; three patients), *Enterococcus faecalis*, *Enterobacter cloacae*, *Streptococcus dysgalactiae*, and *Proteus vulgaris* (all isolated from all wounds). The strict anaerobic bacterial

species was *Peptostreptococcus asaccharolyticus* (one patient). Preoperative blood culture performed in one patient was negative. Antibiotics were selected and administered for four patients (cases 1-4) based on the preoperative antibiotic sensitivity test (Table IV).

Surgical Site Infection. Surgical site infection (SSI) occurred in three patients (43%), including two patients with superficial incisional SSI and one with deep incisional SSI. It was observed in 3/5 patients with exudate, but none in those without exudate. All three patients had received preoperative sensitivity-guided perioperative antibacterial prophylaxis. The bacterial isolates from MWS and surgical sites were identical in two of three patients (MSSA and *Pseudomonas aeruginosa*) and in one other patient (*Pseudomonas aeruginosa*). One patient (case 1) had levofloxacin-sensitive *Pseudomonas aeruginosa* and *Alcaligenes faecalis* cultured from the wound at the initial presentation, and was given levofloxacin hydrate preoperatively. Five days after resection and skin graft, *Pseudomonas aeruginosa* was cultured from the exudate of the grafted skin. Saline washing was performed and the

Table IV. Microbiological analyses and antibiotics.

A, Initial presentation			
Case	Sampling	Bacterial strain	Antibiotics
1	Wound	<i>Pseudomonas aeruginosa</i> <i>Enterococcus faecalis</i> <i>Alcaligenes faecalis</i>	Levofloxacin hydrate
2	Wound	<i>Methicillin-sensitive Staphylococcus aureus</i> <i>Streptococcus dysgalactiae</i>	Clindamycin + Cefazolin sodium → Cefazoplan
	Blood	Negative	
3	Wound	<i>Methicillin-sensitive Staphylococcus aureus</i> <i>Bacillus cereus</i>	Cefazolin sodium
4	Wound	<i>Methicillin-sensitive Staphylococcus aureus</i> <i>Proteus vulgaris</i>	Cefazolin sodium
6	Wound	<i>Enterobacter cloacae</i> <i>Acinetobacter baumannii</i> complex <i>Stenotrophomonas maltophilia</i> <i>Peptostreptococcus asaccharolyticus</i>	Cefazolin sodium
B, Surgical site infection			
Case	Sampling	Bacterial strain	Antibiotics
1	Wound	<i>Pseudomonas aeruginosa</i> <i>Enterococcus faecalis</i>	-
2	Wound	<i>Methicillin-sensitive Staphylococcus aureus</i>	Meropenem
3	Initial surgery		
	Wound, blood, urine	<i>Pseudomonas aeruginosa</i>	Meropenem
	Recurrence		
	Wound	<i>Pseudomonas aeruginosa</i>	Meropenem
	Blood	Negative	

wound healed without delay. In another patient (case 2), MSSA and *Streptococcus dysgalactiae* were isolated from the wound at the initial presentation. Pus was observed in the separated wound after one month of the hip disarticulation, from which MSSA was cultured. Irrigation, debridement, and intravenous meropenem resolved the deep incisional infection. In another patient (case 3), MSSA and *Bacillus cereus* were cultured from the wound at the initial presentation. Resection following reconstruction with free flap and skin graft was performed and cefazolin sodium, to which MSSA was sensitive, was given one day prior to surgery up to four days postoperatively. Fever continued after surgery, and *Pseudomonas aeruginosa* was isolated from the exudate of the grafted skin, in blood, and urine. The wound improved after saline washing and meropenem administration. The patient developed MWs from the recurrence 2.5 years later, for which hip disarticulation was performed. Pus was observed from the separated wound one month after surgery, and *Pseudomonas aeruginosa* was cultured from the wound. Irrigation and debridement were performed and meropenem was administered, which cured the deep incisional infection.

Laboratory investigation. The values of the laboratory tests for each patient are shown in Table SII. Four patients presented with elevated WBC count (average; 10169/ μ l, range: 5820-14820/ μ l), which decreased to the normal value within three weeks after surgery for all patients (Fig. 1A). Five patients presented with elevated CRP (average; 8.4 mg/dl, range: 0.11-27.7 mg/dl), which

decreased to the normal value in three patients and was less than 1 mg/dl in the other two patients after surgery (Fig. 1B). Four patients presented with low Hgb, which was diagnosed as anemia (average; 11.4 g/dl, range: 8.2-14.4 g/dl) (Fig. 1C). Four patients received RBC transfusions. The value of Hgb improved in three patients, though new asymptomatic anemia was seen in two patients after surgery. Two patients presented with elevated levels of BUN (average; 18.4 mg/dl, range: 9.7-43.5 mg/dl), which improved to within normal limits within one week after surgery in both the patients (Fig. 1D). Cr was within the normal range (average; 0.77 mg/dl, range: 0.53-0.96 mg/dl) in all patients during the first presentation and after surgery (Fig. 1E). Six patients presented with low Alb levels (average; 3.2 g/dl, range: 1.6-3.9 g/dl), which improved in three patients after surgery (Fig. 1F). ALT was within the normal range (average; 19 g/dl, range: 6-38 g/dl) during the first presentation, and one patient had transient elevation after surgery (Fig. 1G). All but one patient presented with elevated AST (average; 23 g/dl, range: 11-56 g/dl), which improved within five weeks after surgery (Fig. 1H). Two patients had transient elevation after surgery. All but one patient presented with elevated T-bil (average; 0.98 mg/dl, range: 0.47-2.3 mg/dl), which improved to the normal value one week after surgery (Fig. 1I), and significantly decreased two weeks after surgery (P=0.04).

Prognosis. Among the seven patients, one experienced local recurrence after 4 months, and underwent re-excision of the recurrent lesion. Three patients had distant metastases at

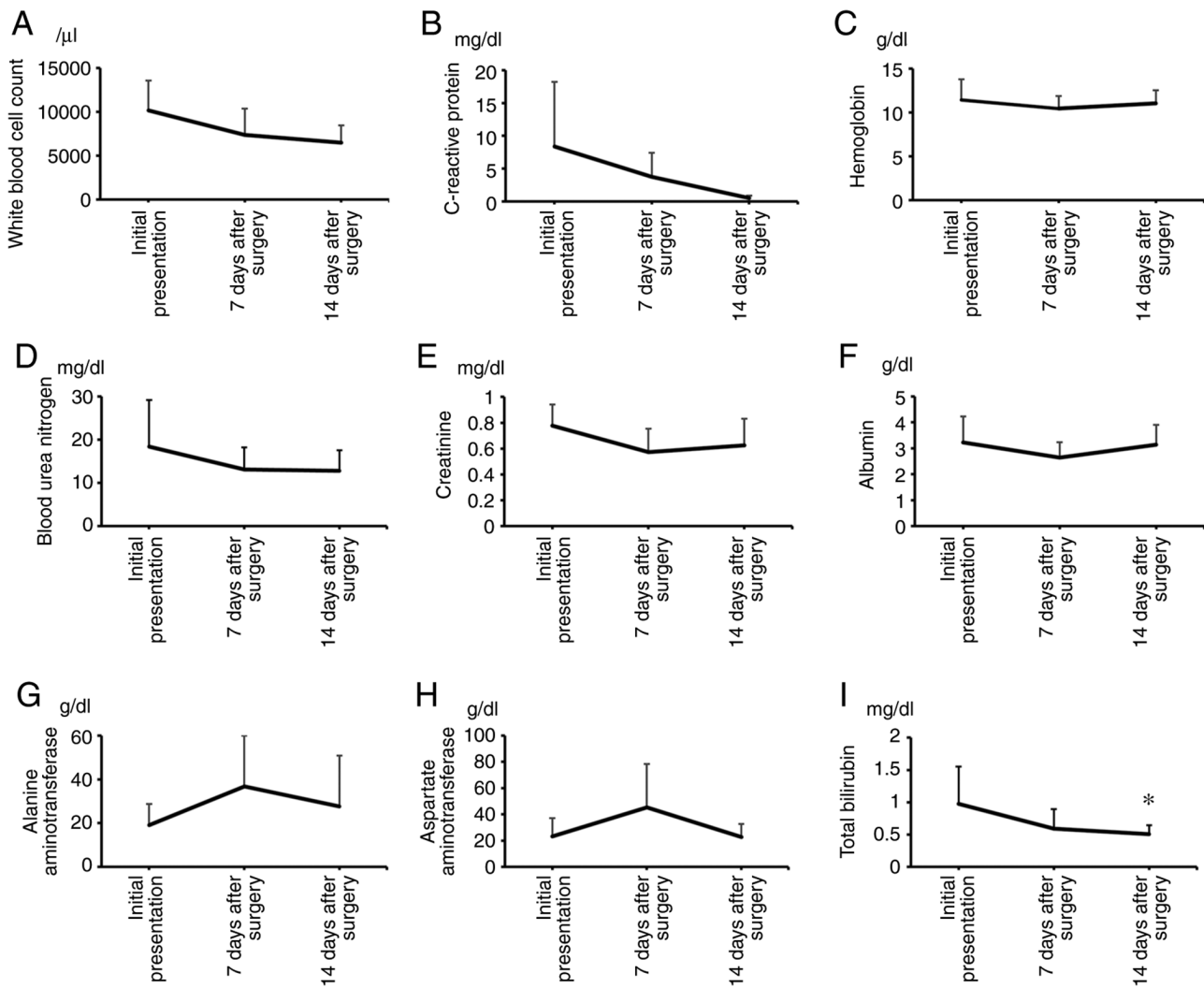


Figure 1. Laboratory results. The levels of WBC, CRP, Hgb, BUN, Cr, Alb, ALT, AST and T-bil were investigated at the initial presentation and after surgery (2-6 weeks). (A) A total of four patients presented with elevated WBC count (average 10169/ μ l), which decreased to the normal range within three weeks after surgery in all patients. (B) A total of five patients presented with elevated CRP (average 8.4 mg/dl), which decreased over time. (C) Four patients presented with low Hgb and were diagnosed as having anemia (average 11.4 g/dl). The level of Hgb improved in three patients. (D) Two patients presented with elevated BUN (average 18.4 mg/dl), which normalized within one week after surgery. (E) Cr was within the normal range (average 0.77 mg/dl) in all patients during the first presentation and after surgery. (F) Six patients presented with low Alb (average 3.2 g/dl), which improved in three patients after surgery. (G) ALT was within the normal value (average 19 g/dl), and one patient experienced transient elevation after surgery. (H) All patients, except for one, presented with elevated AST (average 23 g/dl), which improved within five weeks after surgery. (I) All patients, except for one, presented with elevated T-bil (average 0.98 mg/dl), which improved to within normal limits one week after surgery, and significantly decreased two weeks after surgery. * $P=0.04$. Alb, albumin; ALT, alanine aminotransferase; AST, aspartate aminotransferase; BUN, blood urea nitrogen; Cr, creatinine; CRP, C-reactive protein; Hgb, hemoglobin; T-bil, total bilirubin; WBC, white blood cell.

presentation: lymph node metastasis in two patients, lung metastasis in one patient, and bone metastasis in one patient. Two patients developed distant metastases during the follow-up period, including lymph node metastasis in one patient, lung metastasis in one patient, and soft tissue in one patient. Four patients died before the last follow-up. The 5-year OS rate was 71% (Fig. 2).

Case 1. The patient was a 42-year-old woman with MW from a myxoid liposarcoma in the thigh. She was quickly transported to the hospital because of pain and fatigue. She had a large tumor in her left thigh with bleeding, odor, and exudate on the overlying skin (Fig. 3A and B), and was referred to our institution. MRI revealed a mass with high intensity on T2-weighted images (Fig. 3C and D). CT revealed multiple lesions in both

lungs. Although the patient was conscious (Glasgow Coma Score of 15), she was pale and had abnormal vital signs: fever (39°C), low systolic blood pressure (89 mmHg), tachycardia (123/min), and hyperpnea (38/min). She also had low oxygen saturation (96%). Laboratory examination showed elevation of WBC (14820/ μ l), CRP (27.7 mg/dl), BUN (43.5 mg/dl), AST (56 U/l), and T-bil (2.3 mg/dl), low value of Hgb (8.2g/dl) and Alb (1.6 g/dl), and normal levels of ALT and Cr. Infection was suspected in the presence a qSOFA score of 2 at presentation. The patient received red blood cell (RBC) transfusions and infusion. A diagnosis of sepsis was confirmed by a SOFA score of 2. Culture from the wound revealed MSSA and *Streptococcus dysgalactiae*, for which clindamycin and cefazolin sodium were given. Improvement was seen in both clinical status and abnormal laboratory values. Needle

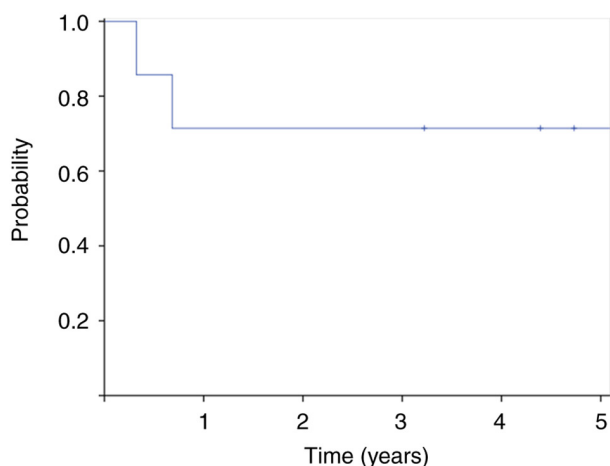


Figure 2. Overall survival. Survival rates were estimated using the Kaplan-Meier method. Five-year overall survival rate was 71%.

biopsy revealed myxoid liposarcoma. Hip disarticulation was performed four days later, and all abnormal values of laboratory examinations improved after surgery. Antibiotics were changed to cefazolin after surgery, which was given for seven days.

Case 6. The patient was a 78-year-old man who was referred to our institution for further examination of MW from a myxofibrosarcoma in the upper arm. He had a large tumor in his right upper arm with odor and exudate on the wounded overlying skin (Fig. 4A). MRI revealed a mass with high intensity on T2-weighted images (Fig. 4B and C). Laboratory examination showed elevation of, CRP (15.1 mg/dl), low value of Hgb (9.5 g/dl) and Alb (2.5 g/dl). Culture from the wound revealed polymicrobial etiology: *Enterobacter cloacae*, *Acinetobacter baumannii* complex, *Stenotrophomonas maltophilia*, and *Peptostreptococcus asaccharolyticus*. Wide resection and free flap (latissimus dorsi flap) were performed. Cefazolin sodium was given for 7 days postoperatively. Improvement was seen in abnormal laboratory values after surgery. Lymph node metastasis was documented four years later, which was excised, and the patient had remained disease-free at the last follow up.

Discussion

Fromantin *et al* identified polymicrobial flora composed of 54 different bacterial types in the microbiological analyses of MWs of breast cancer. The study reported that the average number of bacteria per patient was 3.6 aerobic species and 1.7 anaerobic species, with a predominance of *Staphylococcus aureus*, *Pseudomonas aeruginosa*, *Corynebacterium striatum*, and *Proteus mirabilis* (4). Lutchminarian *et al* reported that the most common pathogen in the wound was *Staphylococcus aureus* (33%), followed by β -hemolytic *Streptococcus* (17%) and *Pseudomonas aeruginosa* (17%) in patients with MWs of STS (13). Similar to these reports, we found that MSSA was the most commonly isolated species, followed by *Pseudomonas aeruginosa* and *Enterococcus faecalis*. Moreover, we first showed that MWs of STS were polymicrobial in etiology, with an average number of bacteria

per patient was 2.6, including 1 aerobic species and 1.6 anaerobic species.

We found that SSI occurred in three of the seven patients (43%). This high rate of SSI is in line with a previous report in which SSI was found to be in as many as 26-42% of patients with MWs (15,18). There are numerous reports investigating the risk factors associated with SSI (28-30). According to the international consensus on orthopedic infection by the Musculoskeletal Infection Society, the risk of developing SSI is influenced by several factors, such as malignancy, malnutrition, preoperative anemia, age (>75 years), and a history of diabetes mellitus (DM) (28). In a systematic review, risk factors associated with SSI among surgical patients include high body mass index, National Nosocomial Infections Surveillance risk index (contamination class, American Society of Anesthesiologists class, and operative time), and a history of DM (30). In this study, patients with MWs had multiple accompanying factors, including malignancy (100%), contaminated or dirty wound (100%), malnutrition with low albumin (86%), and anemia (57%), which would lead to a high SSI rate. Hoshi *et al* reported that *Candida* species were detected most commonly, followed by *Pseudomonas aeruginosa* and *Enterococcus* species from the infected surgical site (18). In this study, we found *Pseudomonas aeruginosa* in two patients and MSSA in one patient from the infected surgical site. We compared the bacterium both in the preoperative wound and the surgical site and found that two of the three patients with SSI had identical isolates on both sites. These three patients had received perioperative prophylaxis. However, it was unclear whether the perioperative antibiotic prophylaxis could be attributed in preventing SSI in patients with MWs. The limited efficacy of systemic antibiotic injections may be due to the necrotic tissue, avascular environment of MWs, and the biofilm (31). Once bacteria adhere to the surface of the tissue or prosthetic materials, they form microcolonies (31-33). Next, they produce an extracellular polymeric matrix and encase themselves in the matrix (33). Bacteria that form biofilms and colonize or infect medical devices or wounds are particularly difficult to treat as biofilms are highly resistant to antibiotics (32-34). Several pharmaceutical interventions for reducing the microbial concentration in the wound have been investigated in patients with MWs to avoid wound contamination of potentially colonized bacterium (32-34). Recently, the use of metronidazole, which is deemed effective in eliminating anaerobes, has been shown to be effective in improving odor in 83-95% of patients (35,36). In a multicenter, open-label, phase III study conducted among patients with unresectable breast cancer, head and neck cancer, skin cancer, and STS, Watanabe *et al* reported that 95% of the patients experienced relief with respect to severity of odor by using topical metronidazole 0.75% gel (36). Mohs' paste has also been shown to be effective for controlling MWs from various malignant tumors, including STS (6-8). It is mainly composed of zinc chloride and was originally developed for curative treatment via repeated fixation and excision until there is complete removal of the tumor (6). Hoshi *et al* reported success in the combined treatment using Mohs' paste and neoadjuvant chemotherapy for undifferentiated pleomorphic sarcoma arising in the right chest wall (9). Systemic chemotherapy and Mohs' paste led to significant shrinkage of the tumor and received wide resection

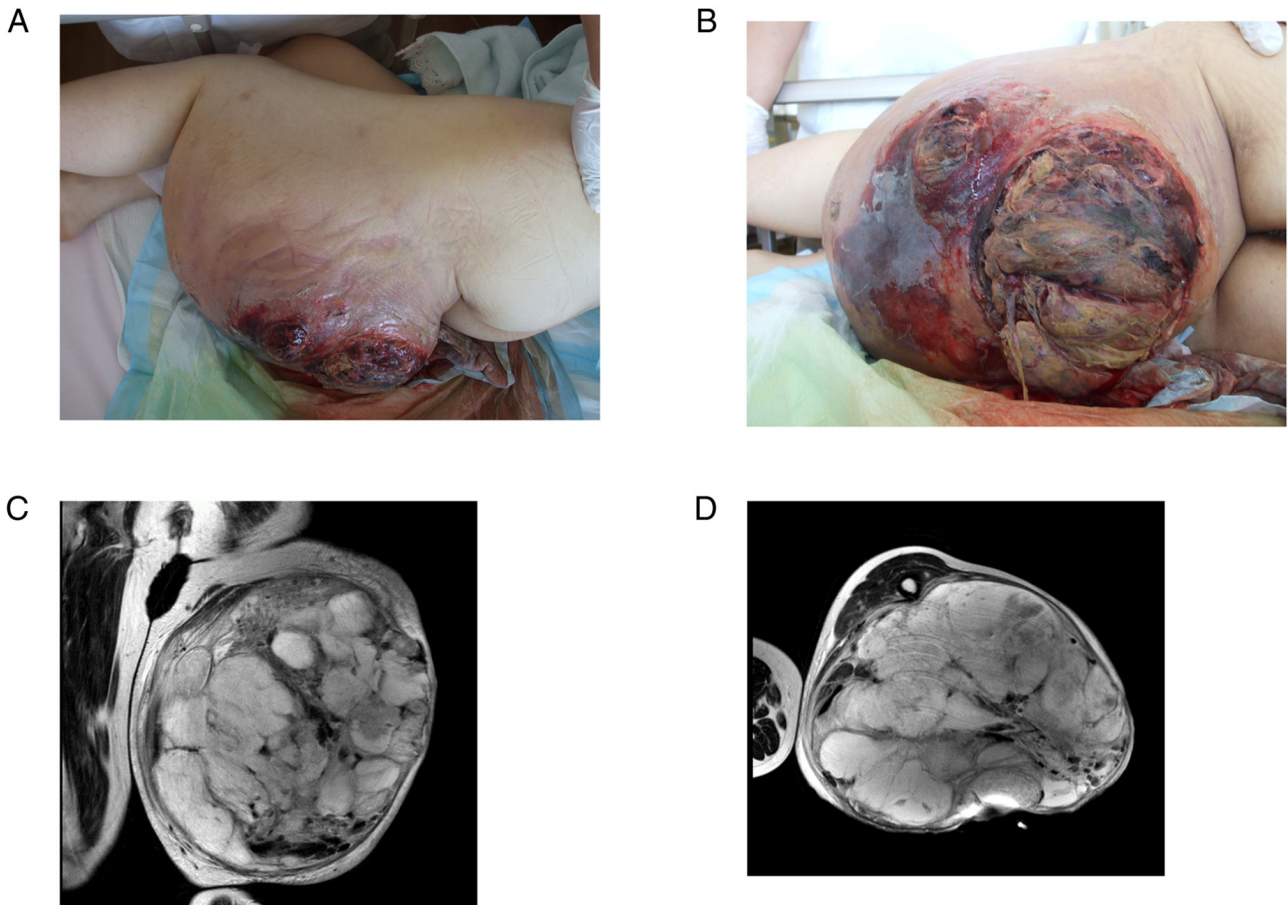


Figure 3. A patient with sepsis. A 42-year-old woman with sepsis from the malignant wound of myxoid liposarcoma in the thigh. (A and B) The skin overlying the large tumor in the left thigh was bleeding and had a foul odor and exudate. (C and D) MRI revealed a mass with high intensity on T2-weighted images.

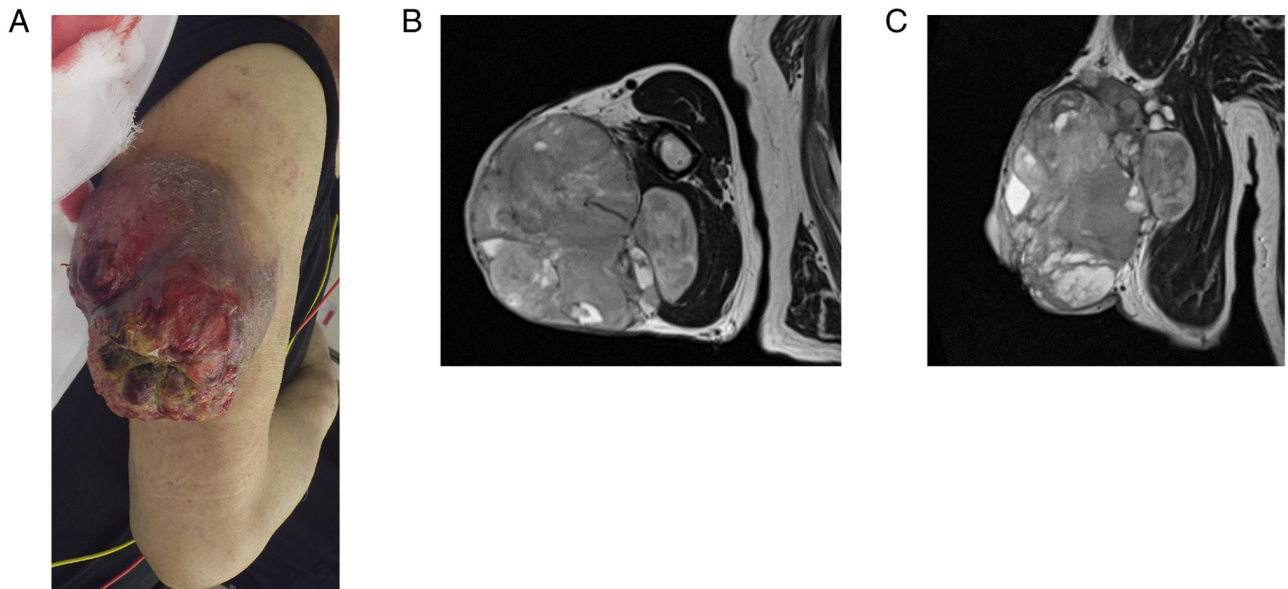


Figure 4. A 78-year-old man with malignant wound from a myxofibrosarcoma in the upper arm. (A) He had a large tumor in his right upper arm with odor and exudate on the wounded overlying skin. (B and C) MRI revealed a mass with high intensity on T2-weighted images.

and reconstruction with a rectus abdominis musculocutaneous flap. In this study, we did not utilize these agents prior to surgery. As patients with MWs frequently require soft tissue

coverage for large defects after resection, it is necessary to adjust the schedule of plastic surgery, as it is not possible to remove it immediately. The pharmacologic agents may be

considered for control of both tumor and the infection when surgery cannot be performed immediately (33). The efficacy of these agents for reducing SSI should be further investigated using randomized controlled trials in the future.

We found that patients with MWs of STS had various symptoms. They had bleeding (71%), exudated (71%), or developed an odor (43%) at the initial presentation. However, these symptoms disappeared after surgery. All except for one patient experienced pain at the site of the MWs on initial presentation, with an average NRS of 4.4. The NRS decreased after surgery, with an average of 1.4 ($P=0.14$) and 0.6 ($P=0.04$) one and two weeks after surgery, respectively. All but one patient had pain at the surgical site at the last follow-up. Two patients presented with fever, which improved one week after surgery. Regarding laboratory results, the patients had elevated CRP level (71%), anemia (57%), malnutrition with low albumin (86%), and renal or liver disturbances (14-29%). These abnormal laboratory values could have been due to the complex effect of both the tumor and infection. We found that these abnormal laboratory values were reversible, as most of them improved after surgery. Then, we think the tumor with MWs should be excised completely if possible.

In this study, one patient was diagnosed with sepsis and required emergency treatment. Although she had poor general condition at the first presentation to the hospital, RBC transfusion and infusion could improve the hemodynamics. In case of MWs at the first presentation, the microbiological condition is sometimes underrecognized or underestimated because physicians tend to focus on investigating the oncological condition of the patient (9). However, physicians should consider that MWs can potentially turn into a life-threatening condition when complicated by sepsis. Clinical parameters, such as vital signs, laboratory results, bacterial culture from the wound should be examined promptly to manage the patients adequately.

We found some studies which highlight the oncological implications of MWs of STS (15-18). In these previous reports, patients with MWs of STS presented with high proportion of metastases (20-33%) and had a poor prognosis with a 5-year OS of 15-26% (15-18). Potter *et al* compared the oncological outcomes between the MWs group and the non-MWs group and found that patients with MWs from STS presented with a higher rate of metastases (33% in the MWs group and 9% in the non-MWs group; $P=0.003$) and had a poor prognosis (5-year OS of 20% in the MWs group and 63% in the non-MWs group; $P<0.0001$) (16). Similarly, Parry *et al* reported that prognosis of patients with MWs was poor compared to that of without MWs (5-year OS of 15% in the MWs group and 66% in the non-MWs group; $P<0.0001$) (17). They also reported that MW was associated with poor prognosis as an independent risk factor. In line with previous reports (15-18), three out of seven patients in our study had distant metastases during presentation. All patients had high-grade sarcoma and a relatively large tumor size (>5 cm), and three patients died because of the disease before the last follow-up, with a 5-year OS rate of 71%. However, limb salvage may be difficult for bulky tumors, which often increases the risk of amputation (20-33%). In previous reports, 48-60% of patients required plastic surgery, including skin graft or flap in limb-sparing surgery (15-18). In the current study, five patients initially underwent limb-sparing surgery, and four patients required skin graft or flap.

This study has some limitations. First, it has a small sample size of only seven patients. MW occur in 3-4% STS. Therefore, it was difficult to include enough cases for this study. Second, we did not investigate the biofilms in the MWs. Since, this is a retrospective study, we had not investigated the biofilms in this series of the patients. Third, due to the retrospective study we had not investigated the preoperative microbiological samples from the necrotic zone of the wound in all patients. However, we showed that the MWs of STS had a polymicrobial etiology with an average number of bacteria per patient was 2.6, and predominance of *Staphylococcus aureus* and *Pseudomonas aeruginosa*, consistency with previous reports. Fourth, we could not determine the effectiveness of selected antibiotics in preventing SSI in patients with MWs, since not all patients received perioperative prophylaxis. Their effectiveness in preventing SSI needs to be investigated in the future. Despite these limitations, this is the first report investigating perioperative clinical symptoms, laboratory examination, and the bacterial landscape in patients with MWs of STS.

In conclusion, MW is composed of high-grade sarcoma and polymicrobial colonization. Physicians should consider that MWs can possibly lead to life-threatening conditions when complicated by sepsis; therefore, clinical and laboratory examinations should be performed promptly to manage patients adequately. Although patients presented with various symptoms and showed abnormal values in laboratory examination, they might improve after surgical resection. The effectiveness of the selected antibiotics based on the results of the preoperative culture in preventing SSI needs to be investigated in the future in patients with MWs.

Acknowledgements

Not applicable.

Funding

No funding was received.

Availability of data and materials

The datasets used and/or analyzed during the current study are available from the corresponding author on reasonable request.

Authors' contributions

EN, TK, and TO designed the study. EN, TF and TK treated the patients. EN, HK and TI collected and analyzed data. EN and TK confirmed the authenticity of all the raw data. All authors have read and approved the final manuscript.

Ethics approval statement and consent to participate

This retrospective chart review study involving human participants was in accordance with the ethical standards of the institutional and national research committee and with the 1964 Helsinki Declaration and its later amendments or comparable ethical standards. The Human Investigation Committee (IRB) of Okayama University Hospital approved this study

(approval no. K2104-020). Patients provided written informed consent for their participation in this study.

Patient consent for publication

Written informed consent was obtained from each participant included in this study.

Competing interests

The authors declare that they have no competing interests.

References

- Alexander S: Malignant fungating wounds: Epidemiology, aetiology, presentation and assessment. *J Wound Care* 18: 273-274, 2009.
- Alvarez O, Kalinski C, Nusbaum J, Hernandez L, Pappous E, Kyriannis C, Parker R, Chrzanowski G and Comfort CP: Incorporating wound healing strategies to improve palliation (symptom management) in patients with chronic wounds. *J Palliat Med* 10: 1161-1189, 2007.
- Vardhan M, Flaminio Z, Sapru S, Tilley CP, Fu MR, Comfort C, Li X and Saxena D: The microbiome, malignant fungating wounds, and palliative care. *Front Cell Infect Microbiol* 9: 373, 2019.
- Fromantin I, Seyer D, Watson S, Rollot F, Elard J, Escande MC, De Rycke Y, Kriegel I and Larreta Garde V: Bacterial floras and biofilms of malignant wounds associated with breast cancers. *J Clin Microbiol* 51:3368-3373, 2013.
- Finlayson K, Teleni L and McCarthy AL: Topical opioids and antimicrobials for the management of pain, infection, and infection-related odors in malignant wounds: A systematic review. *Oncol Nurs Forum* 44: 626-632, 2017.
- Mohs FE, Sevringhaus EL and Schmidt ER: Conservative amputation of gangrenous parts by chemosurgery. *Ann Surg* 114: 274-282, 1941.
- Mohs FE: Chemosurgical treatment of cancer of the extremities and trunk; a microscopically controlled method of excision. *Arch Surg* (1920) 57: 818-832, 1948.
- Nemoto K, Okamoto M, Kito M, Aoki K, Suzuki S, Takazawa A, Yoshimura Y and Kato H: Combined treatment using Mohs' paste and neoadjuvant chemotherapy for giant gluteal soft tissue sarcoma with malignant fungating wound: A case report. *J Surg Case Rep* 2019: rjz137, 2019.
- Hoshi M, Iwai T, Oebisu N and Nakamura H: Successful pre-operative local control of skin exposure by sarcoma using combination of systemic chemotherapy and Mohs' chemosurgery. *World J Surg Oncol* 18: 36, 2020.
- Bower M, Stein R, Evans TR, Hedley A, Pert P and Coombes RC: A double-blind study of the efficacy of metronidazole gel in the treatment of malodorous fungating tumours. *Eur J Cancer* 28A: 888-889, 1992.
- Kalinski C, Schnepf M, Laboy D, Hernandez L, Nusbaum J, McGrinder B, Comfort C and Alvarez OM: Effectiveness of a topical formulation containing metronidazole for wound odor and exudate control. *Wounds* 17: 84-90, 2005.
- Ashford R, Plant G, Maher J and Teare L: Double-blind trial of metronidazole in malodorous ulcerating tumours. *Lancet* 1: 1232-1233, 1984.
- Lutchminarian K and Clarke DL: The microbiology of ulcerative skin cancers: Does the presence of pathogenic bacteria increase the risk of postoperative complications? *S Afr J Surg* 59: 25a-25e, 2021.
- Elfallal AH, Laimon YN and Emile SH: Giant angioliopoma of the back complicated with ulceration and sepsis: Unusual presentation of a rare benign tumour. *Ann R Coll Surg Engl* 101: e91-e93, 2019.
- Okajima K, Kobayashi H, Okuma T, Arai S, Zhang L, Hirai T, Ishibashi Y, Ikegami M, Shinoda Y, Akiyama T, *et al*: Prognosis and surgical outcome of soft tissue sarcoma with malignant fungating wounds. *Jpn J Clin Oncol* 51: 78-84, 2021.
- Potter BK, Adams SC, Qadir R, Pitcher JD and Temple HT: Fungating soft-tissue sarcomas. Treatment implications and prognostic importance of malignant ulceration. *J Bone Joint Surg Am* 91: 567-574, 2009.
- Parry M, Evans S, Sugath S, Wafa H, Jeys L and Grimer R: Fungation in soft tissue sarcomas is associated with poor survival. *Int Orthop* 41: 2613-2618, 2017.
- Hoshi M, Oebisu N, Iwai T, Ieguchi M and Nakamura H: Clinical course of soft tissue sarcomas presenting as malignant wounds. *J Orthop Sci* 24: 1088-1093, 2019.
- Fletcher CD, Bridge JA, Hogendoorn P and Mertens F: WHO Classification of Tumours of soft tissue and bone. 4th edition. IARC Press, Lyon, 2013.
- Guillou L, Coindre JM, Bonichon F, Nguyen BB, Terrier P, Collin F, Vilain MO, Mandard AM, Le Doussal V, Leroux A, *et al*: Comparative study of the National cancer institute and french federation of cancer centers sarcoma group grading systems in a population of 410 adult patients with soft tissue sarcoma. *J Clin Oncol* 15: 350-362, 1997.
- Mangram AJ, Horan TC, Pearson ML, Silver LC and Jarvis WR: Guideline for prevention of surgical site infection, 1999. Hospital infection control practices advisory committee. *Infect Control Hosp Epidemiol* 20: 250-278, 1999.
- Egi M, Ogura H, Yatabe T, Atagi K, Inoue S, Iba T, Kakihana Y, Kawasaki T, Kushimoto S, Kuroda Y, *et al*: The Japanese clinical practice guidelines for management of sepsis and septic shock 2020 (J-SSCG 2020). *J Intensive Care* 9: 53, 2021.
- Rhodes A, Evans LE, Alhazzani W, Levy MM, Antonelli M, Ferrer R, Kumar A, Sevransky JE, Sprung CL, Nunnally ME, *et al*: Surviving sepsis campaign: International guidelines for management of sepsis and septic shock: 2016. *Crit Care Med* 45: 486-552, 2017.
- Seymour CW, Liu VX, Iwashyna TJ, Brunkhorst FM, Rea TD, Scherag A, Rubenfeld G, Kahn JM, Shankar-Hari M, Singer M, *et al*: Assessment of Clinical criteria for sepsis: For the Third International consensus definitions for sepsis and septic shock (Sepsis-3). *JAMA* 315: 762-774, 2016.
- Pandharipande PP, Sanders N, Jacques P, Ely EW and Shintani A: Calculating SOFA scores when arterial blood gases are not available: Validating SpO₂/FIO₂ ratios for imputing PaO₂/FIO₂ ratios in the SOFA scores. *Crit Care Med* 34: A1, 2006.
- Pasricha SR, Colman K, Centeno-Tablante E, Garcia-Casal MN and Peña-Rosas JP: Revisiting WHO haemoglobin thresholds to define anaemia in clinical medicine and public health. *Lancet Haematol* 5: e60-e62, 2018.
- Wittekind C, Compton C, Quirke P, Nagtegaal I, Merkel S, Hermanek P and Sobin LH: A uniform residual tumor (R) classification: Integration of the R classification and the circumferential margin status. *Cancer* 115:3483-3488, 2009.
- Zainul-Abidin S, Amanatullah DF, Anderson MB, Austin M, Barretto JM, Battenberg A, Bedard NA, Bell K, Blevins K, Callaghan JJ, *et al*: General assembly, prevention, host related general: Proceedings of International consensus on orthopedic infections. *J Arthroplasty* 34: S13-S35, 2019.
- Chauveaux D: Preventing surgical-site infections: Measures other than antibiotics. *Orthop Traumatol Surg Res* 101 (Suppl 1): S77-S83, 2015.
- Korol E, Johnston K, Waser N, Sifakis F, Jafri HS, Lo M and Kyaw MH: A systematic review of risk factors associated with surgical site infections among surgical patients. *PLoS One* 8: e83743, 2013.
- Ramasubbu DA, Smith V, Hayden F and Cronin P: Systemic antibiotics for treating malignant wounds. *Cochrane Database Syst Rev*: Aug 24, 2017 (Epu).
- Schierle CF, De la Garza M, Mustoe TA and Galiano RD: Staphylococcal biofilms impair wound healing by delaying reepithelialization in a murine cutaneous wound model. *Wound Repair Regen* 17: 354-359, 2009.
- Salisbury AM, Woo K, Sarkar S, Schultz G, Malone M, Mayer DO and Percival SL: Tolerance of biofilms to antimicrobials and significance to antibiotic resistance in wounds. *Surg Technol Int* 33: 59-66, 2018.
- Hughes G and Webber MA: Novel approaches to the treatment of bacterial biofilm infections. *Br J Pharmacol* 174: 2237-2246, 2017.
- Villela-Castro DL, Santos VLCCG and Woo K: Polyhexanide versus metronidazole for odor management in malignant (fungating) wounds: A double-blinded, randomized, clinical trial. *J Wound Ostomy Continence Nurs* 45: 413-418, 2018.
- Watanabe K, Shimo A, Tsugawa K, Tokuda Y, Yamauchi H, Miyai E, Takemura K, Ikoma A and Nakamura S: Safe and effective deodorization of malodorous fungating tumors using topical metronidazole 0.75% gel (GK567): A multicenter, open-label, phase III study (RDT.07.SRE.27013). *Support Care Cancer* 24: 2583-2590, 2016.

