

Radiofrequency catheter ablation for treatment of premature ventricular contractions triggering ventricular fibrillation from the right ventricular outflow tract in a patient with early repolarization syndrome



Jun Kakahara, MD, Masahiko Takagi, MD, PhD, FHRS, Yusuke Hayashi, MD, Hiroaki Tatsumi, MD, PhD, Atsushi Doi, MD, PhD, Minoru Yoshiyama, MD, PhD

From the Department of Cardiovascular Medicine, Osaka City University Graduate School of Medicine, Osaka, Japan.

Introduction

Ventricular fibrillation (VF) triggered by premature ventricular contraction (PVC) most frequently originates from the His-Purkinje system and right ventricular outflow tract (RVOT) in patients with idiopathic VF. Radiofrequency catheter ablation (RFCA) of triggering PVCs is reportedly useful for the successful elimination of VF.^{1–3}

The diagnosis of early repolarization (ER) syndrome is made on the basis of the presence of J-point elevation ≥ 1 mm in ≥ 2 contiguous inferior and/or lateral leads of a standard 12-lead electrocardiogram (ECG) in patients resuscitated from otherwise unexperienced VF or polymorphic ventricular tachycardia (VT).⁴

However, the efficacy of RFCA of triggering PVCs in ER syndrome has not been fully evaluated. We report a case in which successful RFCA of triggering PVCs eliminated a VF episode in a patient with ER syndrome.

Case report

A 37-year-old man was admitted to our hospital after being resuscitated using an automated external defibrillator for cardiac arrest due to VF. He experienced sudden syncope and collapsed at 7:00 PM while performing desk work. Cardiopulmonary resuscitation was performed immediately by his colleague. The emergency medical service team arrived at the place of his cardiac arrest and applied an automated external defibrillator. The documented presenting rhythm was VF, which was successfully terminated by the defibrillator shock. The patient experienced syncope at the

age of 35 without further examination and was not taking any medicine. There was no familial history of syncope or sudden cardiac death. On admission, a 12-lead ECG showed J-point elevation ≥ 1 mm with notching and slurring in leads I and V₄ to V₆ (Figure 1A). The maximum J-point amplitude was 0.8 mV in lead V₄. Apart from these ECG abnormalities, further examination with coronary angiogram and cardiac magnetic resonance did not reveal any abnormality. An acetylcholine provocation test showed no coronary artery spasms. A pilsicainide (a pure sodium channel blocker agent) provocation test did not reveal Brugada-type ECG pattern. During hospitalization, a 12-lead ECG revealed monomorphic PVC with left bundle branch block morphology and inferior axis (Figure 1B), and ECG monitoring of lead II showed monomorphic PVC and ventricular bigeminy (Figure 1C). Daily fluctuations of J-wave amplitude and morphology were observed (Figure 2A–D). Finally, the patient was diagnosed with ER syndrome and was scheduled for an implantable cardioverter-defibrillator (ICD). However, in the middle of night of his 22nd day of hospitalization, he experienced VF triggered by the same monomorphic PVC (Figure 1C). The VF was successfully converted to sinus rhythm with an external direct current shock at 200 J. ECG monitoring revealed that the QRS morphology of the first beat in this VF episode was identical to that of the previously recorded PVC. Continuous lidocaine infusion was started but could not suppress nonsustained polymorphic VT triggered by the same PVC. After ICD implantation, we performed RFCA of the monomorphic PVC responsible for the triggering of VF. The clinical PVC (PVC1) with left bundle branch block and inferior axis QRS morphology appeared frequently. A decapolar mapping catheter was positioned at the His bundle region. An ablation catheter (NaviStar ThermoCool SmartTouch; Biosense Webster, Inc, Diamond Bar, CA) was advanced into the right ventricle through the femoral vein using an 8.5 F Agilis sheath (St Jude Medical, Inc). Three-dimensional

KEYWORDS Early repolarization syndrome; Ventricular fibrillation; Catheter ablation; Premature ventricular contraction; Right ventricular outflow tract (Heart Rhythm Case Reports 2016;2:342–346)

Address reprints and correspondence: Masahiko Takagi, MD, PhD, FHRS, Department of Cardiovascular Medicine, Osaka City University Graduate School of Medicine, 1-4-3Asahi-machi, Abeno-ku, Osaka 545-8585, Japan. E-mail address: m7424580@msic.med.osaka-cu.ac.jp.

KEY TEACHING POINTS

- The high amplitude of the J-point elevation, horizontal ST segment after early repolarization (ER), and lower T/R ratio may be associated with a high risk of arrhythmic death.
- Catheter ablation for ventricular fibrillation (VF)-triggering monomorphic premature ventricular contractions (PVCs), originating far from the J wave location, may be effective in patients with ER syndrome.
- Radiofrequency catheter ablation (RFCA) for PVCs from the right ventricular outflow tract (RVOT) has a high success rate; thus, RFCA may be considered for VF-triggering PVCs from the RVOT even in patients with ER syndrome.

electroanatomical (CARTO3 system; Biosense Webster Inc, St. Paul, MN) activation mapping of PVC1 was performed in the right ventricle. At a posterolateral site of the RVOT, the earliest activation was recorded at 20 ms before QRS onset and a perfect pace map was shown (Figure 3A). Radiofrequency application at this region was delivered at maximum 35 W of power, and PVC1 disappeared after 5.8 seconds of ablation. However, another type of PVC (PVC2) appeared, with slightly different QRS morphology from that of PVC1. At a posterior attachment of the RVOT, the earliest activation was recorded at 27 ms before QRS onset and a good pace map was shown (Figure 3B). Radiofrequency application at this region was delivered at maximum 35 W of power, and PVC2 disappeared after 6.2 seconds of ablation. However, after successful RFCA, the J-wave pattern did not disappear. During a follow-up of 18 months, the 24-hour Holter ECG recording revealed 1 PVC beat per day; there was no recurrence of VF without taking medication.

Discussion

The major finding in the present case was that RFCA for VF-triggering PVCs originating from the RVOT area successfully suppressed the recurrence of VF in a patient with ER syndrome but did not eliminate the J wave. To the best of our knowledge, this is the first report of VF-triggering PVCs originating from the RVOT that were treated successfully with RFCA in a patient with ER syndrome, with J-wave elevation in the lateral leads.

The ER syndrome, visible as a J-point elevation on 12-lead ECG, was formerly thought to be a benign entity. However, Haïssaguerre et al⁵ reported a 41% increased risk of arrhythmia recurrence in patients with idiopathic VF associated with ER. According to the Heart Rhythm Society/European Heart Rhythm Association/Asia Pacific Heart Rhythm Society (HRS/EHRA/APHRS) consensus statement, ER syndrome is diagnosed on the basis of the presence of J-point elevation ≥ 1 mm in ≥ 2 contiguous inferior

and/or lateral leads of a standard 12-lead ECG in patients resuscitated from otherwise unexperienced VF or polymorphic VT.⁴ In the present case, ECG, cardiac magnetic resonance imaging, and coronary angiography with acetylcholine provocation revealed no structural heart diseases. The pilsicainide provocation test did not induce a type 1 Brugada ECG pattern. The 12-lead ECG on admission showed J-point elevation ≥ 1 mm in leads I and V₄ to V₆, and the J-wave amplitude and morphology showed marked daily fluctuation. Therefore, we diagnosed this patient with ER syndrome. Moreover, this patient had high J-wave amplitude in the lateral leads (maximal J-wave amplitude in lead V₄ was 0.8 mV: 5 mm = 1 mV) and horizontal ST segments in leads I and V₆ after the J point. Tikkanen et al⁶ reported ER patterns associated with high amplitude (> 2 mm) accompanied by an increased risk of arrhythmic death. Additionally, Rosso et al⁷ reported that the combination of J wave with descending or horizontal ST segments increased cardiac events for patients with idiopathic VF. Furthermore, Roten et al⁸ reported that patients with malignant ER have a higher prevalence of low-amplitude T waves, lower T/R ratio (lead II or V₅), and longer QTc interval. In this case, the T wave was low amplitude (0.4 mV), the T/R ratio was low (0.2), and the QTc interval was longer (499 ms) in lead V₅. Therefore, ER pattern and the type of ST segment in this case may be associated with high risk of arrhythmic death.

In the present case, we found that VF-triggering PVCs originated from the posterior and posterolateral portion of the RVOT, and we successfully applied RFCA to the VF-triggering PVCs to eliminate VF. Haïssaguerre et al¹ reported VF-triggering PVCs originating predominantly from the Purkinje system and the RVOT in patients with idiopathic VF, as well as the feasibility of eliminating or decreasing the incidence of VF by RFCA for the PVCs. Nogami² and Noda et al³ also reported the efficacy of RFCA of VF-triggering PVCs arising from the RVOT in patients with idiopathic VF. However, these reports did not investigate the presence of J waves. Yamashina et al⁹ reported a high prevalence of J waves among idiopathic RVOT-VT/PVC patients, and the presence of J wave was associated with enhanced arrhythmogenicity. However, they demonstrated that the significance of J wave was limited in terms of prognosis and VF.

The pathophysiological basis of ER is not fully understood. Koncz et al¹⁰ showed that an accentuation of transmural gradients in the left ventricular (LV) wall underlay the repolarization abnormalities responsible for ER syndrome, giving rise to J-point elevation, and that higher intrinsic levels of I_{to} in the inferior left ventricle provided the greater vulnerability to VF. Moreover, Ghosh et al¹¹ also identified short activation–recovery intervals and a marked dispersion of repolarization in the inferior and lateral regions of the left ventricle. On the other hand, another hypothesis for the mechanism leading to ER suggested association between localized depolarization and repolarization abnormalities. Recently, Latcu et al¹² reported that RFCA of the inferoseptal LV substrate was effective in suppressing electrical storms and disappeared J waves in inferior leads in a patient with ER syndrome. In the present case, we did not detect

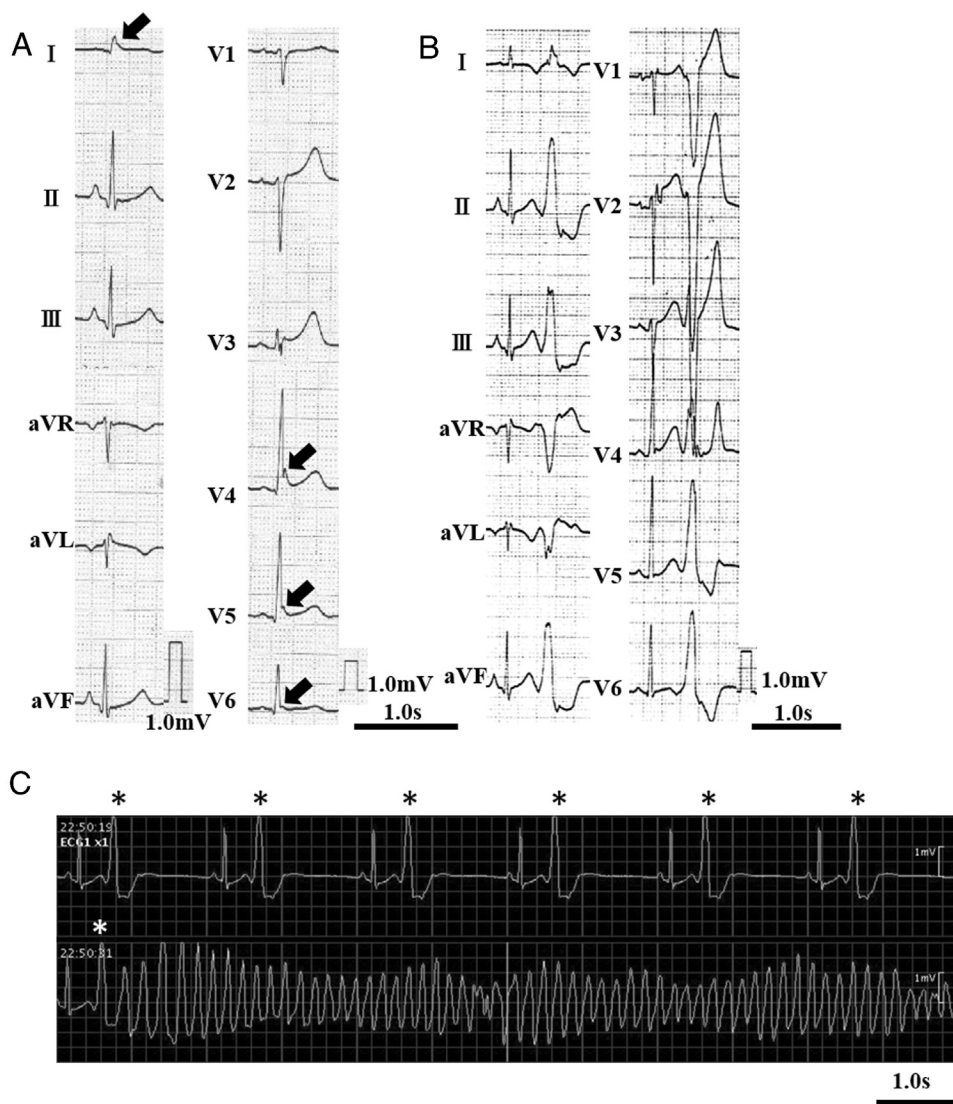


Figure 1 A: The 12-lead electrocardiogram (ECG) on admission. The J wave observed in lead I shows slurring, while those in V₄ to V₆ show notching (black arrows). The maximum J-point amplitude is 0.8 mV in lead V₄. B: Spontaneous clinical premature ventricular contraction (PVC) with left bundle branch block morphology and inferior axis during hospitalization. C: An ambulatory monitoring ECG in lead II shows monomorphic PVC and ventricular bigeminy (asterisk). A PVC with the same morphology induced ventricular fibrillation.

abnormal potentials at the successful RFCA site of PVCs in the posterolateral site of the RVOT, and it remains unknown whether there was local abnormal ventricular activity in the lateral left ventricle, because we did not perform endocardial and epicardial mapping in the left ventricle. However, we succeeded in suppressing VF recurrence by triggering PVCs originating from the RVOT area; nevertheless, the ER in the lateral leads did not disappear. Therefore, in the present case, we speculated that PVCs originating from RVOT might trigger VF, and that the vulnerable substrate linked to repolarization and/or depolarization abnormalities in the lateral LV region was responsible for the maintenance of VF. During a follow-up of 18 months, 24-hour Holter ECG recording and ICD telemetry revealed neither triggering PVCs nor VF recurrence without antiarrhythmic drugs. However, careful management of VF recurrence is necessary owing to presence of ER in the lateral leads.

The EHRA/HRS/APHRS expert consensus on ventricular arrhythmias recommends that RFCA of VTs or triggering focus of VF should be considered in patients with VT/VF storms when adequate experience is available.¹³ The success of RFCA for treatment of idiopathic VF initiated by PVCs from the RVOT has been reported. Thus, RFCA may be considered for treatment of VF-triggering PVCs to minimize the risk of recurrent VF and frequency of ICD discharge even in patients with ER syndrome.

Conclusion

The application of RFCA for VF-triggering PVCs remote from the location of J waves successfully suppressed the recurrence of VF. Thus, RFCA for the VF-triggering PVC may minimize arrhythmic events in ER syndrome.

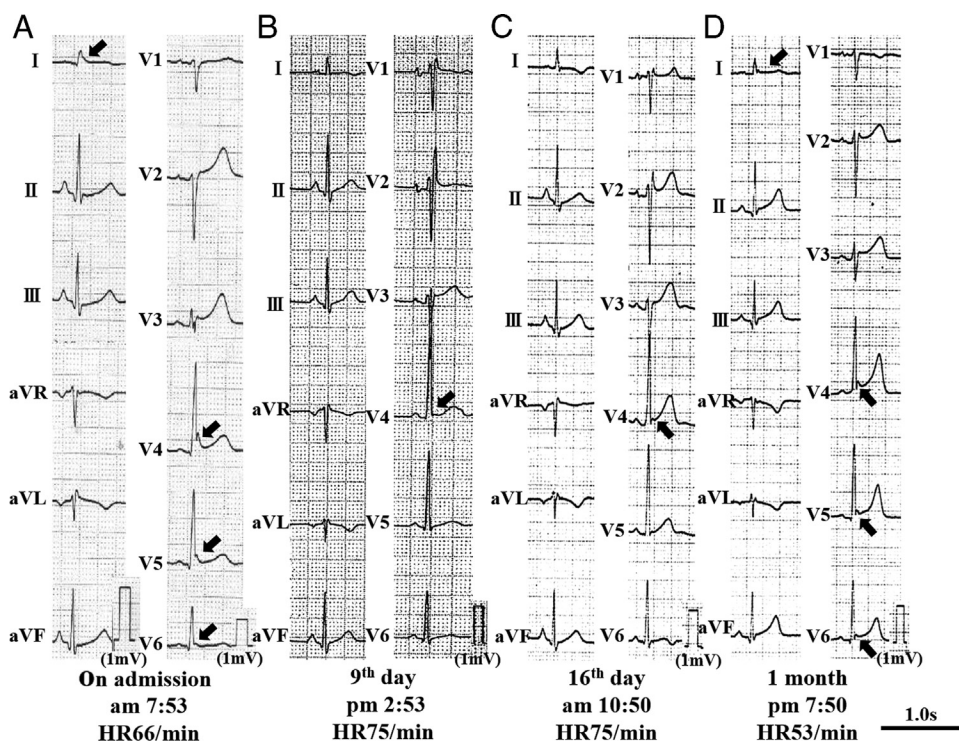


Figure 2 Daily J-wave fluctuations (black arrows) during hospitalization: **A**: on admission; **B**: on day 9 of hospitalization; **C**: on day 16 of hospitalization; **D**: at 1 month of hospitalization. 12-ECG on admission showed more prominent J waves in lateral leads, but J waves disappeared on day 9, and reappeared on day 16 and increased amplitude at 1 month of hospitalization.

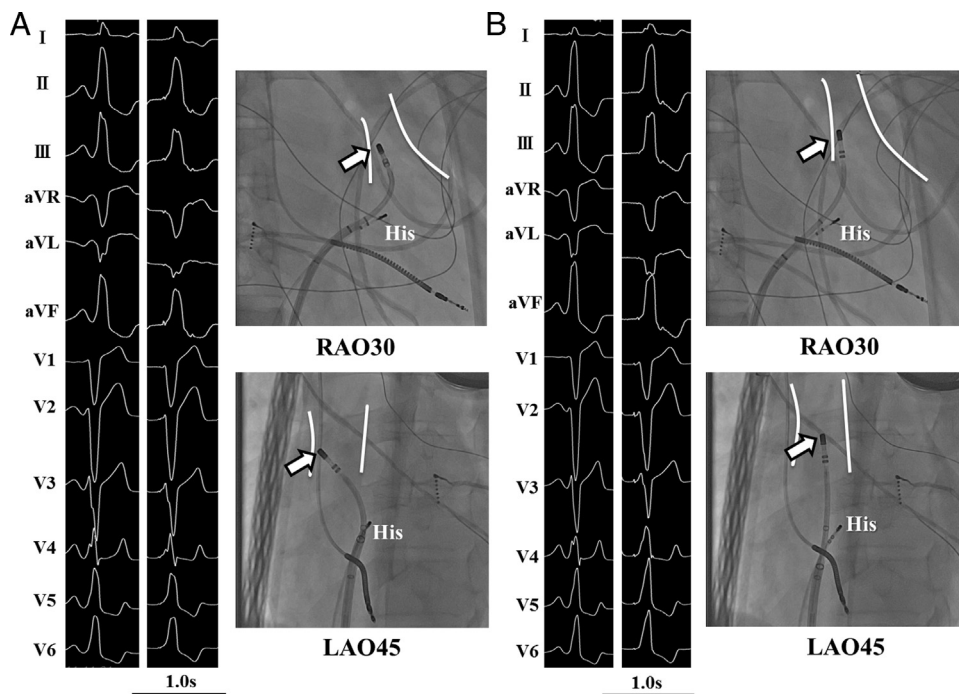


Figure 3 **A**: The 12-lead electrocardiograms (ECGs) of spontaneous clinical PVC1 (left panel) and paced beat (middle panel) and successful ablation site under fluoroscopy (right panel; white arrow) at the posterolateral site of the right ventricular outflow tract (RVOT). **B**: The 12-lead ECGs of spontaneous clinical PVC2 (left panel) and paced beat (middle panel) and successful ablation site under fluoroscopy (right panel; white arrow) at the posterior attachment of the RVOT. RAO = right anterior oblique image; LAO = left anterior oblique image; His = His-bundle catheter.

References

1. Haïssaguerre M, Shoda M, Jaïs P, et al. Mapping and ablation of idiopathic ventricular fibrillation. *Circulation* 2002;106:962–967.
2. Nogami A. Trigger elimination of polymorphic ventricular tachycardia and ventricular fibrillation by catheter ablation: trigger and substrate modification. *J Biomed Res* 2015;29:44–51.
3. Noda T, Shimizu W, Taguchi A, et al. Malignant entity of idiopathic ventricular fibrillation and polymorphic ventricular tachycardia initiated by premature extrasystoles originating from the right ventricular outflow tract. *J Am Coll Cardiol* 2005;46:1288–1294.
4. Priori SG, Wilde AA, Horie M, et al. HRS/EHRA/APHRS expert consensus statement on the diagnosis and management of patients with inherited primary arrhythmia syndromes. *Europace* 2013;15:1389–1406.
5. Haïssaguerre M, Derval N, Sacher F, et al. Sudden cardiac arrest associated with early repolarization. *N Engl J Med* 2008;358:2016–2023.
6. Tikkanen JT, Junttila MJ, Anttonen O, et al. Early repolarization: electrocardiographic phenotypes associated with favorable long-term outcome. *Circulation* 2011;123:2666–2673.
7. Rosso R, Glikson E, Belhassen B, et al. Distinguishing “benign” from “malignant early repolarization”: the value of the ST-segment morphology. *Heart Rhythm* 2012;9:225–229.
8. Roten L, Derval N, Maury P, et al. Benign vs malignant inferolateral early repolarization: focus on the T wave. *Heart Rhythm*. 2016;13:894–902.
9. Yamashina Y, Yagi T, Namekawa A, et al. Prevalence and characteristics of idiopathic right ventricular outflow tract arrhythmias associated with J-waves. *Europace* 2011;13:1774–1780.
10. Koncz I, Gurabi Z, Patocskaï B, et al. Mechanisms underlying the development of the electrocardiographic and arrhythmic manifestations of early repolarization syndrome. *J Mol Cell Cardiol* 2014;68:20–28.
11. Ghosh S, Cooper DH, Vijayakumar R, et al. Early repolarization associated with sudden death: insights from noninvasive electrocardiographic imaging. *Heart Rhythm* 2010;7:534–537.
12. Latcu DG, Bun SS, Zarqane N, Saoudi N. Ablation of left ventricular substrate in early repolarization syndrome. *J Cardiovasc Electrophysiol*. 2016;27:490–491.
13. Pedersen CT, Kay GN, Kalman J, et al. EHRA/HRS/APHRS expert consensus on ventricular arrhythmias. *Heart Rhythm* 2014;11:e166–e196.