

between impaired MBF and adverse prognosis is depicted in **Figure 1A**.

In total, 22 (17%) patients underwent late coronary revascularization on 28 vessels. At baseline evaluation, none of those vessels had obstructive CAD. On regional analysis, absolute stress MBF ($1.2 \pm 0.4 \text{ ml}\cdot\text{g}^{-1}\cdot\text{min}^{-1}$ vs $1.5 \pm 0.5 \text{ ml}\cdot\text{g}^{-1}\cdot\text{min}^{-1}$; $P < 0.001$) and MBF reserve (2.0 ± 0.6 vs 2.5 ± 0.9 ; $P = 0.026$) were lower in vessels that would later undergo revascularization than in the other coronaries with nonobstructive CAD (**Figure 1B**).

Present results show for the first time that a depressed global MBF reserve obtained with dynamic CZT imaging can individuate patients at risk of MACE, independently of relative perfusion parameters and of global CAD burden. In our cohort, MACE concentrated in patients with depressed MBF reserve that showed a cumulative event rate of 29% vs 5% in those with preserved perfusion ($P < 0.001$).

Although the association between CAD burden and adverse cardiac events has been already reported (4), their possible interaction with CZT-derived MBF data was still unknown. Although present data confirmed that the “CAD score”—as an indicator of overall atherosclerotic burden—is a predictor of MACE (3), CZT-derived MBF reserve remained significantly associated with adverse events at follow-up. Moreover, even in the absence of obstructive CAD at baseline, the presence of an impaired regional MBF could identify those vessels that would more frequently require a late coronary revascularization (**Figure 1B**), likely because of heightened CAD progression. In conclusion, we found that in stable CAD patients, CZT-derived MBF data predicted adverse cardiac events independently of overall CAD burden.

Riccardo Liga, MD, PhD
Danilo Neglia, MD, PhD
Annette Kusch, RT
Brunella Favilli, RT
Assuero Giorgetti, MD
Alessia Gimelli, MD*

*Fondazione Toscana G. Monasterio
Via G. Moruzzi 1
56124 Pisa, Italy
E-mail: gimelli@ftgm.it
<https://doi.org/10.1016/j.jcmg.2021.09.030>

© 2022 by the American College of Cardiology Foundation. Published by Elsevier.

The authors have reported that they have no relationships relevant to the contents of this paper to disclose.

The authors attest they are in compliance with human studies committees and animal welfare regulations of the authors' institutions and Food and Drug Administration guidelines, including patient consent where appropriate. For more information, visit the [Author Center](#).

REFERENCES

1. Zavadovsky KV, Mochula AV, Boshchenko AA, et al. Absolute myocardial blood flows derived by dynamic CZT scan vs invasive fractional flow reserve: correlation and accuracy. *J Nucl Cardiol*. 2021 Feb;28(1):249-259. <https://doi.org/10.1007/s12350-019-01678-z>
2. Zavadovsky KV, Mochula AV, Maltseva AN, et al. The diagnostic value of SPECT CZT quantitative myocardial blood flow in high-risk patients. *J Nucl Cardiol*. Published online October 23, 2020. <https://doi.org/10.1007/s12350-020-02395-8>
3. Califf RM, Armstrong PW, Carver JR, D'Agostino RB, Strauss WE. 27th Bethesda Conference: matching the intensity of risk factor management with the hazard for coronary disease events. Task force 5. Stratification of patients into high, medium and low risk subgroups for purposes of risk factor management. *J Am Coll Cardiol*. 1996;27:1007-1019. [https://doi.org/10.1016/0735-1097\(96\)87733-3](https://doi.org/10.1016/0735-1097(96)87733-3)
4. Neglia D, Liga R, Caselli C, et al. Anatomical and functional coronary imaging to predict long-term outcome in patients with suspected coronary artery disease: the EVINCI-outcome study. *Eur Heart J Cardiovasc Imaging*. 2020;21:1273-1282. <https://doi.org/10.1093/ehjci/jez248>

Myocardial Fibrosis Quantified by Cardiac CT Predicts Outcome in Severe Aortic Stenosis After Transcatheter Intervention



In severe aortic stenosis (AS), the timing of surgical aortic valve replacement or transcatheter aortic valve replacement (TAVR) is currently determined by the hemodynamic status of the valve and symptoms, but it is the myocardial damage caused by myocardial fibrosis (MF) that determines outcome after successful intervention (1). Furthermore, dual AS and cardiac amyloidosis (CA) have been detected in 13% to 16% of elderly patients with AS referred for TAVR, adding to the case for myocardial assessment in AS (2). The detection of MF and CA was previously limited to invasive biopsy or cardiovascular magnetic resonance (CMR); neither is suitable for elderly patients referred for TAVR, the dominant mode of treatment in many countries. Contemporary work-up for TAVR includes cardiac computed tomography (CT), where quantification of extracellular volume by CT (ECV_{CT}) can be performed without additional contrast. We sought to noninvasively evaluate the association of MF with outcome in patients with severe AS having excluded concomitant CA.

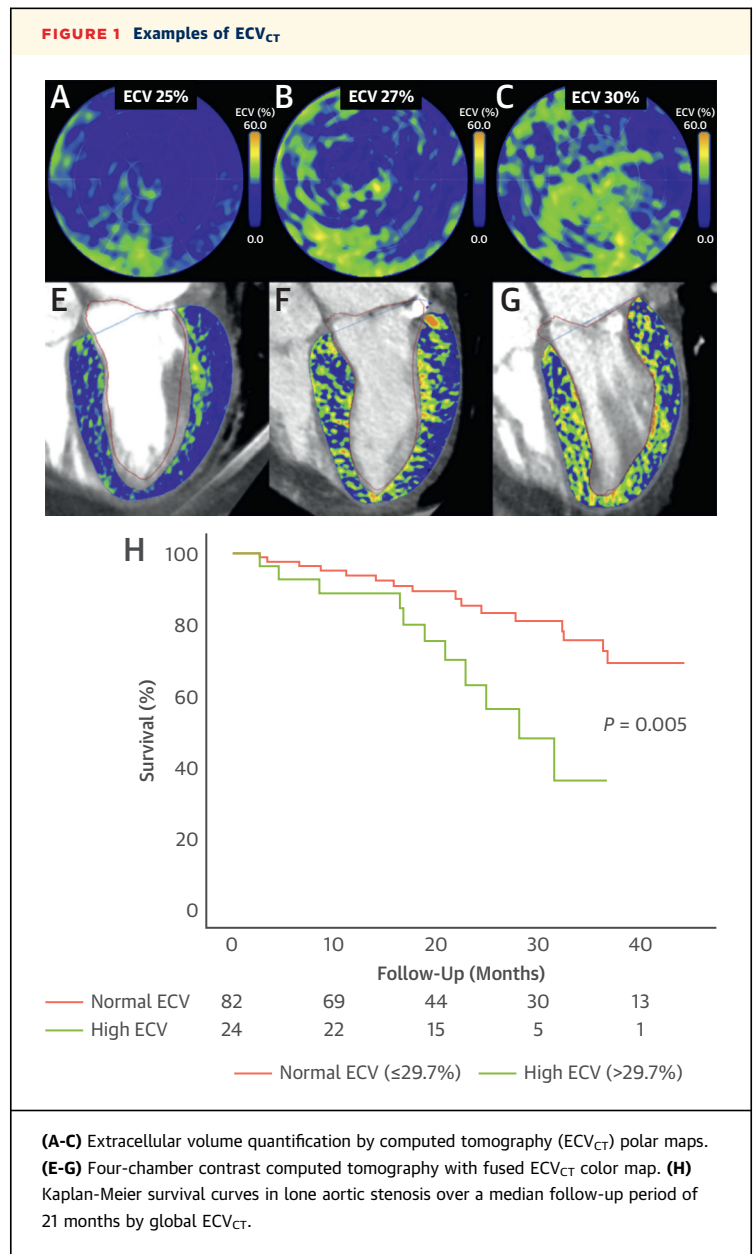
Patients with severe AS ≥ 75 years of age referred for TAVR underwent ECV_{CT} as part of the ATTRact-AS (The Role of Occult Cardiac Amyloid in the Elderly With Aortic Stenosis) study (NCT03029026) protocol (3). This study complied with the Declaration of Helsinki and local ethics and site approvals; all patients provided written informed consent. Patients underwent ^{99m}Tc-3,3-diphosphono-1,2-propanodicarboxylic acid (DPD) scintigraphy to exclude CA, a TAVR computed tomographic protocol (SOMATOM Force, Siemens Healthineers) with

ECV_{CT} (3), echocardiography, and N-terminal pro-brain natriuretic peptide and high-sensitivity troponin T (hsTnT) measurement. The additional ECV_{CT} acquisitions were precontrast baseline and 3 minutes postcontrast pseudo-equilibrium axial shuttle-mode scans, triggered 250 ms after the R wave, analyzed using a dedicated ECV_{CT} prototype for automatic 3-dimensional analysis (Siemens Healthineers). Managing clinicians were blinded to results of ECV_{CT}. All-cause mortality was captured through national mortality registry interrogation. Extended Cox regression with temporal stratification was performed. Survival analysis was performed in R version 4.0.3 (R Foundation for Statistical Computing).

One hundred fifty patients underwent ECV_{CT} and DPD scintigraphy, of whom 18 (12%) were excluded with dual AS-CA; 20 (15%) did not undergo TAVR. One hundred twelve patients (mean age 85 ± 5 years, 49% men) with severe AS (peak aortic valve jet velocity 4.1 ± 0.6 m/s, aortic valve area 0.7 ± 0.2 cm²) and a median ECV_{CT} of 28.0% (IQR: 26.3%-29.7%) were included (Figure 1).

Over a follow-up of 21 months (IQR: 15-35 months), 27 deaths (24%) occurred. Only ECV_{CT} (HR: 1.246; *P* = 0.004) and right ventricular function (tricuspid annular plane systolic excursion; HR: 0.372; *P* = 0.017) were univariate Cox regression predictors. Excluding patients with focal ECV elevation likely corresponding to myocardial infarction (*n* = 13 [12%]), ECV_{CT} remained associated with outcome (*P* = 0.02), with a similar HR (1.22 vs 1.25). On multivariate extended Cox regression, short-term mortality hazard doubled as hsTnT doubled, and medium-term mortality (>1.5 years) doubled for every 2% increase in ECV_{CT} and every 4-mm reduction in tricuspid annular plane systolic excursion (*P* < 0.0001).

ECV_{CT} as part of the preprocedural cardiac CT predicts outcome after TAVR even after exclusion of dual AS-CA. ECV_{CT} therefore serves as a robust screening tool not only for the detection of AS-CA (3) but also for risk stratification in lone AS. ECV_{CT} as a marker of MF predicts medium-term outcome together with right heart function, whereas short-term outcome is predicted by myocardial injury (hsTnT). Compared with CMR, ECV_{CT} is a faster alternative, offering 3-dimensional isotropic, whole-heart ECV quantification, and it can be integrated into routine preprocedural CT for TAVR without additional iodine contrast, with minimal additional radiation and scan time. Although limited by a small number of events restricting adjustment for confounders, the key strength is the exclusion of 1 in 7 patients with AS-CA, who would have fallen in



the high ECV_{CT} category (3). Previous studies showing an association of ECV_{CT} with adverse clinical outcomes post-TAVR could not differentiate fibrosis from amyloidosis as cause of ECV elevation (4), a key missing diagnostic step to target appropriate management (ie, amyloidosis-targeted vs fibrosis-targeted therapeutics) (5). So what is the role of ECV_{CT} in patients under evaluation for TAVR? First, it can be used to identify patients with concomitant AS-CA in order to offer amyloidosis-specific therapies after TAVR. Second, ECV_{CT} can aid in risk stratification according to fibrosis burden, potentially guiding clinicians as to the optimal

timing of TAVR, with elevated ECV_{CT} prompting consideration of intervention prior to symptom onset, similar to how such findings might be handled after the detection of elevated ECV on CMR (EVoLVeD [Early Valve Replacement Guided by Biomarkers of LV Decompensation in Asymptomatic Patients With Severe AS]; [NCT03094143](#)).

Paul R. Scully, MBBS, MRCS

Kush P. Patel, MBBS, BSc

Ernst Klotz, Diply Phys

João B. Augusto, MD

George D. Thornton, MBBS, BSc

Bunny Saberwal, MBBS

Ulrike Haberland, PhD

Simon Kennon, MD

Muhiddin Ozkor, MBBS, MD

Michael Mullen, MBBS, MD

Guy Lloyd, MD

Andrew Kelion, DM

Leon J. Menezes, BA, BM, BCH

Philip N. Hawkins, PhD

James C. Moon, MD

Francesca Pugliese, PhD[†]

Thomas A. Treibel, PhD^{*†}

*Cardiac Imaging Department, 2nd Floor, KGV
Barts Heart Centre
St. Bartholomew's Hospital
West Smithfield, London EC1A 7BE, United Kingdom

E-mail: thomas.treibel@nhs.net

Twitter: [@ThomasTreibel](https://twitter.com/ThomasTreibel)

<https://doi.org/10.1016/j.jcmg.2021.10.016>

© 2022 The Authors. Published by Elsevier on behalf of the American College of Cardiology Foundation. This is an open access article under the CC BY-NC-ND license (<http://creativecommons.org/licenses/by-nc-nd/4.0/>).

[†]Drs Pugliese and Treibel are joint last authors. Dr Scully was supported by a British Heart Foundation Clinical Research Training Fellowship (FS/16/31/32185). Dr Patel is supported by an unrestricted educational grant from Edwards Lifesciences and a British Heart Foundation Clinical Research Training Fellowship (FS/19/48/34523). Dr Klotz is a consultant for Siemens Healthineers. Dr Thornton is supported by a British Heart Foundation Clinical Research Training Fellowship (FS/CRTF/21/24128). Dr Saberwal is supported by an educational grant from Siemens Healthineers. Dr Haberland is an employee of Siemens Healthineers. Drs Moon and Treibel are directly and indirectly supported by the University College London Hospitals National Institute for Health Research (NIHR) Biomedical Research Centre and Biomedical Research Unit at University College London Hospitals and Barts, respectively. Dr Pugliese has received research support from Siemens Healthineers; and this work forms part of the translational research portfolio of the NIHR Cardiovascular Biomedical Research Centre at Barts Heart Centre, which is supported and funded by the NIHR. Dr Treibel is funded by a British Heart Foundation Intermediate Research Fellowship (FS/19/35/34374) and previously received consultancy fees from Toshiba Medical Systems Europe. All other authors have reported that they have no relationships relevant to the contents of this paper to disclose. The authors attest they are in compliance with human studies committees and animal welfare regulations of the authors' institutions and Food and Drug Administration guidelines, including patient consent where appropriate. For more information, visit the [Author Center](#).

REFERENCES

1. Everett RJ, Treibel TA, Fukui M, et al. Extracellular myocardial volume in patients with aortic stenosis. *J Am Coll Cardiol*. 2020;75:304-316.

2. Nitsche C, Scully PR, Patel KP, et al. Prevalence and outcomes of concomitant aortic stenosis and cardiac amyloidosis. *J Am Coll Cardiol*. 2021;77:128-139.

3. Scully PR, Patel KP, Saberwal B, et al. Identifying cardiac amyloid in aortic stenosis: ECV quantification by CT in TAVR patients. *J Am Coll Cardiol Img*. 2020;13(10):2177-2189.

4. Tamarappoo B, Han D, Tyler J, et al. Prognostic value of computed tomography-derived extracellular volume in TAVR patients with low-flow low-gradient aortic stenosis. *J Am Coll Cardiol Img*. 2020;13:2591-2601.

5. Maurer MS, Schwartz JH, Gundapaneni B, et al. Tafamidis treatment for patients with transthyretin amyloid cardiomyopathy. *N Engl J Med*. 2018;379:1007-1016.

Echocardiographic Reporting of Proximal Coronary Artery Origins in Young Competitive Athletes



Coronary artery anomalies are an important cause of sudden cardiac death in young competitive athletes.¹ Current imaging guidelines for young competitive athletes recommend routine assessment of proximal coronary anatomy to assess for the presence of high-risk anomalies regardless of the indication for transthoracic echocardiography (TTE).² Prior studies have documented the ability of TTE to define proximal coronary anatomy, but the frequency with which proximal coronary origins are evaluated and reported in real-world practice remains unknown. The primary aim of this study was to examine the reporting frequency of proximal coronary anatomy among echocardiography laboratories in ORCCA (Outcomes Registry for Cardiac Conditions in Athletes).

This prospective observational cohort study included colleges from the National Collegiate Athletic Association that submitted data to ORCCA from September 1, 2020, to May 21, 2021, as previously reported.³ The inclusion criterion for this study was at least 1 TTE report from a participating echocardiography laboratory. A total of 56 echocardiography laboratories met this inclusion criterion. All available TTE reports were reviewed to assess for the presence of proximal coronary anatomy reporting. "Consistent reporters" were defined as echocardiography laboratories that reported coronary anatomy or the inability to visualize coronary origins in >90% of clinical reports, while "variable reporters" were defined as laboratories that reported coronary data <90% of the time. All aspects of this study were approved by the Massachusetts General Brigham Institutional Review Board (protocol #2020P002667).

Complete reports were available for 1,529 of 3,027 athletes (51%) who underwent transthoracic echocardiographic screening (mean age 20 ± 3 years, 31% women, 27% Black race), representing 25 unique