

***Emergomyces orientalis* Emergomycosis Diagnosed by Metagenomic Next- Generation Sequencing**

Da He¹, Min Quan¹, Hongyan Zhong, Zhixing Chen, Xiaohui Wang, Fang He, Junyan Qu, Taoyou Zhou, Xiaoju Lv, Zhiyong Zong

Author affiliations: Center for Infectious Diseases, West China Hospital of Sichuan University Chengdu, China (D. He, M. Quan, X. Wang, F. He, J. Qu, T. Zhou, X. Lv, Z. Zong); Hospital of Chengdu Office of People's Government of Tibetan Autonomous Region, Chengdu (H. Zhong); West China Hospital of Sichuan University, Chengdu (Z. Chen); Center for Infectious Diseases, Yaan People's Hospital, Yaan, China (X. Wang)

DOI: <https://doi.org/10.3201/eid2710.210769>

Emergomyces is a newly described dimorphic fungus genus; it may cause fatal infections in immunocompromised patients, but diagnosis is often delayed. We report a case of disseminated emergomycosis caused by the novel species *Emergomyces orientalis* in a kidney transplant recipient from Tibet. Infection was diagnosed early by metagenomic next-generation sequencing.

Emergomycosis (formerly called emmonsiosis) is an emerging dimorphic fungal disease, usually caused by *Emergomyces pasteurianus* or *Es. africanus*, usually disseminated and commonly identified and fatal in immunocompromised patients, especially HIV-positive patients from South Africa (1,2). Diagnosis of emergomycosis is often delayed, and best clinical practices for diagnosing and treating organ transplant recipients are lacking. Five species with different geographic distributions have been described: *Es. pasteurianus*, *Es. africanus*, *Es. canadensis*, *Es. europaeus*, and *Es. orientalis*. Globally, the only case of *Es. orientalis* infection, reported in China in 2017, was initially misdiagnosed as disseminated cryptococcosis (3). We report another case of *Es. orientalis* infection involving lung and soft tissue damage that was diagnosed early and accurately and treated precisely.

A 41-year-old man from Tibet who had received a kidney transplant 6 years earlier was admitted to a hospital with a 1-month history of progressive right lower chest pain and mild cough with a small amount of sputum. He was taking

tacrolimus, mycophenolate mofetil, and prednisone. He was a herder caring for sheep, horses, and dogs. We noted reduced breath sounds in his lower right lung; chest computed tomography images indicated pneumonia (Figure, panel A). A bronchoalveolar lavage fluid smear revealed yeast-like fungi on both Gram staining and Grocott-Gomori methenamine silver staining (Figure, panel B). Because pulmonary cryptococcosis was suspected, fluconazole (400 mg 1×/d) was initiated. Results of a cryptococcal antigen lateral flow immunoassay (IMMY, <https://www.immy.com>) was negative, but a Platelia *Aspergillus* antigen immunoenzymatic sandwich microplate assay (Bio-Rad, <https://www.bio-rad.com>) resulted in an unexpectedly high level (6.42 [reference 0.00–0.49] signal:cutoff ratio). After 1 week of ineffective empirically prescribed treatment, we had a lung biopsy performed. Electron microscopy revealed yeast cells in a unique form, measuring ≈3 μm, scattered in necrotizing granulomas (Figure, panel C). Metagenomic next-generation sequencing (mNGS) of fresh tissue indicated *Es. orientalis* (sequence reads 143; Illumina NextSeq 550 platform, <https://www.illumina.com>; Appendix Figure 1, <https://wwwnc.cdc.gov/EID/article/27/10/21-0769-App1.pdf>). We initiated oral itraconazole (200 mg 2×/d) immediately and decreased tacrolimus dosage according to its plasma concentration. Finally, we isolated the pure *Es. orientalis* strain (Figure, panel D). Specific secondary, α-shaped conidiophores clearly indicated *Emergomyces* (Figure, panel E). *Es. orientalis* was confirmed by PCR amplification targeting the rDNA internal transcribed spacer region followed by BLAST sequence comparison (<https://blast.ncbi.nlm.nih.gov/Blast.cgi>; GenBank accession no. NR_148064.1; coverage 96%, identity 99.33%) (Appendix Figure 2).

During treatment, the patient had intermittent mild fever and an acne-like rash on his chin, and a small new pulmonary lesion developed in the right upper lobe. Repeated blood cultures were all negative. We prescribed oral posaconazole (400 mg 2×/d) after determining a MIC of 0.008 μg/mL (Appendix Table). Later, the lung lesions partially resolved, but we found a painful soft tissue abscess (55 × 15 × 30 mm) on the right side of his waist (Figure, panel F) from which we drained purulent grayish-green fluid. We again cultured *Es. orientalis*. Therefore, we added flucytosine (1,000 mg 3×/d) and withdrew tacrolimus and mycophenolate mofetil for 1 month. After 6 months of recurrent hospitalization, we discharged the

¹These authors contributed equally to this article.

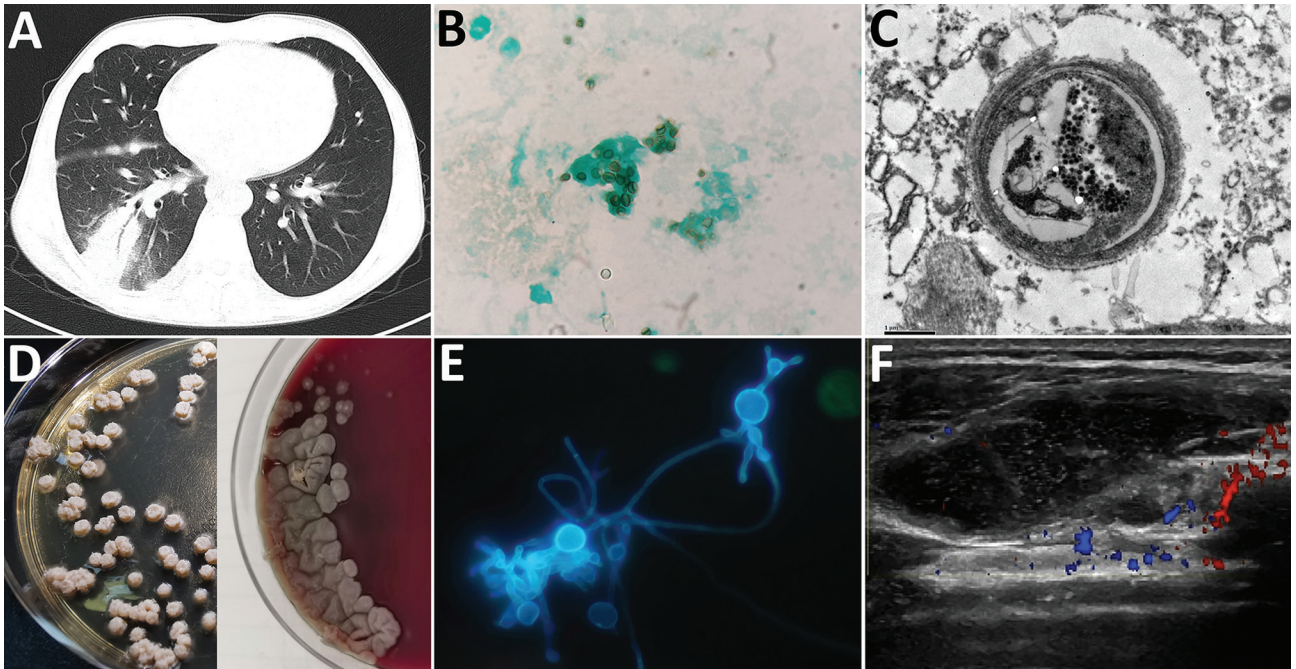


Figure. *Emergomyces orientalis* infection in a kidney transplant patient from Tibet. A) Pulmonary consolidation with the air bronchogram sign shown on a computed tomography scan. B) Microbes stained with Grocott-Gomori's methenamine silver in the bronchoalveolar lavage fluid sample (original magnification $\times 1,000$). C) Pathological image of 1 yeast cell shown by electron microscopy in a necrotizing granuloma from paraffin-embedded pulmonary tissue (original magnification $\times 16,000$). D) Tiny, slightly raised white colonies on Sabouraud agar on day 20 at 25°C (left) and grayish yellow furrowed colonies on blood agar on day 30 at 35°C (right) isolated from bronchoalveolar lavage fluid samples. E) Specific secondary α -shaped conidiophore shown with fluorescent calcium staining (original magnification $\times 1,000$). F) Ultrasound revealed a soft tissue abscess in the patient's right subcostalis.

patient with a diagnosis of disseminated emergomycosis. Six months after discharge, he remained stable. We found no similarly infected or epidemiologically linked person or animal.

Previously, a retrospective study from southern Africa assessed 54 patients with disseminated emergomycosis, of whom 94% were co-infected with HIV; 96% had skin involvement, 88% had lung involvement, 44% received an incorrect diagnosis, and 48% died (4). In this case, we initially identified *Es. orientalis* infection using mNGS, a 1-step, culture-independent method for detecting all pathogens from 1 specimen (5). Although research validating mNGS assays in clinical practice is very limited, challenging cases diagnosed by mNGS have been published and expert consensus has begun to recommend mNGS for diagnosing challenging cases in immunocompromised patients (6,7). Therefore, we recommend using mNGS to diagnose challenging emergomycosis cases.

This case showed that treatment with posaconazole combined with flucytosine is effective in organ transplant recipients with disseminated emergomycosis caused by *Es. orientalis*. Although amphotericin

B deoxycholate is more effective than triazoles for improving emergomycosis survival rate (71% vs. 33%) (4), we could not prescribe it for our patient because of nephrotoxicity. Similar to the earlier reported case of *Es. orientalis* infection, in which type 2 diabetes was the only identified cause of immunodeficiency (3), fluconazole was ineffective in vivo in our patient. Previously, 3 cases in China of *Es. pasteurianus* (formerly *Emmonsia pasteuriana*) infection with or without renal transplantation have also been reported (8–10).

Further research is needed to determine whether kidney transplantation is associated with *Es. orientalis* infection and risk for emergomycosis. In conclusion, clinicians need to become more aware of emergomycosis because of its common misdiagnosis and high death rate.

Acknowledgments

We thank Liubo Xiong and Yuling Xiao for their help.

This study was supported by Sichuan Science and Technology program, China (2018HH0031) and 1.3.5 project for disciplines of excellence, West China Hospital, Sichuan University (2017-046).

About the Author

Dr. He and Dr. Quan are medical students at the Center for Infectious Diseases, West China Hospital of Sichuan University in Chengdu, China. Their research interests are pathogen detection and microbial resistance.

References

1. Schwartz IS, Govender NP, Sigler L, Jiang Y, Maphanga TG, Toplis B, et al. *Emergomyces*: the global rise of new dimorphic fungal pathogens. *PLoS Pathog*. 2019;15:e1007977. <https://doi.org/10.1371/journal.ppat.1007977>
2. Rooms I, Mugisha P, Gambichler T, Hadaschik E, Esser S, Rath PM, et al. Disseminated emergomycosis in a person with HIV infection, Uganda. *Emerg Infect Dis*. 2019;25:1750–1. <https://doi.org/10.3201/eid2509.181234>
3. Wang P, Kenyon C, de Hoog S, Guo L, Fan H, Liu H, et al. A novel dimorphic pathogen, *Emergomyces orientalis* (Onygenales), agent of disseminated infection. *Mycoses*. 2017;60:310–9. <https://doi.org/10.1111/myc.12583>
4. Schwartz IS, Govender NP, Corcoran C, Dlamini S, Prozesky H, Burton R, et al. Clinical characteristics, diagnosis, management, and outcomes of disseminated emmonsiosis: a retrospective case series. *Clin Infect Dis*. 2015;61:1004–12. <https://doi.org/10.1093/cid/civ439>
5. Simner PJ, Miller S, Carroll KC. Understanding the promises and hurdles of metagenomic next-generation sequencing as a diagnostic tool for infectious diseases. *Clin Infect Dis*. 2018;66:778–88. <https://doi.org/10.1093/cid/cix881>
6. Editorial Board of the Chinese Journal of Infectious Diseases. Clinical practice expert consensus for the application of metagenomic next generation sequencing [in Chinese]. *Chin J Infect Dis*. 2020;38:681–9. <https://doi.org/10.3760/cma.j.cn311365-20200731-00732>
7. Clinical Microbiology Group of Chinese Society of Laboratory Medicine, Clinical Microbiology Group of Chinese Society of Microbiology and Immunology, Society of Clinical Microbiology and Infection of China International Exchange and Promotion Association for Medical and Healthcare. Chinese expert consensus on metagenomics next-generation sequencing application on pathogen detection of infectious diseases [in Chinese]. *Chin J Lab Med*. 2021;44:107–20. <https://doi.org/10.3760/cma.j.cn114452-20201026-00794>
8. Feng P, Yin S, Zhu G, Li M, Wu B, Xie Y, et al. Disseminated infection caused by *Emmonsia pasteuriana* in a renal transplant recipient. *J Dermatol*. 2015;42:1179–82. <https://doi.org/10.1111/1346-8138.12975>
9. Tang XH, Zhou H, Zhang XQ, Han JD, Gao Q. Cutaneous disseminated emmonsiosis due to *Emmonsia pasteuriana* in a patient with cytomegalovirus enteritis. *JAMA Dermatol*. 2015;151:1263–4. <https://doi.org/10.1001/jamadermatol.2015.1792>
10. Chik KK, To WK. Autochthonous *Emergomyces pasteurianus* pneumonia in an immunocompromised patient in Hong Kong: a case report. *Hong Kong Med J*. 2020;26:446–8. <https://doi.org/10.12809/hkmj198280>

Address for correspondence: Xiaohui Wang, Center for Infectious Diseases, West China Hospital of Sichuan University, Wuhouqu Guoxuexiang 37#, Chengdu 610041, China; email: wang_xiaohui@scu.edu.cn

Human Infection with Avian Influenza A(H9N2) Virus, Cambodia, February 2021

Samnang Um,¹ Jurre Y. Siegers,¹ Borann Sar, Savuth Chin, Sarika Patel, Seng Bunnary, Makara Hak, Sothy Sor, Oum Sokhen, Seng Heng, Darapheak Chau, Tum Sothyra, Asheena Khalakdina, Joshua A. Mott, Sonja J. Olsen, Filip Claes, Ly Sovann, Erik A. Karlsson

Author affiliations: National Institute of Public Health, Ministry of Health, Phnom Penh, Cambodia (S. Um, S. Chin, D. Chau); Institut Pasteur du Cambodge, Phnom Penh (J.Y. Siegers, E.A. Karlsson); US Centers for Disease Control and Prevention, Phnom Penh (B. Sar); World Health Organization Country Office, Phnom Penh (S. Patel, A. Khalakdina); National Animal Health and Production Research Institute, Phnom Penh (S. Bunnary, T. Sothyra); Food and Agriculture Organization of the United Nations Country Office, Phnom Penh (M. Hak); Prevention and Control Disease Bureau, Provincial Health Department, Siem Reap, Cambodia (S. Sor); Provincial Office of Animal Health and Production, Siem Reap (O. Sokhen); Cambodian Center for Disease Control, Ministry of Health, Phnom Penh (S. Heng, L. Sovann); US Centers for Disease Control and Prevention, Bangkok, Thailand (J.A. Mott, S.J. Olsen); Food and Agriculture Organization of the United Nations Regional Office for Asia and the Pacific, Bangkok (F. Claes)

In February 2021, routine sentinel surveillance for influenza-like illness in Cambodia detected a human avian influenza A(H9N2) virus infection. Investigations identified no recent H9N2 virus infections in 43 close contacts. One chicken sample from the infected child's house was positive for H9N2 virus and genetically similar to the human virus.

Low pathogenicity avian influenza virus subtype LA(H9N2) is endemic in poultry in Asia, the Middle East, and Africa (1). These viruses do not cause mass mortality in poultry but can cause substantial negative economic impacts (2). H9N2 viruses also have zoonotic potential; 74 human infections were reported from 1998 through early 2021 (1,3,4), mainly in children with a history of poultry exposure. The internal gene cassettes of H9N2 viruses contribute to human adaptation of avian influenza viruses (AIV)

¹These authors contributed equally to this article.