



# Arthroscopic Decompression and Subsequent Bone-Grafting of Spinoglenoid Cyst

Patrick Thériault, M.D., Catherine M. Coady, M.D., F.R.C.S.C., and Ivan Wong, M.D., F.R.C.S.C., M.A.cM., Dip. Sports Med

**Abstract:** Spinoglenoid cysts are associated with labral tears; however, little is known about their associated bony pathology. This Technical Note describes an arthroscopic technique to decompress and subsequently graft a spinoglenoid cyst and associated bony defect. Appropriate preoperative imaging is key to understanding the location of the bony defect and therefore crucial to the success of the bone graft. Adequate release of the labrum should be performed to fully visualize the bony lesion. A subchondroplasty cannulated drill is then placed in the bony defect under direct visualization and said defect is then filled with calcium phosphate cement. Care is taken to ensure no cement is allowed to extrude into the shoulder joint. After the cement has cured, labral pathology is repaired and the usual postoperative physiotherapy protocol is initiated.

Spinoglenoid cysts are known to be associated with SLAP lesions. As first described by Thompson et al., there has been increasing evidence of suprascapular nerve injury secondary to compression by these cysts.<sup>1,2</sup> However, little to no literature describes bony pathology in association with spinoglenoid cyst. In this technique paper, we will describe a technique used to treat a spinoglenoid cyst causing a bony defect in the posterior glenoid.

Calcium phosphate cements are injectable bone substitutes that have been used for various applications in orthopaedic surgery. Their chemical characteristics as well as their biomechanical properties (e.g. setting time, injectability, strength, etc.) make them especially useful when repairing bone defects post tumor resection.<sup>3-7</sup> Studies show that bone defects filled with calcium phosphate cement provide adequate strength, minimize

immobilization time, and eliminate the morbidity associated with bone graft harvesting.<sup>7</sup>

## Technique

### Preoperative Assessment

A standard physical examination of the shoulder is performed. Initial shoulder imaging (Figs 1A-E) should include radiographs in the anteroposterior and axillary views, computed tomography (CT) scan with 3-dimensional (3D) reconstruction, and subsequent magnetic resonance imaging should also be completed to evaluate for the presence of a cyst or damage to the rotator cuff and soft tissues. Preoperatively, a 3D reconstruction of the patient's shoulder should be viewed from the CT images to help with operative planning (Fig 2 A-C).

Surgical indications would include the presence of a bony Bankart lesion as well as a subchondral cystic lesion located in the posterior glenoid measuring 23-mm length × 8-mm width × 8-mm depth in size. A further surgical indication for this procedure would be significant cortical bone loss in the posterior glenoid associated with the presence of the cyst.

### Positioning and Preparation

The patient is placed in the lateral decubitus position using a beanbag with the operative side facing up. The operative limb is prepped and draped in the usual sterile manner. The operative limb is placed in 45° of abduction and slight flexion and traction using a SPIDER2

*From the Division of Orthopaedic Surgery, Department of Surgery, Faculty of Medicine, Dalhousie University, Nova Scotia, Canada.*

*The authors report that they have no conflicts of interest in the authorship and publication of this article. Full ICMJE author disclosure forms are available for this article online, as [supplementary material](#).*

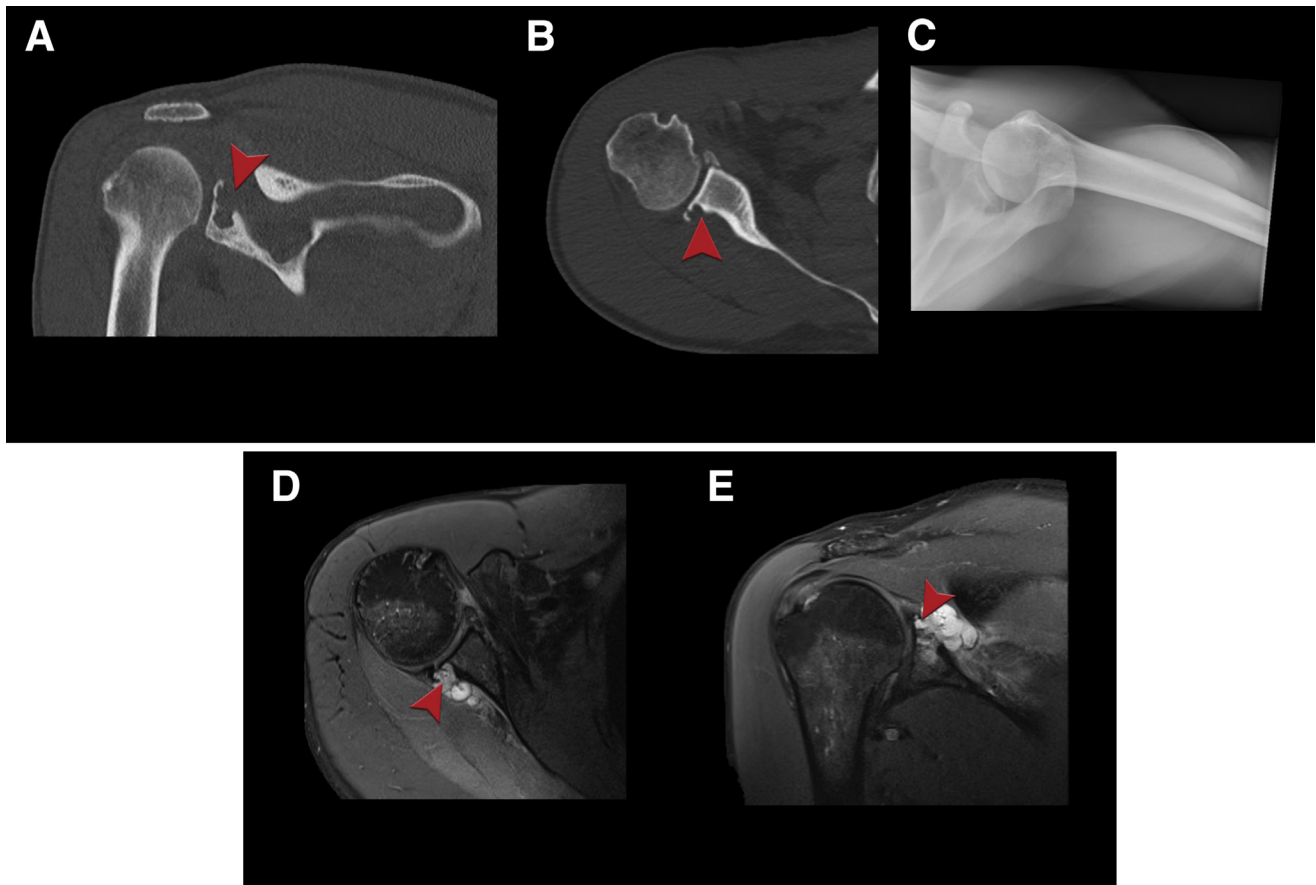
*Received January 28, 2020; accepted May 14, 2020.*

*Address correspondence to Dr. Ivan Wong, M.D., F.R.C.S.(C), Dip. Sports Med., M.A.cM., 5955 Veteran's Memorial Lane, Room 2106 VMB, Halifax, Nova Scotia, Canada. B3H 2E1. E-mail: [iw@drivanwong.com](mailto:iw@drivanwong.com)*

*© 2020 by the Arthroscopy Association of North America. Published by Elsevier. This is an open access article under the CC BY-NC-ND license (<http://creativecommons.org/licenses/by-nc-nd/4.0/>).*

*2212-6287/20158*

*<https://doi.org/10.1016/j.eats.2020.05.009>*



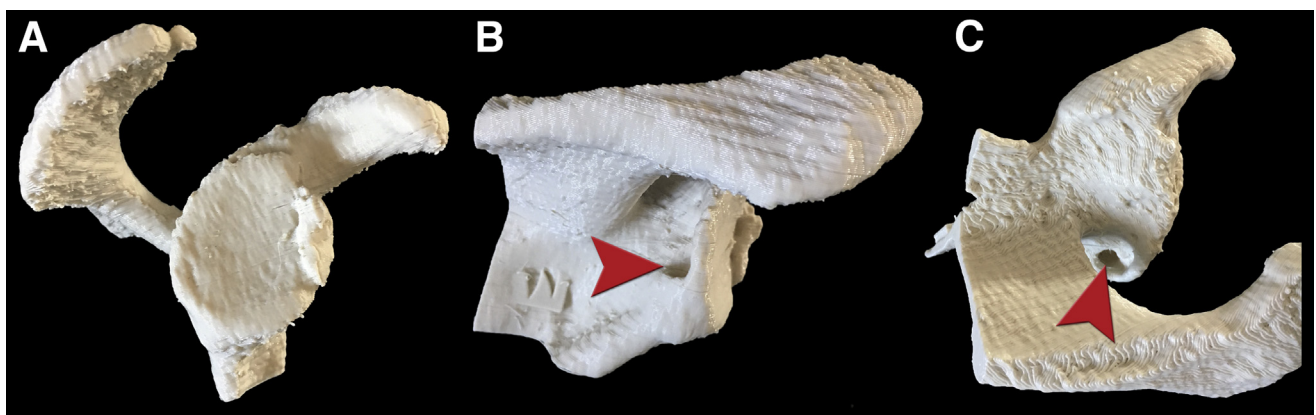
**Fig 1.** (A-B) CT coronal and axial views of cyst; (C-D) axial and coronal T2-weighted images of the cyst; (E) axillary view of patient's right shoulder for assessment before undergoing arthroscopic Decompression and subsequent bone-grafting of a spinglenoid cyst. Arrows point at a posterior glenoid cyst. (CT, computed tomography.)

limb-positioning device (Smith & Nephew, Andover, MA). Anatomical landmarks are then drawn (Fig 3).

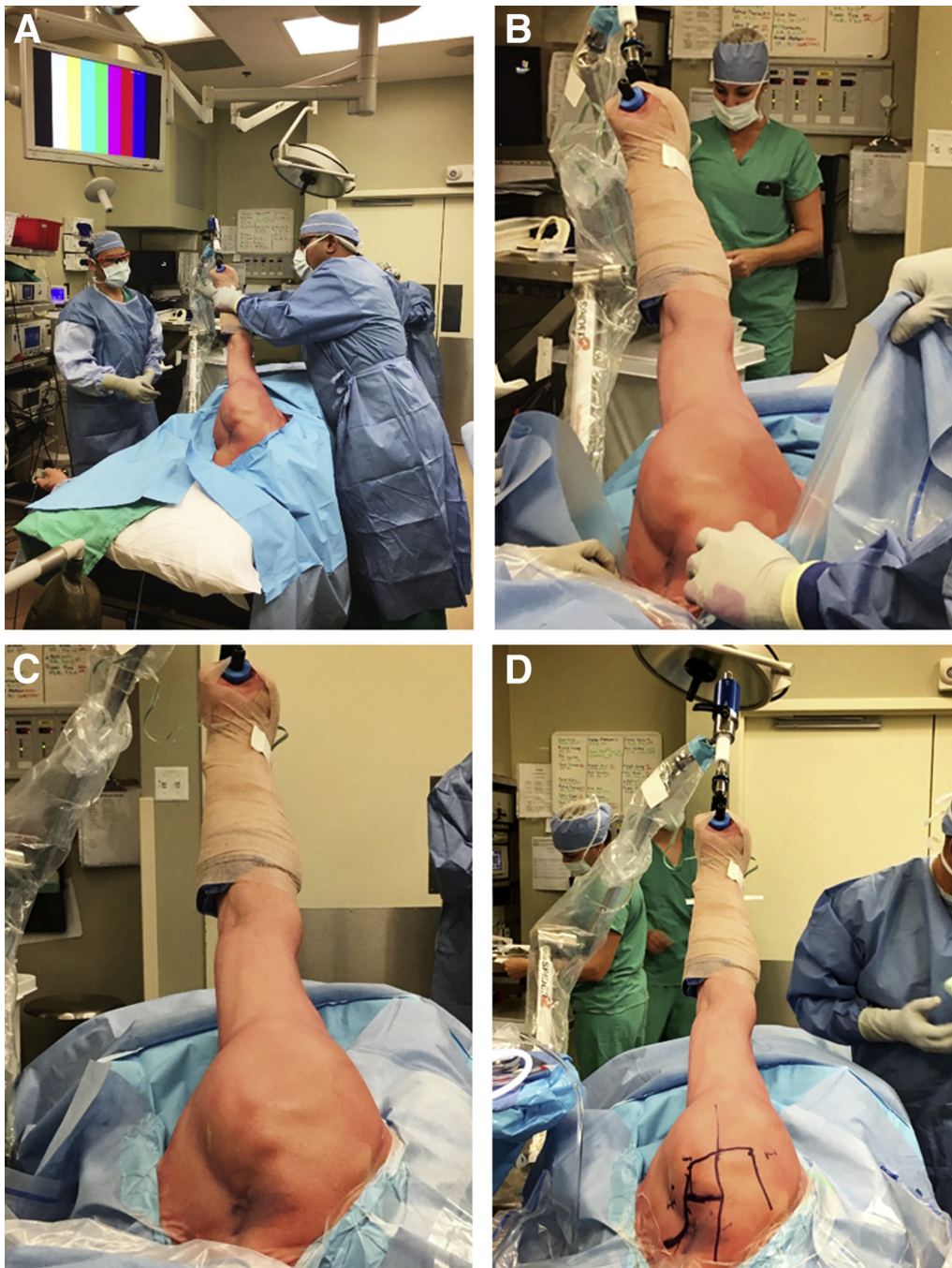### Arthroscopic Portals

Preoperatively, a 3D CT reconstruction model should have been obtained to help with operative planning. This 3D reconstruction of the patient's shoulder can be

used to help determine portal placement, as it will show the location of the cyst. For example, if it is notable that the subchondral bone cyst is quite inferior (i.e. 7-o'clock position), then the posterior portal should be made slightly inferior to address the issue. Two additional portals should then also be made (i.e. anteromedial and anterolateral) (Fig 4 A-B).



**Fig 2.** Preoperative examination of 3-dimensional printed model of right shoulder showing inferior location of bone cyst to determine the more inferior placement of the posterior portal. (A) En face view; (B) posterior view; (C) superior view. Arrow points at a posterior glenoid cyst.

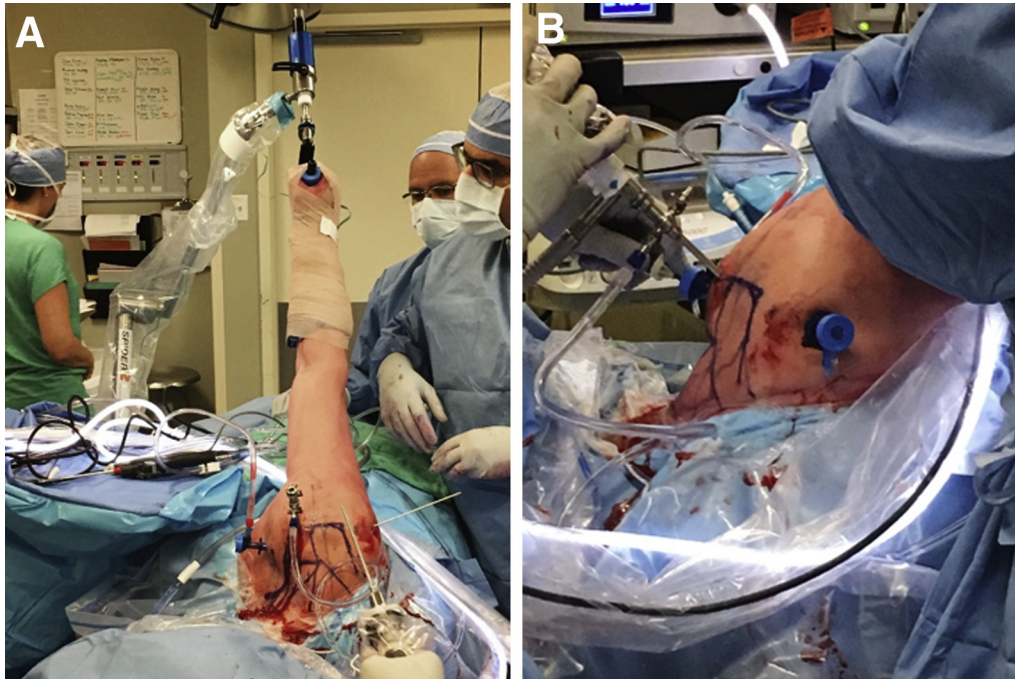


**Fig 3.** Intraoperative photos showing patient positioning in left lateral decubitus with right arm in traction with the SPIDER2 Limb-positioning device, during arthroscopic decompression, and subsequent bone-grafting of a spinoglenoid cyst.

### Initial Evaluation

First, a routine diagnostic shoulder arthroscopy is performed. This is started through the posterior portal. A systematic review of every structure is done according to the 15-point shoulder exam as described by Snyder.<sup>8</sup> The joint should be examined for any indication of marked synovitis. Using the Outerbridge Classification, note any arthritic changes on both the glenoid and the humeral head.<sup>9</sup> Examine the joint for

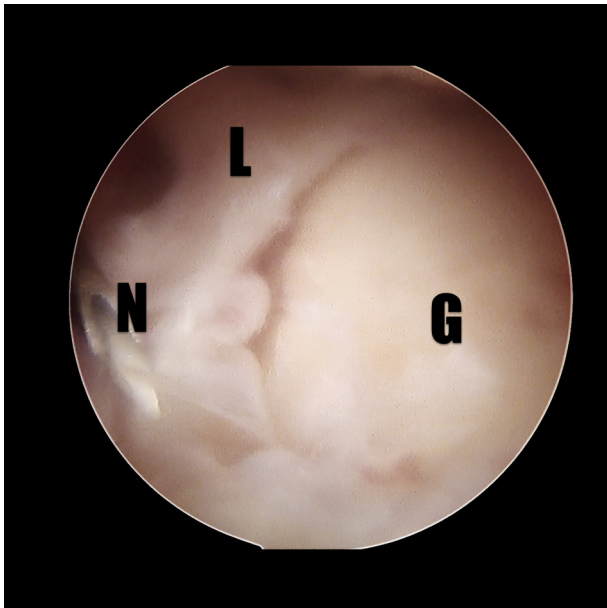
potential labral tears in all regions of the glenoid, including inferior, posterior, superior, and anterior (Fig 5). The rotator cuff also should be examined. The diagnostic arthroscopy is finished by viewing the same structures through the anterosuperior portal, created through an outside-in approach off the anterolateral corner of the acromion, and as far away from the anteroinferior portal as to avoid instrument entanglement.



**Fig 4.** Intraoperative photos showing arthroscopic portal placement: posterior, anteromedial, anterolateral, in the lateral decubitus position with right shoulder. A) Viewing from superior; B) viewing from posterior.

### Tissue Mobilization and Cyst Exposure and Decompression (With Video Illustration)

Viewing from the superior portal, assessment of the posterior portal location can be made. As described previously, the 3D model helps to determine that the posterior portal can be used for cyst decompression as



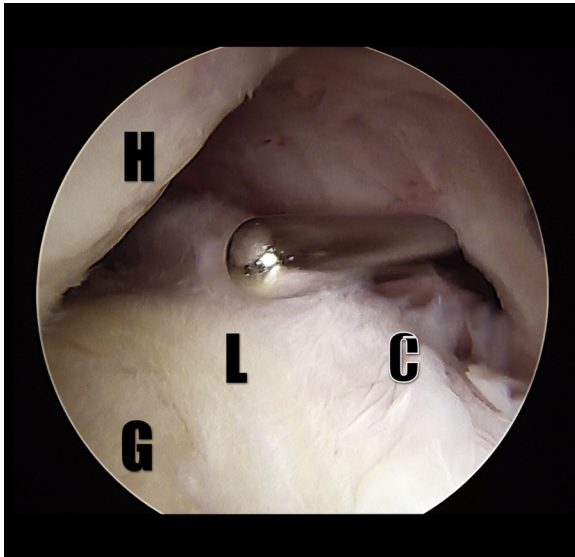**Fig 5.** Patient position: lateral decubitus position, Shoulder: right. Arthroscopic view of glenoid showing large posterior labral tear overlying the spinoglenoid cyst, viewing from posterior portal, needle in anterosuperior portal. (G, glenoid; L, labrum; N, needle.)

well as bone grafting if it is created around the 7-o'clock position. By viewing from the anterosuperior portal, it is easier to identify the most inferior 6-o'clock position, and thus the 7-o'clock position on the glenoid can be estimated. A switching stick can be used to redirect the portal directly above the 7-o'clock position on the glenoid to better access the bony cyst (Figs 2 and 6).

The posterior labrum superior and inferior to the cyst is elevated using a liberator elevator placed in the anteroinferior portal (Fig 7). This allows the best access to the labrum and is in the correct orientation to the posterior rim of the glenoid. Care must be taken to be sure the entire capsule–labral complex is freed so the muscle fibers of the teres minor can be visualized. Occasionally, fluid from the cyst will become visible.

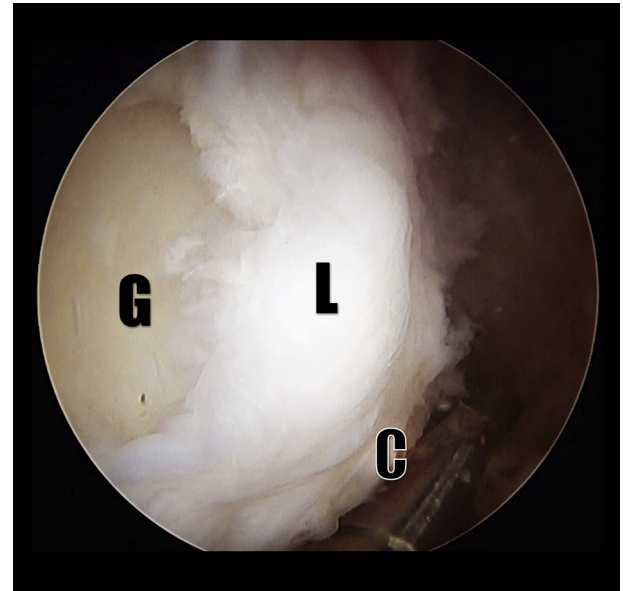
Peri-labral cyst decompression can be carried out using a shaver in the anteroinferior portal and deroofing the cyst by excising the capsule lateral to the labrum at the 7-o'clock position (Fig 8). This is usually visualized as a thinned membrane covering the cyst. The labrum is left intact, but the capsule lateral to the labrum in continuity to the roof of the cyst. This is excised so that the “blush” of cystic fluid can be seen, and then the entire cyst exposed. Care must be taken to remove enough of the cyst wall so that it cannot close off again and reform. This can be determined when no more of the cyst can be undermined to see the entire dimension of the peri-labral cyst.

A subchondroplasty (Zimmer Biomet, Warsaw, IN) drill can then be used through the posterior portal, through the freed tissue between the labrum and



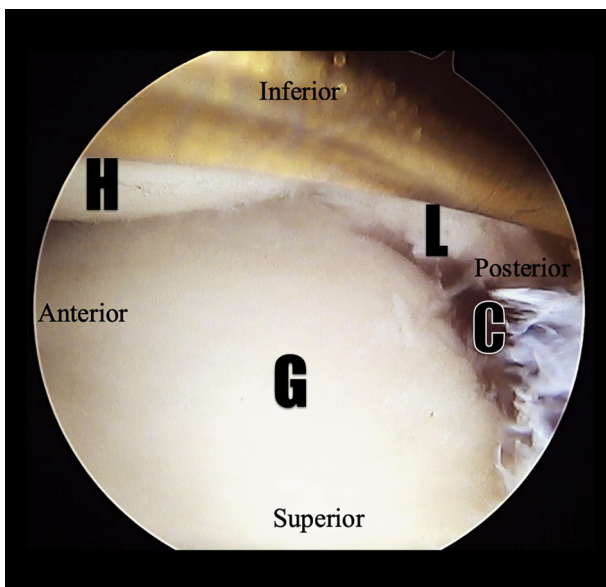
**Fig 6.** Patient position: lateral decubitus position, Shoulder: right. Redirection of the portal above the 7-o'clock position on the glenoid using a switching stick to better access the bony cyst. (C, cyst; G, glenoid; H, humerus; L, labrum.)

glenoid at the 7-o'clock location (Fig 9). Once the location is confirmed (at the level of the labral tear, and medial to the peri-labral cyst as identified on preoperative magnetic resonance imaging and CT imaging), the drill can penetrate the cortex overlying the bony defect in the posterior glenoid (Fig 10 A and B). The void can then be filled with 5 mL of calcium phosphate (Subchondroplasty; Zimmer) through the cannula and can be allowed to solidify for 10 minutes.

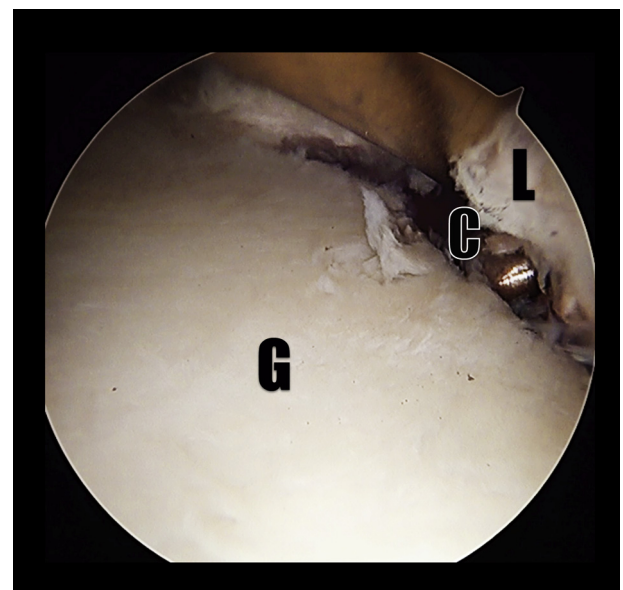


**Fig 8.** Patient position: lateral decubitus position, Shoulder: right. Decompression of the posterior spinoglenoid cyst using radioablation; viewing from the anterosuperior portal. (C, cyst; G, glenoid; L, labrum.)

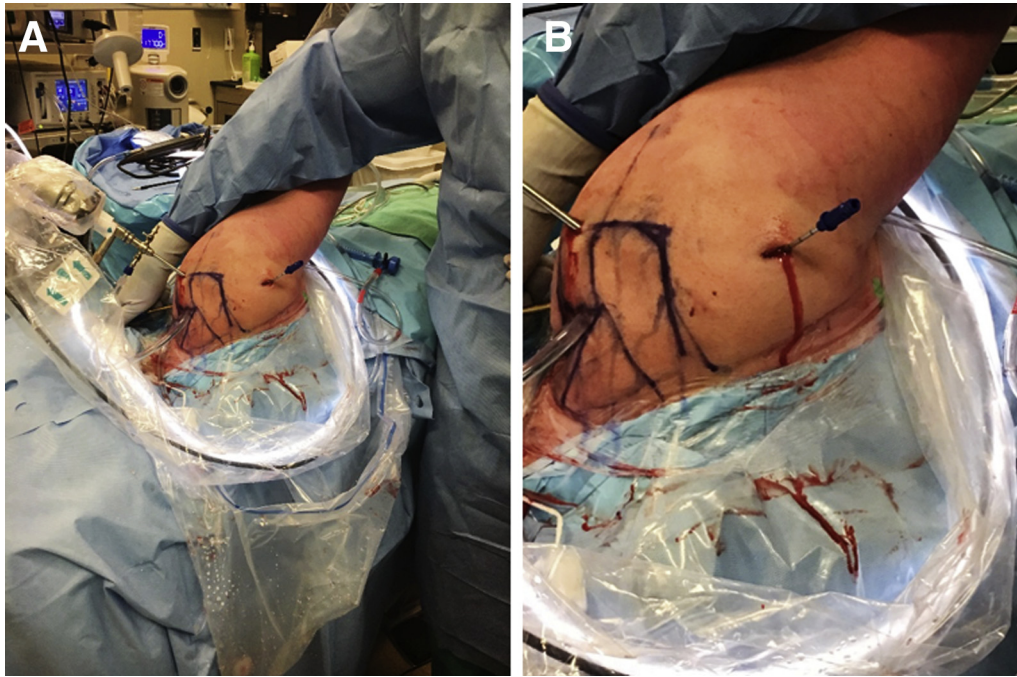
Finally, the posterior labrum can be repaired with 2 Q-FIX (Smith & Nephew) suture anchors (Fig 11). These are placed percutaneously onto the corner of the glenoid rim, one anchor superior and one anchor inferior to the 7-o'clock location. A medium crescent Spectrum suture shuttle (CONMED Linvatec, Largo, FL) is used to shuttle one limb of each anchor through the labrum. Simple suture configuration is created for



**Fig 7.** Patient position: lateral decubitus position, Shoulder: right. The elevation of the posterior labrum superior and inferior to the cyst using a liberator elevator placed in the anteroinferior portal; viewing from anterosuperior portal. (C, cyst; G, glenoid; H, humerus; L, labrum.)



**Fig 9.** Patient position: lateral decubitus position, Shoulder: right. Placement of cannulated drill in spinoglenoid cyst as viewed from the anterolateral portal. (C, cyst; G, glenoid; L, labrum.)

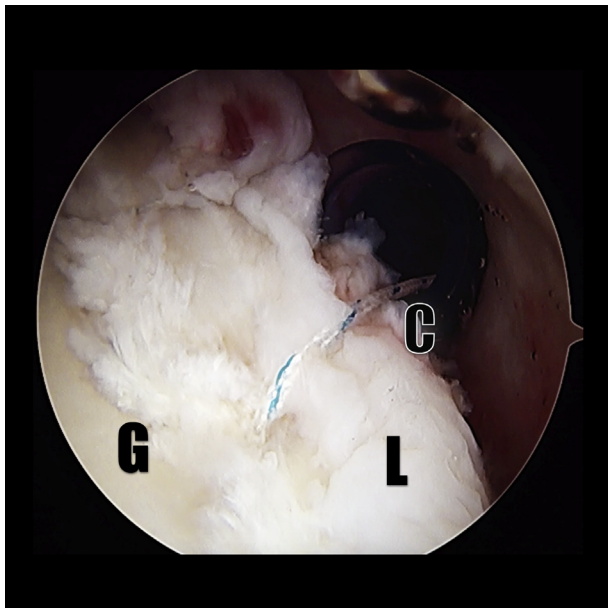


**Fig 10.** Patient position: lateral decubitus position, Shoulder: right. Intraoperative photos showing placement of cannulated drill bit for injection of calcium phosphate used in Subchondroplasty (Zimmer Biomet). A) Viewing from posterior; B) zoomed in focused on the injection site.

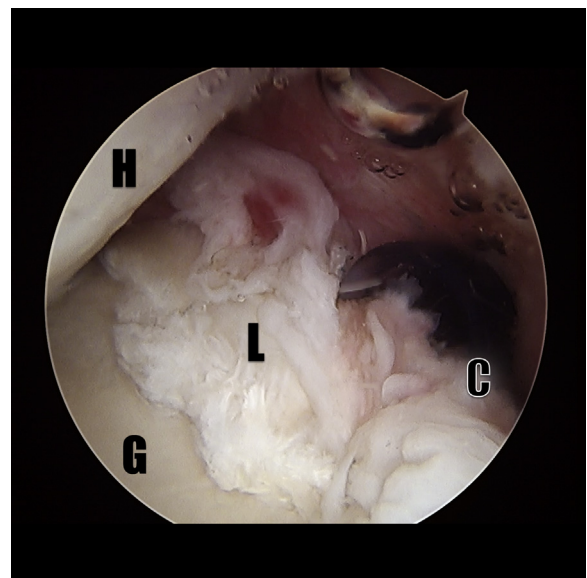
each suture anchor and a SMC knot is tied on the labral tissue away from the glenoid to prevent articular wear. The capsulotomy where the cyst was decompressed is left open to heal by secondary intent. Final inspection should reveal a decompressed cyst and a stable labral repair (Video 1 and Fig 12).

#### Postoperative Care and Mobilization

The patient is placed in a shoulder-immobilizing sling postoperatively to be worn for a total of 6 weeks. Physiotherapy is started 2 days after surgery with gentle passive range of motion (ROM). Active assisted ROM started at 6 weeks and resistance training starting at



**Fig 11.** Patient position: lateral decubitus position, Shoulder: right. Repair of the posterior labrum using Q-FIX anchors (Smith & Nephew) and sliding arthroscopic knots; viewing from antero-superior portal. (C, cyst; G, glenoid; L, labrum.)



**Fig 12.** Patient position: lateral decubitus position, Shoulder: right. Final view of a completed labral reconstruction and spinoglenoid cyst decompression, viewing from antero-superior portal. (C, cyst; G, glenoid; H, humerus; L, labrum.)

**Table 1.** Advantages and Disadvantages of Arthroscopic Decompression and Subsequent Bone-Grafting of a Spinoglenoid Cyst

Advantages	Disadvantages
Address instability and bony defect simultaneously	Technically challenging
Minimally invasive	Increased surgical time/swelling No long-term outcome studies

**Table 2.** Pearls and Pitfalls of Arthroscopic Decompression and Subsequent Bone-Grafting of a Spinoglenoid Cyst

Pearls	Pitfalls
Ensure adequate labral debridement, cyst exposure	Proper preoperative planning necessary to ensure proper placement of drill in cyst
Ensure proper subchondral drill placement within cyst	Inadequate release of labrum will obscure view and compromise cyst repair
Ensure no calcium phosphate cement is spilled into the joint	
Allow 10 min for cement fixation	

12 weeks. There is no restriction in ROM for the posterior labral repair.

### Discussion

Arthroscopic spinoglenoid cyst decompression has been described in literature. However, the decompression of a spinoglenoid cyst along with arthroscopic bone grafting of a defect caused by said cyst has never been described. An advantage of this technique is that the patient can have both the shoulder instability and the bony defect addressed under the same anesthetic, therefore decreasing the risks associated with prolonged anesthetic (Table 1).

The limitation of this technique is the lack of long-term outcome studies. Moreover, this technique is technically demanding and requires thorough preoperative planning. There is also a possibility of the calcium phosphate graft leaking into the joint during the filling of the bony cyst. Therefore, meticulous

technique and letting the calcium phosphate set before the removal of the cannula are essential. This adds to the overall surgical time, increasing the risk of swelling. The pearls and pitfalls of this technique are summarized in Table 2.

In conclusion, this technique illustrates the possibility of treating a spinoglenoid cyst with bony erosion via a single arthroscopic approach. Although there are no clinical outcomes reported, this technique can help restore the bony anatomy while minimizing soft-tissue damage.

### References

1. Thompson WAL, Kopell HP. Peripheral entrapment neuropathies of the upper extremity. *N Engl J Med* 1959;260:1261-1265.
2. Chen AL, Ong BC, Rose DJ. Arthroscopic management of spinoglenoid cyst associated with SLAP lesions and suprascapular neuropathy. *Arthroscopy* 2003;19:E15-E21.
3. Matsumine A, Kusuzaki K, Matsubara T, et al. Calcium phosphate cement in musculoskeletal tumour surgery. *J Surg Oncol* 2006;93:212-220.
4. Welkerling H, Raith J, Kastner N, Marschall C, Windhager R. Painful soft tissue reaction to injectable Norian SRS calcium phosphate cement after curettage of enchondromas. *J Bone Joint Surg* 2003;85B:238-239.
5. Mainard D, Galois L. Treatment of a solitary calcaneal cyst with endoscopic curettage and percutaneous injection of calcium phosphate cement. *J Foot Ankle Surg* 2006;45:436-440.
6. Zhang J, Liu W, Schnitzler V, Tancret F, Bouler JM. Calcium phosphate cements for bone substitution: Chemistry, handling and mechanical properties. *Acta Biomater* 2014;10:1035-1049 (review).
7. Oztürkmen Y, Caniklioğlu M, Karamehmetoğlu M, Sükür E. Calcium phosphate cement augmentation in the treatment of depressed tibial plateau fractures with open reduction and internal fixation. *Acta Orthop Traumatol Turc* 2010;44:262-269.
8. Snyder SJ. *Shoulder arthroscopy*. Ed 2. Philadelphia: Lippincott Williams and Wilkins, 2002.
9. Outerbridge RE. The etiology of chondromalacia patellae. *J Bone Joint Surg Br* 1961;43:752-757.