



Open Access

## INVITED REVIEW

Operational Andrology

# The modern testicular prosthesis: patient selection and counseling, surgical technique, and outcomes

Solomon Hayon<sup>1</sup>, Jamie Michael<sup>2</sup>, R Matthew Coward<sup>1</sup>

The testicular prosthesis can be an afterthought for providers when performing an orchiectomy for testicular cancer, torsion, atrophic testis, or trauma. However, data suggest that patients find the offer of a testicular prosthesis and counseling regarding placement to be extremely important from both a pragmatic and a psychosocial perspective. Only two-thirds of men undergoing orchiectomy are offered an implant at the time of orchiectomy and of those offered about one-third move forward with prosthesis placement. The relatively low acceptance rate is in stark contrast with high patient satisfaction and low complication rates for those who undergo the procedure. The most common postoperative patient concerns are minor and involve implant positioning, size, and weight. Herein, we provide an up-to-date review of modern preoperative evaluation, patient selection, expectation management, surgical technique, and expected outcomes for testicular prostheses.

*Asian Journal of Andrology* (2020) 22, 64–69; doi: 10.4103/aja.aja\_93\_19; published online: 19 November 2019

**Keywords:** anorchia; orchiectomy; patient satisfaction; prostheses and implants; testicular neoplasms; testis

## INTRODUCTION

Whether from anorchia, congenital absence of testis, neonatal torsion, vanishing testis, or orchiectomy, well-known effects of testicular loss or absence include both an empty space in the scrotum and a psychological burden for the patient. There were 71 000 new cases of testicular cancer globally in 2018, with most cases presumably treated with orchiectomy, yet only approximately 49 000 testicular implants were manufactured globally in 2018 (personal communication on February 28, 2019; Coloplast Corp., Minneapolis, MN, USA).<sup>1</sup> This indicates a relatively low testicular prosthetic utilization rate compared to the potential. The clinical relevance of testicular prosthesis underutilization is that the absence of a testicle leads to feelings of shame in some men and male adolescents, which can have a profound impact on quality of life.<sup>2</sup> Testicular prostheses represent a simple, effective, and safe surgical solution that alleviates these feelings of altered body image for many patients.<sup>3</sup>

Testicular implants have been in use for over 50 years. The first testicular prosthetic device was implanted in 1939 by Dr. Ralph Bowers of New York City using vitallium, a nonferrous alloy of chromium, cobalt, and molybdenum.<sup>4</sup> Following the use of vitallium, surgeons experimented with lucite, glass marbles, and gel form.<sup>5–7</sup> Later, surgeons focused on creating a more natural appearance and feel of the prosthesis. Prentiss *et al.*<sup>8</sup> first reported the use of solid silicone rubber prosthetic testes in the 1960s. However, the solid silicone implant was still much firmer than the natural testis. Later, Lattimer *et al.*<sup>9</sup> experimented with a gel-filled silicone prosthesis, which was similar in principle to gel-filled breast prostheses and produced much more natural results. Unfortunately, the silicone prosthesis carried some controversy.

In 1992, the FDA halted the use of gel-filled breast implants, and in 1995, the United States discontinued the manufacture of silicone gel-filled testicular prostheses due to emerging concerns about the association of silicone implants and connective tissue disease.<sup>3,10,11</sup> However, expert panels in the United States and United Kingdom failed to find conclusive evidence of this association. In 1995, Robinson *et al.*<sup>12</sup> analyzed 300 silicone breast implants and found that there was a high rate of device disruption and subsequent “gel bleed”. Afterward, researchers developed a new saline-filled testicular prosthesis. In a prospective study of 149 patients from 18 institutions, Turek and colleagues found that none of the patients developed connective tissue diseases at 1 year, and they concluded that saline-filled prostheses were safe and well-tolerated.<sup>3</sup>

The current manufacturers of testicular implants worldwide include GC Aesthetics (Dublin, Ireland), Aart (Carson City, NV, USA), Coloplast, Osteotec (Christchurch, New Zealand), Rigicon (Hauppauge, NY, USA), Sebbin (Boissy-l’Aillerie, France), Uromed (Oststeinbek, Germany), and Promedon (Córdoba, Argentina). All the current implants are silicone, filled with gel, solid elastomer, or saline. The only FDA-approved testicular implant for adults and children in the US is a saline-filled implant called the Torosa™, manufactured by Coloplast Corp. The Coloplast Torosa™ also represents the testicular prosthesis with the largest global market share among available testicular implants worldwide. In the US, most commercial insurance companies cover the cost of testicular prosthesis placement for patients undergoing simultaneous orchiectomy. Testicular prostheses cost around \$2500–\$3000.<sup>13</sup>

Among men who receive a testicular implant, the most common reasons include undescended/atrophic testes (35%), orchiectomy for

<sup>1</sup>Department of Urology, University of North Carolina School of Medicine, Chapel Hill, NC 27500-7235, USA; <sup>2</sup>University of North Carolina School of Medicine, Chapel Hill, NC 27500-7235, USA.

Correspondence: Dr. S Hayon (solomon.hayon@unhealth.unc.edu) or Dr. RM Coward (mcoward@med.unc.edu)

Received: 07 March 2019; Accepted: 01 July 2019

testis tumor (23%), testis torsion (17%), metastatic prostate cancer (16%), epididymitis/orchitis (8%), and trauma (1%).<sup>14,15</sup>

### PATIENT SELECTION AND COUNSELING

For a procedure as straightforward as placement of a testicular prosthesis, a patient's decision whether or not to obtain one is complex and deeply personal. Some men do not mind the loss of a testicle and see the newly shaped scrotum as "out of sight, out of mind". In contrast, the loss can be an identity-altering crisis for other men, with 17% of long-term testicular cancer survivors reporting a change in body image after orchiectomy.<sup>16</sup> A testicular prosthesis may help alleviate these feelings, with 50%–60% of patients reporting improved body image after testicular prosthesis placement.<sup>17,18</sup> Motivating factors for pursuing a prosthesis may be related to a desire to feel "normal," with concerns regarding self-image often pushing men toward surgery.<sup>19</sup>

Simply the offer of a prosthesis can be psychologically beneficial, with data showing that men not offered an implant are more likely to report feelings of loss than men who are offered, but subsequently reject a prosthesis.<sup>2</sup> Supporting this claim is the fact that approximately 90% of patients believe the offer of a testicular prosthesis to be an important part of preorchiectomy counseling.<sup>20,21</sup> The offer must be accompanied by thorough discussion, and in a study of testicular cancer patients where 100% were offered a prosthesis, 31% of patients believed that their counseling with respect to prosthesis was too short, and 8.5% went as far as to say it was insufficient.<sup>21</sup>

Despite a relatively low complication rate, and possible simultaneous implantation while undergoing orchiectomy, studies show a varying rate of prosthesis offered at the time of orchiectomy. As seen in **Table 1**, approximately one-third of patients are not offered a prosthesis at the time of orchiectomy.<sup>2,20,22</sup> Of the patients actually offered a prosthesis, usually about one-third accept, with some studies showing acceptance rates as high as 87%.<sup>2,20–23</sup> Positive predictive factors for prosthetic placement include having an orchiectomy performed at an academic institution and patient age >35 years.<sup>22</sup> As the authors of this paper practice at an academic institution, our belief is that offering a prosthesis is almost always appropriate, but timing is patient- and situation-dependent.

A 2001 study found that 2% of postorchiectomy patients were advised by their surgeon to not obtain an implant.<sup>20</sup> The reasons were not listed in the questionnaire, but commonly cited reasons why concurrent prosthesis is contraindicated are when previous prosthesis has been extruded, previous scrotal surgery has occurred, or radiotherapy to the region has severely compromised scrotal skin (increasing risk of prosthesis extrusion).<sup>24</sup> Another reason providers may suggest patients postpone testicular implant is when adjuvant chemotherapy or radiotherapy is planned. A 2017 series of 587 patients examined if adjuvant therapy increases the risk of prosthetic complication. The retrospective review demonstrated a complication rate of 4.3% in the adjuvant chemotherapy group, 6.2% in the radiotherapy group, and 5.1% in the overall study population. This equated to no significant difference in prosthesis-related complications between overall study population and both the chemotherapy ( $P = 0.76$ ) and radiotherapy ( $P = 0.71$ ) groups, and the authors therefore concluded that prosthesis insertion at the time of orchiectomy is a safe procedure even for those undergoing adjuvant treatment.<sup>25</sup> This finding was in line with a prior study which reported that there were no situations where chemotherapy was delayed due to infection or other complications related to prosthesis. Even for patients not undergoing adjuvant treatment, a concurrent prosthesis placement does not appear to significantly change the complication or readmission rate compared with orchiectomy alone.<sup>26</sup>

The pediatric population is another group where there is debate regarding simultaneous prosthesis insertion at the time of orchiectomy. This is particularly relevant as approximately 10% of testicular implants are performed on patients under the age of 16 years.<sup>15</sup> One of the early testicular implant studies in the pediatric population by Beer and Kay<sup>27</sup> argued for earlier implantation, stating that it may help mitigate the negative psychological impact of a child missing a testicle as he goes through adolescence. However, the scrotum of a prepubertal patient will likely not accommodate an adult prosthesis, and the patient may need a second surgery to upsize the prosthesis after he reaches adulthood. Some authors argue that this first surgery is still necessary, as this "placeholder" prosthesis will prevent the scrotum from becoming contracted and asymmetrical over time.<sup>24</sup> A 2007 study went on to refute claims that a contracted scrotum creates future issues, reporting

**Table 1: Literature review of testicular implant patient satisfaction**

Study	Patient population (n=implant accepted)	Percentage of accept (%)	Percentage of not offered (%)	Overall satisfaction	Position	Size	Consistency	Shape	Weight	Other
Zilberman <i>et al.</i> <sup>18</sup> (Israel, 2007)	Teenager (n=13)	–	–	100% have again	38% too high	23% too small	38% too heavy	46% not correct	–	15% not comfortable
Skoogh <i>et al.</i> <sup>2</sup> (Sweden, 2009)	Testicular cancer (n=81)	24	35	–	–	–	–	–	–	–
Yossepowitch <i>et al.</i> <sup>23</sup> (Israel, 2011)	Testicular cancer (n=86)	87	–	77% good to excellent	39% too high	11% too small 16% too large	70% too firm	–	22% too heavy; 13% too light	14% not comfortable
Adshead <i>et al.</i> <sup>20</sup> (UK, 2011)	Testicular cancer (n=71)	30	33	73% good to excellent	27% not correct	16% too small 21% too large	–	32% not correct	21% too heavy; 9% too light	–
Dieckmann <i>et al.</i> <sup>21</sup> (Germany, 2015)	Testicular cancer (n=171)	27	0	85% high to very high	30% too high	24% too small	52% too firm	15% inconvenient	–	–
Robinson <i>et al.</i> <sup>26</sup> (UK, 2016)	Testicular cancer (n=228)	55	53	–	–	–	–	–	–	–
Clifford <i>et al.</i> <sup>34</sup> (USA, 2017)	Testicular cancer (n=40)	–	–	88% have again	20% not correct	15% too small 8% too large	44% too firm	13% not correct	10% too heavy	8% not comfortable
Nichols <i>et al.</i> <sup>22</sup> (USA, 2018)	Testicular cancer (n=59)	25	42	90% with overall look	21% not correct	19% not correct	41% not correct	–	10% not correct	49% occasional pain

--: data not included in the referenced study

that in 19 adolescent patients who underwent testicular prosthesis placement after puberty, there was no change in technical difficulty or complications despite a contracted appearance of the hemiscrotum.<sup>18</sup>

In recent years, a new reason for prosthesis, gender reassignment, has emerged. It is possible that the increased frequency of gender reassignment surgery in the past decade has altered the list of most common reasons for a prosthesis, yet there are sparse data regarding best practices in these patients.<sup>28,29</sup> To our knowledge, there are no large studies that examine the long-term outcomes in this population, although several individual authors have described their experiences regarding how and when to perform prosthesis placement. Monstrey advises performing testicular prosthesis placement approximately 1 year after penile prosthesis.<sup>28</sup> Selvaggi suggests inserting testicular prosthesis at the same time as penile prosthesis placement, usually 6–12 months after original scrotophalloplasty.<sup>30</sup> In the setting of metoidioplasty, Djordjevic reports performing a one-stage procedure that involves lengthening the hypertrophied clitoris, creating a scrotum from the labia majora, and simultaneously inserting bilateral prosthetics.<sup>31</sup> As this patient community continues to evolve and grow, it will be interesting to see how the issue of testicular prosthesis is approached.

### SURGICAL TECHNIQUE AND OUTCOMES

There are many different scenarios when placement of a testicular prosthesis is indicated, and the exact surgical technique and implant choice will depend on patient age, hospital setting, and reason for testicular loss. Thorough counseling and expectation management set the stage for a successful outcome, and consistent surgical technique with attention to details can help mitigate the relatively small risks of the procedure and sources for patient dissatisfaction.

The authors of this paper perform most of our implants on a scheduled basis at an academic institution, and we prefer the only FDA-approved device in the USA, the Coloplast Torosa™ implant (Figure 1). The vast majority of implants placed in adults will be size large, although occasionally we will suggest a medium implant if the patient's contralateral testis is atrophic (in order to provide better symmetry). Demonstrating the size to the patient and involving him in the decision preoperatively will lead to better patient satisfaction regarding the size. We will also consider a medium for a patient with an underdeveloped or scarred scrotum or for an adolescent or child. Upsizing for a child or adolescent is appropriate if possible, so that he can later “grow into” the device, lowering the necessity for a revision during adulthood. Coloplast provides a sizing guide along with other helpful resources online here: <https://www.coloplastmd.com/diseases/testicular-prosthesis/>.

A variety of different anesthetic approaches can be utilized. We prefer using general anesthesia with adjunctive local anesthetic, although the procedure can easily be completed with total intravenous anesthesia or even local anesthesia with oral sedation. The anesthetic requirement will primarily depend on whether the testicular implant is being placed during a simultaneous orchiectomy or as a primary procedure, and whether scarring or additional difficulties are anticipated.

Because the size of the device is determined preoperatively, we prefer to prep and fill the implant while the anesthesiologist is inducing anesthesia. The process only takes several minutes, but it requires the primary surgeon's attention to get the “feel” just right. We do not perform the procedure often enough to have a scrub tech familiar enough with the filling process to allow this to be done independently by the tech during the surgical procedure. In addition, we feel that prepping and filling the device before the start of the case

minimizes the risk of exposure of the device to any skin bacteria and also minimizes the surgical time, which is generally about 15 min. The surgeon scrubs in for this process. The supplies required for the filling process include a sterile 21-gauge butterfly needle connected to a Luer lock adapter, sterile, isotonic, pyrogen-free sodium chloride United States Pharmacopeial Convention (U.S.P) solution, and a 20 cc syringe. The syringe is connected to the butterfly needle and is filled with 20 cc of sterile saline (Figure 2). There are two ends to the implant: one end with an injection port for filling (Figure 3a) and the opposite end which includes a suture tab (Figure 3b). After piercing the injection port, begin injecting saline into the implant, and after every several milliliters, pull back to remove an equal amount of air, alternating between injecting saline and removing air until the implant is almost completely filled. Until the surgeon is familiar with this process, it is easier to do this with an assistant manipulating the syringe while the surgeon holds the device and needle. It is important to leave the needle in during this process until the surgeon is happy with the “feel” because the injection port can only be accessed up to 5 times as per the manufacturer's label before the implant would be at risk for spontaneous leak. Initially, the surgeon should overfill the prosthesis by injecting saline into the prosthesis to the appropriate overfill volume according to the selected implant size and the fill volume chart (Table 2). For a large-sized implant, we usually initially inject about 18 cc. In order to remove all air, aspirate out the air bubble and 2–3 additional ccs, leaving a final fill volume of approximately 15 cc before withdrawing the needle. In our experience, the lower



Figure 1: Torosa™ saline-filled testicular prostheses by Coloplast. Figures 1–3 are reproduced with permission from Coloplast Corp.

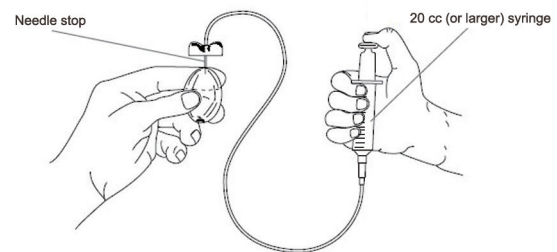


Figure 2: Testicular prosthesis filling procedure.

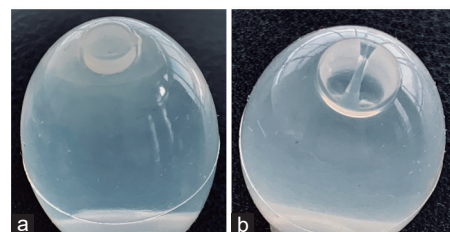


Figure 3: Torosa™ testicular prosthesis (a) injection port and (b) suture tab.



limit of the recommended final volume range results in the most natural feel of the implant. It should be noted that just 1 or 2 cc can be the difference between an implant that feels “natural” or “normal” and one that feels hard and unnatural. When the final fill volume is reached, the implant should be ballotable with enough “give” that it can be squeezed, but not so much “give” that a palpable dimple or notch is felt when it is squeezed. Be sure to completely remove any remaining air bubble as the needle is withdrawn. If the implant needs an adjustment, do not hesitate to re-access the injection port to add or remove a milliliter or two. After the implant is prepped, we prefer to leave it soaking in a bacitracin solution in the supplied dish until it is needed for the case. Although there is no evidence to support this practice, we believe that it may help minimize introduction of bacteria to the implant.

After the implant is prepped and anesthesia has been induced, the scrotum and groin are carefully shaved with a safety razor, and the skin is washed with a 5-min chlorhexidine scrub. The skin is sterilely dried and then formally prepped with a 2% (*w/v*) chlorhexidine gluconate in 70% (*v/v*) isopropyl alcohol prep stick. After sterile draping, the surgical incision is made sharply. We prefer a 2.5-cm subinguinal incision, just medial and inferior to the external inguinal ring in the exact same place we make an incision for a subinguinal microsurgical varicocele repair. A subinguinal incision is close enough to the scrotum to allow for simple placement, and it has the added benefits of easier wound healing with subcuticular closure, lower risk of wound infection, and less scrotal swelling postoperatively than with a scrotal incision. An inguinal incision can also be used, particularly when simultaneous radical orchiectomy is performed. If a testicular implant is being considered during a scrotal exploration for testicular torsion, we prefer an approach of bilateral horizontal high scrotal incisions because a testicular implant has a slightly lower risk of extrusion from a high scrotal incision compared to a midline scrotal incision, and because there is less direct pressure of the implant onto the surgical site during wound healing.

The subinguinal incision is carried down through Camper’s and Scarpa’s fascial layers using electrocautery. Once the wound is opened down beneath Scarpa’s fascia, the track is developed toward the scrotum for the implant. This can often be initially performed with a combination of an army-navy retractor along the surgeon’s index finger, but if scarring from a previous procedure is encountered, the space can also be developed with gentle spreading with or without some electrocautery. From within a subinguinal incision, a long nasal speculum is preferred by these authors for gentle spreading and to make this space which can usually be developed within just a few seconds. An empty sponge stick may alternatively be used, or in the case of an inguinal incision, an empty sponge stick may be preferred for adequate length to reach the most dependent area of the scrotum inferiorly. During a radical orchiectomy, this step is unnecessary, as the implant can be placed directly back into the space from which the testicle came.

**Table 2: Fill volume chart for the Coloplast Torosa™ testicular implant**

Testicular size	Over-fill volume range (ml)		Final fill volume range (ml)	
	Lower limit	Upper limit	Lower limit	Upper limit
Extra small	7	9	5	6
Small	10	12	8	9
Medium	13	15	11	12
Large	17	19	15	16

Table adapted with permission from Coloplast Corp.

We do not recommend trying to create a subdartos pouch or suturing the implant into place using the suture tab. We also do not recommend closing the scrotal neck in adults. The cosmetic outcome of the procedure is much more natural if the implant is not fixed to the scrotal skin, sutured into place, or with the scrotal neck closed, all of which provide the implant the ability to move around within the hemiscrotum just as a natural testicle is allowed to be able to do. Once the space is developed in the most dependent portion of the scrotum for the implant, we prefer to gently slide it in along the blades of the nasal speculum like a child going down a slide on a playground. Anecdotally, we have not had any implants migrate despite not closing the scrotal neck. We do recognize that other surgeons may elect to close the surgical neck to prevent prosthesis displacement, but we believe that additional sutures may lead to excessive scarring or nerve impingement leading to patient discomfort.

Another important key to a successful result for the procedure is placing the implant with the smooth injection port end of the implant inferiorly. Because the suture tab end has an irregular notch which does not feel natural, this irregular end is less noticeable if placed superior-facing if a suture is not desired. In this way, the portions of the implant which are palpable to the patient, and which are the sides and the bottom, are all smooth. Note that this is contrary to the design of the implant. After the implant is adjusted to be sitting dependently, the nasal speculum is withdrawn and the wound is copiously irrigated with bacitracin solution.

Scarpa’s fascia is closed with 3-0 monocryl in running fashion burying the knots, and the skin is closed with 4-0 Vicryl Rapide in subcuticular fashion. The wound is dressed with Dermabond. An athletic supporter is placed, although no scrotal fluffs or padding is utilized in order to minimize the risk of the implant not healing in the most dependent position in the scrotum. The patient is instructed to gently pull down on the implant and to keep it in its preferred dependent position for the first 2 weeks postoperatively. Ice packs, Tylenol, and nonsteroidal anti-inflammatory drugs are the mainstay of postoperative pain control. The final appearance of a testicular implant placed during radical orchiectomy is seen in **Figure 4**.

To reduce the incidence of infection, which is already quite low for testicular implants, we have several preventative measures that we



**Figure 4:** Cosmetic result 2 weeks postoperatively from left inguinal orchiectomy and placement of testicular implant. The figure is reproduced with patient permission.

recommend. Firstly, we prefer shaving with a safety razor rather than using clippers. We have adopted this practice in accordance with the Sexual Medicine Society of North America's Position Statement.<sup>32,33</sup> After shaving, we do a chlorhexidine scrub for 5 min before prepping with 2% (*w/v*) chlorhexidine gluconate in 70% (*v/v*) isopropyl alcohol prep stick. Preincision antibiotics include vancomycin and gentamicin. After the implant is prepped, it is soaked in a solution of bacitracin. The surgical team all change gloves before handling the implant, and after the implant is slid down into place, the wound is copiously irrigated with bacitracin. Prepping the device prior to incision ensures an expeditious case minimizing the risk of exposure of the implant to the skin flora. These authors do not prefer to use postoperative antibiotics.

In summary, the most important surgical pearls for the placement of a testicular prosthesis include the following: prepping the device before making the surgical incision, having the final fill volume on the lower end of the final fill volume range as recommended by the manufacturer, utilizing a subinguinal incision, making the space for the implant with a nasal speculum otherwise minimizing scrotal dissection, not creating a subdartos pouch, not suturing the implant into place, positioning it with the smooth injection port inferiorly, not closing the scrotal neck, and instructing the patient to manipulate the implant inferiorly during the first 2 weeks of the recovery period.

Even in a well-selected patient utilizing the best surgical technique, there is always a risk of postoperative complication with prosthesis placement. The complication rate varies by clinical scenario, and a review of 2500 patients by Marshall demonstrated that implants performed for epididymitis/orchitis had the highest overall complications rate at 31%. In addition, there was a 22% risk of transient scrotal contraction, 11% risk of persistent scrotal contraction, 8% risk of wound dehiscence/prosthetic extrusion, 3% risk of infection, and 3% risk of postoperative pain. Conversely, implants for patients who underwent orchiectomy for testicular tumors had the lowest overall complication rate at 11%.<sup>14</sup> A more recent study showed that major complications are relatively rare, with a general extrusion rate of about 2% and migration rate of <1%. In this study population, there was a 9% incidence of postoperative pain and a 1%–2% incidence of minor complications such as scrotal edema, hematoma, or numbness.<sup>3</sup>

In terms of reintervention, the literature shows that 4.7% of patients require additional surgery, with 0.4% eventually needing prosthesis removal.<sup>21,26</sup> Interestingly, surgical outcomes have been shown to be very similar between those who received a concurrent prosthesis at the time of orchiectomy and those who underwent placement in a subsequent procedure. In a study of 904 patients, there was no significant difference in the length of hospital stay ( $P = 0.387$ ), 30-day hospital readmission rate ( $P = 0.539$ ), and overall removal/revision rate, which was 0.88% for the concurrent implant group compared to 1.3% in the group overall.<sup>26</sup>

The complication rates above focus on technical measures of success, but it is important to remember that a testicular implant is ultimately an elective procedure and outcomes regarding patient satisfaction are equally to, and in some cases may be even more important than, short-term complications and readmission. **Table 1** provides a summary of several patient satisfaction studies, but in general, testicular implant satisfaction is extremely high, with multiple studies reporting that almost 90% of patients would have the procedure again.<sup>21,34</sup> Even stronger satisfaction numbers were reported by Zilberman *et al.*<sup>18</sup> in 2007, who found that 100% of patients would recommend the operation to a friend with a similar problem, and 100% of patients would get the prosthetic replaced

if it had to be removed. Variables most significantly associated with satisfaction are synchronous placement, appropriate size, appropriate positioning, and comfort.<sup>34</sup> Conversely, dissatisfaction with firmness and positioning are significantly associated with lower satisfaction.<sup>23</sup> Numerous studies have reported on these outcome measures, and approximately a third are unhappy with the implant size, 44%–70% believe the implant is too firm, and 20%–40% believe the implant is positioned too high in the scrotum (**Table 1**).<sup>18,20–23,34</sup> These satisfaction measures demonstrate the importance of surgical experience and attention to detail in testicular prosthesis implantation in order to achieve the best outcomes.

## CONCLUSION

The future of testicular implants is primarily geared toward improving patient satisfaction measures by creating a more natural feeling, natural appearing, and potentially a hormonally active prosthesis. One promising development regarding shape and feel is a new prosthesis with an elliptical shape that better mimics a normal testis.<sup>35</sup> Researchers are attempting to develop a testicular prosthesis that provides androgen replacement therapy, and there has been a successful study of a novel Silastic testicular prosthesis that can release testosterone in rats.<sup>36</sup> Possibly the most practical innovation that may affect the field of testicular prosthesis implantation involves the cost of care. To bring down the financial burden for patients, some surgeons are offering testicular prostheses under local anesthesia, which has been shown to decrease total procedural cost for patients paying out-of-pocket.<sup>37</sup>

Regardless of future innovations in testicular implant design or surgical technique, testicular prostheses will undoubtedly be a large part of postorchietomy management. When preparing to perform an orchiectomy, the offer of a prosthesis can help alleviate patient anxiety regarding the loss of a testicle, and thorough counseling can lead to an informed patient decision based on the patient's own personal priorities. Concurrent testicular prosthesis implantation at the time of orchiectomy has been shown to have similar outcomes to orchiectomy alone, so whenever possible, this counseling should be part of the early surgical planning discussion. However, delayed prosthesis implantation is still a viable option, even for teenagers who may have not undergone prosthesis placement at the time of their original orchiectomy. Patients' main complaints postoperatively are regarding implant feel, size, weight, and position. The authors of this review have found that keeping the final fill volume relatively lower, not suturing the implant into place, and having the patient manipulate the implant downward during the first 2 postoperative weeks can subjectively improve these outcome measures. As patient satisfaction is the most important measure of success, thoughtful patient counseling and management of expectations are of paramount importance.

## AUTHOR CONTRIBUTIONS

JM wrote the sections on the history of implants and future technology. SH reviewed current literature and wrote the sections regarding psychosocial impact of prosthesis placement, patient satisfaction, and surgical outcomes. SH edited the paper for consistency. RMC provided clinical expertise and wrote the section on surgical technique. All authors read and approved the final manuscript.

## COMPETING INTERESTS

All authors declared no competing interests.

## ACKNOWLEDGMENTS

Figure 1, 2, 3, Table 2, and testicular implant market data were provided by Coloplast Corporation (Minneapolis, MN, USA) with written permission.

## REFERENCES

- 1 Ferlay J, Colombet M, Soerjomataram I, Mathers C, Parkin DM, *et al*. Estimating the global cancer incidence and mortality in 2018: GLOBOCAN sources and methods. *Int J Cancer* 2019; 144: 1941–53.
- 2 Skoogh J, Steineck G, Cavallin-Stahl E, Wilderang U, Hakansson UK, *et al*. Feelings of loss and uneasiness or shame after removal of a testicle by orchidectomy: a population-based long-term follow-up of testicular cancer survivors. *Int J Androl* 2011; 34: 183–92.
- 3 Turek PJ, Master VA; Testicular Prosthesis Study Group. Safety and effectiveness of a new saline filled testicular prosthesis. *J Urol* 2004; 172: 1427–30.
- 4 Joseph Girsdanský HF. Use of a vitallium testicular implant. *Am J Surg* 1941; 53: 514.
- 5 Rea CE. An evaluation of therapy for the undescended testis. *J Tn State Med Assoc* 1961; 54: 75–80.
- 6 Hazzard CT. The development of a new testicular prosthesis. *J Urol* 1953; 70: 959–60.
- 7 Baumrucker GO. Testicular prosthesis for an intracapsular orchidectomy. *J Urol* 1957; 77: 756–8.
- 8 Prentiss RJ, Boatwright DC, Pennington RD, Hohn WF, Schwartz MH. Testicular prosthesis: materials, methods and results. *J Urol* 1963; 90: 208–10.
- 9 Lattimer JK, Vakili BF, Smith AM, Morishima A. A natural-feeling testicular prosthesis. *J Urol* 1973; 110: 81–3.
- 10 Henderson J, Culkin D, Mata J, Wilson M, Venable D. Analysis of immunological alterations associated with testicular prostheses. *J Urol* 1995; 154: 1748–51.
- 11 Bodiwala D, Summerton DJ, Terry TR. Testicular prostheses: development and modern usage. *Ann R Coll Surg Engl* 2007; 89: 349–53.
- 12 Robinson OG Jr., Bradley EL, Wilson DS. Analysis of explanted silicone implants: a report of 300 patients. *Ann Plast Surg* 1995; 34: 1–6.
- 13 New York Urology Specialists. Testicular Prosthesis – Cost and Insurance Coverage; 2018. Available from: <https://www.newyorkurologyspecialists.com/mens-health/testicular-implants/cost-insurance-coverage/>. [Last accessed on 2019 Jul 01].
- 14 Marshall S. Potential problems with testicular prostheses. *Urology* 1986; 28: 388–90.
- 15 Mohammed A, Yassin M, Hendry D, Walker G. Contemporary practice of testicular prosthesis insertion. *Arab J Urol* 2015; 13: 282–6.
- 16 Rossen P, Pedersen AF, Zachariae R, von der Maase H. Sexuality and body image in long-term survivors of testicular cancer. *Eur J Cancer* 2012; 48: 571–8.
- 17 Incrocci L, Bosch JL, Slob AK. Testicular prostheses: body image and sexual functioning. *BJU Int* 1999; 84: 1043–5.
- 18 Zilberman D, Winkler H, Kleinmann N, Raviv G, Chertin B, *et al*. Testicular prosthesis insertion following testicular loss or atrophy during early childhood—technical aspects and evaluation of patient satisfaction. *J Pediatr Urol* 2007; 3: 461–5.
- 19 Chapple A, McPherson A. The decision to have a prosthesis: a qualitative study of men with testicular cancer. *Psychooncology* 2004; 13: 654–64.
- 20 Adshead J, Khoubehi B, Wood J, Rustin G. Testicular implants and patient satisfaction: a questionnaire-based study of men after orchidectomy for testicular cancer. *BJU Int* 2001; 88: 559–62.
- 21 Dieckmann KP, Anheuser P, Schmidt S, Soyka-Hundt B, Pichlmeier U, *et al*. Testicular prostheses in patients with testicular cancer – acceptance rate and patient satisfaction. *BMC Urol* 2015; 15: 16.
- 22 Nichols PE, Harris KT, Brant A, Manka MG, Haney N, *et al*. Patient decision-making and predictors of genital satisfaction associated with testicular prostheses after radical orchidectomy: a questionnaire-based study of men with germ cell tumors of the testicle. *Urology* 2019; 124: 276–81.
- 23 Yossepowitch O, Aviv D, Wainchwaig L, Baniel J. Testicular prostheses for testis cancer survivors: patient perspectives and predictors of long-term satisfaction. *J Urol* 2011; 186: 2249–52.
- 24 Kogan S. The clinical utility of testicular prosthesis placement in children with genital and testicular disorders. *Transl Androl Urol* 2014; 3: 391–7.
- 25 Musi G, Cozzi G, Bianchi R, Mistretta FA, Tringali VM, *et al*. Safety of testicular prosthesis insertion at the time of radical orchidectomy for testis cancer in patients undergoing adjuvant therapies. *Eur Urol Suppl* 2017; 16: e1897.
- 26 Robinson R, Tait CD, Clarke NW, Ramani VA. Is it safe to insert a testicular prosthesis at the time of radical orchidectomy for testis cancer: an audit of 904 men undergoing radical orchidectomy. *BJU Int* 2016; 117: 249–52.
- 27 Beer M, Kay R. Testicular prostheses. *Urol Clin North Am* 1989; 16: 133–8.
- 28 Monstrey SJ, Ceulemans P, Hoebeke P. Sex reassignment surgery in the female-to-male transsexual. *Semin Plast Surg* 2011; 25: 229–44.
- 29 Lane M, Ives GC, Sluiter EC, Waljee JF, Yao TH, *et al*. Trends in gender-affirming surgery in insured patients in the United States. *Plast Reconstr Surg Glob Open* 2018; 6: e1738.
- 30 Selvaggi G, Hoebeke P, Ceulemans P, Hamdi M, Van Landuyt K, *et al*. Scrotal reconstruction in female-to-male transsexuals: a novel scrotoplasty. *Plast Reconstr Surg* 2009; 123: 1710–8.
- 31 Djordjevic ML, Stanojevic D, Bizic M, Kojovic V, Majstorovic M, *et al*. Metoidioplasty as a single stage sex reassignment surgery in female transsexuals: belgrade experience. *J Sex Med* 2009; 6: 1306–13.
- 32 Sexual Medicine Society of North America. Position Statement: Razors and Preoperative Preparation of the Male Genitalia; 2019. Available from: <http://www.smsna.org/V1/about/position-statements>. [Last accessed on 2019 Jul 01].
- 33 Grober ED, Domes T, Fanipour M, Copp JE. Preoperative hair removal on the male genitalia: clippers vs. razors. *J Sex Med* 2013; 10: 589–94.
- 34 Clifford TG, Burg ML, Hu B, Loh-Doyle J, Hugen CM, *et al*. Satisfaction with testicular prosthesis after radical orchidectomy. *Urology* 2018; 114: 128–32.
- 35 Ning Y, Cai Z, Chen H, Ping P, Li P, *et al*. Development and clinical application of a new testicular prosthesis. *Asian J Androl* 2011; 13: 903–4.
- 36 Chen HX, Yang S, Ning Y, Shao HH, Ma M, *et al*. Novel double-layer silastic testicular prosthesis with controlled release of testosterone *in vitro*, and its effects on castrated rats. *Asian J Androl* 2017; 19: 433–8.
- 37 Alom M, Ziegelmann M, Savage J, Miest T, Kohler TS, *et al*. Office-based andrology and male infertility procedures – a cost-effective alternative. *Transl Androl Urol* 2017; 6: 761–72.

This is an open access journal, and articles are distributed under the terms of the Creative Commons Attribution-NonCommercial-ShareAlike 4.0 License, which allows others to remix, tweak, and build upon the work non-commercially, as long as appropriate credit is given and the new creations are licensed under the identical terms.

©The Author(s) (2019)

