


## Case Report

# Propofol infusion syndrome complicated with mitochondrial myopathy, encephalopathy, lactic acidosis, and stroke-like episodes: a case report

Junji Shimizu,<sup>1</sup>  Takahisa Tabata,<sup>1</sup> Yasuyuki Tsujita,<sup>1</sup> Tetsunobu Yamane,<sup>1</sup> Yutaka Yamamoto,<sup>2</sup> Takahito Tsukamoto,<sup>2</sup> Nobuhiro Ogawa,<sup>2</sup> Hyou Kim,<sup>2</sup> Makoto Urushitani,<sup>2</sup> and Yutaka Eguchi<sup>1</sup>

<sup>1</sup>Emergency and Intensive Care Unit, Shiga University of Medical Science Hospital, and <sup>2</sup>Division of Neurology, Shiga University of Medical Science, Otsu, Shiga, Japan

**Background:** Propofol infusion syndrome (PRIS) is a rare but lethal complication of propofol use. It has been suggested that the pathological mechanism of PRIS involves mitochondrial disorder caused by propofol.

**Case Presentation:** A 24-year-old woman who had been diagnosed with mitochondrial myopathy, encephalopathy, lactic acidosis, and stroke-like episodes was admitted to our hospital with impaired consciousness and myoclonus. To control the non-convulsive status epilepticus, propofol was administered. Arterial blood gas revealed metabolic acidosis, and creatinine kinase was elevated. The patient was diagnosed with PRIS. We treated her with interruption of propofol. She required mechanical ventilation for 25 days. After rehabilitation, she recovered and was discharged.

**Conclusion:** Mitochondrial disorder is a risk factor for PRIS. It is important for clinicians to be aware that mitochondrial disorder is a risk factor for PRIS, especially under conditions of critical illness and status epilepticus.

**Key words:** MELAS syndrome, mitochondrial disease, propofol, propofol infusion syndrome, status epilepticus

## INTRODUCTION

PROPOFOL INFUSION SYNDROME (PRIS) is a rare but life-threatening complication of propofol. The pathological mechanism of PRIS has been suggested to be mitochondrial disorder caused by propofol.<sup>1,2</sup> Mitochondrial myopathy, encephalopathy, lactic acidosis, and stroke-like episodes (MELAS) is a mitochondrial disorder caused by mutations in the genes in mitochondrial DNA. The pathological mechanism of MELAS is mitochondrial dysfunction that leads to insufficient energy generation.<sup>3</sup> Therefore, MELAS is considered a risk factor for PRIS.<sup>1,2</sup> However, there are few reports on PRIS associated with MELAS. We

report herein on a case of MELAS accompanying PRIS with severe lactic acidosis and rhabdomyolysis.

## CASE REPORT

A 24-YEAR-OLD woman was admitted to our hospital with mildly impaired consciousness and myoclonus in the extremities. She had been diagnosed with MELAS at 21 years of age. Genetic testing revealed a 3271 T>C transition in the *MT-TL1* gene, clinically confirming the diagnosis of MELAS.

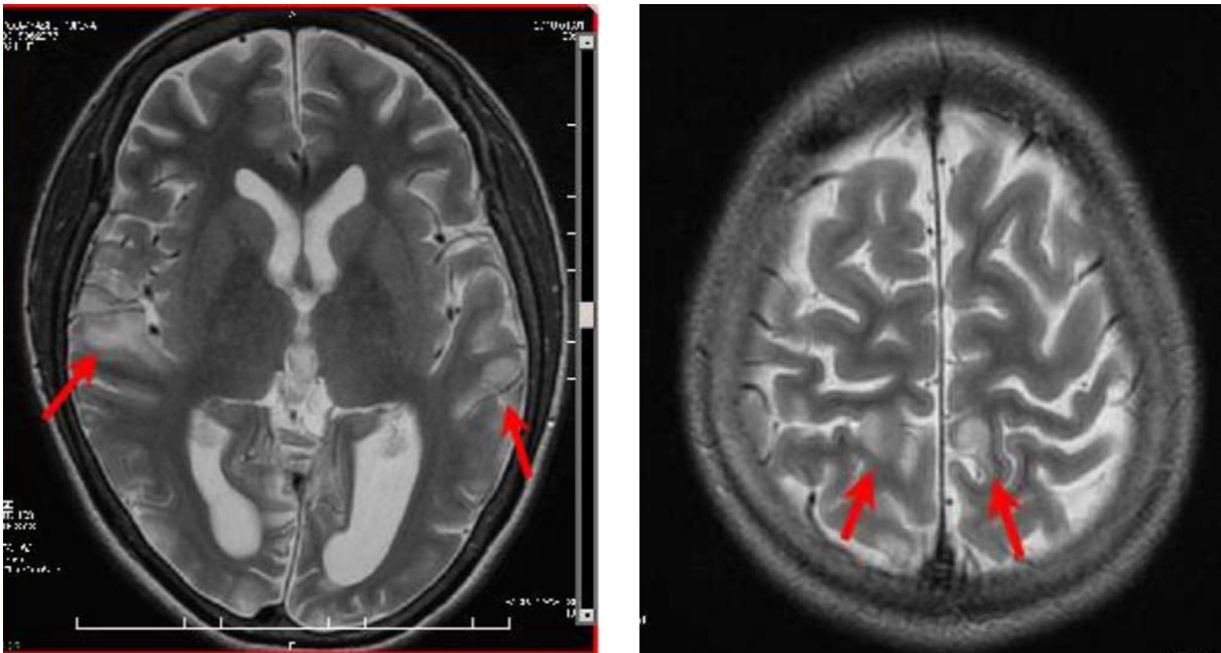
After admission to hospital, neurological examination showed myoclonic movement in the extremities, mandible, and trunk. Muscle weakness was detected in the upper and lower limbs bilaterally. A laboratory examination showed increased serum pyruvic acid (2.1 mg/dL) and lactate (75 mg/dL). Brain magnetic resonance imaging showed bilateral high-intensity lesions in the temporal and parietal lobes of the cortical and subcortical areas in T2 weighted imaging (Fig. 1). Antiepileptic drugs levetiracetam, perampanel, lacosamide, and clobazam were initiated. L-arginine, coenzyme Q10, and L-carnitine

**Corresponding:** Junji Shimizu, MD, Emergency and Intensive Care Unit, Shiga University of Medical Science Hospital, Seta Tsukinowa-cho, Otsu, Shiga 520-2192, Japan. E-mail: jushimi77@gmail.com.

Received 24 Jul, 2019; accepted 10 Nov, 2019; online publication 4 Dec, 2019

### Funding information

No funding information provided.



**Fig. 1.** Arrows indicate bilateral high-intensity lesions in the temporal and parietal lobes of the cortical and subcortical areas in T2-weighted images.

aimed at supporting mitochondrial energy production were given simultaneously.

As the impaired consciousness and myoclonus persisted for 2 weeks, we undertook brain magnetic resonance imaging again, which revealed high-intensity lesions in the right cortical temporal lobe, and arterial spin labeling showed increased blood flow in the bilateral frontal and temporal cortex. Electroencephalography revealed high-amplitude slow and spiked waves. We diagnosed the patient with non-convulsive status epilepticus.

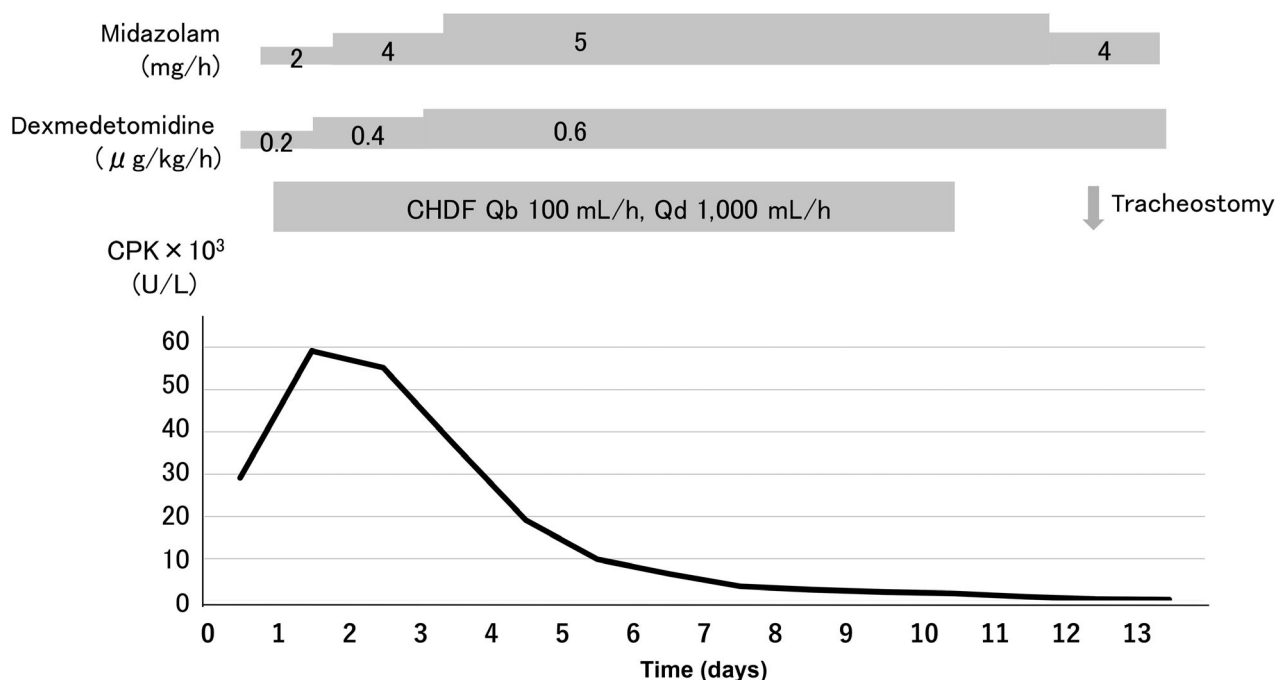
To control the seizures, propofol was given at a dose of 2.7 mg/kg/h for 12 h and then increased to 5.4 mg/kg/h, with midazolam added at a dose of 2 mg/h. On day 5, the urine appeared brown and arterial blood gas revealed metabolic acidosis (pH 7.261, pCO<sub>2</sub> 33.0 mmHg, HCO<sub>3</sub><sup>-</sup> 14.4 mmol/L, and lactate 99 mg/dL). Creatinine kinase was elevated at 20,999 U/L. The patient was diagnosed with PRIS. She was transferred to the intensive care unit (ICU) on day 19 of hospitalization.

On admission to the ICU, the vital signs were as follows: body temperature, 39°C; blood pressure, 150/80 mmHg; heart rate, 150 b.p.m.; respiratory rate, 30 breaths/min; and SpO<sub>2</sub>, 99% (FiO<sub>2</sub> 40%). Laboratory findings showed metabolic acidosis (lactic acid, 99 mg/dL; pyruvic acid, 0.92 mg/dL), creatinine kinase 29,560 U/L, and myoglobin 9,845 ng/mL. We treated her with interruption of propofol

and continuous hemodiafiltration for metabolic acidosis. We continued coenzyme Q10, L-carnitine, and L-arginine for mitochondrial support for MELAS and antiepileptic drugs including levetiracetam, perampanel, lacosamide, and clobazam. After concurrent treatment of PRIS and MELAS, metabolic acidosis and creatinine kinase gradually decreased after reaching 59,000 IU/L on day 2 of ICU admission. Continuous hemodiafiltration was discontinued on day 11. Tracheostomy was carried out because i.v. midazolam treatment was prolonged to control the status epilepticus. Mechanical ventilation was discontinued on day 25 (Fig. 2). After rehabilitation, the patient was discharged on foot.

## DISCUSSION

**P**ROPOFOL IS USED for sedation in mechanical ventilation. Recently, propofol has been considered as an alternative treatment to barbiturates for control of refractory status epilepticus.<sup>4</sup> The clinical features of PRIS include metabolic acidosis and rhabdomyolysis with or without Acute Kidney Injury, hyperkalemia, lipidemia, cardiac failure, fever, and elevated liver enzymes.<sup>1,2</sup> The risk factors for PRIS are reported to be propofol at a high dose of over 5 mg/kg/h or over a long term of more than 48 h and critical illness such as sepsis, head trauma, and status epilepticus.<sup>1,2</sup>



**Fig. 2.** Clinical course of a 24-year-old woman with propofol infusion syndrome. Propofol was interrupted. Creatinine kinase (CPK) level decreased gradually after peaking at 5,900 U/L. CHDF, continuous hemodiafiltration; Qb, blood flow rate; Qd, dialysate flow rate.

The pathophysiological mechanism of PRIS involves mitochondrial disorder caused by propofol. Propofol inhibits the activity of carnitine palmitoyl transferase I. This enzyme converts long-chain fatty acyl CoA to the corresponding long-chain acylcarnitines.<sup>5</sup> Accumulation of acylcarnitine is reported in PRIS cases, with fatty acid accumulation in various organs.<sup>5</sup> Propofol affects the electron transport chain in the mitochondria. Animal studies have shown that propofol decreases electron complex chain II and III and coenzyme Q activities and inactivates cytochrome c.<sup>6</sup> These pathological mechanisms suggest that mitochondrial disease might provoke the possibility of PRIS. There have been few reports of PRIS patients with genetically proven mitochondrial disease.<sup>7,8</sup>

In the present case, propofol was given for 6 days at a maximum dose of 5.4 mg/kg/h. The dose of propofol was high; therefore, the patient had high risk of developing PRIS even in other backgrounds except MELAS. Furthermore, the underlying diseases were MELAS and status epilepticus. It was suspected that the patient's mitochondrial energy demand was increased; therefore, there was a higher risk of developing PRIS.

Nitric oxide (NO) deficiency occurs in MELAS and could lead to complications, including lactic acidosis and stroke-like episodes. Supplementation with NO precursors such as

L-arginine increases NO production, and L-arginine therefore has potential therapeutic utility in MELAS.<sup>9</sup> Coenzyme Q10 could improve the efficacy of the electron transport chain through its antioxidant effects.<sup>10</sup> Carnitine transfers long-chain fatty acids across the mitochondrial inner membrane as acylcarnitine esters. These esters are oxidized to acetyl CoA, leading to subsequent generation of adenosine triphosphate. Cofactors and antioxidants are common therapies for MELAS patients.

The pathological mechanisms of PRIS, defects in the production of adenosine triphosphate, are similar to those of MELAS, which suggests that treatment with antioxidants and mitochondrial cofactors might be useful. These findings suggest new treatment options for PRIS.

In the present case, however, L-arginine, coenzyme Q10, and carnitine had been administered for MELAS, and the patient developed PRIS. The combination of high-dose propofol, non-convulsive status epilepticus, and MELAS might trigger PRIS. The best management of PRIS is prevention. Clinicians should be aware of the risk of PRIS even when using propofol to control refractory status epilepticus. In patients with mitochondrial disorders, it might be better to avoid using propofol. Clinicians need to consider alternative anticonvulsant drugs or alternative sedative agents to prolonged and high doses of propofol.

## CONCLUSION

**WE EXPERIENCED** A rare case of PRIS with MELAS. It is important for clinicians to be aware that mitochondrial disorder is a risk factor for PRIS, especially under conditions of critical illness and status epilepticus.

## DISCLOSURE

Approval of the research protocol: N/A.

Informed consent: Informed consent was obtained from the patient and patient's family for publication of this case report and accompanying images.

Registry and the registration no. of the study/trial: N/A.

Animal studies: N/A.

Conflict of interest: None.

## REFERENCES

- 1 Mirrakhimov AE, Voore P, Halytsky O, Khan M, Ali AM. Propofol infusion syndrome in adults: a clinical update. *Crit. Care Res. Pract.* 2015; 2015: 260385.
- 2 Hemphill S, McMenamin L, Bellamy MC, Hopkins PM. Propofol infusion syndrome: a structured literature review and analysis of published case reports. *Br. J. Anaesth.* 2019; 122: 448–59.
- 3 Sproule DM, Kaufmann P. Mitochondrial encephalopathy, lactic acidosis, and strokelike episodes: basic concepts, clinical phenotype, and therapeutic management of MELAS syndrome. *Ann. N. Y. Acad. Sci.* 2008; 1142: 133–58.
- 4 Rossetti AO, Reichhart MD, Schaller MD, Despland PA, Bogousslavsky J. Propofol treatment of refractory status epilepticus: a study of 31 episodes. *Epilepsia* 2004; 45: 757–63.
- 5 Wolf A, Weir P, Segar P, Stone J, Shield J. Impaired fatty acid oxidation in propofol infusion syndrome. *Lancet* 2001; 357: 606–7.
- 6 Vanlander AV, Okun JG, de Jaeger A *et al.* Possible pathogenic mechanism of propofol infusion syndrome involves coenzyme q. *Anesthesiology* 2015; 122: 343–52.
- 7 Mtaweh H, Bayir H, Kochanek PM, Bell MJ. Effect of a single dose of propofol and lack of dextrose administration in a child with mitochondrial disease: a case report. *J. Child Neurol.* 2014; 29: 40–6.
- 8 Savard M, Dupre N, Turgeon AF, Desbiens R, Langevin S, Brunet D. Propofol-related infusion syndrome heralding a mitochondrial disease: case report. *Neurology* 2013; 81: 770–1.
- 9 El-Hattab AW, Emrick LT, Chanprasert S, Craigen WJ, Scaglia F. Mitochondria: role of citrulline and arginine supplementation in MELAS syndrome. *Int. J. Biochem. Cell Biol.* 2014; 48: 85–91.
- 10 Duberley KE, Heales SJ, Abramov AY *et al.* Effect of Coenzyme Q10 supplementation on mitochondrial electron transport chain activity and mitochondrial oxidative stress in Coenzyme Q10 deficient human neuronal cells. *Int. J. Biochem. Cell Biol.* 2014; 50: 60–3.