



OPEN ACCESS

# Cartilage issues in football—today's problems and tomorrow's solutions

Kai Mithoefer,<sup>1</sup> Lars Peterson,<sup>2</sup> Marcy Zenobi-Wong,<sup>3</sup> Bert R Mandelbaum<sup>4</sup>

<sup>1</sup>Department of Orthopedics and Sports Medicine, Harvard Vanguard Medical Associates, Harvard Medical School, Boston, Massachusetts, USA

<sup>2</sup>Department of Orthopedic Surgery, University of Gothenburg, Gothenburg, Sweden

<sup>3</sup>Cartilage Engineering and Regeneration Laboratory, ETH Zurich, Zurich, Switzerland

<sup>4</sup>Santa Monica Orthopedics and Sports Medicine Foundation, Los Angeles, USA

## Correspondence to

Dr Kai Mithoefer, Harvard Vanguard Medical Associates, Harvard Medical School, 291 Independence Drive, Chestnut Hill, MA 02467, USA; kmithoefer@partners.org

Accepted 5 March 2015

## ABSTRACT

Articular cartilage injury is prevalent in football players and results from chronic joint stress or acute traumatic injuries. Articular cartilage injury can often result in progressive painful impairment of joint function and limit sports participation. Management of articular cartilage injury in athletes aims to return the player to competition, and requires effective and durable joint surface restoration that resembles normal hyaline articular cartilage that can withstand the high joint stresses of football. Existing articular cartilage repair techniques can return the athlete with articular cartilage injury to high-impact sports, but treatment does not produce normal articular cartilage, and this limits the success rate and durability of current cartilage repair in athletes. Novel scientific concepts and treatment techniques that apply modern tissue engineering technologies promise further advancement in the treatment of these challenging injuries in the high demand athletic population. We review the current knowledge of cartilage injury pathophysiology, epidemiology and aetiology, and outline existing management algorithms, developing treatment options and future strategies to manage articular cartilage injuries in football players.

## THE PROBLEM OF ARTICULAR CARTILAGE INJURY IN FOOTBALL PLAYERS

### Epidemiology and injury mechanisms

Football, the most popular sport in the world, is played by more than 300 million people. Increasing participation is associated with an increase in articular cartilage injuries in the high-impact sport, particularly at the competitive and world class level.<sup>1 2</sup> Injury of articular cartilage surfaces occurs in 36% of athletes, which is more than twice than that in the general population.<sup>3</sup> Higher injury rates are noted in competitions than during practice, in athletes with body mass index (BMI) over 30, and in certain playing positions.<sup>4</sup>

Articular cartilage injury in athletes may occur in two separate pathways. Chronic repetitive loading of the articular cartilage during sports activity can lead to progressive articular cartilage degradation with accumulation of catabolic enzymes and cytokines, fragmentation of collagen and aggrecan, and resultant fissuring and progressive breakdown of the articular surface.<sup>5</sup> The sports-associated chronic biochemical and metabolic changes are similar to the changes described in early osteoarthritis (OA) and contribute to the progressive joint degeneration observed in athletes.<sup>5</sup> The high demands on the joint observed in impact athletes lead to a high incidence of cartilage abnormalities in asymptomatic

athletes.<sup>6</sup> Continued high-intensity loading, particularly in association with additional joint pathology, such as meniscal deficiency, joint instability or axis deviation, can cause symptoms and lead to rapid progression of cartilage injury.<sup>7 8</sup> A study of Scandinavian athletes with isolated severe chondral damage in the weight-bearing condyles demonstrated a significant decline of athletic activity 14 years after injury, with radiographic evidence of OA.<sup>9</sup> These results are supported by the up to 12-fold increased risk of knee OA in football athletes, particularly at the elite level.<sup>8 10 11</sup>

Normal articular cartilage possesses the ability to adjust to the level of activity. Increasing weight-bearing activity in athletes increases the volume and thickness of articular cartilage,<sup>12</sup> and in the healthy athlete, there is a positive linear dose–response relationship between repetitive loading activities and articular cartilage function. However, this dose–response curve reaches a threshold after which there is maladaptation and articular cartilage injury.<sup>13</sup> High-impact joint loading above this threshold decreases cartilage proteoglycan content, increases levels of degradative enzymes and causes chondrocyte apoptosis.<sup>14 15</sup> If the integrity of the functional weight-bearing unit is lost, either through acute sports-related injury or chronic microtrauma, a chondropaenia results—loss of articular cartilage volume and stiffness, increased contact pressures, and development or progression of articular cartilage defects. Without intervention, chondropaenia contributes to the deterioration of articular cartilage function in athletes and can ultimately progress to OA and the inability to participate in the sport.

Besides a chronic pathway, acute traumatic athletic cartilage injury in football players can frequently occur in association with other joint injuries, such as ligament or meniscal tears or dislocations. Depending on the force on the joint, acute traumatic cartilage injury may present with a spectrum of severity, such as (1) acute macroscopic chondral and osteochondral defects, or (2) a less obvious ultrastructural injury to the articular cartilage with disruption of chondral collagen and the proteoglycan network, as well as direct cell damage and apoptosis that may lead to gradual degradation of the articular cartilage.<sup>3 5 16</sup> Irrespective of their origin, articular cartilage injuries in football athletes will often limit the athlete's ability to play sport. Besides causing loss of playing time, progressive articular cartilage degeneration and OA, which occurs in up to 32% of football players, is a major cause for disability and retirement from the sport.<sup>10 11 17</sup>



Open Access  
Scan to access more  
free content



CrossMark

**To cite:** Mithoefer K, Peterson L, Zenobi-Wong M, et al. *Br J Sports Med* 2015;**49**:590–596.

## CLINICAL EVALUATION AND CLASSIFICATION OF CARTILAGE DEFECTS IN FOOTBALL PLAYERS

A systematic approach to assessment of chondral lesions in athletes is critical to guide treatment (figure 1). Obtaining a thorough history of athletes with knee cartilage defects is the first step. Symptoms from cartilage defects are usually non-specific and can mimic other knee pathology, such as meniscal tears. Pain with weight bearing often presents with impact activities. Catching and locking sensations can arise from cartilage flaps or larger defects. Joint effusion is frequently reported, particularly after demanding impact activities. Defects of the femoral condyles often produce focal tenderness over the condyle rather than the joint line. Patellar or trochlear lesions usually lead to pain when ascending or descending stairs, driving a car, getting out of a chair or squatting. Symptoms of patellar instability may be reported.

The knee should be routinely evaluated for ligamentous instability, patellar maltracking or instability, or lower extremity malalignment. The patient's BMI should be assessed.

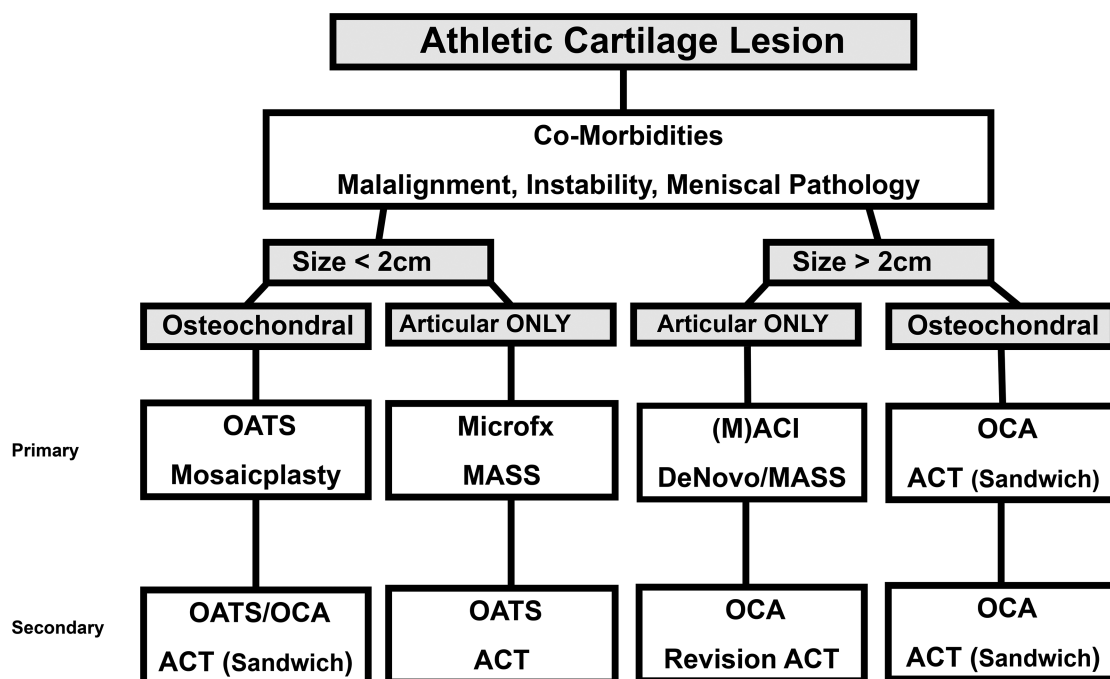
Plain radiographs, including weight-bearing anteroposterior and lateral views, Rosenberg views, long-leg films and Merchant views to identify osteochondral lesions, joint space narrowing, patellar maltracking or lower extremity malalignment are taken. Cartilage sensitive MRI presents a sensitive, specific and accurate tool for non-invasive diagnosis of articular cartilage injury.<sup>18</sup> It provides useful information about meniscal and ligamentous status, subchondral bone, lesion size and depth. Owing to the pathological changes in the surrounding cartilage, the final size of the defect usually is larger than defect size measured on pre-operative MRI.<sup>19</sup> New functional MRI techniques, such as delayed gadolinium-enhanced MRI (dGEMRIC), T2 mapping or T1 rho provide insights into the biochemical and biomechanical status of cartilage and the subchondral bone in addition to morphological appearance. High powered (>3 T) MRI can be as reliable as arthroscopy in diagnosing chondral defects but not for differentiating between grade II and III lesions.<sup>20</sup> Despite

advances in MRI technology, chondral lesions may remain undetected until arthroscopy.<sup>21</sup> A number of systems have been described to classify chondral injury during arthroscopy. The Outerbridge, Bauer and Shariaree systems are validated, qualitative arthroscopic classifications that grade lesions 1–4.<sup>22–24</sup> The chondropaenia severity score provides objective scores based on anatomical location of cartilage injury and meniscal status, and correlates with patient-reported outcomes.<sup>25</sup>

Clinical outcome tools should be used to measure the patient's subjective symptoms and to monitor disease progression or response to treatment. Valid patient-reported outcome measures that are specific for the knee and used for prospective evaluation of knee articular cartilage repair include the knee injury and outcome score (KOOS), and the International Knee Documentation Committee (IKDC) score.<sup>26–27</sup> In athletes, activity-related scores, such as Tegner score and Marx activity rating scale, are valid tools as well.<sup>28</sup> The International Cartilage Repair Society (ICRS) has developed a classification for knee evaluation that helps to provide uniform standards.<sup>29</sup> This system includes factors identified through the clinical history, examination and investigations. The ICRS systematic method enables understanding of the 'injury personality' based on nine variables that influence management: aetiology, defect thickness, lesion size, degree of containment, location, ligamentous integrity, meniscal integrity, alignment and relevant factors in the patient's history.

## TODAY'S OPTIONS FOR TREATMENT OF CARTILAGE INJURY IN FOOTBALL PLAYERS

The rationale for management of cartilage defects is based on understanding the pathophysiology underlying chondral lesions. The relative avascularity of articular cartilage prevents a physiological inflammatory response to cartilage injury and limits spontaneous repair of articular cartilage injury.<sup>11</sup> Repetitive loading of the injured articular cartilage during sports activity leads to cellular degeneration, accumulation of catabolic enzymes and



**Figure 1** Algorithm for the current treatment options for articular cartilage repair in the athlete. OATS, osteochondral autograft transplantation; OCA, osteochondral allograft; ACT, autologous chondrocyte transplantation; MASS, mesenchymal augmentation and scaffold stimulation; MACI, matrix-associated chondrocyte implantation.

cytokines, disruption of collagen ultrastructure and progressive macroscopic breakdown of the articular surface.<sup>5</sup>

Owing to the detrimental effect of high-impact articular loading, articular cartilage surface restoration should withstand the substantial mechanical joint stresses of up to 20 times body weight generated during high-impact, pivoting sports.<sup>5–11</sup> Goals of treatment are to reduce pain, increase mobility, improve knee function and ideally allow the player to return to sport at the preinjury level.<sup>6</sup> Several surgical techniques have achieved successful return to sport after articular cartilage repair with variable durability.<sup>30–33</sup>

However, surgery does not produce completely normal hyaline articular cartilage. Note that existing joint pathology, such as instability, malalignment or meniscal deficiency, must be corrected to produce a successful and lasting cartilage repair.<sup>30–33</sup> Concomitant pathology can be addressed at the initial surgery or subsequently in a staged approach. The simultaneous approach reduces the need for prolonged, repeated rehabilitation and absence from sport, and does not delay return to sport. Importantly, rehabilitation is critical for the success of any cartilage repair procedure and new concepts for cartilage rehabilitation in the athlete continue to develop.<sup>34</sup>

### Marrow stimulation techniques (mesenchymal stem cells)

First-generation microfracture still presents the most frequently used cartilage repair technique in athletes and uses pluripotent marrow-derived mesenchymal stem cells (MSC) which subsequently produce a mixed fibrocartilage repair tissue that contains varying amounts of type II collagen.<sup>35–39</sup> Knee function improves in 58–95% of athletes after microfracture and activity scores improve significantly. In total, 44–95% of athletes returned to competition after microfracture—57% at the preoperative level. Best results were seen with surgery within 12 months of injury—in athletes younger than 40 years and lesion size  $\leq 200$  mm.<sup>2</sup> After initial functional improvement, there was deterioration of knee function in 47–80% of athletes 18–36 months postsurgery, but knee function still remained better than before surgery after 10 years.<sup>40</sup> The exact reason for the functional decline is not known but insufficient volume of cartilage repair, limited integration of new material to the surrounding cartilage or subchondral bone changes may contribute.<sup>37–39</sup>

### Osteochondral transplantation

Osteochondral autograft transplantation restores hyaline cartilage by harvesting cylindrical osteochondral grafts from areas of limited weight bearing and transfers them into small to midsize (1–4 cm<sup>2</sup>) defects of weight-bearing cartilage using a press-fit technique. Prospective studies have evaluated this technique in athletes and demonstrated up to 95% good or excellent results, with significantly improved knee function scores after 26–36 months.<sup>41–42</sup> Return to athletic activity was reported in 61–93% as early as 4–9 months postoperatively. Some athletes showed a decrease of athletic activity after 7 years.<sup>42</sup> Longer preoperative symptoms and age >30 years were associated with decreased return to sport. Donor site morbidity may occur immediately after surgery, but this appears to resolve.

Osteochondral allografts (ie, from cadavers) avoid donor site morbidity and restore hyaline cartilage in large and deep chondral and osteochondral lesions. To optimise chondrocyte viability, matrix composition and mechanical properties, hypothermically stored cartilage grafts should be implanted within 14–21 days of graft harvest. The best function and fastest incorporation is observed for thin grafts (<15 mm). Osteochondral allograft transplantation in athletes allowed 88%

to return to sport and 79% to their preinjury level.<sup>43</sup> Better outcomes were seen in athletes younger than 25 years and in those with symptoms less than 1 year. Besides osteochondral allograft and autograft, synthetic bilayer scaffolds have been developed that mimic the anatomy of osteochondral plugs. However, the results in the high demand athletic population have not yet been established.<sup>44</sup>

### Cartilage cell-based repair techniques

The concept of using cartilage cells (chondrocytes) in the repair of articular cartilage defects was first reported in humans in 1994.<sup>45</sup> Autologous chondrocyte transplantation is a two-stage technique for hyaline-like repair of full-thickness articular cartilage lesions in the knee. It has provided long-term functional improvement for up to 20 years and functional MRI, using dGEMRIC technology, shows repair tissue quality similar to the surrounding normal cartilage 18 years after implantation.<sup>46–47</sup> Two prospective multicentre studies in athletes, including football players, showed good to excellent results in 72–96% athletes, with improved activity scores in 82–100%.<sup>48–49</sup> Between 33% and 96% returned to high-impact athletics, while 60–80% were at the same skill level. Return to sport was best in competitive football athletes (83%) and adolescent athletes (96%), and 87% of returning athletes maintained their ability to perform 52 months after surgery. Athletes with single lesions, age <25 years, and short preoperative intervals had the best rate of return to sport.

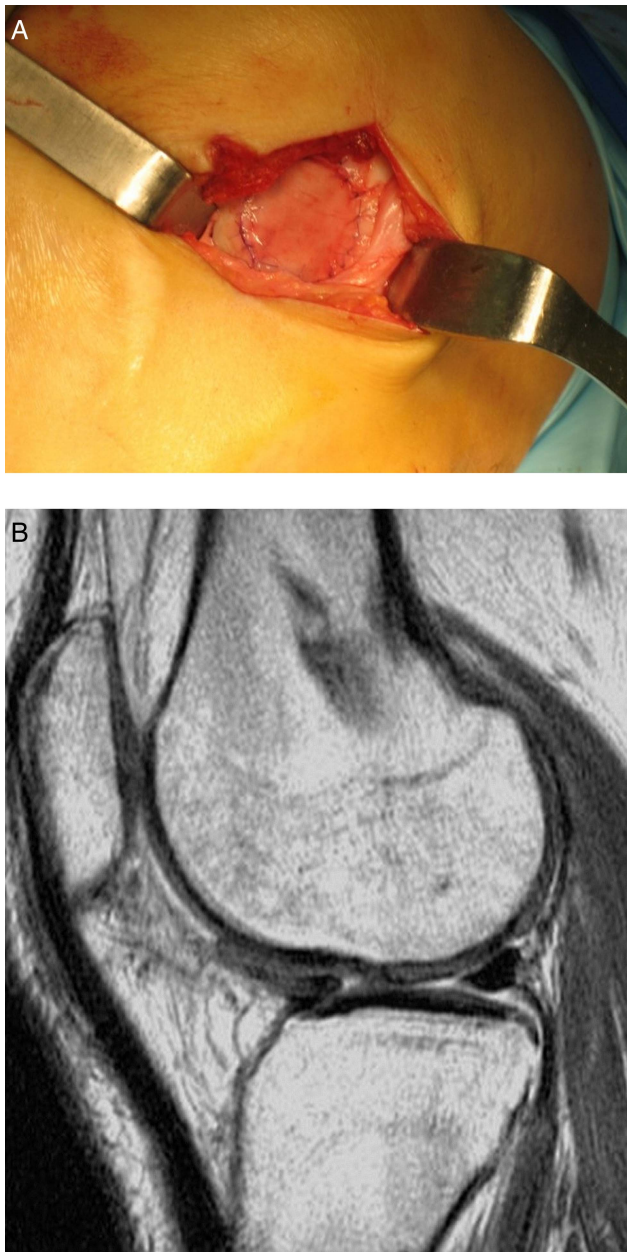
Limitations of this first-generation technique included its invasiveness, prolonged postoperative rehabilitation and graft delamination from periosteal hypertrophy. Sport-specific rehabilitation has been successful in reducing the time to return to sport to as low as 10 months; substitution of the periosteum with a collagen membrane has reduced the risk for hypertrophy and delamination while maintaining the excellent clinical results of the first-generation technique.<sup>50–51</sup>

Second-generation autologous cartilage transplantation techniques use biodegradable scaffolds to temporarily support the chondrocytes until they are replaced by matrix components synthesised from the implanted cells (figure 2). Scaffolds can be based on carbohydrates, protein polymers, artificial polymers or composite polymer matrices. Matrix-associated chondrocyte implantation (MACI) has been used with excellent results in Europe and Australia, but is not routinely available in the USA. The biomatrix seeded with chondrocytes reduces surgical invasiveness and demonstrated improved knee function scores, KOOS sports and activity scores, minimal graft hypertrophy and hyaline-like repair tissue.<sup>52</sup> Arthroscopic MACI has been described and showed improvement of knee function in 90% of athletes/patients, with improvement persisting to 5 years.<sup>39–53</sup> Better results were seen in patients younger than 30 years and athletes participating in higher level competitive sports.

### Rehabilitation and return to sport

Rehabilitation aims to enable return to full sporting activity, prevent reinjury and minimise the progression to OA by facilitating a mechanical environment for the local adaptation and remodelling. Owing to the complex nature of cartilage repair and the variable defect characteristics and comorbidities, rehabilitation requires an individualised approach and it should be recognised that not all athletes will return to their preinjury levels of function after articular cartilage repair.

Rehabilitation must be adapted to the biology of the surgical repair technique, individual cartilage defect specifications and each athlete's sport-specific demands. This can be achieved by a



**Figure 2** Intraoperative image of second-generation scaffold-assisted autologous chondrocyte implant of the knee of an athlete (A). Postoperative MRI at 24 months demonstrating complete fill of the defect with full peripheral integration (B).

stepwise, phased rehabilitation approach consisting of (1) an initial protection and joint activation phase, (2) a progressive joint loading and functional restoration phase, and finally (3) an activity restoration phase. The length of rehabilitation ultimately depends on an individual's performance at each stage of rehabilitation. Consideration must be given to the method of surgical repair, as each approach has specific healing constraints. Thus, the type of surgery will determine how early weight bearing can start. A key benefit of osteochondral grafting is that early weight bearing can be tolerated due to graft stability. This is not the same with ACI/MACI or microfracture, where the repair construct has to be given time to embed in the subchondral bone. However, accelerated rehabilitation protocols have been developed for patients with ACI/MACI and reduce time to return to sport to less than 12 months.<sup>50 54 55</sup>

Addressing concomitant injuries, such as anterior cruciate ligament (ACL) ruptures, is critical in the success of cartilage repair strategies. Combined procedures (ACL reconstructions, high tibial osteotomy, and meniscal allografts and repair) do not adversely affect the return-to-sport rate after cartilage repair. However, rehabilitation guidelines may need to be modified taking into account the healing characteristics of the concomitant lesion.

Irrespective of the technique used, the rate for return to sports is higher for younger and more competitive athletes.<sup>56</sup> Athletic and quadriceps deconditioning, thickened subchondral bone in chronic lesions and expanding lesion margins may all delay successful return.<sup>57</sup> Other patient-specific factors, including no prior surgical interventions, and higher preinjury and postsurgical level of sports, also correlate with improved clinical outcomes and higher rate of return to sports.<sup>58</sup> Defect-specific factors, such as smaller lesion size and isolated medial femoral condyle lesion location, also correlated with successful return to sports and better clinical results. Conversely, longer preoperative duration of symptoms >12 months was a negative prognostic factor for returning to athletic activity.<sup>37</sup>

## TOMORROW'S SOLUTIONS FOR ARTICULAR CARTILAGE INJURY IN ATHLETES

### Emerging treatment strategies

To address the limitations of existing cartilage repair technology, the continued scientific and clinical evolution aims to provide complex and individualised treatment options to treat articular cartilage injury in the football player. These evolving technologies aim to achieve more hyaline cartilage repair of high quality, faster progression of cartilage repair rehabilitation with quicker return to sports and more consistent durability of high-impact sports participation. Since injuries to articular cartilage of the knee present one of the most common causes of permanent disability in athletes, management of articular cartilage in this high-demand population has important long-term implications.

### NON-OPERATIVE OPTIONS

Platelet-rich plasma (PRP) has been used safely; its proposed healing properties are attributed to the increased concentrations of autologous growth factors and secretory proteins that may enhance recruitment, proliferation and differentiation of cells involved in tissue regeneration.<sup>59</sup> While the few studies evaluating platelet aggregates in the treatment of chondral lesions or OA report decreased pain in the postinjection period compared with hyaluronic acid,<sup>60 61</sup> these do not allow for comparative analysis of clinical effectiveness. There is currently insufficient evidence for PRP to be recommended in key guidelines, but well-designed randomised controlled trials are being conducted to test the clinical utility of PRP in this setting. Besides injection of growth factor combinations, injections of individual growth factors, such as transforming growth factor  $\beta$ 3 and bone morphogenetic protein 7, to induce chondrogenic marker gene expression for type II/IX collagen, cartilage oligomeric matrix protein and aggrecan with both qualitative and quantitative improvement of joint articular cartilage or repair tissue have been tested; controlled clinical studies are pending.<sup>62 63</sup>

### SURGICAL OPTIONS

#### Mesenchymal augmentation and scaffold stimulation techniques

New technologies have been developed to improve the limitations of first-generation marrow stimulation technologies. These second-generation technologies are based on marrow-derived

MSC, and use modern tissue engineering technologies, such as growth factors and scaffolds, to augment and facilitate chondrogenic differentiation for both qualitative and quantitative improvement of repair cartilage tissue.<sup>64</sup> Clinical evaluation of these mesenchymal augmentation and scaffold stimulation technologies has been encouraging. Autologous Matrix-Induced Chondrogenesis (AMIC, Geistlich, Princeton, New Jersey, USA) demonstrated high satisfaction in 87% of treated patients and improved knee scores as early as 12 months.<sup>65</sup> One report showed successful return to professional football 10 months after AMIC.<sup>66</sup> Similarly, in situ solidification of the microfracture clot with the thrombogenic and adhesive polysaccharide polymer chitosan-glycerol phosphate (BST-Cargel, Piramal Healthcare, Laval, Canada) improved cartilage repair tissue volume and biochemical composition compared with microfracture and with better functional knee scores after 24 months.<sup>67</sup> Augmentation using a combination of micronised allograft chondrons and autologous growth factors to create a BioCartilage cartilage (Arthrex, Naples, Florida, USA) has also been applied successfully in the clinical setting; however, results in athletes are still pending.<sup>68</sup>

Bone marrow aspirate concentrate (BMAC) utilises a one-step surgery with concentrated MSC aspirated from the pelvis and injected under a collagen I/III matrix. Early clinical results show improved cartilage repair compared with microfracture in animal models and significant improvement of joint function in humans.<sup>69</sup> BMAC may be particularly useful in the treatment of lesions of the tibia plateau where access is often limited by location. Clinical evidence demonstrating efficacy is evolving, but while BMAC offers an interesting therapeutic perspective its clinical data, specifically in the athletic population, are still limited.

### Neocartilage implantation

Using advanced tissue engineering technology, this two-step technique uses autologous chondrocytes that are seeded in a bovine collagen gel/sponge scaffold. The three-dimensional (3D) construct is incubated under defined hydrostatic pressure in a specifically designed bioreactor stimulating the chondrocytes to produce cartilage matrix proteins and form a firm sponge-like neocartilage containing both active chondrocytes and extracellular matrix (ECM; NeoCart, Histogenics, Waltham, USA). Implantation is performed using a novel bioadhesive which facilitates a minimally invasive surgical approach (figure 3). Clinical trials showed good cartilage fill, peripheral integration and pain relief in 86% of patients up to 2 years after implantation. MRI T<sub>2</sub> mapping demonstrated hyaline cartilage in 57%.<sup>70</sup> A larger prospective, randomised comparison of this technique with microfracture is currently being completed.

### Cartilage allograft implantation

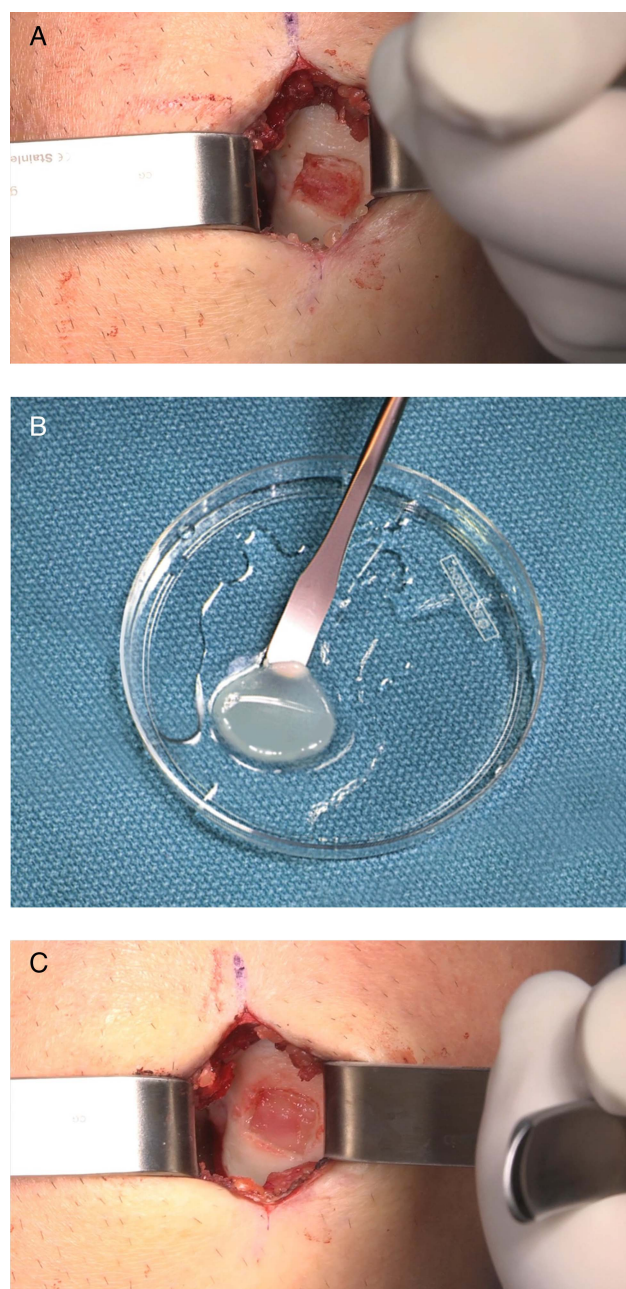
Repair of focal articular cartilage defects using allograft cartilage fragments has been recently described (DeNovo, Zimmer, Warsaw, USA). Hyaline cartilage fragments are obtained from juvenile donor joints and contain viable juvenile chondrocytes that possess significantly (up to  $\times 100$ ) higher metabolic activity than adult chondrocytes. The small cartilage particles are moulded to the size of the recipient cartilage defect and implanted using fibrin glue fixation and a minimally invasive arthrotomy (figure 4). Preliminary results from a prospective, multicentre case series, with follow-up of 25 patients of up to 24 months, demonstrated improved IKDC and KOOS scores as well as good cartilage repair tissue fill of the defects on MRI.<sup>39</sup> Larger, intermediate-term prospective clinical evaluation is

currently under way using this technique to further evaluate the long-term results of this technique.

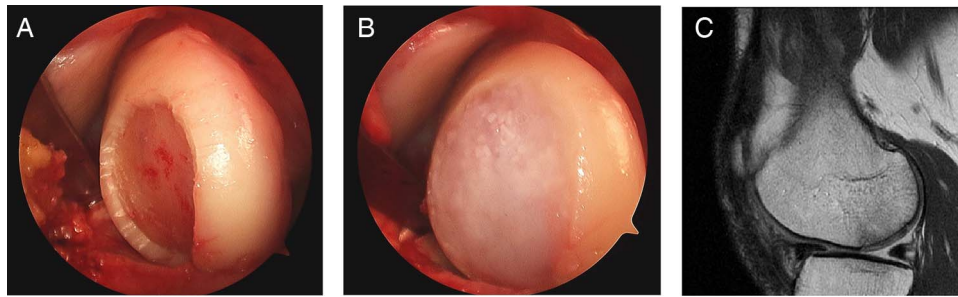
### Novel scientific approaches

#### Novel chondrogenic cell sources

Although articular cartilage is generally thought to have poor self-renewal capacity, articular cartilage lesions undergoes perfect regeneration in the womb.<sup>71–72</sup> Scar-free fetal healing occurs in many tissue types and continues to inspire the design of regenerative environments to aid in healing of adult tissues. In articular cartilage, one of the most intriguing discoveries of the past decade is the existence of cartilage progenitor cells (CPCs) in the tissue.<sup>73–78</sup> These progenitor cells are distinguishable from resident chondrocytes by their migratory behaviour,



**Figure 3** Intraoperative images of articular cartilage defect in an athlete's knee (A). A neocartilage disk generated from autologous cartilage cells in a bioreactor (B) is used to create an implant fitted to the dimensions of the defect and providing immediate neocartilage fill (C).



**Figure 4** Intraoperative image demonstrating a large cartilage defect of the lateral femoral condyle before (A) and after (B) repair with chondral allograft fragments. Postoperative MRI at 12 months shows complete fill of the defect (C).

multidifferentiation capacity and clonogenicity. In young healthy cartilage, the outgrowth of CPCs can form abundant neocartilage.<sup>73</sup> Interestingly, CPCs may also be present in adult tissue,<sup>79</sup> and repair tissue from late stage OA cartilage<sup>75</sup> and their migration can be stimulated by mechanical damage, possibly through the release of chemoattractants from apoptotic cells.<sup>77</sup>

#### Injectable chondroinductive materials

With the identification of progenitor cells in articular cartilage comes the hope that these cells could be harnessed to heal damaged cartilage. If this approach were successful, it would eliminate the extensive cell culturing and expensive regulatory complexities required for cell-based therapies. A successful application of CPCs, however, will require a biomaterial which induces migration, but also has the optimal biomechanical, immunological and biochemical 3D environment to control the fate of the regenerating cells. This material should, furthermore, be injectable, adherent to the lesion surface and have tunable biostability/degradability. Indeed, the field is turning increasingly towards acellular biomaterials with boosted bioactivity and functionality.<sup>79–80</sup> Scaffolds based on decellularised cartilage ECM represent one fruitful way to incorporate some of the vast complexity of the native chondrocyte microenvironment into a scaffold. Other options are materials with cues for cell migration and adhesion, and growth factor binding which are anti-inflammatory,

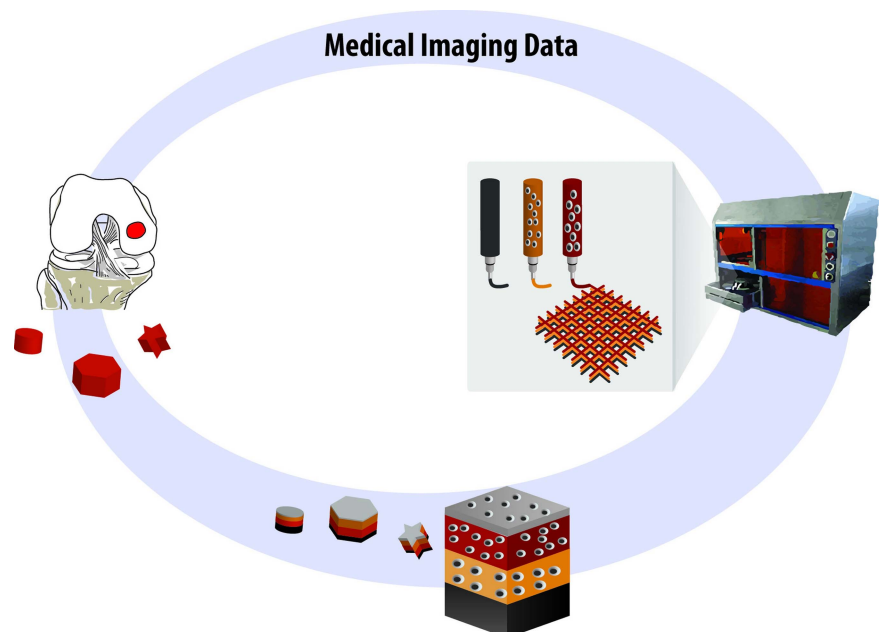
antioxidant and/or antiangiogenic.<sup>81–83</sup> Although to date there is not a single biomaterial which incorporates all of the above properties, combinations of polymeric systems, called interpenetrating networks, can increase the overall functionality of the material.

#### Bioprinting of complex cartilage structures

For repair of large osteochondral lesions, one emergent technology for production of patient-specific grafts is 3D bioprinting. Though still in the experimental stage, cartilaginous organs have been appealing early targets for bioprinting technology because they are relatively simple tissues with a single cell type, an absence of vasculature and a function which is primarily structural in nature. The zonal organisation of articular cartilage is also particularly amenable to bioprinting, which is a layer-by-layer additive procedure. Bioprinting involves the extrusion of special biofriendly polymers which can be deposited in 3D space. As in the case of injectable biomaterials, the ‘bioinks’ used for organ printing can also be given enhanced function using similar concepts as those aforementioned (figure 5).

Lee *et al*<sup>84</sup> bioprinted an acellular humeral head scaffold and obtained complete regeneration of the synovial surface by loading the scaffold with growth factors, which in turn stimulated the migration and/or differentiation of endogenous CPCs. Several studies have also demonstrated the biological benefit of incorporating particulate ECM particles, such as BioCartilage,

**Figure 5** In the future articular cartilage grafts could be printed based on medical image data of the lesion geometry. The grafts are printed in a layer-by-layer fashion using bioinks representing the different layers of articular cartilage.



into the bioinks. The vision of bioprinting patient-specific osteochondral structures to replace injured joints lies in the future. Challenges include nourishing the cells residing in the core of large printed structures, adhesion of printed structures to the native tissue and design of a material which is at the same time bioactive, cell-friendly and mechanically robust.

### Scientific collaboration

Progress in articular cartilage restoration in athletes relies on close collaboration between basic scientists, clinical cartilage experts, athletes and sports organisations. FIFA has recognised the importance of articular cartilage injury in the football player and plays a critical role as a catalyst for scientific progress in this area of football medicine. Research studies by FIFA-Medical Assessment and Research Center (F-MARC) have identified articular cartilage injuries as a serious knee injury that can be associated with inability to play.<sup>85</sup>

F-MARC and the ICRS have found a common goal and developed an active collaboration in an effort to help advance the science and the understanding of articular cartilage injury and degeneration in the football player as well as the options for its treatment and prevention. As part of the efforts to advance science and education of cartilage injury in football, FIFA established the 'Cartilage Regeneration Professorship' at the Swiss Federal Institute (ETH Zurich), published a special supplement on cartilage injuries in the football player in the journal *Cartilage*,<sup>86</sup> convened regular ICRS scientific focus meetings in the FIFA auditorium in Zurich and sponsored a FIFA/ICRS science award. Regular FIFA symposia at the ICRS World Congress have provided a foundation to develop innovative prevention and treatment strategies that aim to further reduce the incidence of cartilage injury and risk of OA in football players of all ages and skill levels.

**Competing interests** None.

**Provenance and peer review** Not commissioned; externally peer reviewed.

**Open Access** This is an Open Access article distributed in accordance with the Creative Commons Attribution Non Commercial (CC BY-NC 4.0) license, which permits others to distribute, remix, adapt, build upon this work non-commercially, and license their derivative works on different terms, provided the original work is properly cited and the use is non-commercial. See: <http://creativecommons.org/licenses/by-nc/4.0/>

### REFERENCES

- Peterson L, Junge A, Chomiak J, et al. Incidence of football injuries and complaints in different age groups and skill-level groups. *Am J Sports Med* 2000;28(5 Suppl): S51-7. 732-7.
- Ekstrand J, Häggglund M, Kristenson K, et al. Fewer ligament injuries but no preventive effect on muscle injuries and severe injuries: an 11-year follow-up of the UEFA Champions League injury study. *Br J Sports Med* 2013;47:732-7.
- Flanigan DC, Harris JD, Trinh TQ, et al. Prevalence of chondral defects in athletes' knees: a systematic review. *Med Sci Sports Exerc* 2010;42:1795-801.
- Brophy RH, Rodeo SA, Barnes RP, et al. Knee articular cartilage injuries in the National Football League: epidemiology and treatment approach by team physicians. *J Knee Surg* 2009;22:331-8.
- Mandelbaum B, Waddell D. Etiology and pathophysiology of osteoarthritis. *Orthopedics* 2005;28(2 Suppl):s207-14.
- Walczak BE, McCulloch PC, Kang RW, et al. Abnormal findings on knee magnetic resonance imaging in asymptomatic NBA players. *J Knee Surg* 2008;21:27-33.
- Aune KT, Andrews JR, Dugas JR, et al. Return to play after partial lateral meniscectomy in National Football League Athletes. *Am J Sports Med* 2014;42:1865-72.
- Kujala UM, Kettunen J, Paananen H, et al. Knee osteoarthritis in former runners, soccer players, weight lifters, and shooters. *Arthritis Rheum* 1995;38:539-46.
- Maletius W, Messner K. The long-term prognosis for severe damage to the weightbearing cartilage in the knee: a 14-year clinical and radiographic follow-up in 28 young athletes. *Acta Orthop Scand* 1996;67:165-8.
- Felson DT. Osteoarthritis: new insights. Part 1: the disease and its risk factors. *Ann Intern Med* 2000;133:635-46.
- Buckwalter JA, Mankin HJ. Articular cartilage. Part II: degeneration and osteoarthritis, repair, regeneration, and transplantation. *J Bone Joint Surg Am* 1997;79:612-32.
- Jones G, Bennell K, Cicuttini FM. Effect of physical activity on cartilage development in healthy kids. *Br J Sports Med* 2003;37:382-3.
- Kiviranta I, Tammi M, Jurvelin J. Articular cartilage thickness and glycosaminoglycan distribution in the canine knee joint after strenuous running exercise. *Clin Orthop Relat Res* 1992;283:302-8.
- Arokoski J, Kiviranta I, Jurvelin J, et al. Long-distance running causes site-dependent decrease of cartilage glycosaminoglycan content in the knee joint of beagle dogs. *Arthritis Rheum* 1993;36:1451-9.
- Shelbourne KD, Jari S, Gray T. Outcome of untreated traumatic articular cartilage defects of the knee: a natural history study. *J Bone Joint Surg Am* 2003; 85(Suppl 2):8-16.
- Brophy RH, Zeltser D, Wright RW, et al. Anterior cruciate ligament reconstruction and concomitant articular cartilage injury: incidence and treatment. *Arthroscopy* 2010;26:112-20.
- Drawer S, Fuller CW. Propensity for osteoarthritis and lower limb joint pain in retired professional soccer players. *Br J Sports Med* 2001;35:402-8.
- Potter HG, Chong le R. Magnetic resonance imaging assessment of chondral lesions and repair. *J Bone Joint Surg Am* 2009;91(Suppl 1):126-31.
- Henn RF III, Gomoll AH. A review of the evaluation and management of cartilage defects in the knee. *Phys Sportsmed* 2011;39:101-7.
- von Engelhardt LV, Schmitz A, Burian B, et al. [3-Tesla MRI vs. arthroscopy for diagnostics of degenerative knee cartilage diseases: preliminary clinical results]. *Orthopade* 2010;37:914, 916-922.
- Figuroa D, Calvo R, Vaisman A, et al. Knee chondral lesions: incidence and correlation between arthroscopic and magnetic resonance findings. *Arthroscopy* 2007;23:312-15.
- Bauer M Jr, Ogilvie-Harris D, Morbidi M. Classificazione artroscopica delle lesioni condrali del ginocchio. *Med Sport* 1987;40:41-4.
- Cameron ML, Briggs KK, Steadman JR. Reproducibility and reliability of the outerbridge classification for grading chondral lesions of the knee arthroscopically. *Am J Sports Med* 2003;31:83-6.
- Shariaree H. Chondromalacia. *Contemp Orthop* 1985;11:27-39.
- Pro SLB BW, McAdams TR, Mandelbaum BR. Chondropenia Severity Score: an arthroscopic stratification tool of structural cartilage changes in the knee as correlated to patient reported outcomes (SS-28). *Arthroscopy* 2009; 28(6 Supplement 1):e16.
- Davidson M, Keating J. Patient-reported outcome measures (PROMs): how should I interpret reports of measurement properties? A practical guide for clinicians and researchers who are not biostatisticians. *Br J Sports Med* 2014;48:792-6.
- Hambly K, Griva K. IKDC or KOOS? Which measures symptoms and disabilities most important to postoperative articular cartilage repair patients? *Am J Sports Med* 2008;36:1695-704.
- Mithoefer K, Acuna M. Clinical outcomes assessment for articular cartilage restoration. *J Knee Surg* 2013;26:31-40.
- International Cartilage Repair Society Documentation and Classification System. Freiburg, Switzerland, Newsletter 1, March 1998:5-8.
- Mithoefer K, Peterson L, Mandelbaum B, et al. Articular cartilage repair in soccer players with autologous chondrocyte transplantation: functional outcome and return to competition. *Am J Sports Med* 2005;33:1639-46.
- Steadman JR, Rodkey WG, Singleton SB, et al. Microfracture technique for full thickness chondral defects: technique and clinical results. *Oper Tech Orthop* 1997;7:300-4.
- Hangody L, Rathonyi GK, Duska Z, et al. Autologous osteochondral mosaicplasty. Surgical technique. *J Bone Joint Surg Am* 2004;86(Suppl 1):65-72.
- Gross A. Fresh osteochondral allograft for posttraumatic knee defects: surgical technique. *Oper Tech Orthop* 1997;7:334-9.
- Mithoefer K, Hambly K, Logerstedt D, et al. Current concepts for rehabilitation and return to sport after knee articular cartilage repair in the athlete. *J Orthop Sports Phys Ther* 2012;42:254-73.
- Gobbi A, Karnatzikos G, Kumar A. Long-term results after microfracture treatment for full-thickness knee chondral lesions in athletes. *Knee Surg Sports Traumatol Arthrosc* 2014;22:1986-96.
- Steadman JR, Miller BS, Karas SG, et al. The microfracture technique in the treatment of full-thickness chondral lesions of the knee in national football league players. *J Knee Surg* 2003;16:83-6.
- Mithoefer K, Williams RJ, Warren RF, et al. High-impact athletics after knee articular cartilage repair. A prospective evaluation of the microfracture technique. *Am J Sports Med* 2006;34:1413-18.
- Mithoefer K, McAdams T, Williams RJ, et al. Clinical efficacy of the microfracture technique for articular cartilage repair in the knee: an evidence-based systematic analysis. *Am J Sports Med* 2009;37:2053-63.
- Kon E, Filardo G, Berruto M, et al. Articular cartilage treatment in high-level male soccer players: a prospective comparative study of arthroscopic second-generation

- autologous chondrocyte implantation versus microfracture. *Am J Sports Med* 2011;39:2549–57.
- 40 Gudas R, Gudaite A, Pocius A, *et al.* Ten-year follow-up of a prospective, randomized clinical study of mosaic osteochondral autologous transplantation versus microfracture for the treatment of osteochondral defects in the knee joint of athletes. *Am J Sports Med* 2012;40:2499–508.
- 41 Kish G, Modis L, Hangody L. Osteochondral mosaicplasty for the treatment of focal chondral and osteochondral lesions of the knee and talus in the athlete. Rationale, indications, technique, and results. *Clin Sports Med* 1999;18:45–66.
- 42 Marcacci M, Kon E, Delcogliano M, *et al.* Arthroscopic autologous osteochondral grafting for cartilage defects of the knee: prospective study results at a minimum 7-year follow-up. *Am J Sports Med* 2007;35:2014–21.
- 43 Krych AJ, Robertson CM, Williams RJ III. Return to athletic activity after osteochondral allograft transplantation in the knee. *Am J Sports Med* 2012;40:1053–9.
- 44 Hindle P, Hendry JL, Keating JF, *et al.* Autologous osteochondral mosaicplasty or TruFit™ plugs for cartilage repair. *Knee Surg Sports Traumatol Arthrosc* 2014;22:1235–40.
- 45 Brittberg M, Lindahl A, Nilsson A, *et al.* Treatment of deep cartilage defects in the knee with autologous chondrocyte transplantation. *N Engl J Med* 1994;331:889–95.
- 46 Peterson L, Vasiliadis HS, Brittberg M, *et al.* Autologous chondrocyte implantation: a long-term follow-up. *Am J Sports Med* 2010;38:1117–24.
- 47 Vasiliadis HS, Danielson B, Ljungberg M, *et al.* Autologous chondrocyte implantation in cartilage lesions of the knee: long-term evaluation with magnetic resonance imaging and delayed gadolinium-enhanced magnetic resonance imaging technique. *Am J Sports Med* 2010;38:943–9.
- 48 Mithoefer K, Peterson L, Saris DBF, *et al.* Evolution and current role of autologous chondrocyte transplantation for the treatment of articular cartilage defects in the football (soccer) player. *Cartilage* 2012;3(1 Suppl):315–65.
- 49 Mithöfer K, Minas T, Peterson L, *et al.* Functional outcome of articular cartilage repair in adolescent athletes. *Am J Sports Med* 2005;33:1147–53.
- 50 Della Villa S, Kon E, Filardo G, *et al.* Does intensive rehabilitation permit early return to sport without compromising the clinical outcome after arthroscopic autologous chondrocyte implantation in highly competitive athletes? *Am J Sports Med* 2010;38:68–77.
- 51 Steinwachs M, Kreuz PC. Autologous chondrocyte implantation in chondral defects of the knee with a type I/III collagen membrane: a prospective study with a 3-year follow-up. *Arthroscopy* 2007;23:381–7.
- 52 Bartlett W, Skinner JA, Gooding CR, *et al.* Autologous chondrocyte implantation versus matrix-induced autologous chondrocyte implantation for osteochondral defects of the knee: a prospective, randomized study. *J Bone Joint Surg Br* 2005;87:640–5.
- 53 Filardo G, Kon E, Di Martino A, *et al.* Arthroscopic second-generation autologous chondrocyte implantation: a prospective 7-year follow-up study. *Am J Sports Med* 2011;39:2153–60.
- 54 Wondrasch B, Risberg MA, Zak L, *et al.* Effect of accelerated weightbearing after matrix-associated autologous chondrocyte implantation on the femoral condyle: a prospective, randomized controlled study presenting MRI-based and clinical outcomes after 5 years. *Am J Sports Med* 2015;43:146–53.
- 55 Ebert JR, Fallon M, Zheng MH, *et al.* A randomized trial comparing accelerated and traditional approaches to postoperative weightbearing rehabilitation after matrix-induced autologous chondrocyte implantation: findings at 5 years. *Am J Sports Med* 2012;40:1527–37.
- 56 Harris JD, Brophy RH, Siston RA, *et al.* Treatment of chondral defects in the athlete's knee. *Arthroscopy* 2010;26:841–52.
- 57 Ebert JR, Smith A, Edwards PK, *et al.* Factors predictive of outcome 5 years after matrix-induced autologous chondrocyte implantation in the tibiofemoral joint. *Am J Sports Med* 2013;41:1245–54.
- 58 Mithoefer K, Hambly K, Della Villa S, *et al.* Return to sports participation after articular cartilage repair in the knee: scientific evidence. *Am J Sports Med* 2009;37(Suppl 1):1675–765.
- 59 Foster TE, Puskas BL, Mandelbaum BR, *et al.* Platelet-rich plasma: from basic science to clinical applications. *Am J Sports Med* 2009;37:2259–72.
- 60 Kon E, Mandelbaum B, Buda R, *et al.* Platelet-rich plasma intra-articular injection versus hyaluronic acid viscosupplementation as treatments for cartilage pathology: from early degeneration to osteoarthritis. *Arthroscopy* 2011;27:1490–501.
- 61 Sanchez M, Fiz N, Azofra J, *et al.* A randomized clinical trial evaluating plasma rich in growth factors (PRGF-Endoret) versus hyaluronic acid in the short-term treatment of symptomatic knee osteoarthritis. *Arthroscopy* 2012;28:1070–8.
- 62 Kuo AC, Rodrigo JJ, Reddi AH, *et al.* Microfracture and bone morphogenetic protein 7 (BMP-7) synergistically stimulate articular cartilage repair. *Osteoarthritis Cartilage* 2006;14:1126–35.
- 63 Morisset S, Frisbee DD, Robbins PD, *et al.* Il-1ra/IGF-1 gene therapy modulates repair of microfractured chondral defects. *Clin Orthop Relat Res* 2007;462:221–8.
- 64 Neumann K, Dehne T, Endres M, *et al.* Chondrogenic differentiation capacity of human mesenchymal progenitor cells derived from subchondral corticospongiosus bone. *J Orthop Res* 2008;26:1449–56.
- 65 Gille J, Schuseil E, Wimmer J, *et al.* Mid-term results of Autologous Matrix-Induced Chondrogenesis for treatment of focal cartilage defects in the knee. *Knee Surg Sports Traumatol Arthrosc* 2010;18:1456–64.
- 66 Bark S, Riepenhof H, Gille J. AMIC cartilage repair in a professional soccer player. *Case Rep Orthop* 2012;2012:36–43.
- 67 Stanish WD, McCormack R, Forriol F, *et al.* Novel scaffold-based BST-CarGel treatment results in superior cartilage repair compared with microfracture in a randomized controlled trial. *J Bone Joint Surg Am* 2013;95:1640–50.
- 68 Desai S. Surgical treatment of a tibial osteochondral defect with debridement, marrow stimulation, and micronized allograft cartilage matrix—an all-arthroscopic technique: a case report. *J Foot Ankle Surg* 2014;53:1067–2516.
- 69 Gobbi A, Karnatzikos G, Sankineani SR. One-step surgery with multipotent stem cells for the treatment of large full-thickness chondral defects of the knee. *Am J Sports Med* 2014;42:648–57.
- 70 Crawford DC, DeBerardino TM, Williams RJ III. NeoCart, an autologous cartilage tissue implant, compared with microfracture for treatment of distal femoral cartilage lesions: an FDA phase-II prospective, randomized clinical trial after two years. *J Bone Joint Surg Am* 2012;94:979–89.
- 71 Farr J, Tabet SK, Margerrison E, *et al.* Clinical, radiographic, and histological outcomes after cartilage repair with particulated juvenile articular cartilage: a 2-year prospective study. *Am J Sports Med* 2014;42:1417–25.
- 72 Namba RS, Meuli M, Sullivan KM, *et al.* Spontaneous repair of superficial defects in articular cartilage in a fetal lamb model. *J Bone Joint Surg Am* 1998;80:4–10.
- 73 Bos PK, Kops N, Verhaar JA, *et al.* Cellular origin of neocartilage formed at wound edges of articular cartilage in a tissue culture experiment. *Osteoarthritis Cartilage* 2008;16:204–11.
- 74 Hattori S, Oxford C, Reddi AH. Identification of superficial zone articular chondrocyte stem/progenitor cells. *Biochem Biophys Res Commun* 2007;358:99–103.
- 75 Koelling S, Kruegel J, Irmer M, *et al.* Migratory chondrogenic progenitor cells from repair tissue during the later stages of human osteoarthritis. *Cell Stem Cell* 2009;4:324–35.
- 76 Jiang Y, Tuan RS. Origin and function of cartilage stem/progenitor cells in osteoarthritis. *Nat Rev Rheumatol* 2014;10:1038.
- 77 Seol D, McCabe DH, Choe D, *et al.* Chondrogenic progenitor cells respond to cartilage injury. *Arthritis Rheum* 2012;64:3626–37.
- 78 Thornemo M, Tallheden T, Sjogren Jansson E, *et al.* Clonal populations of chondrocytes with progenitor properties identified within human articular cartilage. *Cells Tissues Organs* 2005;180:141–50.
- 79 Grogan SP, Miyaki S, Asahara H, *et al.* Mesenchymal progenitor cell markers in human articular cartilage: normal distribution and changes in osteoarthritis. *Arthritis Res Ther* 2009;11:R85.
- 80 Burdick JA, Mauck RL, Gorman JH, *et al.* Acellular biomaterials: an evolving alternative to cell-based therapies. *Sci Transl Med* 2013;5:176ps174.
- 81 Yu Y, Brouillette MJ, Seol D, *et al.* Functional full-thickness articular cartilage repair by rhSDF-1alpha loaded fibrin/ha hydrogel network via chondrogenic progenitor cells homing. *Arthritis Rheumatol* 2015;10:1002.
- 82 Mhanna R, Ozturk E, Vallmajo-Martin Q, *et al.* FGF2-modified MMP-sensitive polyethylene glycol hydrogels induce chondrogenic differentiation of human mesenchymal stem cells. *Tissue Eng Part A* 2014;20:1165–74.
- 83 Freeman I, Kedem A, Cohen S. The effect of sulfation of alginate hydrogels on the specific binding and controlled release of heparin-binding proteins. *Biomaterials* 2008;29:3260–8.
- 84 Lee CH, Cook JL, Mendelson A, *et al.* Regeneration of the articular surface of the rabbit synovial joint by cell homing: a proof of concept study. *Lancet* 2010;376:440–8.
- 85 Dvorak J. Osteoarthritis in football: FIFA/F-MARC approach. *Br J Sports Med* 2011;45:673–6.
- 86 Mandelbaum B, Mithoefer K, Peterson L, *et al.* Cartilage issues in football (soccer): an executive summary of the Federation Internationale de Football Association (FIFA)/International Cartilage Repair Society (ICRS) initiative. *Cartilage* 2012;3(Suppl 1):65–105.