

Oculosporidial polyp infected secondarily by *Enterobius vermicularis*

S. Anuradha, K. Bharathi, Abdul Khalique

Department of Pathology, Shri Satya Sai Medical College and Research Institute, Ammapettai, Kancheepuram District, Tamilnadu, India

Abstract

Oculosporidiosis caused by *Rhinosporidium seeberi* is a common infectious disease of south India. Here we are reporting a rare case of oculosporidial polyp containing another parasite *Enterobius vermicularis* as a co infection. This is the first report of its kind in literature. A nine year old school going girl from a rural area presented with a reddish polypoidal lesion from conjunctiva along with complaints of severe itching over it. On examination, the polyp measured 5 mm × 5 mm in size, reddish, granular with a tendency to bleed on touch. Her vision was normal. All the basic investigations were within normal limits. A differential diagnosis of conjunctival papilloma, foreign body granuloma and oculosporidiosis were considered clinically. The polyp was removed completely using electro cautery with healthy margins around the lesion. To our surprise histopathological examination of the swelling revealed the presence of two different parasites in the conjunctival polyp. Sections showed sporangia of *Rhinosporidium seeberi*, fragments of *Enterobius vermicularis* and its eggs. She was then treated with anti helminthic drugs. Two months of follow up till now showed no recurrence of the lesion.

Key Words: Conjunctival polyp, *Enterobius vermicularis*, oculosporidiosis, rare case

Address for correspondence:

Dr. K. Bharathi, Shri Satya Sai Medical College and Research Institute, Ammapettai, Kancheepuram District, Tamil Nadu - 603 108, India.

E-mail: bharathi.pathos@gmail.com

Received: 25.05.2012, Accepted: 14.07.2012

INTRODUCTION

Oculosporidiosis of the eye is a chronic granulomatous inflammatory condition caused by *Rhinosporidium seeberi* (first described by Seeber). Here we are reporting the first case report documenting the presence of *Enterobius vermicularis* inside the oculosporidial polyp as a secondary infection.

CASE REPORT

A nine year old school going girl from a rural area presented to our outpatient department with a reddish polypoidal lesion in conjunctiva of left eye. She had severe itching over it for duration of 2 weeks. On examination, the polyp was reddish, granular arising from the palpebral conjunctiva measuring 5 mm × 5 mm in size with a tendency to bleed on touch. Her vision was normal. All the basic investigations were within normal limits.

Lab values: Hb-10 gm/dl, Total count-9000 cells/cu.mm, Differential count-P₆₅L₃₀E₅ Stool Examination: Negative for any worm or its ova.

She gave a positive history of taking bath in in the village ponds. A differential diagnosis of conjunctival

Access this article online	
Quick Response Code:	Website: www.advbiores.net
	DOI: 10.4103/2277-9175.140673

Copyright: © 2014 Anuradha. This is an open-access article distributed under the terms of the Creative Commons Attribution License, which permits unrestricted use, distribution, and reproduction in any medium, provided the original author and source are credited.

How to cite this article: Anuradha S, Bharathi K, Khalique A. Oculosporidial polyp infected secondarily by *Enterobius vermicularis*. Adv Biomed Res 2014;3:195.

papilloma, foreign body granuloma and oculosporidiosis were considered clinically. She was admitted in the hospital and the polyp was removed completely with electro cautery leaving healthy margins around the lesion.

The specimen was sent to histopathology department. Sections studied from the polyp showed many sporangia of *Rhinosporidium seeberi* of about 200 – 300 μ in size filled with spores. Microscopic examination of the swelling also revealed the presence of another parasite *Enterobius vermicularis* in the conjunctival polyp [Figures 1 and 2]. Few fragments of *Enterobius vermicularis* worm and its eggs were seen inside the polyp. Cutsection of gravid female *Enterobius vermicularis* filled with eggs was also seen. The eggs of *Enterobius* are typically planoconvex of 50-60 μ size with a hyaline wall. Parasites were surrounded by granulomatous inflammation containing lymphocytes and eosinophils [Figure 3 and 4]. Hence the diagnosis of 'Oculosporidiosis with the secondary infection of

Enterobius vermicularis' was made. This is the first case reporting the presence of *Enterobius vermicularis* in the oculosporidial polyp. She was then treated with anti helminthic drugs. Two months of follow up till now showed no recurrence of the lesion.

DISCUSSION

Rhinosporidium seeberi, causative agent for oculosporidiosis is not a classic fungus as thought of once but it is considered to be an aquatic Protista parasite belonging to a new DRIP clade 'Mesomycetozoa'.^[1] This novel clade includes fish and amphibian pathogens (Dermocystidium, the Rosette agent, Ichthyophonus, Psorospermium).^[2] This is the reason for the positive history of bathing in stagnant pond water in 90% of the cases and also in our case.

Though rhinosporidiosis occurs worldwide, it is endemic

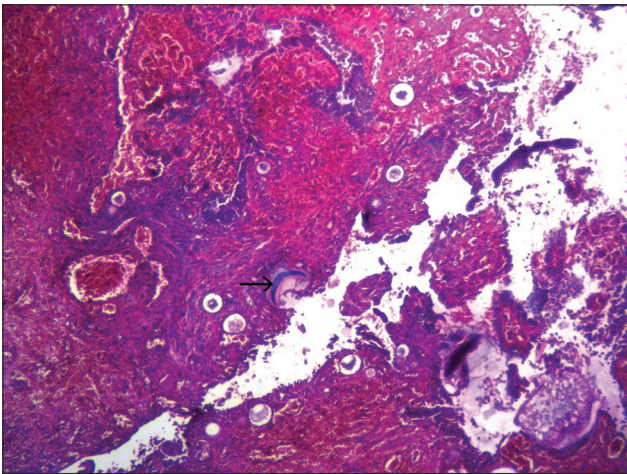


Figure 1: Photomicrograph shows stratified squamous epithelium of conjunctival polyp containing sporangia of *Rhinosporidium seeberi*. It also shows fragment of *Enterobius vermicularis* worm (H and E, $\times 100$)

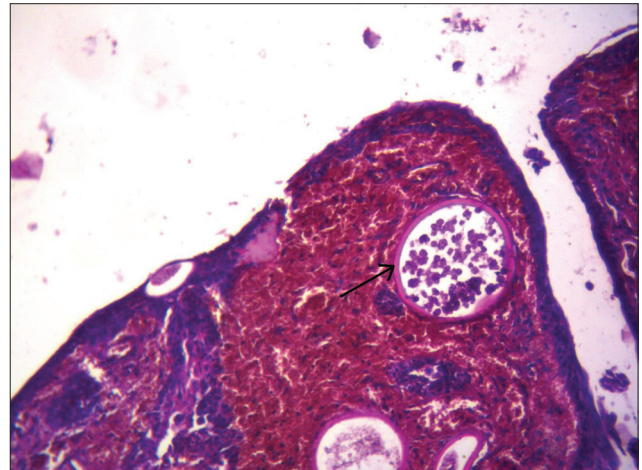


Figure 2: Photomicrograph from conjunctival polyp shows sporangia of *Rhinosporidium seeberi* containing spores and thick chitinous wall under higher magnification (H and E, $\times 100$)

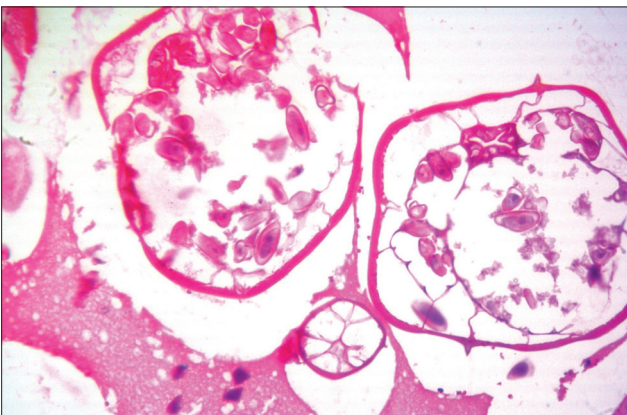


Figure 3: Photomicrograph shows cut section of gravid *Enterobius vermicularis* filled with eggs in the polyp (H and E, $\times 400$)

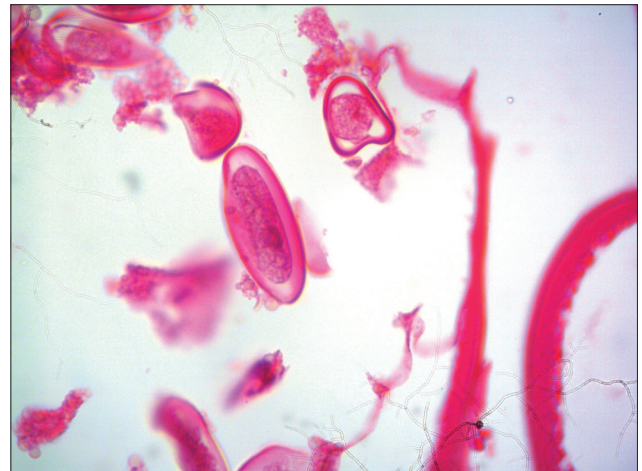


Figure 4: Photomicrograph shows typical planoconvex eggs of *Enterobius vermicularis* under higher magnification (H and E, $400\times$)

in South India and Srilanka.^[3] Males are commonly affected. The upper respiratory tract is involved in majority of cases. Eye with its adnexa is involved in about 15% of cases. Rhinosporidiosis is also known to involve the rare sites like male urethra, penis, bone, vagina, vulva, parotid duct, trachea, larynx and may become disseminated to occur in a generalized form.^[4,5,6,7]

In our case, the oculosporidial polyp showed the presence of another parasite *Enterobius vermicularis*. Gravid uterus of a female enterobius filled with eggs was seen in the histopathological sections.

Enterobius vermicularis, a common intestinal nematode of Indian children, is commonly seen in areas of poor faecal sanitation. The commonest symptom of *Enterobius vermicularis* is perianal pruritus. Man is the only host of the worm. The common route of transmission is through the ingestion of embryonated eggs in the contaminated food and water. The other common route of infection in children is the autoinfection, hand to mouth spread due to perianal itching. The contaminated finger nails are the biggest inoculum to spread the worm and its ova to the eye and thereby to the the oculosporidial polyp while itching. This may be the most possible route of spread in our case.

NIH swab or cellophane swab or scotch tape swab method is used to collect the eggs from the perianal skin. Stool examination may not be helpful at times because eggs are not often released in the faeces. Occasionally eggs are detected in the urine and vaginal smears.^[7] The adult worms are identified by the double bulb esophagus and a pair of cervical alae in the anterior end.

The highlight of our case report is the secondary infection of *Enterobius vermicularis* in the oculosporidial polyp. *Enterobius vermicularis* in the eye and its adnexa is documented in three case reports from different countries.^[8,9] But the oculosporidial polyp containing the *Enterobius vermicularis* is very rare and to our knowledge, this is the first case report of its kind.

CONCLUSION

This case report is presented for its rarity and also to stress the need of eradicating the parasitic diseases by inculcating sanitation. Though the parasitic diseases are not fatal, can cause high morbidity, malnutrition and diminished work capacity in children. Health education about personal hygiene and proper disposal of human excreta in rural areas will prevent most of the parasitic diseases including enterobiasis. The best possible preventive measure for rhinosporidiosis is avoiding any contact with stagnant ponds.

ACKNOWLEDGMENTS

We gratefully acknowledge our thanks to the department of ophthalmology for providing us with the specimen and case history.

REFERENCES

1. Arseculeratne SN. Recent advances in rhinosporidiosis and Rhinosporidium seeberi. Indian J Med Microbiol 2002;20:119-31.
2. Herr RA, Ajello L, Taylor JW, Arseculeratne SN, Mendoza L. Phylogenetic analysis of Rhinosporidium seeberi's 18S small-subunit ribosomal DNA groups this pathogen among members of the protoctistan Mesomycetozoa clade. J Clin Microbiol 1999;37:2750-4.
3. Sudarshan V, Gahine R, Daharwal A, Kujur P, Hussain N, Krishnani C, et al. Rhinosporidiosis of the parotid duct presenting as a parotid duct cyst - a report of three cases. Indian J Med Microbiol 2012;30:108-11.
4. Ravi R, Mallikarjuna VS, Chaturvedi HK. Rhinosporidiosis mimicking penile malignancy. Urol Int 1992;49:224-6.
5. Pal DK, Mukherjee B, Hati GC, Chowdhry MK. Rhinosporidiosis in male urethra. Indian J Urol 2003;19:162-3.
6. Rekha P, Thomas B, Pappachan JM, Venugopal KP, Jayakumar TK, Sukumaran P. Tracheal rhinosporidiosis. J Thorac Cardiovasc Surg 2006;132:718-9.
7. Shetty JB, Kulkarni DV, Prabhu V. Eggs containing larvae of *Enterobius vermicularis* in vaginal smear. J Cytol 2012;29:94-6.
8. Dutta LP, Kalita SN. *Enterobius vermicularis* in the conjunctival sac. Indian J Ophthalmol 1976;24:34-6.
9. Babady NE, Awender E, Geller R, Miller T, Scheetz G, Arguello H, et al. *Enterobius vermicularis* in a 14-year-old girl's eye. J Clin Microbiol 2011;49:4369-70.

Source of Support: Nil, Conflict of Interest: None declared.