

## RESEARCH

# The combination of ATA classification and FNA results can improve the diagnostic efficiency of malignant thyroid nodules

Zhenzhen Wang<sup>1</sup>, Xiangying Zhu<sup>1</sup>, Xiaohui Yu<sup>1</sup>, Haixia Guan<sup>1</sup>, Lei Zhao<sup>2</sup>, Yixia Zhang<sup>2</sup>, Yuge Li<sup>2</sup>, Liang Sang<sup>2</sup>, Yuchen Han<sup>3</sup>, Yushu Li<sup>1</sup>, Zhongyan Shan<sup>1</sup> and Weiping Teng<sup>1</sup>

<sup>1</sup>Department of Endocrinology and Metabolism, Institute of Endocrinology, The First Affiliated Hospital of China Medical University, Shenyang, China

<sup>2</sup>Department of Ultrasonography, The First Affiliated Hospital of China Medical University, Shenyang, China

<sup>3</sup>Department of Pathology, Shanghai Chest Hospital, Shanghai Jiao Tong University, Shanghai, China

Correspondence should be addressed to Y Li: [liyushu@hotmail.com](mailto:liyushu@hotmail.com)

## Abstract

**Purpose:** To determine the diagnostic efficiency of the ATA classification and ultrasound-guided fine-needle aspiration (FNA) results in identifying the risk factors of malignancy, we analyzed the thyroid nodules of patients who underwent thyroidectomy and compared preoperative ATA classifications with FNA results.

**Methods:** We retrospectively analyzed 274 nodules of 196 patients who underwent ultrasonography, FNA and thyroidectomy. Histopathological findings of thyroid nodules were considered as the Au standard in the analysis of the diagnostic efficiency of the ATA classification and FNA results. Univariate analysis and binary multivariate logistic regression analysis were applied to identify the ultrasound features associated with malignancy.

**Results:** The overall malignancy rate of 274 nodules was 41.6%. The areas under the ROC curves (AUCs) for the ATA classification and FNA results were 0.88 and 0.878, respectively ( $P < 0.001$ ). The sensitivity and specificity of the ATA classification were 86 and 86.9%, whereas those of FNA results were 68.5 and 91.4%, respectively. The specificity (98.7%) and sensitivity (94.3%) increased after the combined use of the ATA classification and FNA results. Taller-than-wide shape, microcalcifications, hypoechogenicity and irregular margins were independent risk factors for malignancy. Microcalcifications had the highest OR (7.58), and taller-than-wide shape had the highest specificity in BSRTC I, II, III and IV cytology.

**Conclusion:** The diagnostic efficiency of the ATA classification and FNA results in identifying malignant nodules was high, and the use of both criteria improved the diagnostic accuracy. Taller-than-wide shape, microcalcifications, hypoechogenicity and irregular margins were independent risk factors for malignancy.

## Key Words

- ▶ thyroid nodule
- ▶ ultrasound features
- ▶ fine-needle aspiration
- ▶ ATA guidelines

*Endocrine Connections*  
(2020) **9**, 903–911

## Introduction

Nodular thyroid disease is common in endocrine practice. In iodine-sufficient areas, the thyroid nodule detection rate, as determined by palpation, is 5% in women and 1% in men (1, 2), whereas the detection rate, as determined by high-resolution ultrasonography, is 19–68%.

Thyroid nodules are more common in women and the elderly (3, 4), with 5–15% of thyroid nodules characterized as malignant (5). Therefore, the accurate diagnosis of nodules and the prompt treatment of malignant nodules can improve patient outcomes.

Currently, fine-needle aspiration (FNA) is the most accurate diagnostic method in the identification of malignant thyroid nodules (6). The Bethesda System for Reporting Thyroid Cytopathology (BSRTC) has been widely used since 2009, and it classifies thyroid nodules into six categories based on FNA results, provides recommendations for managing malignant tumors and identifies the risk factors for malignancy (7). Although the sensitivity of FNA in the diagnosis of malignant nodules is 65–98%, the specificity is 72–100% and the accuracy is >95% (7, 8), approximately 20% of FNA results are inconclusive due to poorly preserved specimens (9) and 20–25% are indeterminate due to the presence of follicular lesions or follicular neoplasms (8, 10, 11), although most lesions with indeterminate cytology are surgically confirmed to be benign (7, 12). Thus, an improved awareness of risk factors for thyroid nodules, such as age, gender, and especially the ultrasound features, can reduce the frequency of unnecessary surgeries for benign lesions.

High-resolution ultrasonography is a simple, reliable and commonly used method that can describe a thyroid nodule's morphology, characteristics and lymphadenopathy, which can facilitate diagnosis. In addition, ultrasonography can guide FNA, which can reduce the generation of non-diagnostic specimens. Ultrasound features, such as solidity, hypoechogenicity, microcalcifications, taller-than-wide shape and irregular margins, are useful in the diagnosis of malignant nodules (13, 14, 15, 16, 17, 18). Furthermore, other studies have reported that a simple cystic and spongiform appearance have a higher negative predictive value (NPV) for malignancy (13, 19, 20). However, there is overlap in the ultrasound features of benign and malignant nodules (21, 22), and the sensitivity and specificity of malignant nodules are also different when considering these features (23, 24, 25). The '2015 American Thyroid Association (ATA) Management Guidelines for Adult Patients with Thyroid Nodules and Differentiated Thyroid Cancer' (referred to as the ATA classification) (26) more comprehensively defines the ultrasound features and risk factors of thyroid nodules, and characteristics of solidity, hypoechogenicity, irregular margins (i.e. infiltrative, microlobulated), taller-than-wide shape, microcalcifications, rim calcification interruption, and evidence of extrathyroidal extensions are signs of malignancy. Therefore, the ATA classification is useful in the diagnosis and treatment of nodules when FNA results are non-diagnostic or indeterminate.

Presently, the ATA classification is not commonly used in the stratification of risk factors for thyroid nodule malignancy in China. In this study, we analyzed

274 nodules of 196 patients with ultrasound-guided FNA results, compared ATA classification with histopathology results, and discussed the diagnostic efficiency of the ATA classification and FNA results for thyroid nodules.

## Materials and methods

### Patients

This study retrospectively analyzed 274 nodules (160 benign and 114 malignant) of 196 patients (28 male and 168 female) pathologically confirmed from June 2016 to June 2018 at the First Affiliated Hospital of China Medical University. The average age was  $47.24 \pm 12.15$  years, and the average nodule size was  $19.18 \pm 11.82$  mm. All patients underwent ultrasonography, FNA and thyroidectomy and received complete ultrasonography, FNA cytology and pathology results. Patients with a history of thyroid surgery, thyroid metastasis, and those with surgically removed nodules that were not one-to-one matched with the ultrasound findings were excluded from the study.

The study was approved by Ethics Institutional Review Board of China Medical University. Data collection followed the principles outlined in the Declaration of Helsinki. All patients provided their written informed consent to share their own anonymous information to participate in our study.

### Ultrasound findings and evaluation

Toshiba color Doppler ultrasound instruments (models ssa-680 and aplio770, Japan) were used with a 7- to 10-MHz linear array transducer. The ultrasonography reported several parameters as follows: number, size, location, morphology, margins, the presence or absence of taller-than-wide shape, echogenicity, calcifications and vascularity. Clinical results were stored in workstations connected to the ultrasound instruments. According to the ATA classification (26), the ultrasound malignant risk classifications were as follows: high suspicion, intermediate suspicion, low suspicion, very low suspicion and benign.

### Ultrasound-guided fine-needle aspiration and cytopathological evaluation

The ultrasound-guided FNA was performed on nodules with at least one suspicious ultrasound characteristic or on the largest lesion when none of the thyroid nodules had

any suspicious ultrasound features. FNA was performed with a 25-gauge needle attached to a 2 mL syringe. Each nodule was aspirated at least twice, and the aspirated specimens were expelled onto glass slides, which were then placed into 95% alcohol for Papanicolaou staining. FNA cytopathological results were classified according to BSRTC (7) as follows: (i) non-diagnostic or unsatisfactory (DN/UNS); (ii) benign; (iii) atypia (or follicular lesion) of undetermined significance (AUS/FLUS); (iv) follicular neoplasm or suspicious for a follicular neoplasm (FN/SFN); (v) suspicious for malignancy (SPUS); and (vi) malignant.

### Statistical analyses

Analyses were performed with SPSS version 25.0 software. Differences in nodule characteristics between benign and malignant nodules were analyzed using *t*-test or  $\chi^2$  test. The diagnostic efficiency was expressed as the sensitivity, specificity and accuracy. Receiver operating characteristic (ROC) curves were constructed, and the areas under the curves (AUCs) were calculated. The predetermined level of significance was set at  $P < 0.05$ . The binary multivariate logistic regression analysis was performed to identify the independent factors associated with malignancy, and their diagnostic value in the prediction of thyroid cancer was then tested.

## Results

### ATA classification, FNA results and histopathological findings of thyroid nodules

Among 274 nodules, 43.4% (119) were ATA classified as high suspicion, 17.9% (49) as intermediate suspicion, 27.7% (76) as low suspicion, and 10.9% (30) as very low suspicion. The malignancy rates in these categories were as follows: 82.4 (98), 16.3 (8), 9.2 (7) and 3.3% (1), respectively, and the malignancy rate was significantly different among the groups ( $\chi^2 = 137.31$ ,  $P < 0.001$ ). FNA cytopathological classifications were as follows: 6.6% (18) were BSRTC I, 36.1% (99) were BSRTC II, 23% (63) were BSRTC III, 2.9% (8) were BSRTC IV, 20.4% (56) were BSRTC V and 10.9% (30) were BSRTC VI. The malignancy rates in these classifications were as follows: 50 (9), 6.1 (6), 39.7 (25), 12.5 (1), 78.6 (44) and 96.7% (29), respectively, and the malignancy rate was significantly different among the groups ( $\chi^2 = 123.8$ ,  $P < 0.001$ ). For BSRTC I nodules, all very low and low suspicion nodules were benign, and most (90%) intermediate and high suspicion

nodules were malignant. For BSRTC III and IV nodules, 78.6% high suspicion nodules were malignant, and most (90.7%) other nodules were benign (Table 1).

### Diagnostic efficiency of the ATA classification and FNA results

When a nodule classified according to the ATA classification was considered highly suspicious, the AUC was 0.880 (95% CI 0.837–0.923,  $P < 0.001$ ) (Fig. 1A); the Youden index (0.729) was highest; the sensitivity, specificity, positive predictive value (PPV), negative predictive value (NPV) and accuracy (AC) were 86, 86.9, 82.4, 89.7 and 86.5%, respectively (Table 2). After BSRTC I specimens were excluded, the best cutoff point for diagnosis was BSRTC V; the AUC was 0.878 (95% CI 0.834–0.921,  $P < 0.001$ ) (Fig. 1B); the Youden index (0.609) was highest; the sensitivity, specificity, PPV, NPV and AC were 69.5, 91.4, 84.9, 81.2 and 82.4%, respectively (Table 2).

When a nodule classified according to one criterion (either the ATA classification or FNA results) was considered malignant, and then both criteria were used to re-classify the nodule, the sensitivity, specificity, PPV, NPV and AC were 94.3, 77.5, 74.4, 95. and 84.4%, respectively. The AUC was 0.859 (95% CI 0.811–0.907). When a nodule classified according to both criteria (the ATA classification and FNA results) was considered malignant, the sensitivity, specificity, PPV, NPV and AC were 61.9, 98.7, 97, 78.8 and 83.6%, respectively. The AUC was 0.803 (95% CI 0.742–0.864) (Table 2).

### Analysis of nodule characteristics

The clinical characteristics of patients and the ultrasound features of nodules were examined by univariate analysis (Table 3). Younger patients with single and smaller nodules had a higher malignancy rate ( $P < 0.05$ ), although no significant differences in gender and nodule location were noted ( $P = 0.437$  and  $0.895$ , respectively). With regard to the ultrasound features of nodules, those that were solid and hypoechoic, with irregular margins, taller-than-wide shape, microcalcifications, and posterior echo attenuation were malignant, whereas those with regular halo were benign, and the differences were significant ( $P < 0.001$ ). In binary multivariate logistic regression analysis, hypoechogenicity (OR=2.74, 95% CI 1.421–5.29), taller-than-wide shape (OR=5.81, 95% CI 1.79–18.86), microcalcifications (OR=7.58, 95% CI 3.89–14.77) and irregular margins (OR=3.87, 95% CI 2.0–7.46) were

**Table 1** ATA classification, FNA results and histopathological findings of thyroid nodules.

BSRTC	ATA classification										Total (%)	Malignancy rate (%) <sup>a</sup>	Malignancy rate (%) <sup>b</sup>
	Very low		Low		Intermediate		High		All				
	Ben-	Mal-	Ben-	Mal-	Ben-	Mal-	Ben-	Mal-	Ben-	Mal-			
I (DN/UUS)	2	0	6	0	0	2	1	7	9	9	18 (6.6)	50.0	1-4
II (Benign)	20	0	37	0	24	2	12	4	93	6	99 (36.1)	6.1	0-3
III (AUS/FLUS)	5	0	16	1	11	2	6	22	38	25	63 (23)	39.7	5-15
IV (FN/SFN)	1	0	5	0	1	1	0	0	7	1	8 (2.9)	12.5	15-30
V (SFM)	1	1	5	4	4	1	2	38	12	44	56 (20.4)	78.6	60-75
VI (Malignant)	0	0	0	2	1	0	0	27	1	29	30 (10.9)	96.7	97-99
All	29	1	69	7	41	8	21	98	160	114	274	41.6	
Total (%)	30 (10.9)	1	76 (27.7)	7	49 (17.9)	8	119 (43.4)	82.4	274	41.6			
Malignancy rate (%) <sup>c</sup>	3.3		9.2		16.3		82.4		41.6				
Malignancy rate (%) <sup>d</sup>	<3		5-10		10-20		70-90						

<sup>a</sup>The malignancy rate of the FNA results in this study, <sup>b</sup>The malignancy rate of BSRTC (7), <sup>c</sup>The malignancy rate of the ATA classification in this study and <sup>d</sup>The malignancy rate of the ATA classification (26). Ben, benign; Mal, malignant.

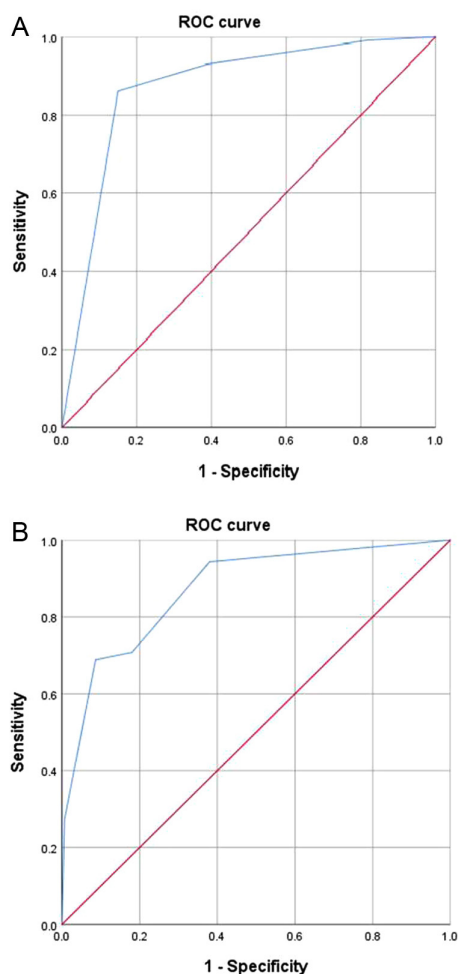
independent risk factors for thyroid nodule malignancy (Table 4).

We evaluated the diagnostic efficiency of the malignant ultrasound features for nodules classified according to FNA results as BSRTC I, II, III and IV (Table 5). Taller-than-wide shape showed the highest specificity (95.6–100%) for all nodules, and BSRTC II showed the highest accuracy (91.9%), but its sensitivity was poor. The sensitivity of each ultrasound feature was low (<70%). In the presence of microcalcifications or hypoechoogenicity, the sensitivity of all nodules was the highest (83.3–92.3%).

### Discussion

A variety of methods are available for the preoperative examination of thyroid nodules. The ultrasonography is a commonly used imaging technology that utilizes a high-resolution probe to identify thyroid nodule features (27). FNA is one of the most accurate methods for differentiating between the benign and malignant thyroid nodules (6); however, the FNA is often performed by experienced personnel at medical centers in China. Therefore, the diagnosis of thyroid nodules as benign or malignant based on ultrasound features is important for the subsequent treatment of the disease.

A total of 274 nodules from 196 patients were included in this study, and the overall malignancy rate was 41.6%. Potential selection bias may have contributed to the higher malignancy rate. According to the different ultrasound features, the ATA classification categorized thyroid nodules into five categories, namely high suspicion, intermediate suspicion, low suspicion, very low suspicion and benign, and the malignancy rates were 70–90, 10–20, 5–10, <3 and <1%, respectively (26). By contrast, the malignancy rates were 82.4, 16.3, 9.2 and 3.3%, respectively, when we re-classified nodules according to the ATA classification. The malignancy rate of the FNA results was higher than that of the BSRTC classification, except for BSRTC IV and VI nodules (7). Among BSRTC I nodules, all very low and low suspicion were benign, and 90% of intermediate and high suspicion nodules were malignant. Furthermore, 78.6% of high suspicion BSRTC III and IV nodules were malignant, and most (90.7%) other nodules were benign. These findings were consistent with those reported by Tang *et al.* (28, 29). Collectively, these results indicate that the ATA classification, when used in combination with FNA results, can improve the detection accuracy of benign and malignant nodules (30, 31). In our study, 18 (6.6%) nodules were classified as BSRTC I



**Figure 1**  
AUCs of the ATA classification (A) and FNA results (B).

according to the FNA results, with a high malignancy rate of 50%, which was caused by selection bias. Among these nodules, 61.1% (11/18) nodules were <10 mm in size, and 44.4% (8/18) nodules were classified as high suspicion nodules according to the ATA classification. Chinese guidelines recommend nodules <10 mm but with malignant ultrasound characteristics should undergo FNA as well, which increased the proportion of non-diagnostic

results of FNAB and their malignancy rate in this study. Furthermore, 99 (36.1%) nodules were classified as BSRTC II according to the FNA results, with a malignancy rate of 6.1%, and these patients underwent surgery for two main reasons. First, intermediate and high suspicion nodules accounted for 42.4% of all nodules, and among the low and very low suspicion nodules, more than half measured >2 cm. Therefore, clinicians in China are more likely to adopt and to devise treatment protocols using the ultrasound features of nodules. Secondly, surgery was preferred by patients.

The AUCs of the ATA classification and FNA results were 0.88 and 0.878, respectively ( $P < 0.001$ ), indicating a high diagnostic value. The ATA classification showed a sensitivity of 86% and a specificity of 86.9%. For the ATA classification, a number of studies reported a sensitivity of 77.3–98.2% and a specificity of 37.4–76.6% (32, 33, 34, 35), consistent with the results of this study, whereas FNA results showed a sensitivity of 68.5% and a specificity of 91.4%. The low sensitivity indicated a high rate of misdiagnosis. In this study, the optimal cutoff point of the FNA results was BSRTC V, indicating that BSRTC III nodules were classified as benign in the calculation of sensitivity. Because the malignancy rate of BSRTC III nodules was 39.7% and these nodules were considered benign, the misdiagnosis rate increased. On the other hand, FNA results showed a high specificity (91.4%), indicating that the misdiagnosis rate was low, and a NPV of 81.2%, suggesting that the FNA results contributed to the diagnosis of thyroid cancer.

After combining the ATA classification and FNA results, if a nodule was considered malignant by both criteria, the specificity and PPV increased to 98.7 and 97%, respectively, indicating that when both criteria indicate malignancy or a suspicious malignancy, the malignant possibility of such a nodule is very high, and the probability of misdiagnosing a malignant nodule as a benign nodule is very low. Therefore, surgery is required for these patients. If a nodule was considered malignant by one criterion, the sensitivity and NPV increased

**Table 2** Diagnostic efficiency of the ATA classification, FNA results and both criteria in combination.

Method	SEN	SPE	PPV	NPV	AC	AUC	95% CI	P value of the AUC
ATA	86	86.9	82.4	89.7	86.5	0.880	0.837–0.923	< 0.001
FNA	69.5	91.4	84.9	81.2	82.4	0.878	0.834–0.921	< 0.001
Combination 1	94.3	77.5	74.4	95.1	84.4	0.859	0.811–0.907	< 0.001
Combination 2	61.9	98.7	97	78.8	83.6	0.803	0.742–0.864	< 0.001

Combination 1: Conditions under which a nodule was diagnosed as malignant according to one criterion (the ATA classification or FNA results).  
Combination 2: Conditions under which a nodule was diagnosed as malignant according to both criteria (the ATA classification and FNA results).  
AC, accuracy; NPV, negative predictive value; PPV, positive predictive value; SEN, sensitivity; SPE, specificity.

**Table 3** Clinical characteristics of patients and ultrasound features of thyroid nodules.

Characteristics		Benign (160)	Malignancy (114)	$\chi^2/Z$ value	P value
Sex	Male	20 (52.6%)	18 (47.4%)	0.603	0.437
	Female	140 (59.3%)	96 (40.7%)		
Age		53 (46.25, 58.75)	40 (32, 51)	2.524	<0.001
Size (mm)		18.55 (11.5, 31.68)	13.1 (9.08, 19)	33.107	<0.001
Location	Isthmus	3 (50%)	3 (50%)	0.222	0.895
	Left	77 (59.2%)	53 (40.8%)		
	Right	80 (58%)	58 (42%)		
Number	Single	11 (31.4%)	24 (68.6%)	12.009	0.001
		149 (62.3%)	90 (37.7%)		
Structure	Solid	62 (43.7%)	80 (56.3%)	27.407	<0.001
	Mainly solid	85 (72.6%)	32 (27.4%)		
	Mainly Cystic	13 (86.7%)	2 (13.3%)		
Hypoechoic	Present	59 (41.3%)	84 (58.7%)	36.148	<0.001
	Absent	101 (77.1%)	30 (22.9%)		
Margins	Regular	129 (78.2%)	36 (21.8%)	66.846	<0.001
	Irregular	31 (28.4%)	78 (71.6%)		
Taller-than-wide shape	Present	5 (22.73%)	17 (77.3%)	12.525	0.001
	Absent	155 (61.5%)	97 (38.5%)		
Calcification	Micro	23 (23.2%)	76 (76.8%)	78.88	<0.001
	Macro	36 (60%)	24 (40%)		
	Comet tail-like	35 (63.6%)	20 (36.4%)		
Halo	Regular	35 (87.5%)	5 (12.5%)	16.332	<0.001
	Irregular	2 (33.3%)	4 (66.7%)		
Echotexture	Homogeneous	31 (66%)	16 (34%)	1.336	0.248
	Heterogeneous	129 (56.8%)	98 (43.2%)		
Posterior echo attenuation	Present	13 (29.5%)	31 (70.5%)	17.956	<0.001
Attenuation	Absent	147 (63.9%)	83 (36.1%)		

to 94.3 and 95.1%, respectively, indicating that when both criteria indicate non-malignancy, the malignant possibility of such a nodule is low. Therefore, follow-up is recommended for these patients.

Recent studies have indicated that no single ultrasound feature can directly and accurately predict the malignancy of a nodule (36, 37); however, some characteristics, such as hypoechogenicity, irregular margins, taller-than-wide shape, microcalcifications and solidity, may predict thyroid cancer (14, 16, 17, 19, 20, 38). In this study, solidity, hypoechogenicity, irregular margins, taller-than-wide shape, microcalcifications and posterior echo attenuation associated with malignant nodules, whereas regular halo associated with

benign nodules. Furthermore, taller-than-wide shape, microcalcifications, hypoechogenicity and irregular margins were independent risk factors for malignancy, consistent with the results of previous studies (15, 18, 39, 40, 41). Taller-than-wide shape is a highly specific indicator of thyroid cancer, with studies reporting a specificity of 81.5–98.5% for malignant thyroid nodules with a taller-than-wide shape (15, 23, 42). In this study, the OR value of taller-than-wide shape was 5.81, which significantly increased the risk of malignancy. The specificity was >95% for all nodules, and the accuracy of BSRTC II nodules was 91.9%. Microcalcifications are another important feature in predicting malignant thyroid nodules. The specificity of microcalcifications was high (90%), but the sensitivity was low (35.4–44.2%) (24, 42). In this study, 65.8% of malignant nodules had microcalcifications, which increased the risk of malignancy by 7.6 times. Furthermore, the sensitivity was >50%, whereas the specificity was >85%, indicating that the predictive value was high. Hypoechogenicity is another important indicator of malignancy, but the ability to predict malignancy was poor compared with taller-than-wide shape and microcalcifications. BSRTC I nodules showed high sensitivity (77.8%), specificity (88.9%) and accuracy (83.3%). In the presence of

**Table 4** Binary multivariate logistic regression analysis of ultrasound features for the detection of malignant thyroid nodules.

US characteristics	$\beta$	OR (95% CI)	P value
Hypoechoic	1.008	2.74 (1.421–5.29)	0.003
Taller-than-wide shape	1.760	5.81 (1.79–18.86)	0.003
Microcalcification	2.025	7.58 (3.89–14.77)	<0.001
Irregular margins	1.352	3.87 (2.0–7.46)	<0.001

$\beta$ , regression coefficient; OR, odds ratio.

**Table 5** Diagnostic efficacy of ultrasound features for the detection of malignant thyroid nodules.

US characteristics	BSRTC I			BSRTC II			BSRTC III and IV		
	SEN	SEP	AC	SEN	SEP	AC	SEN	SEP	AC
Hypoechoic	77.8	88.9	83.3	66.7	64.5	64.6	69.2	62.2	64.8
Taller-than-wide shape	22.2	100	61.1	16.7	96.8	91.9	11.5	95.6	64.8
Microcalcification	55.6	88.9	72.2	50	85	82.8	61.5	86.7	77.5
Irregular margins	66.7	88.9	77.8	50	77.4	75.8	65.4	84.4	77.5
Either microcalcification or hypoechoic	88.9	77.8	83.3	83.3	55.9	57.9	92.3	57.8	70.4

microcalcifications or hypoechogenicity, the sensitivity increased and the misdiagnosis rate decreased for various nodules.

Age and nodule size are also important predictors of malignancy. We found that patients with malignant nodules were younger than those with benign nodules, consistent with the results of previous studies (14, 43, 44). The research by Kwong *et al.* found an increased prevalence of thyroid nodules with older patients, but it decreases the risk that such nodules will be malignant with advancing age (44). Although young patients have a high malignant of thyroid nodules, they have a better prognosis. The 8th Edition of AJCC for TNM staging suggested that extending the cutoff age to 55 years would prevent over-staging in low-risk patients and prevent over-aggressive treatment (45). However, the usefulness of nodule size in the diagnosis of malignancy is still controversial. A previous study has revealed a nonlinear correlation between size and malignant tumor risk. For nodules measuring 2.5 cm, the malignancy risk was the lowest. For nodules measuring <2.5 cm, the risk increased 53% for every centimeter decrease in size, and for nodules measuring >2.5 cm, the risk increased 39% for every centimeter increase in size (46). Kamran reported that the malignant risk of nodules measuring 1.0–1.9 cm was 10.5%, whereas that of nodules measuring >2 cm were 15%. However, the malignant risk of nodules measuring >2 cm was not increased (47). In a study of 1003 nodules from 659 patients, nodules measuring <2 cm (~30%) had the highest malignancy risk with no graded decrease in risk for nodules measuring >2 cm (~20%), indicating that thyroid nodule size is inversely related to malignancy risk, as larger nodules showed lower malignancy rates (48), consistent with the results of this study. However, in our study, 75.5% of nodules were <2.5 cm in diameter, and considering that patients with larger nodules may have underwent surgery in the absence of FNA, there was selection bias, which increased the malignancy rate of small nodules.

There were several limitations in our study. First, the number of cases and samples were small, and further

studies with larger sample sizes are needed. Secondly, there was selection bias, because patients included in this study underwent FNA and surgery, indicating that patients were not representative of the whole population. Therefore, the malignancy rate may be higher than that reported in this study. Thirdly, this was a single-center, retrospective study, which may have reduced the statistical significance. Therefore, multi-center and prospective studies from different institutions and regions are necessary to verify our findings.

In conclusion, both the ATA classification and FNA results had high value in detecting benign and malignant nodules. The combined use of both criteria was more effective determining the nature of thyroid nodules. Analysis of ultrasound features revealed that taller-than-wide shape, microcalcifications, hypoechogenicity and irregular margins were the main predictive factors of malignancy. For BSRTC I, III and IV nodules, taller-than-wide shape showed the highest specificity, which greatly reduced the misdiagnosis rate. In the presence of microcalcifications or hypoechogenicity, the sensitivity improved, thereby reducing the misdiagnosis rate. Therefore, the combined use of the ATA classification, FNA results and specific ultrasound features can determine the nature of nodules more accurately, provide more valuable reference information for the selection of the treatment protocol, and guide clinicians to make correct decisions.

#### Declaration of interest

The authors declare that there is no conflict of interest that could be perceived as prejudicing the impartiality of the research reported.

#### Funding

This study was supported by the National Natural Science Foundation of China (Grant No. 81770784).

#### References

- Vander JB, Gaston EA & Dawber TR. The significance of nontoxic thyroid nodules. Final report of a 15-year study of the incidence of thyroid malignancy. *Annals of Internal Medicine* 1968 **69** 537–540. (<https://doi.org/10.7326/0003-4819-69-3-537>)

- 2 Tunbridge WMG, Evered DC, Hall R, Appleton D, Brewis M, Clark F, Evans JG, Young E, Bird T & Smith PA. The spectrum of thyroid disease in a community: the Whickham survey. *Clinical Endocrinology* 1977 **7** 481–493. (<https://doi.org/10.1111/j.1365-2265.1977.tb01340.x>)
- 3 Tan GH & Gharib H. Thyroid incidentalomas: management approaches to nonpalpable nodules discovered incidentally on thyroid imaging. *Annals of Internal Medicine* 1997 **126** 226–231. (<https://doi.org/10.7326/0003-4819-126-3-199702010-00009>)
- 4 Guth S, Theune U, Aberle J, Galach A & Bamberger CM. Very high prevalence of thyroid nodules detected by high frequency (13 MHz) ultrasound examination. *European Journal of Clinical Investigation* 2009 **39** 699–706. (<https://doi.org/10.1111/j.1365-2362.2009.02162.x>)
- 5 Hegedüs L. Clinical practice. The thyroid nodule. *New England Journal of Medicine* 2004 **351** 1764–1771. (<https://doi.org/10.1056/NEJMcp031436>)
- 6 Gharib H. Fine-needle aspiration biopsy of thyroid nodules: advantages, limitations, and effect. *Mayo Clinic Proceedings* 1994 **69** 44–49. ([https://doi.org/10.1016/s0025-6196\(12\)61611-5](https://doi.org/10.1016/s0025-6196(12)61611-5))
- 7 Cibas ES, Ali SZ & NCI Thyroid FNA State of the Science Conference. The Bethesda system for reporting thyroid cytopathology. *American Journal of Clinical Pathology* 2009 **132** 658–665. (<https://doi.org/10.1309/AJCPHLMWMI3JV4LA>)
- 8 Gharib H & Goellner JR. Fine-needle aspiration biopsy of the thyroid: an appraisal. *Annals of Internal Medicine* 1993 **118** 282–289. (<https://doi.org/10.7326/0003-4819-118-4-199302150-00007>)
- 9 Yang J, Schnadig V, Logrono R & Wasserman PG. Fine-needle aspiration of thyroid nodules: a study of 4703 patients with histologic and clinical correlations. *Cancer* 2007 **111** 306–315. (<https://doi.org/10.1002/cncr.22955>)
- 10 Yassa L, Cibas ES, Benson CB, Frates MC, Doubilet PM, Gawande AA, Moore FD, Kim BW, Nosé V, Marqusee E, *et al.* Long-term assessment of a multidisciplinary approach to thyroid nodule diagnostic evaluation. *Cancer* 2007 **111** 508–516. (<https://doi.org/10.1002/cncr.23116>)
- 11 Miller B, Burkey S, Lindberg G, Snyder WH & Nwariaku FE. Prevalence of malignancy within cytologically indeterminate thyroid nodules. *American Journal of Surgery* 2004 **188** 459–462. (<https://doi.org/10.1016/j.amjsurg.2004.07.006>)
- 12 American Thyroid Association (ATA) Guidelines Taskforce on Thyroid Nodules and Differentiated Thyroid Cancer, Cooper DS, Doherty GM, Haugen BR, Kloos RT, Lee SL, Mandel SJ, Mazzaferri EL, McIver B, Pacini F
- 13 Zhang Y, Meng F, Hong L & Chu L. A risk score model for evaluation and management of patients with thyroid nodules. *Hormone and Metabolic Research* 2018 **50** 543–550. (<https://doi.org/10.1055/a-0630-5239>)
- 14 He Y, Xu H, Zhao C, Sun L, Li X, Yue W, Guo L, Wang D, Ren W, Wang Q, *et al.* Cytologically indeterminate thyroid nodules: increased diagnostic performance with combination of US TI-RADS and a new scoring system. *Scientific Reports* 2017 **7** 6906. (<https://doi.org/10.1038/s41598-017-07353-y>)
- 15 Cappelli C, Pirola I, Cumetti D, Micheletti L, Tironi A, Gandossi E, Martino E, Cherubini L, Agosti B, Castellano M, *et al.* Is the anteroposterior and transverse diameter ratio of nonpalpable thyroid nodules a sonographic criteria for recommending fine-needle aspiration cytology? *Clinical Endocrinology* 2005 **63** 689–693. (<https://doi.org/10.1111/j.1365-2265.2005.02406.x>)
- 16 Deng XH, Tang LN, Liu SQ, Li XL, He YP & Xu HX. A proposal to stratify the intermediate-risk thyroid nodules according to the AACE/ACE/AME guidelines with ultrasound features. *Scientific Reports* 2017 **7** 17901. (<https://doi.org/10.1038/s41598-017-18207-y>)
- 17 Kim GR, Kim MH, Moon HJ, Chung WY, Kwak JY & Kim EK. Sonographic characteristics suggesting papillary thyroid carcinoma according to nodule size. *Annals of Surgical Oncology* 2013 **20** 906–913. (<https://doi.org/10.1245/s10434-012-2830-4>)
- 18 Kuru B & Kefeli M. Risk factors associated with malignancy and with triage to surgery in thyroid nodules classified as Bethesda category IV (FN/SFN). *Diagnostic Cytopathology* 2018 **46** 489–494. (<https://doi.org/10.1002/dc.23923>)
- 19 Kim DW, Lee EJ, In HS & Kim SJ. Sonographic differentiation of partially cystic thyroid nodules: a prospective study. *American Journal of Neuroradiology* 2010 **31** 1961–1966. (<https://doi.org/10.3174/ajnr.A2204>)
- 20 Moon WJ, Baek JH, Jung SL, Kim DW, Kim EK, Kim JY, Kwak JY, Lee JH, Lee JH, Lee YH, *et al.* Ultrasonography and the ultrasound-based management of thyroid nodules: consensus statement and recommendations. *Korean Journal of Radiology* 2011 **12** 1–14. (<https://doi.org/10.3348/kjr.2011.12.1.1>)
- 21 Wienke JR, Chong WK, Fielding JR, Zou KH & Mittelstaedt CA. Sonographic features of benign thyroid nodules: interobserver reliability and overlap with malignancy. *Journal of Ultrasound in Medicine* 2003 **22** 1027–1031. (<https://doi.org/10.7863/jum.2003.22.10.1027>)
- 22 Malhi HS, Velez E, Kazmierski B, Gulati M, Deurdulian C, Cen SY & Grant EG. Peripheral thyroid nodule calcifications on sonography: evaluation of malignant potential. *American Journal of Roentgenology* 2019 **213** 672–675. (<https://doi.org/10.2214/AJR.18.20799>)
- 23 Kim EK, Park CS, Chung WY, Oh KK, Kim DI, Lee JT & Yoo HS. New sonographic criteria for recommending fine-needle aspiration biopsy of nonpalpable solid nodules of the thyroid. *American Journal of Roentgenology* 2002 **178** 687–691. (<https://doi.org/10.2214/ajr.178.3.1780687>)
- 24 Moon WJ, Jung SL, Lee JH, Na DG, Baek JH, Lee YH, Kim J, Kim HS, Byun JS, Lee DH, *et al.* Benign and malignant thyroid nodules: US differentiation – multicenter retrospective study. *Radiology* 2008 **247** 762–770. (<https://doi.org/10.1148/radiol.2473070944>)
- 25 Woliński K, Szkudlarek M, Szczepanek Parulska E & Ruchała M. Usefulness of different ultrasound features of malignancy in predicting the type of thyroid lesions: a meta-analysis of prospective studies. *Polish Archives of Internal Medicine* 2014 **124** 97–104. (<https://doi.org/10.20452/pamw.2132>)
- 26 Haugen BR, Alexander EK, Bible KC, Doherty GM, Mandel SJ, Nikiforov YE, Pacini F, Randolph GW, Sawka AM, Schlumberger M, *et al.* 2015 American Thyroid Association Management Guidelines for adult patients with thyroid nodules and differentiated thyroid cancer: the American Thyroid Association Guidelines Task Force on thyroid nodules and differentiated thyroid cancer. *Thyroid* 2016 **26** 1–133. (<https://doi.org/10.1089/thy.2015.0020>)
- 27 Bastin S, Bolland MJ & Croxson MS. Role of ultrasound in the assessment of nodular thyroid disease. *Journal of Medical Imaging and Radiation Oncology* 2009 **53** 177–187. (<https://doi.org/10.1111/j.1754-9485.2009.02060.x>)
- 28 Tang AL, Falciiglia M, Yang H, Mark JR & Steward DL. Validation of American Thyroid Association ultrasound risk assessment of thyroid nodules selected for ultrasound fine-needle aspiration. *Thyroid* 2017 **27** 1077–1082. (<https://doi.org/10.1089/thy.2016.0555>)
- 29 Park CJ, Kim EK, Moon HJ, Yoon JH, Park VY & Kwak JY. Thyroid nodules with nondiagnostic cytologic results: follow-up management using ultrasound patterns based on the 2015 American Thyroid Association guidelines. *American Journal of Roentgenology* 2018 **210** 412–417. (<https://doi.org/10.2214/AJR.17.18532>)
- 30 Maia FF, Matos PS, Pavin EJ & Zantut-Wittmann DE. Thyroid imaging reporting and data system score combined with Bethesda system for malignancy risk stratification in thyroid nodules with indeterminate results on cytology. *Clinical Endocrinology* 2015 **82** 439–444. (<https://doi.org/10.1111/cen.12525>)
- 31 Maffione AM & Rubello D. Diagnosis: indeterminate thyroid nodules – two scores are better than one. *Nature Reviews: Endocrinology* 2014 **10** 580–581. (<https://doi.org/10.1038/nrendo.2014.140>)



- 32 Lee JH, Han K, Kim EK, Moon HJ, Yoon JH, Park VY & Kwak JY. Validation of the modified 4-tiered categorization system through comparison with the 5-tiered categorization system of the 2015 American Thyroid Association guidelines for classifying small thyroid nodules on ultrasound. *Head and Neck* 2017 **39** 2208–2215. (<https://doi.org/10.1002/hed.24888>)
- 33 Gao L, Xi X, Jiang Y, Yang X, Wang Y, Zhu S, Lai X, Zhang X, Zhao R & Zhang B. Comparison among TIRADS (ACR TI-RADS and KWAK-TI-RADS) and 2015 ATA guidelines in the diagnostic efficiency of thyroid nodules. *Endocrine* 2019 **64** 90–96. (<https://doi.org/10.1007/s12020-019-01843-x>)
- 34 Yoon JH, Lee HS, Kim EK, Moon HJ & Kwak JY. Malignancy risk stratification of thyroid nodules: comparison between the thyroid imaging reporting and data system and the 2014 American Thyroid Association management guidelines. *Radiology* 2016 **278** 917–924. (<https://doi.org/10.1148/radiol.2015150056>)
- 35 Ahmadi S, Oyekunle T, Jiang X, Scheri R, Perkins J, Stang M, Roman S & Sosa JA. A direct comparison of the ATA and TI-RADS ultrasound scoring systems. *Endocrine Practice* 2019 **25** 413–422. (<https://doi.org/10.4158/EP-2018-0369>)
- 36 De Napoli L, Bakkar S, Ambrosini CE, Materazzi G, Proietti A, Macerola E, Basolo F & Miccoli P. Indeterminate single thyroid nodule: synergistic impact of mutational markers and sonographic features in triaging patients to appropriate surgery. *Thyroid* 2016 **26** 390–394. (<https://doi.org/10.1089/thy.2015.0311>)
- 37 Nicolaou MA, Jacobs K, Bhana S, Naidu K & Nicolaou V. A retrospective study correlating sonographic features of thyroid nodules with fine-needle aspiration cytology in a South African setting. *SA Journal of Radiology* 2019 **23** 1749. (<https://doi.org/10.4102/sajr.v23i1.1749>)
- 38 Park JY, Lee HJ, Jang HW, Kim HK, Yi JH, Lee W & Kim SH. A proposal for a thyroid imaging reporting and data system for ultrasound features of thyroid carcinoma. *Thyroid* 2009 **19** 1257–1264. (<https://doi.org/10.1089/thy.2008.0021>)
- 39 Batawil N & Alkordy T. Ultrasonographic features associated with malignancy in cytologically indeterminate thyroid nodules. *European Journal of Surgical Oncology* 2014 **40** 182–186. (<https://doi.org/10.1016/j.ejso.2013.11.015>)
- 40 Chieng JSL, Lee CH, Karandikar AA, Goh JPN & Tan SSS. Accuracy of ultrasonography-guided fine needle aspiration cytology and significance of non-diagnostic cytology in the preoperative detection of thyroid malignancy. *Singapore Medical Journal* 2019 **60** 193–198. (<https://doi.org/10.11622/smedj.2018105>)
- 41 Durante C, Grani G, Lamartina L, Filetti S, Mandel SJ & Cooper DS. The diagnosis and management of thyroid nodules: a review. *JAMA* 2018 **319** 914–924. (<https://doi.org/10.1001/jama.2018.0898>)
- 42 Li RQ, Yuan GH, Chen M, Shao YM, Zhu SN, Zhang JQ & Guo XH. Evaluation of diagnostic efficiency of ultrasound features on malignant thyroid nodules in Chinese patients. *Chinese Medical Journal* 2016 **129** 1784–1788. (<https://doi.org/10.4103/0366-6999.186643>)
- 43 Bessey LJ, Lai NBK, Coorrough NE, Chen H & Sippel RS. The incidence of thyroid cancer by fine needle aspiration varies by age and gender. *Journal of Surgical Research* 2013 **184** 761–765. (<https://doi.org/10.1016/j.jss.2013.03.086>)
- 44 Kwong N, Medici M, Angell TE, Liu X, Marqusee E, Cibas ES, Krane JF, Barletta JA, Kim MI, Larsen PR, *et al.* The influence of patient age on thyroid nodule formation, multinodularity, and thyroid cancer risk. *Journal of Clinical Endocrinology and Metabolism* 2015 **100** 4434–4440. (<https://doi.org/10.1210/jc.2015-3100>)
- 45 Kim M, Kim YN, Kim WG, Park S, Kwon H, Jeon MJ, Ahn HS, Jung SH, Kim SW, Kim WB, *et al.* Optimal cut-off age in the TNM staging system of differentiated thyroid cancer: is 55 years better than 45 years? *Clinical Endocrinology* 2017 **86** 438–443. (<https://doi.org/10.1111/cen.13254>)
- 46 Banks ND, Kowalski J, Tsai HL, Somervell H, Tufano R, Dackiw APB, Marohn MR, Clark DP, Umbricht CB & Zeiger MA. A diagnostic predictor model for indeterminate or suspicious thyroid FNA samples. *Thyroid* 2008 **18** 933–941. (<https://doi.org/10.1089/thy.2008.0108>)
- 47 Kamran SC, Marqusee E, Kim MI, Frates MC, Ritner J, Peters H, Benson CB, Doubilet PM, Cibas ES, Barletta J, *et al.* Thyroid nodule size and prediction of cancer. *Journal of Clinical Endocrinology and Metabolism* 2013 **98** 564–570. (<https://doi.org/10.1210/jc.2012-2968>)
- 48 Cavallo A, Johnson DN, White MG, Siddiqui S, Antic T, Mathew M, Grogan RH, Angelos P, Kaplan EL & Cipriani NA. Thyroid nodule size at ultrasound as a predictor of malignancy and final pathologic size. *Thyroid* 2017 **27** 641–650. (<https://doi.org/10.1089/thy.2016.0336>)

Received in final form 12 August 2020

Accepted 17 August 2020

Accepted Manuscript published online 18 August 2020