

Surgery First Approach in Orthognathic Surgery - Considerations and Clinical Case Report

Thaynan Maximiano Borges, Izabella Sol, Cristovão Marcondes de Castro Rodrigues, Felipe Gomes Gonçalves Peres Lima, Claudia Jordão Silva, Lair Mambrini Furtado

Department of Oral and Maxillofacial Surgery, Traumatology and Implantology - Hospital de Clínicas, Federal University of Uberlândia, Uberlândia, Minas Gerais, Brazil

Abstract

The Rationale: The surgery first approach is a safe and stable procedure for the correction of dentofacial deformities that requires little orthodontic correction, leading to a faster return of functions. **Patient Concerns:** Patient with facial discrepancies seeks treatment that returns function and aesthetics, requiring a less prolonged treatment with adequate results. **Diagnosis:** Clinical, facial, and radiological image analysis was used for diagnosis and treatment plan. **Treatment:** Surgery first approach was performed in a patient with facial pattern II dolichocephalic, vertical maxillary excess, mandibular growth deficiency, aesthetic, and functional complaints, with the completion of the orthodontic treatment in 15 months. **Outcomes:** Follow-up of 36 months showed no evidence of recurrence of the initial condition and occlusal stability was maintained. The patient had no more functional and aesthetic complaints. **Take-away Lessons:** Aesthetic and functional improvements were observed more rapidly due to the correction of the skeletal deformity, with improvement in behavior and self-esteem.

Keywords: Dentofacial deformities, maxillofacial abnormalities, orthodontics, orthognathic surgery

INTRODUCTION

Dentofacial deformities are associated with malocclusion, masticatory, phonetic, and respiratory difficulties and are usually treated through three stages: preoperative orthodontics, orthognathic surgery, and postoperative orthodontics. Presurgical orthodontic procedures, despite producing satisfactory results, are a slow process and may cause masticatory discomfort during orthodontic treatment and psychosocial problems associated with delayed response to patient complaints and worsening of the facial profile discrepancy, causing great dissatisfaction and possible patient dropout.^[1]

Given the circumstances of time and results, surgery before orthodontic treatment has been consolidated. In this way, presurgical orthodontic treatment is eliminated, and the maxillary-mandibular complex is repositioned in the ideal position and then orthodontics is performed.^[2] The patient benefits from a shorter period of orthodontics and eliminates the phase of greater facial discrepancy, requiring greater preparation from the surgeon.^[3,4] These factors can lead to high rates of patient satisfaction from the early stages of treatment and better cooperation during postoperative orthodontics.^[5]

The uniqueness of this case is the treatment of a patient with vertical maxillary excess and mandibular growth deficiency, with aesthetic and functional complaints, whose anticipated benefit for bimaxillary orthognathic surgery was effective to restore the self-esteem and functions to the patient in short time when compared to the standard treatment.

CASE REPORT

A 20-year-old female was admitted to the Oral and Maxillofacial Surgery and Traumatology Team, with the main complaint of gingival smile.

Address for correspondence: Dr. Lair Mambrini Furtado,
Av. Pará, 1720, Bloco 4T, Sala 2G07, Campus Umuarama, Uberlândia,
Minas Gerais, Brazil.
E-mail: ctbmf@umurama.ufu.br

Received: 09-01-2021

Last Revised: 13-05-2021

Accepted: 10-06-2021

Published: 01-02-2022

This is an open access journal, and articles are distributed under the terms of the Creative Commons Attribution-NonCommercial-ShareAlike 4.0 License, which allows others to remix, tweak, and build upon the work non-commercially, as long as appropriate credit is given and the new creations are licensed under the identical terms.

For reprints contact: WKHLRPMedknow_reprints@wolterskluwer.com

How to cite this article: Borges TM, Sol I, de Castro Rodrigues CM, Peres Lima FG, Silva CJ, Furtado LM. Surgery first approach in orthognathic surgery - Considerations and clinical case report. Ann Maxillofac Surg 2021;11:349-51.

Access this article online

Quick Response Code:



Website:
www.amsjournal.com

DOI:
10.4103/ams.ams_8_21

Upon clinical examination, the patient had increased lower facial height (upper third 56mm, middle third 58 mm, and lower third 72 mm), no passive lip seal, 10 mm of upper incisor exposure with relaxed lips, 5 mm gingival smile, and retrognathism [Figure 1]. The patient had concerns about her facial aesthetics, looking for a treatment that would provide the reestablishment of its functions and that would not demand treatment in a long period, with a low rate of complication.

After facial analysis, clinical and tomographic evaluation, bimaxillary orthognathic surgery by surgery first approach (anticipated benefit), and postsurgical orthodontics were defined as a treatment plan. The treatment goals were to improve the facial profile, provide a stable and satisfactory occlusion, improve the exposure of the central incisors, decrease the gummy smile, and promote better facial harmony.

Virtual planning of surgical movements was carried out with the Dolphin Imaging® software: for the maxilla, 8.5 mm impaction, and 2 mm advancement; for the mandible, 10 mm advancement with counterclockwise rotation of the plane occlusal angle, and 5 mm of chin impaction. The intermediate splint was made using 3D printing and used at the time of surgery. Orthodontic brackets were installed to optimize the transoperative intermaxillary block.

Following the planning above, orthognathic surgery was performed under general anaesthesia, without complications [Figure 2]. The patient was discharged after 48 h with a home prescription of amoxicillin 500 mg every 8 h for 7 days and sodium dipyrone 500 mg every 6 h for 3 days. Guidance was also given regarding the diet (60 days liquid/pasty) and care for the surgical wound.

In the postoperative clinical control, the patient presented a satisfactory evolution in the period with an improvement in facial harmony, masticatory, respiratory function, and absence of pain in the temporomandibular joint, reduction of the overjet and overbite and Class I occlusion, with improvement of the facial thirds (upper third of 56 mm, middle third of 50 mm, and lower third of 69 mm). Orthodontic treatment was started 3 months after surgery, first in the maxilla and 3 months later in the mandible, with completion after 15 months. During outpatient visits, the patient showed an improvement in behavior and self-esteem. After 36 months of follow-up, no evidence of recurrence of the initial condition was observed, and occlusal stability was maintained [Figure 3].

DISCUSSION

The literature demonstrates favourable conditions for the surgery first approach, highlighting positive results. In an analysis of cases in patients with maxillofacial deformities, Hernández-Alfaro *et al.*^[5] report a satisfactory result and early patient motivation without any aesthetic worsening at any time during treatment. After 36 months of the surgery, the patient's reported an improvement of her self-esteem associated with the restoration of functional and aesthetic functions.

We observed the completion of the treatment in 18 months after the orthognathic surgery, corroborating the literature as reported

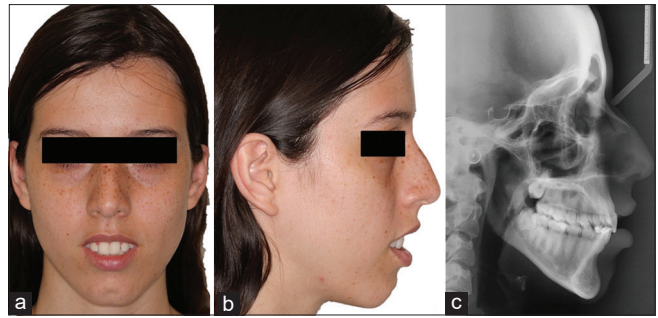


Figure 1: Preoperative facial analysis in (a) front and (b) lateral view. (c) X-ray analysis proving Class II dolichocephalic pattern

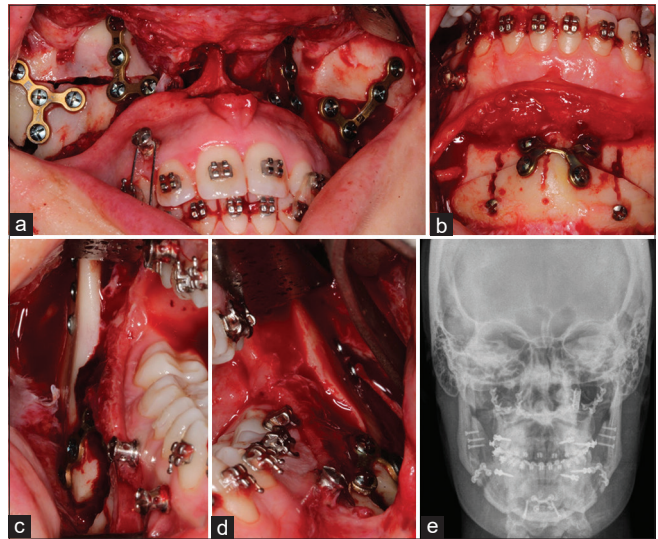


Figure 2: Transoperative steps of (a) Impaction and advancement of the maxilla, (b) Chin impaction, and (c and d) Advancement of mandible, (e) Immediate X-ray

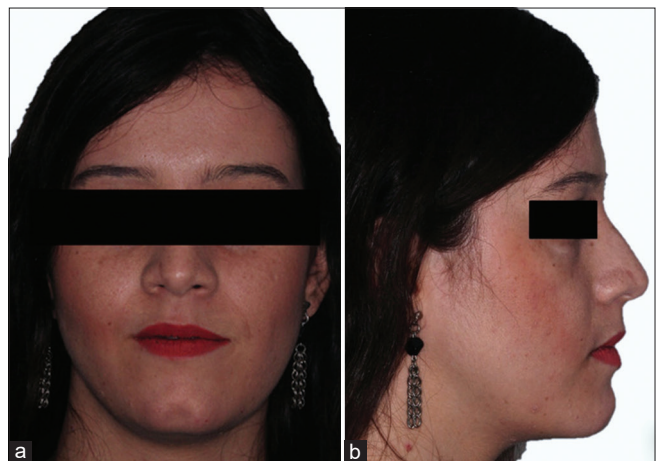

Figure 3: Postoperative facial analysis in (a) front and (b) lateral view after 36 months of surgery

in the studies of Yu *et al.*,^[6] which demonstrated reduction in treatment time to a margin between 14 and 19 months and an early aesthetic improvement. In the same way, Kishore *et al.*^[2]

highlight as a safe treatment modality when well indicated, benefiting the patient with the suppression of the worsening phase, preoperative aesthetics, and reduced treatment time.

In a systematic review and meta-analysis of ten retrospective studies, Yang *et al.*^[7] compared the stability, effectiveness, and results between the anticipated benefit and conventional surgery, showing that the anticipated benefit was more effective in relation to the total duration of treatment, with similar stability and surgical results compared with conventional surgery. Corroborating with these findings, we demonstrated reduction of the total treatment time with aesthetic gain without obstacles during the subsequent orthodontic treatment, leaving the patient satisfied and reducing the chances of abandonment of treatment due to the worsening of facial profile and occlusion showed when the orthodontic is performed before the surgery.

After the performance of surgical osteotomies, stimulation of periodontal metabolism occurs for 3–4 months postoperatively, facilitating postoperative orthodontic movement.^[8,9] As for the conventional method, the literature has shown a criticism regarding time, damage to teeth and support structures, demotivation, and psychosocial damage.^[3] With the rapid restoration of maxillomandibular discrepancy, we observed increased patient collaboration during treatment, where progressive clinical improvement and satisfaction were observed monthly in follow-ups.

There is no doubt how complex the orthognathic treatment is, from planning to execution. Mahmood *et al.* (2018)^[4] emphasize that the indication must be accurate, requiring minimal transverse discrepancy between dental arches and mild-moderate sagittal, vertical, and transverse discrepancies from the patient and carried out by experienced professionals. In addition, the adjunct use of virtual planning increases the predictability of the expected outcome,^[4] as corroborated in our clinical report.

The virtual planning helped in the execution of this case due to the surgical predictability at the end of the work, making it possible to predict the dental mesh to be achieved. With the evolution of osteosynthesis materials for rigid fixation of bone segments during the surgery, the ability to diagnose and plan with 3D technology has made surgical procedures more predictable, contributing to a more concrete treatment approach and a broader view of the patient, being able to be supported by conclusive and visible prognoses.^[10]

Our report shows the treatment of only one patient, representing a limitation of our study and making it necessary to carry out randomized clinical studies to show the effectiveness that this technique undoubtedly provides, thus solving the professionals' fears about its performance. However, this case reinforces the

benefits of indicating this approach for correcting dentofacial discrepancies, making treatment faster and more satisfactory, and at the same time providing greater patient collaboration.

CONCLUSION

Adoption of the anticipated benefit for the treatment of dental skeletal deformities shows the main benefits of good predictability, agility, and comfort to the patient in relation to conventional surgery, eliminating the presurgical phase of worsening of the discrepancy and facial profile.

Declaration of patient consent

The authors certify that they have obtained all appropriate patient consent forms. In the form, the patient has given her consent for her images and other clinical information to be reported in the journal. The patient understands that name and initials will not be published and due efforts will be made to conceal identity, but anonymity cannot be guaranteed.

Financial support and sponsorship

Nil.

Conflicts of interest

There are no conflicts of interest.

REFERENCES

1. Gandedkar NH, Chng CK, Tan W. Surgery-first orthognathic approach case series: Salient features and guidelines. *J Orthod Sci* 2016;5:35-42.
2. Kishore MS, Ankush B, Rachala MR, Dharmender SR. Surgery first orthognathic approach: A review article. *Int J Sci Tech* 2016;6:25-34.
3. Mah DH, Kim SG, Oh JS, You JS, Jung SY, Kim WG, *et al.* Comparative study of postoperative stability between conventional orthognathic surgery and a surgery-first orthognathic approach after bilateral sagittal split ramus osteotomy for skeletal class III correction. *J Korean Assoc Oral Maxillofac Surg* 2017;43:23-8.
4. Mahmood HT, Ahmed M, Fida M, Kamal AT, Fatima F. Concepts, protocol, variations and current trends in surgery first orthognathic approach: A literature review. *Dental Press J Orthod* 2018;23:36.e1-36.e6.
5. Hernández-Alfaro F, Guijarro-Martínez R, Peiró-Guijarro MA. Surgery first in orthognathic surgery: What have we learned? A comprehensive workflow based on 45 consecutive cases. *J Oral Maxillofac Surg* 2014;72:376-90.
6. Yu HB, Mao LX, Wang XD, Fang B, Shen SG. The surgery-first approach in orthognathic surgery: A retrospective study of 50 cases. *Int J Oral Maxillofac Surg* 2015;44:1463-7.
7. Yang L, Xiao YD, Liang YJ, Wang X, Li JY, Liao GQ. Does the surgery-first approach produce better outcomes in orthognathic surgery? A systematic review and meta-analysis. *J Oral Maxillofac Surg* 2017;75:2422-9.
8. Park HM, Lee YK, Choi JY, Baek SH. Maxillary incisor inclination of skeletal Class III patients treated with extraction of the upper first premolars and two-jaw surgery: Conventional orthognathic surgery vs surgery-first approach. *Angle Orthod* 2014;84:720-9.
9. Kim JY, Jung HD, Kim SY, Park HS, Jung YS. Postoperative stability for surgery-first approach using intraoral vertical ramus osteotomy: 12 month follow-up Jun-Young Kima. *Br J Oral Maxillofac Surg* 2014;52:539-44.
10. Moreira LM, Leal MPS. Virtual planning in Orthognathic Surgery: A shift of paradigm. *Rev bras odontol* 2013;70:46-8.