

Case Report

Treatment of co-existing thoracic and abdominal aortic aneurysms using combined endoluminal stent grafts and conventional surgery

N Arya, M Rao, B Lee, RJ Hannon, CV Soong

Accepted 24 September 2003

We report three patients with a descending thoracic aortic aneurysm (DTAA) and a separate infra-renal abdominal aortic aneurysm (AAA) who had initial endovascular repair of the DTAA followed by repair of AAA. Endovascular stent repair of DTAA avoids the significant morbidity associated with thoracotomy and open repair. Hence more patients with multilevel aortic aneurysm may be eligible for surgical intervention. Aortic aneurysms most often present as a confluent dilatation, either of the thoracic, the thoraco-abdominal or the infra renal abdominal aorta. Co-existing multilevel aortic aneurysms are present in a small subgroup of patients. Of these, the combination of infra-renal abdominal aortic aneurysm (AAA) and an aneurysm of descending thoracic aorta is the most frequently encountered.¹ The usual method of open repair of these aneurysms is through simultaneous or sequential thoracotomy and laparotomy, which is associated with significant morbidity and mortality.

Endoluminal treatment of infrarenal AAA and descending thoracic aorta aneurysm (DTAA) is now feasible as an alternative to conventional open repair. This is especially true for the repair of DTAA. We report three patients with a descending thoracic aneurysm and a separate infra-renal AAA who had initial endovascular repair of the DTAA followed by repair of AAA.

CASE REPORT

Case 1 A 70-year-old woman with an AAA was suspected to have a concomitant thoracic aneurysm on her chest x-ray. This was confirmed with contrast enhanced spiral CT scan which also allowed detailed evaluation of the aneurysm for

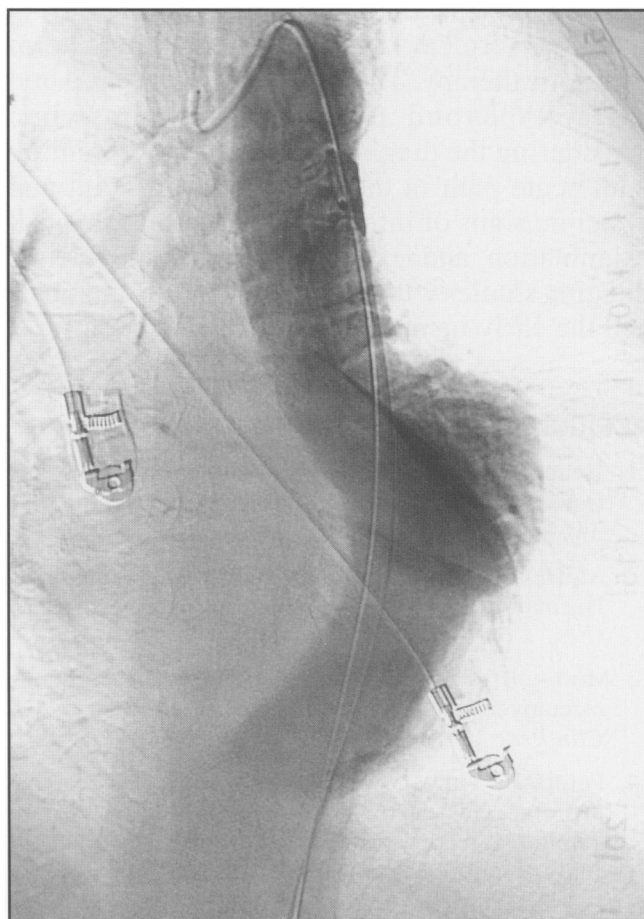


Fig 1. Intraoperative angiogram delineating the DTAA prior to stent graft placement.

Regional Vascular and Endovascular Surgery Unit, Belfast City Hospital, Lisburn Road, Belfast BT9 7AB.

N Arya, FRCS, SpR Vascular Surgery
M Rao, FRCS, SpR General Surgery
B Lee, MD, Consultant Surgeon
RJ Hannon, MD, Consultant Surgeon
CV Soong, MD, Consultant Surgeon
Correspondence to Mr Arya

endovascular repair. It confirmed the presence of a saccular DTAA measuring 70mm in maximum diameter and 110mm in length. The aneurysm commenced 35mm distal to the left subclavian artery, terminating 40mm proximal to the coeliac axis. The diameter of the aorta distal to this aneurysm was 33mm, whilst the aorta at the left subclavian was 29mm. The infrarenal AAA was 56mm in maximum diameter, and was found unsuitable for endovascular repair due to a short conical neck.

The patient subsequently underwent endovascular stent-graft repair of the DTAA, using two modular stent-grafts, each 40mm diameter, 100mm long (Talent, Medtronic). The stent-graft was passed via the right common femoral artery which was exposed surgically. Imaging was performed through a catheter positioned in the arch of the aorta, inserted percutaneously through the left femoral artery. An intra-operative angiogram showed complete exclusion of the thoracic aneurysm with no endoleak. The post-operative period was uneventful. A follow-up CT scan six weeks later demonstrated the stent to be in a satisfactory position, with no evidence of endoleak. The abdominal aortic aneurysm was then repaired using a retroperitoneal approach with an 18mm tube graft. A repeat CT scan at one year revealed a satisfactory repair with no endoleak.

Case 2 A 78-year-old man was found to have a large abdominal and thoracic aortic aneurysm during investigations for prostatic symptoms. Subsequent contrast enhanced CT scan showed a DTAA 56mm in maximum diameter, 150mm in length, arising 90mm distal to the left subclavian artery. The upper abdominal aorta was normal in caliber. The infrarenal AAA measured 90mm in diameter. Angulation and conicity of the infrarenal neck made it unsuitable for endovascular repair. In addition, there were bilateral common iliac aneurysms measuring approximately 45mm in diameter, with the left iliac aneurysm extending into the internal iliac artery.

The thoracic aneurysm was repaired first using three 40mm diameter stent-grafts (Talent, Medtronic), each 150mm in length, inserted through a surgically exposed right common femoral artery. Imaging was again performed using a catheter passed percutaneously via the left femoral artery. A completion intraoperative angiogram showed no evidence of endoleak.

Due to a post-operative chest infection, the repair of the AAA was deferred for two months. This was then repaired through a transperitoneal approach using a bifurcated graft anastomosed distally to the origins of both external iliac arteries. The right internal iliac artery was revascularised using a 6mm Dacron graft from the left limb of the bifurcated graft. At 12 months the patient remained well and repeat CT scan of the chest showed no endoleak.

Case 3 A 76 year-old man was detected as having a DTAA and an AAA following investigation of a heart murmur. The thoracic aneurysm measured 68mm in maximum diameter, arising 50mm distal to the left subclavian artery. The diameter of the aorta below the aneurysm was 35mm. The infrarenal AAA measured 59mm in maximum diameter, with a 15mm parallel neck distal to the origin of the renal arteries. This was deemed suitable for endovascular stent-graft repair.

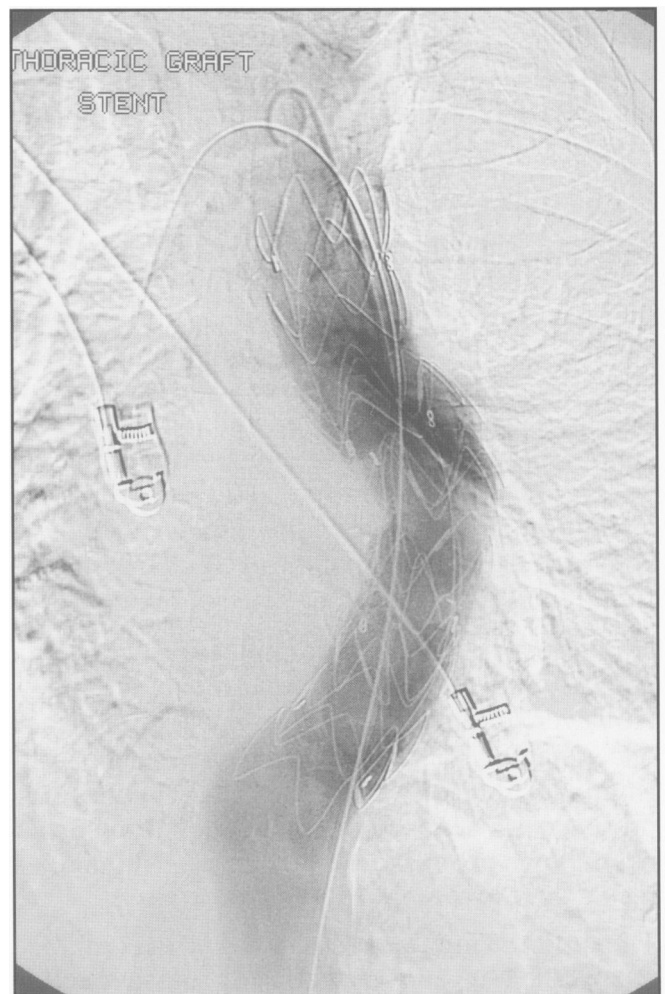


Fig 2. Intraoperative angiogram showed exclusion of DTAA after stent graft deployment.

The thoracic aneurysm was repaired using two 42mm diameter x 96mm stent-grafts (Talent, Medtronic) using the same technique as described above. Intraoperative completion angiography showed no evidence of endoleak. The AAA was repaired six weeks later using an endovascular bifurcated stent-graft system (Talent, Medtronic). It was inserted through the common femoral arteries after surgical exposure. No endoleak was detected at intraoperative angiography. A follow-up CT scan three months later showed no evidence of endoleak in either DTAA or AAA.

DISCUSSION

The coexistence of a DTAA in patients with AAA continues to pose problems in relation to the type of repair employed, and the option of simultaneous or sequential repair. Conventional open repair of the thoracic aneurysm carries a high rate of morbidity and mortality. Many of these patients have significant co-morbidity, rendering them ineligible for such open repair.¹

The endovascular stent-graft was initially introduced for the repair of abdominal aortic aneurysm. In 1992, Dake *et al* reported the use of an endovascular stent-graft for the repair of DTAA.² With recent widespread use, the feasibility of this less invasive surgical alternative is now well established, despite the uncertainties over its long-term durability. The repair of synchronous aneurysms of the descending thoracic aorta and the abdominal aorta can be carried out simultaneously, or sequentially, with an interval of a few weeks. In sequential repair, although each operative episode is shorter, a small risk of rupture of the remaining aneurysm exists in the inter-operative period.¹ In asymptomatic patients, the DTAA which is considered the 'greater of the two evils' is stented first.

Paraplegia is a known complication with both conventional and endovascular repair of DTAA. However, in endovascular repair, the incidence of paraparesis is less than in conventional repair.^{2,3} Endovascular repair of DTAA, even in the presence of severe co-morbid conditions, has been shown to be associated with good immediate results and low morbidity and mortality.²

The reported numbers of patients with combined repair of DTAA and AAA is small,⁴ but favourable results have so far been reported when endovascular repair is utilized for one or both aneurysms.^{1,4,5} The above three cases support the

technical feasibility of treating these patients with endovascular repair of at least the thoracic component. The long-term durability of the thoracic stent-graft system for the exclusion of the aneurysm is yet to be established. However, endovascular repair provides an option of treating patients with multilevel aortic aneurysm, even in those who are otherwise unfit for conventional thoracic surgery. The availability of endovascular stenting should therefore increase the number of patients with DTAA and AAA that will be suitable for surgical intervention.

REFERENCES

1. Moon MR, Mitchell RS, Dake MD, Zarins CK, Fann JJ, *et al*. Simultaneous abdominal aortic replacement and thoracic stent-graft placement for multilevel aortic disease. *J Vasc Surg* 1997; **25**(2): 332-40.
2. Dake MD, Miller DC, Semba CP, Mitchell RS, Walker PJ, Liddell RP. Transluminal placement of endovascular stent-grafts for the treatment of descending thoracic aortic aneurysms. *N Eng J Med* 1994; **331**(26): 1729-34.
3. Umana JP, Mitchell RS. Endovascular treatment of aortic dissections and thoracic aortic aneurysms. *Semin Vasc Surg* 2000; **13**(4): 290-8.
4. Cohnert TU, Chavan A, Wahlers T, Oelert F, Karck M, Galanski M, *et al*. Simultaneous treatment of thoracic and infrarenal aortic aneurysm using a combination of conventional surgery and endoluminal stent-grafting. *Langenbecks Arch Surg* 2000; **385**(1): 27-30.
5. Wolf YG, Zarins CK, Rubin GD, Fogarty TJ. Concomitant endovascular repair of descending thoracic and abdominal aortic aneurysm. *Circulation* 2000; **102**(6): E36.