

Received: 2018.06.27  
Accepted: 2018.09.11  
Published: 2019.01.05

# Long-Term Clinical Outcomes of Complicated Retrievable Inferior Vena Cava Filter for Deep Venous Thrombosis Patients: Safety and Effectiveness

Authors' Contribution:

Study Design A  
Data Collection B  
Statistical Analysis C  
Data Interpretation D  
Manuscript Preparation E  
Literature Search F  
Funds Collection G

AE 1 **Shiyuan Chen**  
BC 2 **Yong Gao**  
CD 3 **Wenbin Wang**  
CD 2 **Chaowen Yu**  
DF 2 **Wenbo Tang**  
F 2 **Xiaogao Wang**  
F 2 **Chao Xu**  
EG 1,3 **Aman Xu**

1 First Clinical Medical College of Anhui Medical University, Hefei, Anhui, P.R. China  
2 Department of Vascular Surgery, The First Affiliated Hospital of Bengbu Medical College, Bengbu, Anhui, P.R. China  
3 Department of General Surgery, The Fourth Affiliated Hospital of Anhui Medical University, Hefei, Anhui, P.R. China

**Corresponding Author:** Aman Xu; e-mail: sddhf56@yahoo.com

**Source of support:** This work was supported by grants from Major Projects of Education Department of Anhui, KJ2016SD38

**Background:** Inferior vena cava (IVC) filters have proven valuable for the prevention of pulmonary embolism. However, retrieval of IVC filters can be challenging and complicated techniques are needed. The aim of this study was to retrospectively review the outcomes after retrieval of retrievable IVC filters which required complicated retrieval techniques.





**Material/Methods:** This study was a single-center retrospective observational study. All patients who underwent complicated IVC filter retrieval from September 2012 to May 2016 were included. Patient demographics and filter retrieval procedure were documented. Clinical outcomes and procedure-related complications were evaluated. Villalta score and VEINES-QOL/Sym were recorded to assess post-thrombotic syndrome.

**Results:** A total of 79 consecutive patients, 37 males and 42 were female, with a mean age of 46.5 years (age range: 22–65 years) were included in this study. IVC filters, with mean indwell time of 108 days (range: 74–157 days), were refractory to standard treatment and underwent complicated IVC filter retrieval. There were 6 serious procedure-related complications: 4 popliteal puncture area hematoma complications and 2 hematuria complications. With a mean follow-up of 20.5 months (range: 18–24 months), no pulmonary embolisms occurred, and 2 patients experienced recurrent deep venous thrombosis. Twenty-seven patients developed post-thrombotic syndrome within the first 2 years after IVC retrieval.

**Conclusions:** Complicated methods can be used to safely remove IVC filters, alleviate filter-related morbidity, and reduce risk for post-thrombotic syndrome. The application of these techniques was safe and effective for patients with refractory IVC filters.

**MeSH Keywords:** **Outcome Assessment (Health Care) • Pulmonary Embolism • Venous Thrombosis**

**Full-text PDF:** <https://www.medscimonit.com/abstract/index/idArt/911813>

 2498  4  2  25



## Background

Venous thromboembolism (VTE), consisting of deep venous thrombosis (DVT) and pulmonary embolism (PE), is one of the major causes of morbidity and mortality [1]. Standard treatment for VTE is anticoagulation, consisting of parenteral agents such as low-molecular-weight heparin (LMWH) and unfractionated heparin (UFH). However, anticoagulation is contraindicated in patients who underwent complex surgery or who had hemorrhagic stroke or advanced liver diseases. For these patients, inferior vena cava (IVC) filters are an alternative option, especially in high-risk patients who are unable to receive pharmacological prophylaxis.

IVC filters have been in clinical use since 1970s and have gained acceptance for the prevention of PE arising from DVT of the lower extremity. IVC filters have been designed, since then, to be left in place permanently within the inferior vena cava. However, permanent filters reduced the frequency of PE at the cost of increased risk of complications such as recurrent DVT, venous stasis disease and IVC thrombosis with no reduction in mortality [2,3]. To avoid these side effects of long-term filter placement, retrievable IVC filters have been available since the late 1990s. Their use has become commonplace, and the numbers implanted increase annually.

However, in August 2010 the United States Food and Drug Administration (FDA) released a safety alert recommending physicians and clinicians consider removing the filters as soon as protection from PE is no longer needed [4]. With this growing awareness and responsibility, filter retrieval rates increased during last few years from 29% to 60%. A previous study reported that the successful retrieval rate for a retrievable filter was 70% to 100% [5]. However, some filters are refractory to routine retrieval methods due to filter fracture, or embedded or IVC thrombosis, thus require complex retrieve methods. These patients have an associated increased risk of filter-related complications. In addition, although some studies have investigated the outcomes of patients with IVC filters [6,7], very little reliable data on the long-term efficacy and safety of complicated retrievable filters are available.

Here, 79 patients who underwent complicated IVC filter retrieve were enrolled in this retrospective study. The aim of our study was to evaluate long-term safety and efficacy.

## Material and Methods

### Patients

We reviewed medical records of all patients who received filter retrieval in our center from September 2012 to May 2016.

Our study was approved by the institutional review board of the First Affiliated Hospital to Bengbu Medical College. The study included 79 consecutive patients with previously implanted IVC filters, who underwent attempted filter retrieval procedures in regional hospitals. Criteria for study inclusions were: patients diagnosed with DVT of the low extremity who had received retrievable IVC filters, failure of attempted filter retrieval with routine retrieval methods, and finally receiving complex retrieval techniques. We considered complex retrievals as those in which the usual attempts had failed, the filter had a significant tilt, the filter hook had made contact with the wall of the IVC, or additional maneuvers were required aside from conventional snaring. The following exclusion criteria were applied: permanent IVC filter placement, contraindication for anticoagulation or thrombolytic agents, factor V gene Leiden mutation, elevated levels of factor VIII and the presence of the prothrombin G20210A mutation, in combination of malignant tumor, life expectancy of 1 year or less. In this study, we excluded patients with contraindications for anticoagulation since we aimed to evaluate the long-term outcomes including frequency of post-thrombotic syndrome (PTS) and anticoagulation was related to the occurrence of the PTS in patients with DVT according to previous studies [8,9].

### IVC filter placements and retrievals

IVC filter placement and retrieval procedure reports were reviewed for filter type, venous access site(s), filter retrieval technique(s), and post-procedural complications. Indications for filter placement were prophylactic for increased risk of thromboembolic disease. IVC filter placement was performed as described previously [10]. Alternative techniques were then implemented to address each refractory filter. All complex retrievals were performed under fluoroscopic guidance using the following techniques. 1) Bidirectional pull-back technique was applied to free strut-embedded filter using guidewires to pass through a guiding catheter, then both wires are snared and exteriorized through the opposing respective sheaths to rock the filter free from the caval wall. 2) Rigid endobronchial forceps were used in cases in which the filter was densely embedded in the IVC wall. With rigid bronchoscopy forceps, the tissue surrounding the filter tip would be dissected. 3) Stiff wire-displacement technique was performed to reorient a filter with significant tilt by passing a stiff wire between the filter apex and cava wall. 4) Balloon-displacement technique used angioplasty balloon and curved-tip guiding catheter to displace the filter from the caval wall. 5) Sling technique used wire loop to capture the apex of filter and 2 sheaths to contract refractory filter. Our general algorithmic approach to filter retrieval was to attempted filter retrieval by routine technique, and then attempted retrieval by complex techniques only if routine technique failed. When necessary, pre-procedure thrombolysis of acute IVC thrombus was performed using overnight

infusion of urokinase. After retrieval, all patients continued therapeutic anticoagulation for at least 1 year under guidance of international normalized ratio (INR). All the patients were recommended to wear compression stockings (class II 30–40 mmHg) as standard adjunctive treatment.

**Follow-up and outcome measures**

Clinical follow-up was scheduled in the Outpatient Department by venography or duplex ultrasound after 3 months, 6 months, 12 months, 18 months, and 2 years. Villalta score and Venous Insufficiency Epidemiological and Economic Study-Quality of Life (VEINES-QOL) and Severity of Venous Lower Limb Symptoms (VEINES-Sym) were obtained to assess quality of life after treatment and to obtain possible evidence of PST. Symptoms and signs of PTS were assessed using the Villalta scale, which grades the severity of each of 5 symptoms (pain, cramps, heaviness, pruritus, and paresthesia) and 6 signs (edema, skin induration, hyperpigmentation, venous ectasia, redness, and pain during calf compression) from 0 (absent) to 3 (severe). The VEINES-QOL summary score (25 items) provides an estimate of the overall impact on the patient’s quality of life. The VEINES-Sym summary score (10 items) is a validated subscale of the VEINES-QOL that measures venous symptom severity. A recurrence of VTE was defined as a composite of symptomatic, objectively confirmed DVT, nonfatal PE, or fatal PE.

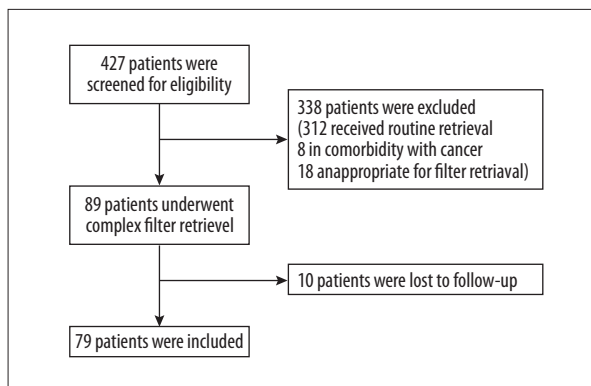
**Statistical analyses**

Descriptive results are presented as mean ±SD and ranges, and discrete outcomes are presented as percentages. The recruitment of all patients was planned to obtain data on filter retrieval procedures. Adverse clinical events occurring at the time of device retrieval, and up to 2 years after retrieval, whether or not device-related, were recorded.

**Results**

**Patient characteristics**

A total of 427 patients were identified with confirmed VTE during the study period. After the exclusion of 312 patients who received routine filter retrieval, 8 patients with comorbidity with malignant cancer, and 18 patients who were inappropriate for filter retrieval, a total of 89 patients underwent complex filter retrieval after routine attempt failed. Ten patients were lost to follow-up. Finally, our study consisted of 79 patients. The disposition of the study participants is shown in Figure 1. Of these 79 patients, 37 were male and 42 were female. Mean age at diagnosis of DVT was 46.5 years (age range: 22–65 years). Median duration of symptoms before diagnosis of DVT was 4.5 days. Thrombosis was located on the right side



**Figure 1.** Patient flow diagram.

**Table 1.** Clinical characteristics of patients.

Characteristic	
Age (mean, range, years)	46.5, 22–65
Gender (male,%)	37 (46.7)
Duration of symptoms before diagnosis (mean, days)	4.5
Side of DVT (%)	
Right	30 (37.9)
Left	47 (59.6)
Bilateral	2 (2.5)
Localization of DVT (%)	
Popliteal vein	41 (51.9)
Femoral and iliac vein	38 (48.1)
Risk factors (%)	
Recent major surgery	16 (20.2)
Immobilization	13 (16.5)
Hormonal replacement therapy	11 (13.9)
Oral contraceptive use	4 (5.1)
Spontaneous	35 (44.3)

DVT – deep venous thrombosis.

in 30 patients, on the left side in 47 patients, and bilateral in 2 patients. Risk factors for DVT included recent major surgery, immobilization, hormonal replacement therapy, and oral anti-contraceptive use. Patient characteristics of the 79 patients are summarized in Table 1.

**IVC filter placement and retrievals**

The IVC filters were implanted in all of the 79 patients diagnosed with DVT. IVC filters were placed for patients with a high

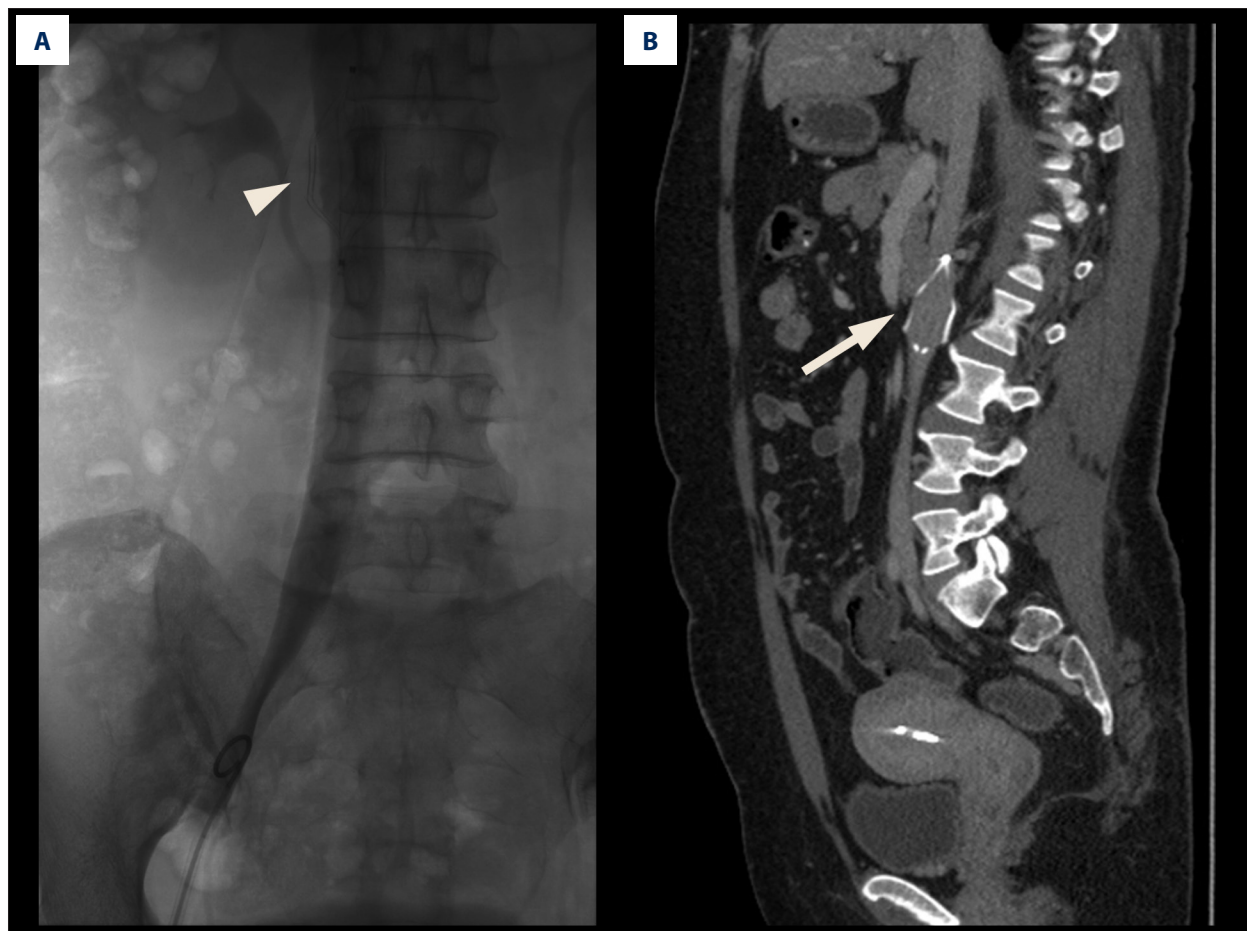
**Table 2.** Clinical data for IVC filter placement.

Parameter		
Location of filter apex (%)		
L1/L2 vertebrate	12	(15.2)
L2/L3 vertebrate	67	(84.8)
IVC diameter (mean $\pm$ SD, range, mm)	21.5 $\pm$ 6.7 (14.2–28.6)	
Filter type (%)		
OptEase	46	(58.2)
Aegisy	33	(41.8)
Indwell time (mean, range, days)	108 (74–157)	

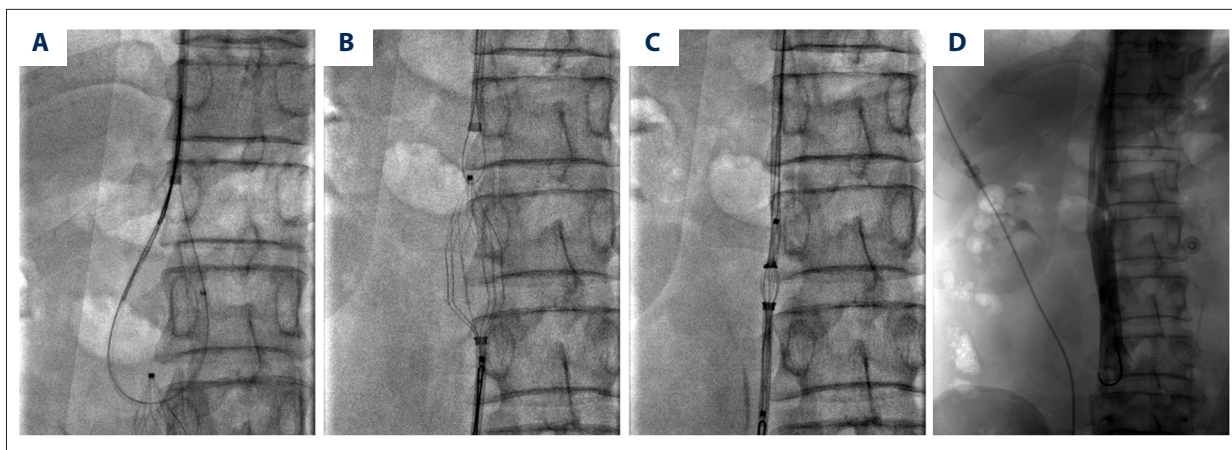
IVC – inferior vena cava; SD – standard deviation.

risk of PE. All IVC filter implantation were successful without intraoperative complications. Sixty-seven patients had the filter apex located at the level of L2/L3 vertebrate. The mean IVC diameter at the site of filter placement was 21.5 $\pm$ 6.7 mm

(range, 14.2–28.6 mm). IVC filter type included OptEase (Cordis, Warren, USA) and Aegisy (LifeTech, Shenzhen, China). They all have a “double-basket” trapezoidal shape, which is similar to the permanent TrapEase filter with the exception of a fixation hooks. All the patients underwent attempted filter retrieval with routine methods, which use a goose neck snare to capture the hooks, but routine retrieval methods failed. The details including indwell time and filter types are summarized in Table 2. Intraoperative venography or preoperative computed tomography revealed that neither filter tilting, migration, nor penetration of the caval wall occurred (Figure 2). The mean indwell time was 108 days (range, 74–157 days). Patients wished to avoid filter-related complications and the filter was medically no longer need before retrieval. The following complex retrieval techniques were used: bidirectional pull-back technique in 23 patients, rigid endobronchial forceps technique in 8 patients, stiff wire-displacement technique in 24 patients, balloon-displacement technique in 12 patients, and sling technique in 12 patients (Figure 3). Mean retrieval time was 26.5 $\pm$ 7.5 minutes and mean fluoroscopy time was 10.2 $\pm$ 4.5 minutes. Mean contrast medium use was 42.3 $\pm$ 13.2 mL (Table 3). Complex filter



**Figure 2.** Inferior vena cava (IVC) filter tilting and penetration. (A) Intraoperative venography showed IVC filter tilting (arrow). (B) Preoperative computed tomography revealed filter penetration of the caval wall (arrow).



**Figure 3.** Sling technique for refractory inferior vena cava (IVC) filter. (A) A reverse-curve catheter was positioned below the filter apex and a snare was used to grasp the wire. Then a “sling” was created around the filter. (B) The other snare was approached to fix the caudal hook. (C) Two sheaths were advanced to the filter hooks and tractions were applied in opposite direction. (D) Post-operative venography revealed successful removal of IVC filter.

**Table 3.** Clinical data for IVC filter retrieval.

Parameter	
Technique (%)	
Bidirectional pull-back	23 (29.1)
Rigid endobronchial forceps	8 (10.1)
Stiff wire-displacement	24 (30.4)
Balloon-displacement	12 (15.2)
Sling technique	12 (15.2)
Retrieval time (mean ±SD, min)	26.5±7.5
Fluoroscopy time (mean ±SD, min)	10.2±4.5
Contrast medium use (mean ±SD, ml)	42.3±13.2
Venous access (%)	
Femoral vein	31 (39.2)
Jugular and femoral vein	48 (60.8)

IVC – inferior vena cava; SD – standard deviation.

retrieval was successful in all 79 cases (100%). After filter retrieval, all the patients received anticoagulation (LMWH) and physical therapy (compression stocking) for at least 1 year.

**Outcome measures**

During the period of retrieval procedures, no procedure-related complications happened. Immediate post-procedure venography showed a mild stenosis at the attachment site in 2 patients. One patient who complained of mild back pain acquired complete resolution of pain after filter removal. Hematoma occurred in 4 popliteal puncture areas and hematuria in 2 patients.

Of note is that 3 out of 4 hematomas came from the use of rigid endobronchial forceps. Although statistical significance of the higher complication rate associated with rigid forceps compared with other complex techniques was not investigated by our study, we believe that caution should be exercised when considering use of this technique. Mean duration of hospital stays was 5.5±2.5 days. No other complications were observed in all patients before discharged from hospital.

Mean follow-up duration was 20.5 months (range: 18–24 months). Two patients experienced recurrent DVT and underwent thrombolytic treatment during follow-up. No PE occurred during this period. Since all patients enrolled in our study were confirmed with DVT, we evaluated the presence of PTS during follow-up. Table 4 lists the change in mean Villalta score and VEINES-QOL/Sym score. According to our data, 11 patients developed PTS at 1 year and 16 patients developed PTS at 2 years. The frequency without PTS at 1 year and 2 years were 86.1% and 79.7%, respectively.

**Discussion**

The efficacy of IVC filter in preventing PE was first confirmed by the PREPIC study group [11]. Several following studies demonstrated that IVC filter placement could prevent PE in selected patients with VTE and in patients at high risk for the development of DVT and PE who were contraindicated to anticoagulation [12,13]. A study by Thery et al. [14] included 132 patients and observed lysing of a clot by thrombolytic agent within the filter in 41 patients. These results might reveal that the filter could prevent PE. However, some other research reports are not in accordance with this conclusion. In these studies, the authors claimed that the prophylactic use

**Table 4.** Outcome measures during follow-up.

Measure	Time point				
	3 months	6 months	12 months	18 months	24 months
Villalta score	6.37±2.11	6.02±1.58	5.73±1.72	5.15±1.92	4.94±1.68
VEINES-QOL	44.51±8.79	47.79±7.02	49.25±9.22	50.25±6.35	51.02±5.37
VEINES-Sym	43.22±5.28	46.57±5.89	47.95±7.37	49.29±5.32	50.32±6.32

of an IVC filter is unnecessary because of the low rate of PE. For example, Bjarnason et al. [15] found that only 2 out of 214 DVT patients developing PE. In our study, all the patients were diagnosed with DVT and received an IVC filter. We also found that more than half of these patients underwent major surgery, and immobilization or hormonal medicine before venous embolization, which are considered risk factors for VTE. Thus, all the patients in our study received prophylactic use of filter implantation.

In parallel with the increase of IVC filter usage, the complications of filters have become increasingly evident [16,17]. Sella et al. [18] reported complications of IVC including IVC penetration, filter embolization and movement, IVC occlusion, and so on. Despite numerous studies on complications related to IVC filter, only a minority of retrievable filters placed have actually been removed. Several publications described a broad range of retrieval rates from 1.0% to 40.5% [19–21]. During the past few years, heightened awareness for closer follow-up and removal of implanted devices have been acceptable for physicians and public, however, many filters cannot be removed by using routine methods. For that reason, some complex approaches to filter retrieval have been discussed [22,23]. Among these approaches are: realignment techniques, stiff wire-displacement techniques, dual-access techniques, and so on. In our study, we applied bidirectional pull-back technique, rigid endobronchial forceps, stiff wire-displacement technique, balloon-displacement technique, and sling technique. The choice of which advanced technique to use was operator-dependent determined by individual operators. Of note was that 3 out of 4 hematomas came from the use of rigid endobronchial forceps, thus we believed that caution should be exercised when considering use of this technique. In addition, clinicians should take the type of filter into consideration when perform complicated technique. According to our experience, fractured filters were more common with conical-shaped filter. All the patients included in our studies received trapezoidal shape filters, which is inserted and removed more safely with a high degree of technical success.

Although many studies have reported the outcomes of patients with an IVC filter, seldom does research pay attention to the outcomes of complicated retrievable IVC filter DVT patients. To the best of our knowledge, this is the first report implicating the long-term clinical outcomes of patients underwent complicated retrievable IVC filter. In our study, no patients experienced symptomatic PE after filter insertion, which reconfirmed the effectiveness of IVC filter. However, 2 patients experienced recurrent DVT and the incidence of recurrent DVT was 2.5%. A study by Charles et al. [7] included 179 patients who underwent standard retrieval treatment and reported the incidence rate of PE was 0.5%. Another study documented 1 patient (1%) developed recurrent PE and required lifelong anticoagulation. Compared to those patients who received standard filter retrieval methods, the complication rate was acceptable in our study. In addition, in our study, although the mean retrieval time showed a comparatively longer time compared with previous studies, the increased time did not lead to higher incidence of complications. Besides, since IVC filter was related to an increased risk of PTS, we evaluated the incidence of PTS in our study. Our results showed that 27 patients developed PTS. The frequency without PTS at 1 year and 2 years were 86.1% and 79.7%, respectively. Several studies have shown that PTS developed in up to almost half of the patients with DVT within the first 2 years [24]. Chow et al. [25] demonstrated that the incidence of post-filter PTS was 44.6%. Our study revealed that removal of IVC filter contributed to reduction of PTS.

## Conclusions

The present study evaluated the clinical outcomes following complex IVC filter retrieval. Our results revealed the efficacy and safety of complicated IVC filter retrieval methods. However, to ameliorate analysis of risk of complicated IVC filter retrieval, a prospective randomized trial or cohort study is needed.

## References:

- White RH: The epidemiology of venous thromboembolism. *Circulation*, 2003; 107(23 Suppl.1): 14–8.
- PREPIC Study Group: Eight-year follow-up of patients with permanent vena cava filters in the prevention of pulmonary embolism: The PREPIC (Prevention du Risque d'Embolie Pulmonaire par Interruption Cave) randomized study. *Circulation*, 2005; 112: 416–22
- Tardy B, Mismetti P, Page Y et al: Symptomatic inferior vena cava filter thrombosis: clinical study of 30 consecutive cases. *Eur Respir J*, 1996; 9: 2012–16
- Alerts FJM, March MB: Notices (Medical Devices) 8/9/2010: Accessed at: <http://www.fda.gov/MedicalDevices/Safety/AlertsandNotices/ucm221676.htm> 11: 26 AM Abstract No. 57 Modified loop snare technique for the removal of Bard Recovery, G2, G2 Express and Eclipse inferior vena cava filters F. Lynch; Penn State Hershey Medical Center, Hershey, PA Purpose: This work describes a novel technique for the removal of tilted and apex embedded Bard Recovery, G2, G2 Express and Eclipse inferior vena cava filters (IVCFs)(Bard Peripheral Vascular Tempe AZ), 2009
- Stein PD, Matta F, Hull RD: Increasing use of vena cava filters for prevention of pulmonary embolism. *Am J Med*, 2011; 124: 655–61
- Mismetti P, Laporte S, Pellerin O et al: Effect of a retrievable inferior vena cava filter plus anticoagulation vs. anticoagulation alone on risk of recurrent pulmonary embolism: A randomized clinical trial. *JAMA*, 2015; 313: 1627–35
- Ray CE, Mitchell E, Zipser S et al: Outcomes with retrievable inferior vena cava filters: A multicenter study. *J Vasc Interv Radiol*, 2006; 17: 1595–604
- Dongen CJJ, Prandoni P, Frulla M et al: Relation between quality of anticoagulant treatment and the development of the postthrombotic syndrome. *J Thromb Haemost*, 2005; 3: 939–42
- Chitsike RS, Rodger MA, Kovacs MJ et al: Risk of post-thrombotic syndrome after subtherapeutic warfarin anticoagulation for a first unprovoked deep vein thrombosis: Results from the REVERSE study. *J Thromb Haemost*, 2012; 10: 2039–44
- Oliva VL, Szatmari F, Giroux M-F et al: The Jonas study: Evaluation of the retrievability of the Cordis OptEase inferior vena cava filter. *J Vasc Interv Radiol*, 2005; 16: 1439–45
- Decousus H, Leizorovicz A, Parent F et al: A clinical trial of vena caval filters in the prevention of pulmonary embolism in patients with proximal deep-vein thrombosis. *New Engl J Med*, 1998; 338: 409–15
- Spencer FA, Bates SM, Goldberg RJ et al: A population-based study of inferior vena cava filters in patients with acute venous thromboembolism. *Arch Intern Med*, 2010; 170: 1456–62
- White RH, Zhou H, Kim J, Romano PS: A population-based study of the effectiveness of inferior vena cava filter use among patients with venous thromboembolism. *Arch Intern Med*, 2000; 160: 2033–41
- Théry C, Bauchart JJ, Lesenne M et al: Predictive factors of effectiveness of streptokinase in deep venous thrombosis. *Am J Cardiol*, 1992; 69: 117–22
- Bjarnason H, Kruse JR, Asinger DA et al: Iliofemoral deep venous thrombosis: Safety and efficacy outcome during 5 years of catheter-directed thrombolytic therapy. *J Vasc Interv Radiol*, 1997; 8: 405–18
- Wang W, Spain J, Tam MD: Acute abdominal pain after retrievable inferior vena cava filter insertion: Case report of caval perforation by an option filter. *Cardiovasc Intervent Radiol*, 2011; 34: 883–85
- Hajduk B, Tomkowski WZ, Małek G, Davidson BL: Vena cava filter occlusion and venous thromboembolism risk in persistently anticoagulated patients: A prospective, observational cohort study. *Chest*, 2010; 137: 877–82
- Sella DM, Oldenburg WA: Complications of inferior vena cava filters. *Semin Vasc Surg*, 2013; 26: 23–28
- Janjua M, Younas F, Moinuddin I et al: Outcomes with retrievable inferior vena cava filters. *J Invasive Cardiol*, 2010; 22: 235–39
- Helling TS, Kaswan S, Miller SL, Tretter JF: Practice patterns in the use of retrievable inferior vena cava filters in a trauma population: A single-center experience. *J Trauma*, 2009; 67: 1293–96
- Kalva SP, Marentis TC, Yeddula K et al: Long-term safety and effectiveness of the “OptEase” vena cava filter. *Cardiovasc Intervent Radiol*, 2011; 34: 331–37
- Iliescu B, Haskal ZJ: Advanced techniques for removal of retrievable inferior vena cava filters. *Cardiovasc Intervent Radiol*, 2012; 35: 741–50
- Kuo WT, Robertson SW, Odegaard JJ, Hofmann LV: Complex retrieval of fractured, embedded, and penetrating inferior vena cava filters: A prospective study with histologic and electron microscopic analysis. *J Vasc Intervent Radiol*, 2013; 24: 622–30.e1
- Kahn SR, Shrier I, Julian JA et al: Determinants and time course of the post-thrombotic syndrome after acute deep venous thrombosis. *Ann Intern Med*, 2008; 149: 698–707
- Chow FC-L, Chan Y-C, Cheung GC-Y, Cheng SW-K: Mid-and long-term outcome of patients with permanent inferior vena cava filters: A single center review. *Ann Vasc Surg*, 2015; 29: 985–94